

ALLOCENTRIC AND EGOCENTRIC SPATIAL IMPAIRMENTS IN A CASE OF TOPOGRAPHICAL DISORIENTATION

Thomas Nyffeler, Klemens Gutbrod, Tobias Pflugshaupt, Roman von Wartburg, Christian W. Hess and René M. Müri

(Perception and Eye Movement Laboratory, Department of Neurology, University Hospital, University of Berne, Switzerland)

ABSTRACT

We describe a patient with a topographical disorientation after a stroke of the right mediotemporooccipital lobe including the parahippocampal cortex (PHC). Clinical observations and neuropsychological testing reveal an impairment of allocentric spatial representations as well as impairments of visuospatial learning and memory. These findings are in accordance with the well-known function of the PHC in topographical disorientation. As a new finding, results from oculomotor tasks show additional impairments of the egocentric spatial coordinate frame suggesting that in topographical disorientation due to a lesion of the right mediotemporooccipital lobe not only allocentric but also egocentric visuospatial functions are disturbed.

Key words: oculomotor, egocentric, allocentric, topographical disorientation, parahippocampal cortex

INTRODUCTION

The ability to follow routes in previously unfamiliar environments is a complex behaviour. It depends on many cognitive abilities like attention, visual perception, and executive functions. Most of all, however, it depends on the encoding of spatial information that characterizes the route, i.e. route knowledge. Processing of topographical information may be conducted within an egocentric or allocentric coordinate frame (Aguirre and D'Esposito, 1999; Barrash et al., 2000). In the former, the location of an object is processed with reference to the retina, head, and to the body, in the latter the spatial relationship between objects of the environment is processed. It is generally accepted, that egocentric spatial representations may be formed in the right posterior parietal cortex (PPC) (Levine et al., 1985; Bisiach et al., 1993), whereas allocentric spatial processing depends on the integrity of the right parahippocampal cortex (PHC) (Epstein and Kanwisher, 1998; Epstein et al., 1999; Aguirre and D'Esposito, 1999; Barrash et al., 2000). Humans with lesions of either the PPC or the PHC may lose their ability to find their way within environments, a rare disorder called topographical disorientation (Levine et al., 1985; Bisiach et al., 1993; Bohbot et al., 1998; Luzzi et al., 2000; for a review see Aguirre and D'Esposito, 1999).

Patients with lesions of the PPC show deficits in way finding within previously familiar and novel environments, and are impaired in tasks needing an egocentric coordinate system. Hence, topographical disorientation is seen as a consequence of a spatial deficit based on egocentric coordinates (Aguirre and D'Esposito, 1999; Bisiach et al., 1993; Levine et al., 1985). In contrast, patients with a lesion of the

PHC show a topographical impairment that is confined mainly to novel environments as well as deficits in visuospatial tasks and spatial memory needing allocentric coordinates. Neuroimaging studies emphasize the critical role of the PHC in allocentric encoding of environments (Maguire et al., 1996; Aguirre and D'Esposito, 1999). In this context topographical disorientation is attributed to a selectively impaired acquisition and storage of novel topographical knowledge.

However, there is evidence that the PHC not only subserves allocentric visual processing. Neurophysiological studies in awake behaving monkeys describe, amongst other cell types, head direction and egocentric cells in the PHC (Rolls et al., 1997). Furthermore, in humans it has been shown in an oculomotor study that the PHC is involved in egocentric spatial memorization (Ploner et al., 2000). In the memory-guided saccade task, subjects have to memorize the spatial location of a target, and after a delay, a saccade towards the memorised location has to be performed. Compared to controls, patients with a lesion of the PHC showed a significant delay-dependent inaccuracy of contralateral memory-guided eye movements.

The aim of the present study was to analyse if in topographical disorientation due to a lesion of the PHC not only impairments of the allocentric but also egocentric coordinate frame could be demonstrated. We tested a patient with topographical disorientation due to an ischemic lesion of the right mediotemporooccipital lobe with impaired allocentric spatial representations by means of a comprehensive neuropsychological test battery and four different oculomotor paradigms. The advantage of studying eye movements is that the egocentric (i.e. retinotopic and craniotopic) coordinate frame may

be examined in a detailed way. The same oculomotor paradigms were chosen that are generally used to examine the egocentric reference frame controlled by the PPC (Pierrot-Deseilligny et al., 1991; Heide et al., 1995). First, the retinotopic coordinate frame, where a saccade is planned and executed on the basis of retinal information was analysed with the aforementioned paradigm of memory-guided saccades and the gap and overlap task.

In the gap task, the lateral visual target appears 200 ms after the central fixation point is switched off, whereas in the overlap task the central fixation point remains switched on during lateral target presentation. In patients with lesions of the egocentric coordinate frame due to a lesion of the PPC the amplitude of such reflexive visually-guided saccades is decreased. Furthermore, the latency i.e. the triggering of these saccades is delayed (Pierrot-Deseilligny et al., 1991). Second, the craniotopic coordinate frame, where saccadic programming is based on craniotopic information, was analysed with the double-step task. In the double-step task, subjects have to make two successive saccades in response to two successively flashed targets located in both hemifields. Since the targets are very rapidly flashed within the latency of the first saccade, the amplitude of the second saccade cannot be calculated in retinotopic coordinates. In patients with lesions of the craniotopic coordinate frame due to a lesion of the PPC the second saccade is inaccurate when the first saccade is directed into the lesional hemifield (Heide et al., 1995).

CASE REPORT

M.E., a 67 year-old right-handed man was on holiday when suddenly he developed acute

visual blurring, gait disturbances, and difficulty in orienting himself in the holiday apartment adjoining his wife's bedroom with his own. The next day he was referred to the neurological department for evaluation. The neurological examination revealed a left incomplete homonymous hemianopia and a slight left-sided hemiparesis. MRI showed a right posterior cerebral artery stroke with destruction of the parahippocampal gyrus, fusiform gyrus, lingual gyrus, and mediotemporooccipital gyrus.

CLINICAL OBSERVATIONS

As long as M.E. was an inpatient, he remained incapable of orienting himself. In the room he shared with five other patients, he had great difficulty finding his own bed, his wardrobe, and the toilets. He tried to manage these problems by relying on landmarks, names, and numbers. For example, he reported that he only could recognize his bed by reading his name on it (name and date of birth of the patients are noted on the bed frame) and by his own alarm clock on the bedside table. When asked to draw a map of the hospital room from memory he completely failed (Figure 1).

When walking in the ward alone he tried to cope by verbalizing the way: "When I go downstairs, I know that I have to turn right when I see the painting of the boy eating an apple...I always count the doors, the third is the one of the resident..." However, according to his wife he had no special problems orientating himself in well-known environments such as his apartment, where he had been living for 30 years. Moreover, he could draw a correct map of this apartment (Figure 2).

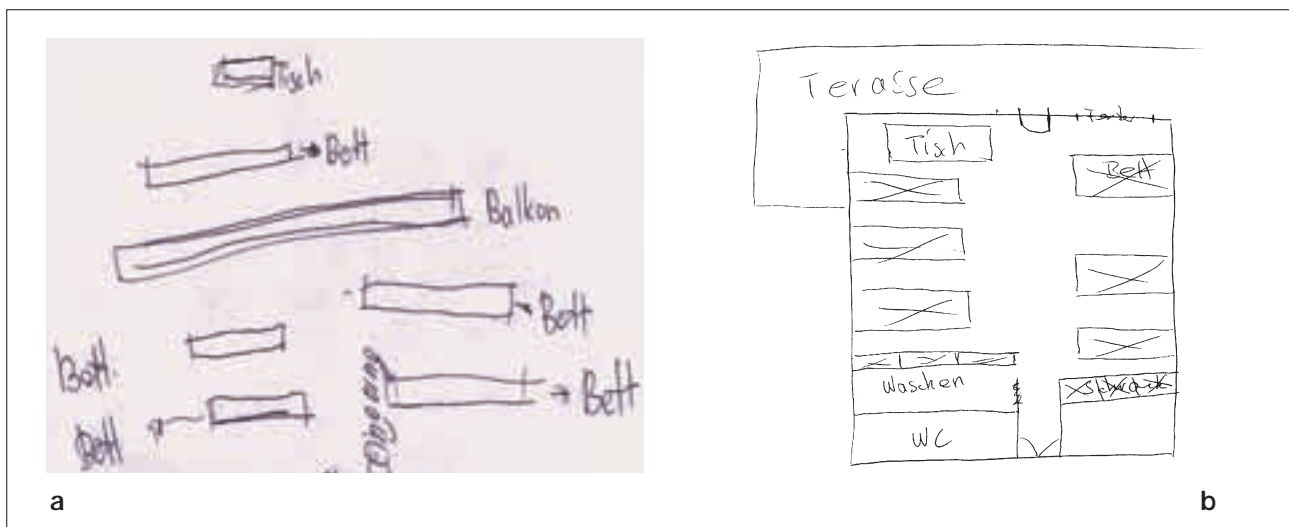


Fig. 1 – Drawings of the hospital room. a) The patient was asked to draw a map of the hospital room from memory. Although all elements (bed, table) are drawn, he completely failed to arrange them in an accurate manner. Furthermore, when asked to draw also the alignment of the walls and the balcony he was not able to. b) The same task is perfectly performed by a patient at the same age with a polyneuropathy who slept in the same room. (Translation: Tisch = table, Bett = bed, Balkon = balcony, Eingang = entrance, Terrasse = terrace, Waschen = lavatory, WC = toilet).

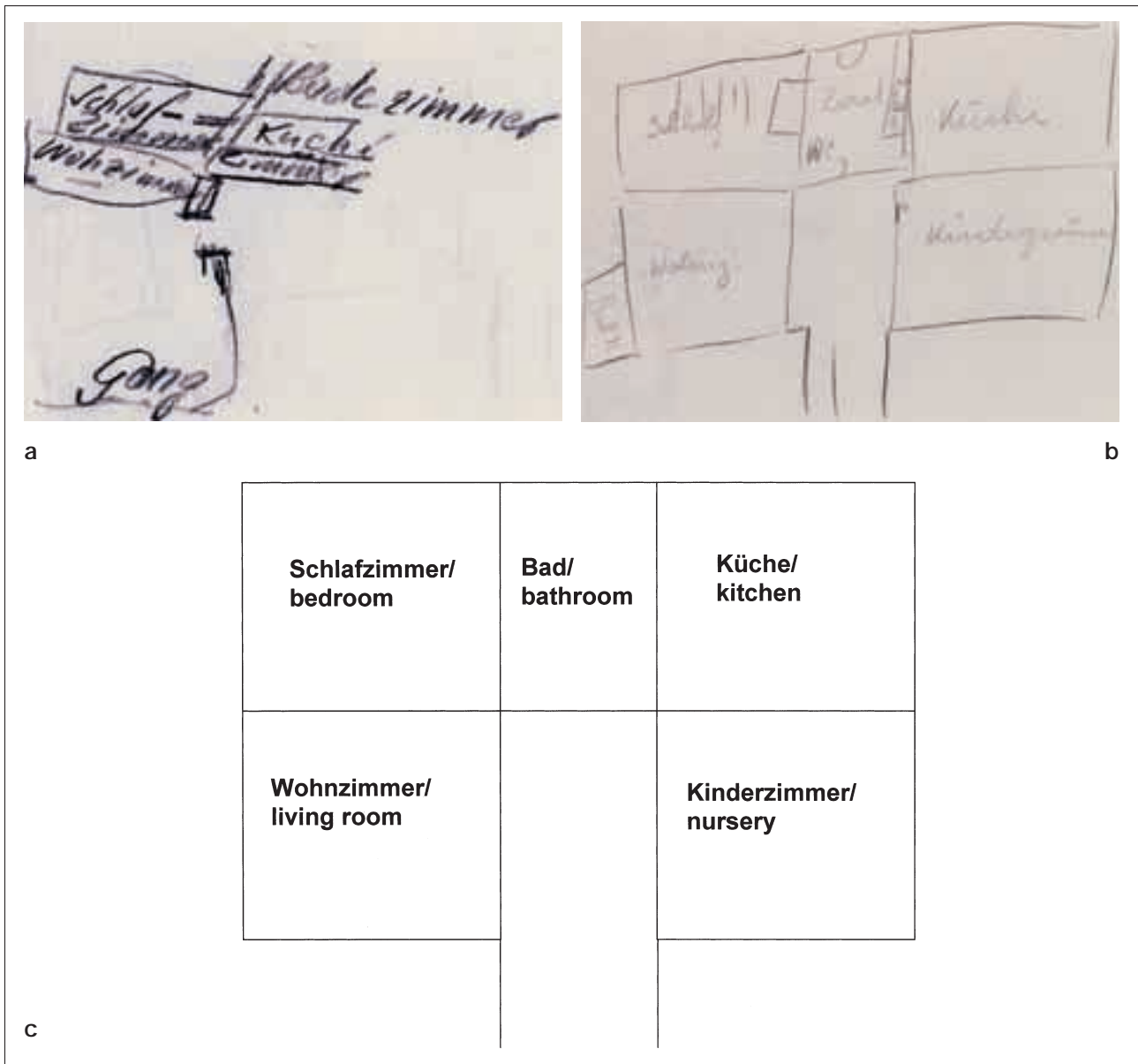

Fig. 2 – Drawings of the patient’s apartment. a) The patient was asked to draw a map of his apartment from memory where he had been living for 30 years. The floor plan is correctly drawn when comparing it with the drawing of his wife b) and illustrates the preserved topographical orientation in familiar buildings. Translations and a simplified plan of the apartment is shown in c).

One year after the ischemic stroke, the patient still had major problems orientating himself in novel environments. When he came to our hospital, he told us that he would have practically no problems when leaving his apartment and walking through the streets to the bus station which was about 500 metres away. However it was much more difficult for him to find his way from the bus station to the hospital. Also, when walking home after a meal out with friends from a restaurant he had never visited before, he got lost and had to ask the way.

NEUROPSYCHOLOGICAL ASSESSMENT

Scores with percentiles of neuropsychological tests are presented in Table I.

The main finding was a profound deficit in non-verbal, visuospatial learning, and memory. Although his immediate visual memory span was normal (low average) he showed severe deficits in non-verbal and visuospatial learning and recall of non-verbal designs (Rey Visual Design Learning) as well as a visuospatial trail (Ruff-Light Trail Learning Test). Normal values for performance were found in intelligence, orientation, language, arithmetic skills, praxis, executive functions, verbal learning and memory, and attention. There were no signs of agnosia or neglect. Basic as well as higher processes of visuoperceptual, visuospatial, and visuocognitive abilities were average to above average. Due to the left incomplete hemianopia speed of visual information processing was mildly impaired.

TABLE I
Scores of neuropsychological tests

Task / Reference	Score	Percentile
Intelligence		
• Vocabulary Intelligence Test (Lehrl et al., 1991); IQ	94	36
Orientation		
• Orientation questionnaire (von Cramon and Säring, 1982)		
Person (max. 5)	4	✓*
Place (max. 5)	4	✓
Situation (max. 5)	5	✓
Time (max. 5)	5	✓
Language		
• Token Test of the Aachen Aphasia Test (Huber et al., 1983); Errors (max. 50)	3	95
• Naming of the Aachen Aphasia Test (Huber et al., 1983); (max. 120)	113	97
Arithmetic Skills		
• Simple Calculations (Errors; max. 25)	2	✓
• Arithmetic of the Wechsler Adult Intelligence Scale-R (Tewes, 1991)	11	25
Praxis		
• Ideomotor (Errors; max. 5)	0	✓
• Limb Kinetic (Errors; max. 3)	0	✓
• Buccofacial (Errors; max. 3)	0	✓
Executive Functions		
• Word Fluency (Aschenbrenner et al., 2000); Correct	28	76
• Design Fluency (Haid et al., 2004); Correct	32	76
• Stroop Test (Spreen and Strauss, 1991)		
Part C: Seconds	25	24
Errors	0	100
• Wisconsin Card Sorting Test (Heaton, 1981)		
Categories achieved	5	30
Perseverative errors	13	46
Verbal Learning and Memory		
• Digit Span Forward (Härting et al., 2000)	6	24
• Auditory-Verbal Learning Test (Helmstaedter et al., 2001)		
Learning total	48	50
Delayed recall	9	24
Recognition	10	18
• Logical Memory of the Wechsler Memory Scale-R (Härting et al., 2000)		
Immediate recall	20	18
Delayed recall	25	82
Non-verbal Learning and Memory		
• Visual Memory Span Forward (Härting et al., 2000)	6	14
• Rey Visual Design Learning Test (Rey, 1964)		
Learning total	21	3
Delayed recall	3	< 1
Recognition	10	< 1
• Rey-Osterrieth Complex Figure Test: Delayed Recall (Meyers and Meyers, 1995)	6	2
• Ruff-Light Trail Learning Test (Ruff and Allen, 1999)		
Total correct (Trials 2-10)	71	< 1
Total step errors (Trials 2-10)	82	< 1
Delayed correct	9	< 1
Delayed errors	7	< 1
Visuoperceptual, Visuospatial, and Visuocunstructive Abilities; Agnosia		
• Birmingham Object Recognition Battery (Riddoch and Humphreys, 1993)		
Length match task (version B)	26/30	31
Size match task (version B)	29/30	74
Orientation match task (version B)	23/30	26
Position of gap match task (version B)	39/40	83
Overlapping figures (letters, shapes, drawings); in seconds : (all within normal limits of healthy controls)	-	
Minimal feature view task	24/25	61
Foreshortened view task	22/25	55
Object decision (version A; hard)	30/32	96
Item match task	32/32	85
• Rey-Osterrieth Complex Figure Test: Copy (Meyers and Meyers, 1995)	32	> 16
• Block Design of the Wechsler Adult Intelligence Scale-R (Tewes, 1991)	20	38
Neglect		
• Star cancellation (Wilson et al., 1987)	54/54	✓
Attention		
• Concentration Endurance d2 Test, (Brickenkamp, 1981; Spreen and Strauss, 1991)		
Total	378	54
Error Percentage	11	30
• Trail Making Test A (extended Version; Oswald and Roth, 1978); sec.	110	10

* = no deficit

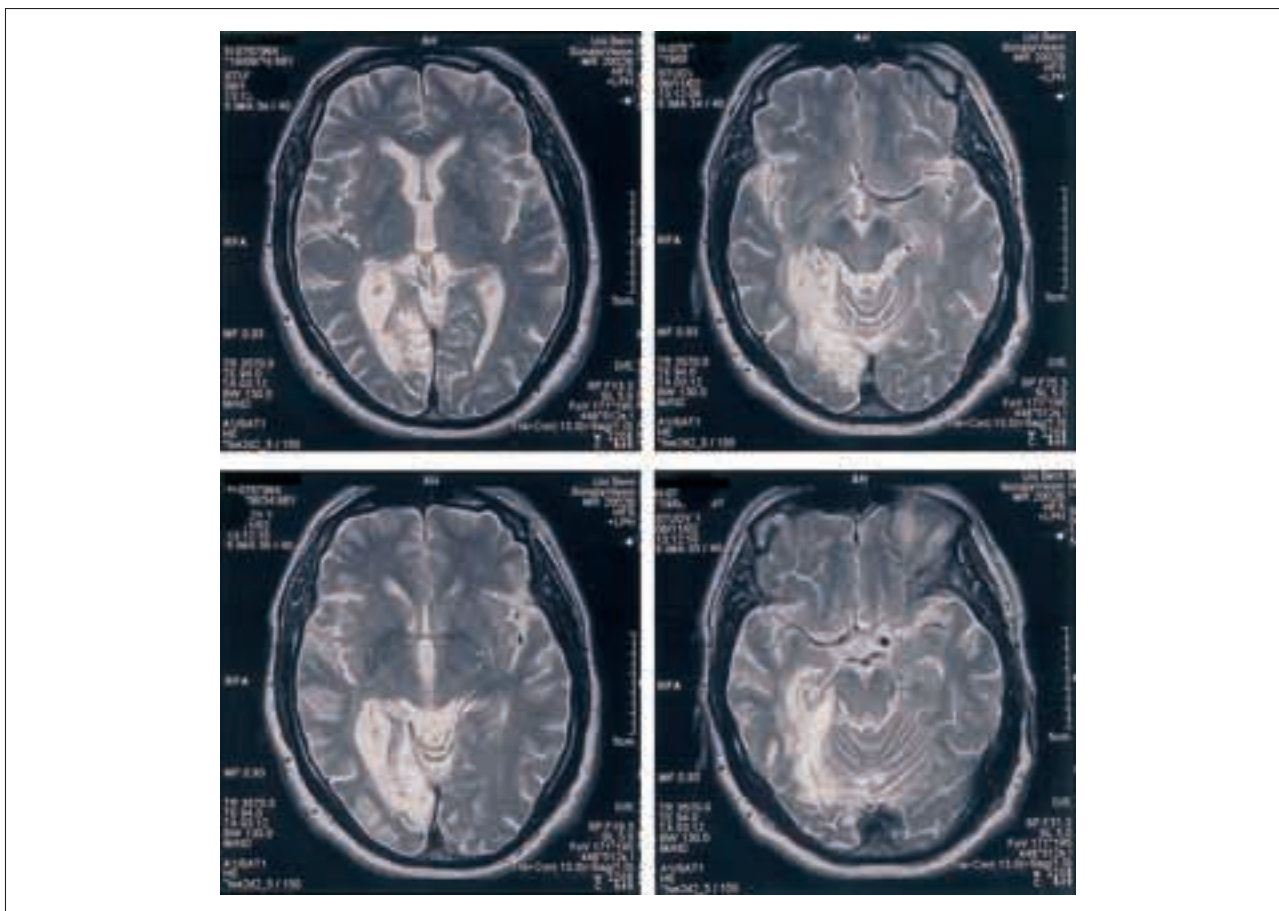


Fig. 3 – MRI scan showing axial cuts of the patient one year after the ischemic stroke. Areas of high signal are noticeable in the distribution of the right posterior cerebral artery involving the parahippocampal gyrus, fusiform gyrus, lingual gyrus and medial occipitotemporal gyrus.

OCULOMOTOR ASSESSMENT

The extent of the brain lesion at the time of examination is shown in Figure 3.

Ophthalmological assessment revealed a left incomplete homonymous hemianopia sparing 20° of central vision (Figure 4).

Four oculomotor paradigms were tested (Figure 5): 1) the gap task, 2) the overlap task, 3) the double-step task, and 4) the paradigm of memory-guided saccades with two different delays (figure 5).

During the experiment the patient was seated in total darkness 114 cm from a light emitting diodes (LED) target screen. Visual targets were bright LED. The head was fixed to avoid head movements. Eye movements were measured with an infrared corneal reflection device (Iris Skalar) (gap task, overlap task, double step task) with a spatial resolution of 0.1° and sample rate of 1000 Hz. Memory-guided saccades were acquired by means of dc-electro-oculography (bitemporal electrodes, sampling frequency 1000 Hz, bandwidth 0 – 100 Hz). Before each data acquisition, the eye movement recording device was calibrated. The signals were stored on the

computer for off-line analysis. The trials were presented in blocks of three or five, and the patient was always informed beforehand which condition will be tested. Pauses were made between the blocks.

The patient was examined in five sessions each lasting about 45 min. Due to the incomplete hemianopia, all visual targets were presented within 16 degrees eccentricity.

GAP AND OVERLAP TASK

In the gap task, the patient started to look at a central fixation point. After a random duration of between 1,5 and 2,5 sec the central fixation point was switched off and after another 200 msec, a horizontal, lateral target with a distance of 12° occurred (with unpredictable direction). The patient had then to perform a saccade to the lateral target. For each direction 40 trials were acquired. Median saccadic gain (saccade amplitude/target amplitude) and latency for each direction were calculated. The overlap task differed from the gap task by the fact that the central fixation point was switched continuously on.

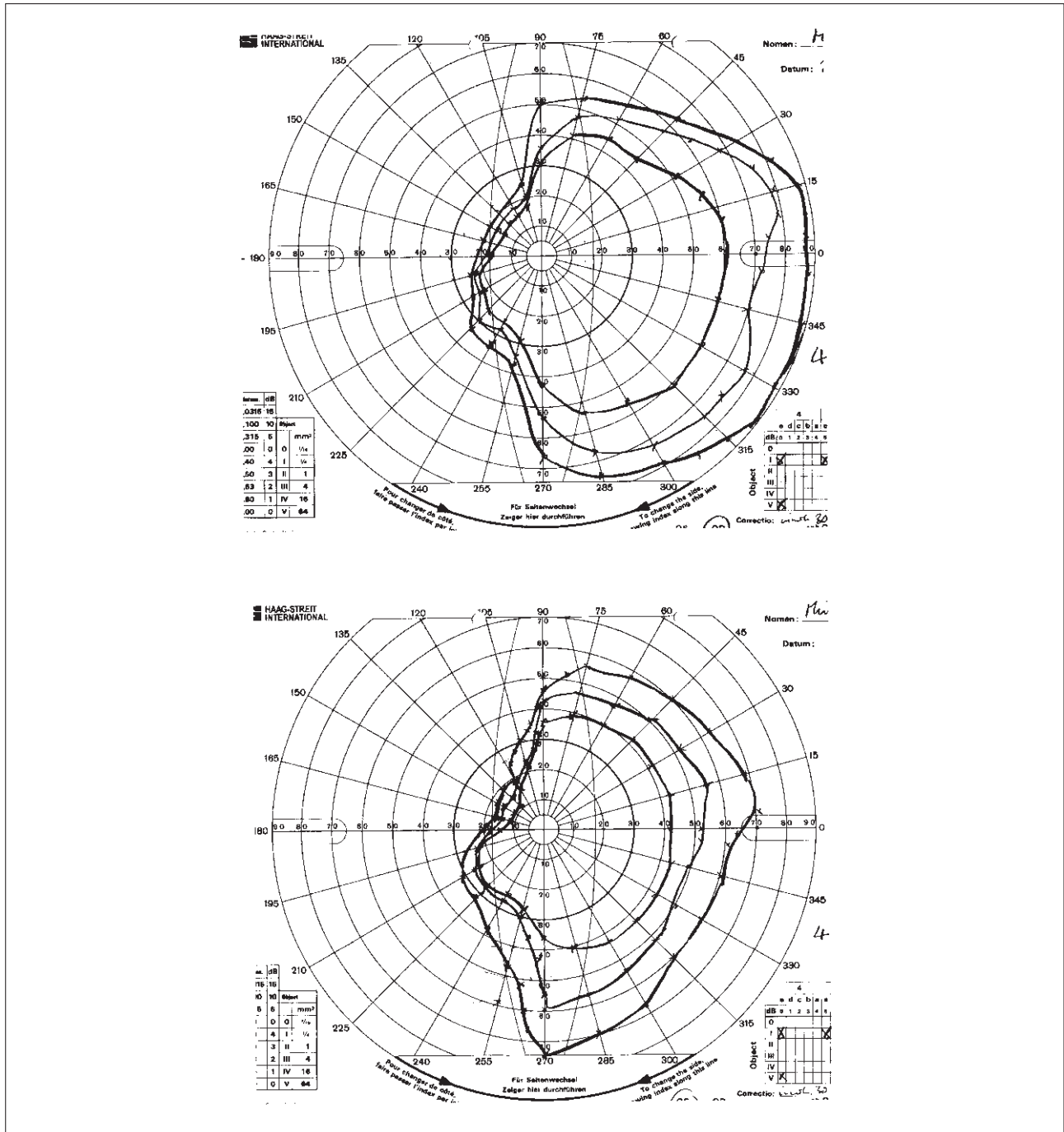


Fig. 4 – Goldmann perimetry is shown revealing a left incomplete homonymous hemianopia sparing central vision with 20°.

DOUBLE-STEP TASK

In the double-step task, the patient was instructed to make two successive saccades in response to two successively, flashed lateral targets. After the central fixation point was switched off a first lateral peripheral target appeared during 140 msec to the left or right of the center (ranging from 8 to 16 degrees), immediately followed by a second target presented for 100 msec in the opposite hemifield (ranging from 8 to 16 degrees). Thus, both targets

disappeared prior to the onset of the first saccade. The patient was always informed beforehand whether the first target would appear in either the left or the right hemifield. For each direction 40 trials were acquired. Data analysis was performed as described in a previous paper (Van Donkelaar and Müri, 2002). Using this paradigm it is possible to separate retinotopic and craniotopic coding of the saccade. Whereas the first saccade is done on the basis of retinal information, the second saccade relies on a craniotopic coordinate frame: as the retinal coordinates of the second

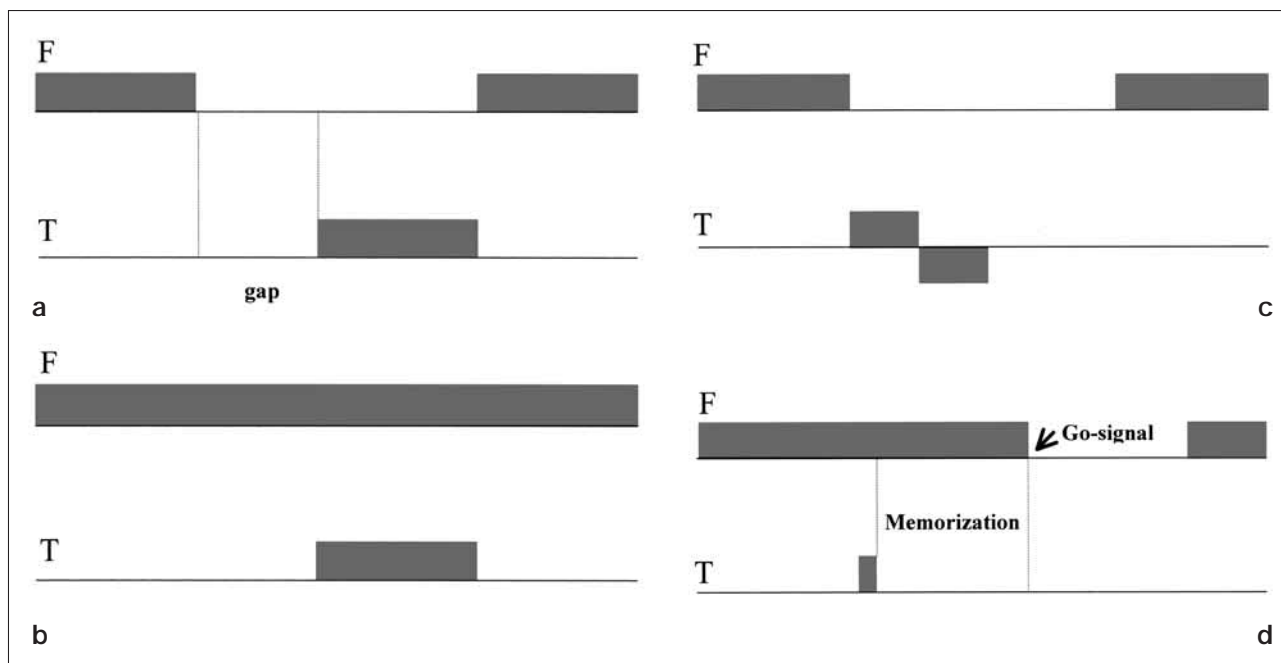


Fig. 5 – Oculomotor paradigms. a) gap task, in which the lateral target appears after the central fixation point is switched off 200 ms before; b) overlap task, in which the central fixation point remains switched on while the lateral target occurs; c) double-step task, in which the subject has to make two successive saccades in response to two successively flashed lateral targets; d) memory-guided saccade paradigm, in which a peripheral flashed target has to be memorized. After the go signal a memory-guided saccade has to be performed to the remembered position of the peripheral flashed target.

F = Fixation point (central), T = target (lateral).

target have changed after the first saccade, the brain must use a signal of eye displacement to update the retinal representation (Guthrie et al., 1983; Goldberg and Bruce, 1990; Duhamel et al., 1992; Hallett and Lightstone, 1976). Furthermore, the second saccade can compensate the error of the first saccade. However, if there is a failure of craniotopic coding no compensation occurs. To study these properties, linear regression was performed to analyse the relationship between the first saccade gain and the second saccade gain (Van Donkelaar and Müri, 2002).

PARADIGM OF MEMORY-GUIDED SACCADES

The patient was instructed to memorise the location of a horizontally flashed lateral target (with a non-predictive amplitude ranging from 8 to 16 degrees) while fixating a central point. The target was always flashed for 80 msec. After the memorisation delay (3 or 30 sec) the central fixation point was switched off, which was the go-signal for the patient to perform a saccade towards the memorised target. After another 2 sec, the target was shown again and the subject had to make a corrective saccade if necessary. For each delay condition and each direction 20 trials were performed, and the patient was always informed beforehand which condition would be tested. Percentage of error in amplitude (PEA) for each condition and direction was calculated. PEA was calculated according to the formula:

$$\frac{\text{saccade amplitude} - \text{target amplitude}}{\text{target amplitude}} \times 100$$

The statistical analysis was based on Mann-Whitney U Test, comparing leftward versus rightward saccades.

RESULTS

Gap task

There was no statistically significant difference in the latencies between leftward and rightward saccades (median latency for leftward saccades: 161 msec, interquartile range (IQR) 70; median latency for rightward saccades: 147 msec, IQR 30). The gain of leftward saccades was significantly decreased (hypometric saccades) compared to rightward saccades (median gain for rightward saccades 0.9, IQR 17; median gain for leftward saccades 0.83; IQR 0.24; $p = 0.004$).

Overlap task

The median latency was symmetric for both leftward and rightward saccades (median latency for leftward saccades: 317 msec, IQR 149; median latency for rightward saccades: 329 msec, IQR 130). The gain for leftward saccades was significantly decreased (hypometric saccades) compared to rightward saccades (median gain for rightward saccades 0.93, IQR 11; median gain for leftward saccades 0.8, IQR 0.16 ($p = 0.001$)).

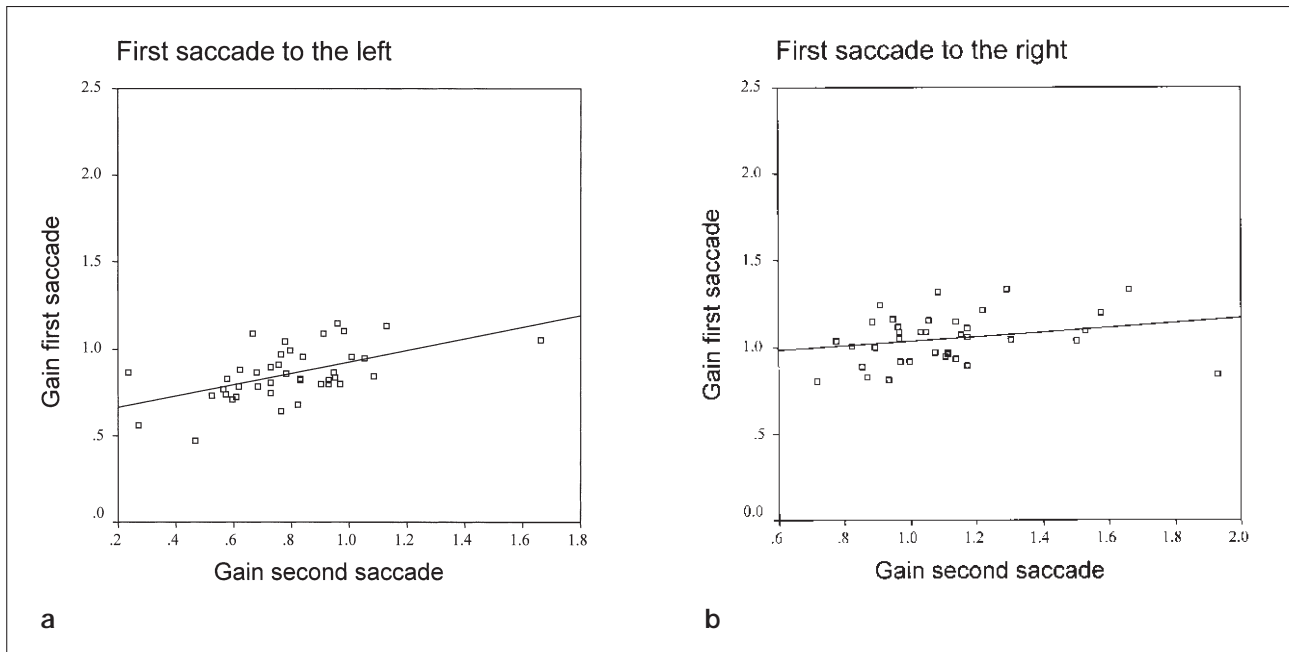


Fig.6 – The correlation between the first saccade gain and the second saccade gain in the double-step task.

Double-step task

The results from the analysis of the relationship between the first saccade gain and the second saccade gain are shown in Figure 6.

When the first saccade is made to the left the error of the first saccade can be compensated by the second saccade (Figure 6a) (Regression analysis: Beta 0.544; $p < 0.001$) i.e. a craniotopic coordinate frame was used to calculate the second saccade. However, when the first saccade is made to the right the error of the first saccade was not compensated suggesting a failure of the craniotopic updating process for the calculation of the second saccade (figure 6b) (Regression analysis: Beta 0.242; $p > 0.1$).

The gain of the second leftward saccades in the double-step paradigm furthermore shows a significant correlation with the gain of leftward saccades in the gap (Pearson correlation coefficient 0.717; $p < 0.001$) and overlap paradigm (Pearson correlation coefficient 0.845; $p < 0.001$).

Paradigm of memory-guided saccades

The median latencies were symmetric in both short and long delay paradigms (Short delay paradigm: median latency for leftward saccades 248 msec, IQR 85; median latency for rightward saccades 265 msec, IQR 110. Long delay paradigm: median latency for leftward saccades 354 msec, IQR 105; median latency for rightward saccades 354 msec, ICR 108).

For the short delay paradigm there was no difference between leftward and rightward saccades in the PEA (PEA for leftward saccades 3, IQR

0.16; PEA for rightward saccades 5, IQR 0.13). In the long delay paradigm, the PEA was significantly increased for leftward saccades (PEA 38, IQR 0.24) relative to rightward saccades (PEA 19; IQR 0.27, $p < 0.05$). This is shown in Figure 7.

DISCUSSION

We describe a patient who showed a severe and long lasting deficit in orientating himself in novel environments after an ischemic stroke of the right mediotemporoccipital lobe including the PHC. Clinical observations and neuropsychological testing revealed an impairment of allocentric spatial representations mainly confined to novel environments and a profound deficit in non-verbal, visuospatial learning and memory. These findings are in accordance with results from previous case reports and emphasize the importance of an impaired allocentric coordinate frame in the pathogenesis of topographical disorientation which may arise after a lesion of the PHC (Maguire et al., 1996; Luzzi et al., 2000; Aguirre and D'Esposito, 1999). The salient finding of this case report is that results from oculomotor testing provide evidence for an additional impairment of the egocentric coordinate frame, independently of the control of the PPC.

First, in the gap and overlap task reflexive visually guided saccades were hypometric when directed into the lesional hemifield. It is known from previous studies that patients with complete, dense hemianopia due to an occipital lesion may undershoot visual targets presented in the lesional hemifield (Meienberg et al., 1981). As hypometric

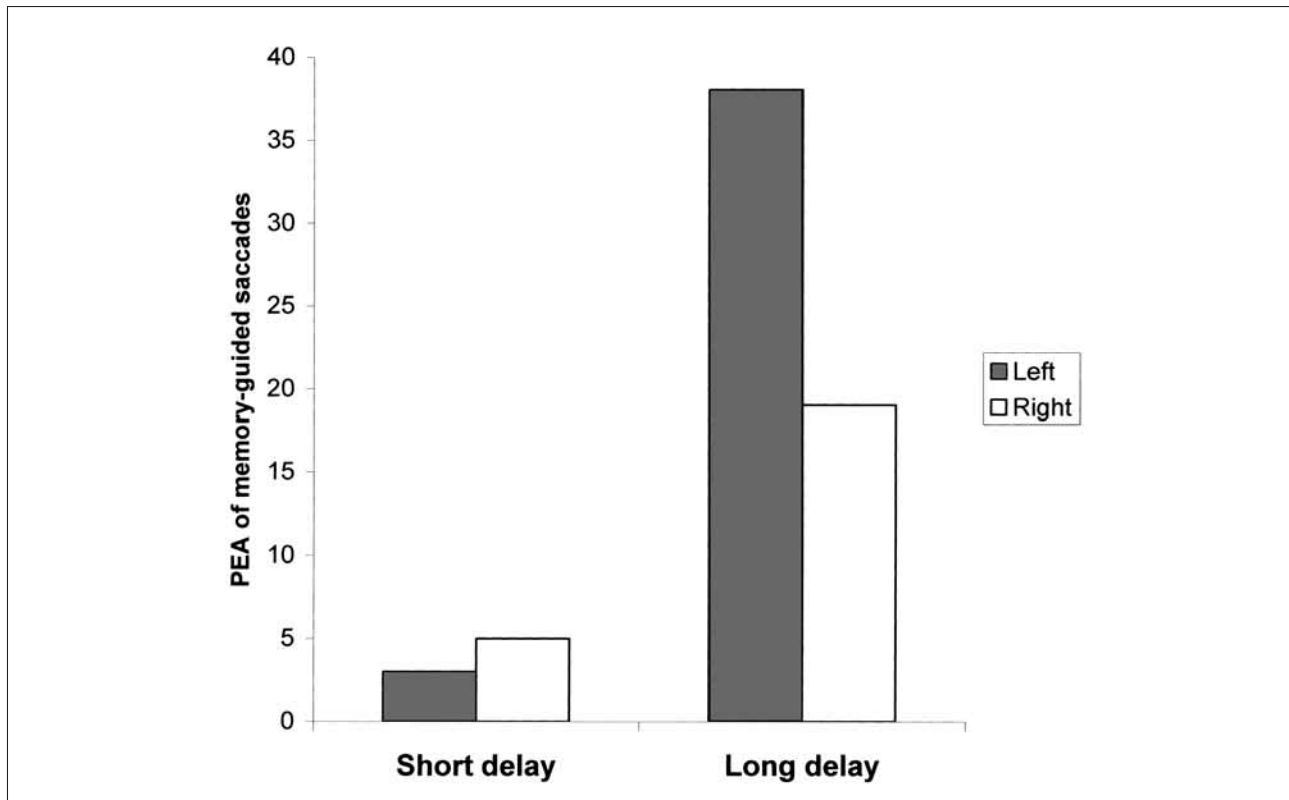


Fig 7 – The PEA of memory-guided saccades with 3 and 30 sec delay.

saccades were nearly always followed by further small saccades producing a staircase pattern, it was suggested that patients might use a compensatory strategy to find and fixate objects in the blind hemifield. Our results rather suggest an impairment of the egocentric coordinate frame than an employment of a compensatory strategy since in our patient left hemianopia was incomplete sparing central vision with 20 degrees, and all visual targets (bright LED's) were presented within 16 degrees. Theoretically, it may be assumed that a large lesion of the mediotemporooccipital lobe may result in retrograde effects on the posterior parietal cortex and therefore affecting the egocentric coordinate frame, as intense anatomical connections between those areas have been described (Seltzer and Pandya, 1984; Ding et al., 2000). However, in patients with posterior parietal lesions the latency of contralateral reflexive visually guided saccades are typically prolonged (Pierrot-Deseilligny et al., 1991), whereas in our patient the latencies were symmetrical and within normal range. Further evidence for an impairment of the egocentric coordinate frame comes from the double-step task. In this paradigm, where the subject has to make two successive saccades in response to two successively flashed lateral targets, the egocentric spatial representations may be tested accurately (Van Donkelaar and Müri, 2002). In our patient craniotopic updating of the second saccade (i.e. an egocentric spatial representation) was

impaired when the first saccade had been directed into the right, nonlesional hemifield. To our knowledge this has not been described before. The results clearly differ from those which are found in patients with an impaired egocentric coordinate frame due to right posterior parietal lesions (Heide et al., 1995). In the latter, a failure of craniotopic updating of the second saccade occurs when the first saccade is directed into the lesional hemifield.

More evidence for an impaired egocentric coordinate frame, independent of the control of the PPC, comes from the memory-guided saccade task. In the short delay paradigm the accuracy of memory-guided eye movements was symmetrical. In patients with a lesion of the PPC the accuracy of contralateral memory-guided saccades would be decreased (Pierrot-Deseilligny et al., 2002). In the long delay paradigm however, the accuracy of memory-guided eye movements contralateral to the lesion side was significantly impaired. This result is in line with previous studies and suggests that the mediotemporal lobe contributes to egocentric spatial memory at delays longer than 20 seconds (Ploner et al., 1998, 1999, 2000).

In summary the results of our oculomotor study suggest that a lesion of the mediotemporooccipital lobe itself may affect specifically the egocentric coordinate frame. This assumption is corroborated by the significant correlation between the gain of leftward saccades in the gap and overlap paradigm and the gain of the second leftward saccade in the

double step paradigm. The part of the egocentric coordinate frame, which is controlled by the PPC, however, seems to be intact.

Our findings are supported by electrophysiological studies in monkeys. Neurons in the mediotemporal cortex have been described which display an activity related to the egocentric spatial position of stimuli, some responding during sample presentation and some in the delay period (Cahusac et al., 1989; Rolls et al., 1989; Feigenbaum and Rolls, 1991). Furthermore, some neurons have been described in the hippocampal and inferotemporal cortex, which respond due to eye position (Nowicka and Ringo, 2000).

The extent to which the egocentric impairments of our patient may contribute to topographical disorientation remains speculative. The reduced amplitude of left-sided reflexive visually guided saccades and the impaired updating of left visual space across saccades in the double-step task seems not to be of much relevance, as both in the clinical and neuropsychological assessment a general visuospatial deficit was absent. However, theoretically it may be conceivable that an encoding deficit of left-sided objects, as it was found in the memory-guided saccade paradigm with long delays, may contribute to impaired route knowledge in our patient. Finally, one might also speculate that impaired functions of egocentric orientation in the mediotemporal lobe may contribute to topographical disorientation by preventing the building up of allocentric spatial representations.

In conclusion, additionally to the neuropsychological tests our oculomotor studies give new insight into the mechanism of topographical disorientation due to a lesion of the right mediotemporoccipital lobe suggesting that not only the allocentric but also egocentric coordinate frame is disturbed.

REFERENCES

- AGUIRRE GK and D'ESPOSITO M. Topographical disorientation: A synthesis and taxonomy. *Brain*, 122: 1613-1628, 1999.
- ASCHENBRENNER S, TUCHA O and LANGE KW. *RWT. Regensburger Wortflüssigkeits-Test*. Göttingen: Hogrefe, 2000.
- BARRASH J, DAMASIO H, ADOLPHS R and TRANEL D. The neuroanatomical correlates of route learning impairment. *Neuropsychologia*, 38: 820-836, 2000.
- BISIACH E, BROUCHON M, PONCET M and RUSCONI ML. Unilateral neglect in route description. *Neuropsychologia*, 31: 1255-1262, 1993.
- BOHBOU VD, KALINA M, STEPANKOVA K, SPACKOVA N, PETRIDES M and NADEL L. Spatial memory deficits in patients with lesions to the right hippocampus and to the right parahippocampal cortex. *Neuropsychologia*, 36: 1217-1238, 1998.
- BRICKENKAMP R. *Test d2: Aufmerksamkeits-Belastungs-Test*. Göttingen: Hogrefe, 1981.
- CAHUSAC PM, MIYASHITA Y and ROLLS ET. Responses of hippocampal formation neurons in the monkey related to delayed spatial response and object-place memory tasks. *Behavioral Brain Research*, 33: 229-240, 1989.
- DING SL, VAN HOESEN G and ROCKLAND KS. Inferior parietal lobule projections to the presubiculum and neighboring ventromedial temporal cortical areas. *Journal of Comparative Neurology*, 425: 510-530, 2000.
- DUHAMEL JR, COLBY CL and GOLDBERG ME. The updating of the representation of visual space in parietal cortex by intended eye movements. *Science*, 255: 90-92, 1992.
- EPSTEIN R, HARRIS A, STANLEY D and KANWISHER N. The parahippocampal place area: recognition, navigation, or encoding? *Neuron*, 23: 115-125, 1999.
- EPSTEIN R and KANWISHER N. A cortical representation of the local visual environment. *Nature*, 392: 598-601, 1998.
- FEIGENBAUM JD and ROLLS ET. Allocentric and egocentric spatial information processing in the hippocampal formation of the behaving primate. *Psychobiology*, 19: 21-40, 1991.
- GOLDBERG ME and BRUCE CJ. Primate frontal eye fields. III. Maintenance of a spatially accurate saccade signal. *Journal of Neurophysiology*, 64: 489-508, 1990.
- GUTHRIE BL, PORTER JD and SPARKS DL. Corollary discharge provides accurate eye position information to the oculomotor system. *Science*, 221: 1193-1195, 1983.
- HÄID TH, MARTL C, SCHUBERT F, WENZL M, KOFLER M and SALTUARI L. *Hamasch 5 Point Test-Revised (H5PT-R) – additional normative data*. Modena: First congress of the European Neuropsychological Societies, 191, 2004.
- HALLETT PE and LIGHTSTONE AD. Saccadic eye movements towards stimuli triggered by prior saccades. *Vision Research*, 16: 99-106, 1976.
- HÄRTING CH, MARKOWITSCH HJ, NEUFELD H, CALABRESE P, DEISINGER K and KESSLER J. *WMS-R. Wechsler Gedächtnistest. Revidierte Fassung. Deutsche Adaptation der revidierten Fassung der Wechsler Memory Scale*. Bern: Huber, 2000.
- HEIDE W, BLANKENBURG M, ZIMMERMANN E and KOMPFF D. Cortical control of double-step saccades: implications for spatial orientation. *Annals of Neurology*, 38: 739-748, 1995.
- HEATON RK. *Wisconsin Card Sorting Test*. Odessa FL: Assessment Resources, 1981.
- HELMSTAEDTER H, LENDT M and LUX S. *Verbaler Lern- und Merkfähigkeitstest*. Bern: Huber, 2001.
- HUBER W, POECK K, WENIGER D and WILLMES K. *Der Aachener Aphasie Test*. Göttingen: Hogrefe, 1983.
- LEHRL S, MERZ J, BURKARD G and FISCHER B. *Mehrfach-Wortschatz-Intelligenztest: MWTa*. Erlangen: Perimed-Fachbuch-Verlagsgesellschaft, 1991.
- LEVINE DN, WARACH J and FARAH M. Two visual systems in mental imagery: dissociation of "what" and "where" in imagery disorders due to bilateral posterior cerebral lesions. *Neurology*, 35: 1010-1018, 1985.
- LUZZI S, PUCCI E, DI BELLA P and PICCIRILLI M. Topographical disorientation consequent to amnesia of spatial location in a patient with right parahippocampal damage. *Cortex*, 36: 427-434, 2000.
- MAGUIRE EA, BURKE T, PHILLIPS J and STAUNTON H. Topographical disorientation following unilateral temporal lobe lesions in humans. *Neuropsychologia*, 34: 993-1001, 1996.
- MEIENBERG O, ZANGEMEISTER WH, ROSENBERG M, HOYT WF and STARK L. Saccadic eye movement strategies in patients with homonymous hemianopia. *Annals of Neurology*, 9: 537-544, 1981.
- MÜRI RM, GAYMARD B, RIVAUD S, VERMERSCH A, HESS CW and PIERROT-DESEILLIGNY C. Hemispheric asymmetry in cortical control of memory-guided saccades. A transcranial magnetic stimulation study. *Neuropsychologia*, 38: 1105-1111, 2000.
- MÜRI RM, VERMERSCH AI, RIVAUD S, GAYMARD B and PIERROT-DESEILLIGNY C. Effects of single-pulse transcranial magnetic stimulation over the prefrontal and posterior parietal cortices during memory-guided saccades in humans. *Journal of Neurophysiology*, 76: 2102-2106, 1996.
- MEYERS JE and MEYERS KR. *Rey Complex Figure Tests and Recognition Trial*. Odessa FL: Psychological Assessment Resources, 1995.
- NOWICKA A and RINGO JL. Eye position-sensitive units in hippocampal formation and in inferotemporal cortex of the macaque monkey. *European Journal of Neuroscience*, 12: 751-759, 2000.
- OSWALD W and ROTH E. *Der Zahlenverbindungstest*. Göttingen: Hogrefe, 1978.
- PIERROT-DESEILLIGNY C, MURI RM, RIVAUD-PECHOUX S, GAYMARD B and PLONER CJ. Cortical control of spatial memory in humans: the visuoculomotor model. *Annals of Neurology*, 52: 10-19, 2002.
- PIERROT-DESEILLIGNY C, RIVAUD S, GAYMARD B and AGID Y. Cortical control of reflexive visually-guided saccades. *Brain*, 114: 1473-1485, 1991.

- PLONER CJ, GAYMARD BM, EHRLE N, RIVAUD-PECHOUX S, BAULAC M, BRANDT SA, CLEMENCEAU S, SAMSON S and PIERROT-DESEILLIGNY C. Spatial memory deficits in patients with lesions affecting the medial temporal neocortex. *Annals of Neurology*; 45: 312-319, 1999.
- PLONER CJ, GAYMARD B, RIVAUD S, AGID Y and PIERROT-DESEILLIGNY C. Temporal limits of spatial working memory in humans. *European Journal of Neuroscience*, 10: 794-797, 1998.
- PLONER CJ, GAYMARD BM, RIVAUD-PECHOUX S, BAULAC M, CLEMENCEAU S, SAMSON S and PIERROT-DESEILLIGNY C. Lesions affecting the parahippocampal cortex yield spatial memory deficits in humans. *Cerebral Cortex*, 10: 1211-1216, 2000.
- REY A. *L'examen clinique en psychologie*. Paris: Presses Universitaires de France, 1964.
- RIDDOCH MJ and HUMPHREYS GW. *BORB. Birmingham Object Recognition Battery*. Hove: Lawrence Erlbaum Associates, 1993.
- ROLLS ET, MIYASHITA Y, CAHUSAC PM, KESNER RP, NIKI H, FEIGENBAUM JD and BACH L. Hippocampal neurons in the monkey with activity related to the place in which a stimulus is shown. *Journal of Neuroscience*, 9: 1835-1845, 1989.
- ROLLS ET, ROBERSTON RG and PIERRE GF. Spatial view cells in the primate hippocampus. *European Journal of Neuroscience*, 9: 1789-1794, 1997.
- RUFF RM and ALLEN CC. *RULIT. Ruff-Light Trail Learning Test. Professional Manual*. Odessa FL: Psychological Assessment Resources, 1999.
- SCHLAG J and SCHLAG-REY M. Through the eye, slowly: delays and localization errors in the visual system. *Nature Review Neuroscience*, 3: 191-215, 2002.
- SELTZER B and PANDYA DN. Further observations on parieto-temporal connections in the rhesus monkey. *Experimental Brain Research*, 55: 301-312, 1984.
- SPREEN O and STRAUSS E. *A Compendium of Neuropsychological Tests*. Oxford: Oxford University Press, 1991.
- TEWES U. *HAWIE-R: Hamburg-Wechsler Intelligenztest für Erwachsene*. Bern: Huber, 1991.
- VAN DONKELAAR P and MÜRI RM. Craniotopic updating of visual space across saccades in the human posterior parietal cortex. *Proceedings of the Royal Society of London, Series B Biological Sciences*, 269: 735-739, 2002.
- VON CRAMON D and SÄRING W. Störung der Orientierung beim hirnorganischen Syndrom. In D Bente, H Coper and S Kanowski (Eds), *Hirnorganische Psychosyndrome im Alter*. Berlin: Springer, 1982.
- WILSON B, COCKBURN J and HALLIGAN P. *Behavioural Inattention Test*. Titchfield: Thames Valley Test Company, 1987.
- Thomas Nyffeler, Department of Neurology, University Hospital, University of Berne, Freiburgstrasse 10, 3010 Berne, Switzerland.
e-mail: thomas.nyffeler@insel.ch

(Received 28 April 2003; reviewed 27 June 2003; revised 31 July 2003; accepted 15 August 2003; Action Editor Jason Mattingley)