

NOTE

PROSOPAGNOSIA: A BIHEMISPHERIC DISORDER*

Thierry M. Ettlin¹, Mace Beckson^{1,2}, D. Frank Benson¹, John T. Langfitt², Edwin C. Amos¹
and Gregorio S. Pineda³

(¹Department of Neurology, UCLA School of Medicine, Los Angeles, CA; ²Department of Psychiatry and Biobehavioral Science, UCLA School of Medicine, Los Angeles, CA; ³San Joaquin Hospital, Bakersfield, CA)

It is well recognized that prosopagnosia, the acquired inability to recognize familiar faces, follows posterior cerebral damage; whether prosopagnosia can result from a unilateral lesion or demands bilateral brain damage remains a topic of controversy (Damasio, Damasio and Van Hoesen, 1982; Landis, Cummings, Christen et al., 1986). With only one exception, all cases of well-defined prosopagnosia that have come to autopsy have had bilateral lesions (Damasio et al., 1982; Meadows, 1974) and, in addition, many clinically defined cases have had evidence of bilateral lesions based on clinical or CT data (Assal, Favre and Anderes, 1984; Bruyer, Laterre, Seron et al., 1983; Damasio et al., 1982; Malone, Morris, Kay et al., 1982; Meadows, 1974; Nardelli, Buonanno, Coccia et al., 1982). There are, however, a number of cases with clinical evidence of unilateral involvement only in which prosopagnosia has been reported (Assal, 1969; De Renzi, 1986; Hécaen et al., 1956, 1957; Landis et al., 1986; Meadows, 1974; Lhermitte and Pillon, 1975; Michel, Perenin and Sieroff, 1986; Sergent and Villemure, 1989; Whiteley and Warrington, 1977). The majority has had evidence suggesting right posterior pathology, most often left visual field defect, but at least four cases with clinical evidence of focal left posterior hemispheric damage have been recorded (Meadows, 1974). A summary of all reported cases in the literature is provided by Farah (1990). The most convincing case of unilateral damage producing prosopagnosia is a patient reported by Landis et al. (Landis, Regard, Blietle et al., 1988). Their patient died 10 days after she had developed prosopagnosia and at postmortem a unilateral right occipito-temporal infarct was demonstrated.

We present an individual who suffered a stepwise succession of infarction, each involving discrete portions of the posterior brain. Prosopagnosia manifested only after both occipital areas were damaged.

CASE REPORT

A 54-year-old, right-handed male with a 10th-grade education and a long history of alcohol abuse had significant hypertensive disease. On 2/27/85, he experienced loss of control of his left arm and leg, noted a strange feeling in his left arm and general incoordination. Examination revealed left arm weakness, blood pressure of 220/120 and a heart rate of 110. CT scan (3/1/85) revealed a wedge-shaped right parietal lucency (Figure 1). Both the hypertension and the tachycardia were controlled with medication.

He remained well until 6/30/88 when he experienced an episode of nausea, vomiting, confusion, intermittent visual problems and anxiety. A left homonymous hemianopsia, car-

* Presented as a poster at the Annual Meeting of the American Neurological Association, October 18, 1990, Atlanta, Georgia.

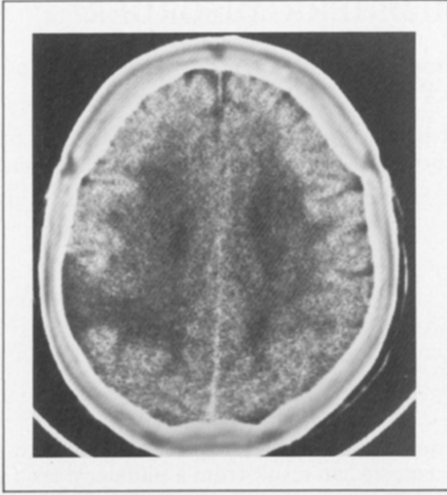


Fig. 1 - CT scan following first CVA demonstrating infarction in the right parietal borderzone territory. Clinically, neither visual field defect nor prosopagnosia was present.

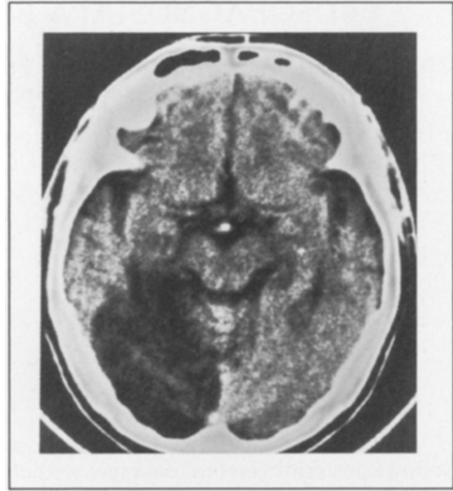


Fig. 2 - CT scan one month following the second CVA that produced a large occipital/parietal/posterior-medial-temporal infarction. The patient had a left homonymous hemianopsia but no difficulty recognizing familiar faces.

diomyopathy, and arrhythmia were noted. A CT scan (Figure 2) performed one month later, August 1, 1988, revealed a large area of lucency that involved the posterior cerebral artery territory of the right occipital lobe and posterior-medial parts of the right temporal lobe, as well as the original right parietal infarct.

The left visual field defect persisted but the patient had no problems identifying objects or acquaintances. In January of 1989, he experienced another episode of confusion with an abrupt onset of decreased vision (for several days he could barely discern movement in either eye). CT scan done at this time (1/18/89) (Figure 3) revealed a hemorrhage involving the left parieto-occipital area. Over a course of several weeks his vision improved so that he had no problem in identifying (naming) objects or in reading but he realized that he was no longer able to recognize familiar faces. He could not identify his wife or close friends until they spoke and even his own face in the mirror was not familiar. A repeat CT scan performed one month later (2/14/89) (Figure 4) revealed resolution of the left hemisphere hemorrhage leaving only minimal evidence of left occipital infarction.

One year later the patient was thoroughly evaluated. Ophthalmological examination revealed a left homonymous hemianopsia and a right superior quadrantanopsia confirmed by Octopus 2000. Visual acuity with correction was 20/30 in the right and 20/25 in the left eye. The neurological examination revealed a mild left facial weakness and extinction to double simultaneous stimulation on the left side of the patient's body but was otherwise normal.

Neuropsychological evaluation demonstrated low-average range performance on tests of general verbal abilities (Wechsler, 1981), verbal fluency (Spreeen and Benton, 1969) and immediate and delayed verbal memory (Russel, 1988). When correction was made for his visual neglect, the patient performed within normal limits on a standardized aphasia screening test (Halstead and Wepman, 1959). Visuo-perceptual and constructional difficulties were noted for complex, but not for simple stimuli. He could not correctly complete any items from the Picture Completion and Block Design subtests of the WAIS-R. Although he could copy a triangle and a square and reproduced both from memory 30 minutes later, he could not copy more complex designs nor even select them from a set of similar foils. He correctly named objects in his environment and all objects, actions, letters, forms, and numbers on the word discrimination subtest of the Boston Diagnostic Aphasia Examination (Goodglass and Ka-

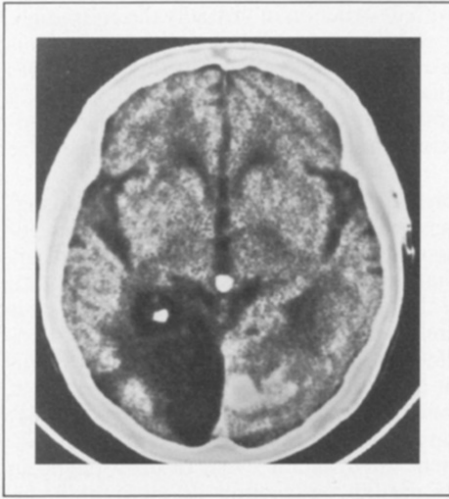


Fig. 3 - CT scan following the third CVA demonstrating hemorrhage in the left posterior cerebral territory. The patient had left homonymous hemianopsia, right superior quadrantanopsia and prosopagnosia.

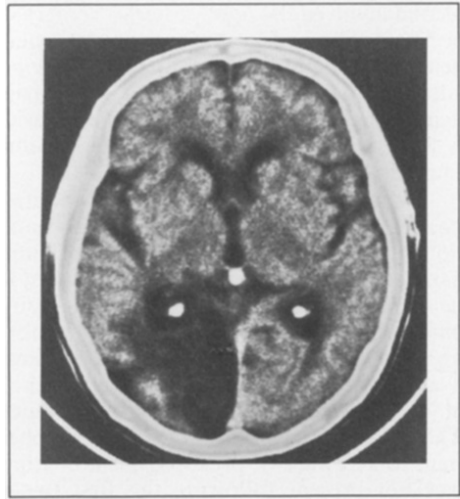


Fig. 4 - CT scan one month after the third CVA showing only minimal residual of the hemorrhagic infarction. Prosopagnosia persisted.

plan, 1972). He could not, however, name any of the colors on the same subtest.

Facial discrimination and recognition were severely impaired. He performed in the severely impaired range (6 of 27 correct) on a match-to-sample task of facial recognition (Benton, Hamsher, Varney and Spreen, 1983). Error analysis revealed that this few correct answers were based on matching individual facial details and he was totally unable to match faces when they were viewed from different perspectives. On the Remote Memory Battery Famous Faces Test (Albert, Butters and Levin, 1979), he was unable to recognize the personalities in any of the photographs presented even when given multiple choice, although he could correctly identify gender, race, and such details as moustache, hat etc. In the hospital he did not learn to recognize (visually) any of his physicians or nurses but could identify them by voice. Visually, he could discriminate gender, shape and amount of hair and the presence of associated cues (e.g., glasses, necktie) but all faces looked alike. When looking in a mirror he could identify the different parts of his face (e.g., nose, lips) but remained uncertain that it was his own face.

COMMENT AND DISCUSSION

Prosopagnosia is generally defined as a variant of visual agnosia featuring an acquired inability to recognize, by facial features, individuals who have long been known (spouse, children, relatives, close friends) and includes an inability to learn recognition of the faces of new acquaintances (Damasio, 1985; Farah, 1990). In contrast, non-visual cues such as voice and gait are used for positive identification and many non-facial visual features such as facial blemish, moustache and hair color provide identification clues. While rare, the disorder is so dramatic that a sizable literature has arisen. In this case the two right hemispheric infarcts produced an extensive right posterior hemisphere lesion. The first was located in the right borderzone area and destroyed much of the right posterior parietal area. The

second involved the right posterior cerebral artery with destruction of virtually the entire right occipital lobe and posterior-medial tissues of the right temporal lobe. Left homonymous hemianopsia and left visual neglect were present after the second CVA but the patient was adamant that he had no trouble recognizing familiar faces. Following the third episode, a hemorrhagic infarct involving the left parieto-occipital lobe, there was an initial near-blindness. As visual acuity recovered he was immediately aware of a total inability to recognize familiar faces.

Neurobehavior evaluation one year after the third incident revealed persistent prosopagnosia as well as difficulties with color naming, facial recognition, high level visual perception and construction. While the latter findings may well have been present after the two earlier right hemispheric infarcts, the patient insists that prosopagnosia was never present until he suffered the third, left hemispheric insult. Since the claim of absence of prosopagnosia is based on the patient's own report it cannot be entirely excluded that he might have been unaware of this deficit. Sergent and Villemur's (1989) hemispherectomized patient was not aware of her prosopagnosia and two of the six right hemispheric cases collected by Landis et al. (1986) were unconcerned about their illness and one denied to suffer from prosopagnosia. This raises the question if the left hemispheric lesion is for some reason necessary for the patient to be aware of prosopagnosia. With our patient the dramatic event of prosopagnosia was not present following the first two episodes despite destruction of all right hemisphere visual tissues but was immediately noted after damage in the left hemisphere visual area.

Another problem displayed by this case concerns reliance on current brain imaging information. The CT scan performed one month after the third cerebrovascular incident demonstrated that the hemorrhage in the left posterior hemisphere, clearly present at the onset of the prosopagnosia (Figure 3), had resolved (Figure 4) and no clearly defined area of infarction could be outlined. While left posterior damage would be suspected by experienced examiners, the lesion is not obvious. A significant functional defect is present in the absence of a readily identified structural defect (as measured by x-ray CT).

The cases in which unilateral brain damage is said to have produced prosopagnosia have been based on CT findings (De Renzi, 1986; Landis et al., 1986; Michel et al., 1986; Whiteley and Warrington, 1977), ablation of an occipital epileptic zone (Hécaen et al., 1956; Lhermitte and Pillon, 1975), or evacuation of an intracerebral hematoma (Assal, 1969; Meadows, 1974). In none of these cases can bilateral involvement be ruled out absolutely. A further question to raise is whether unilateral damage produces transient rather than permanent prosopagnosia. In the 6 unilateral cases collected by Landis et al. (1986), followup data were available in 4. One showed persistent prosopagnosia but 3 had recovered the ability to recognize familiar faces, at least to some degree. One of the two cases of unilateral prosopagnosia reported by Hécaen et al. (1956, 1957) also resolved within a few weeks as did the case of Assal (1969). In Meadow's (1974) unilateral case the prosopagnosia was only partial and the case of Michel et al. (1986) also showed some recovery. De Renzi's two cases (1986) with CT evidence of right unilateral damage only, however, had long-standing prosopagnosia. The single case report with strong evidence for prosopagnosia following unilateral lesion (based on autopsy findings) is in a patient who died 10 days after a right posterior cerebral territory stroke (Landis et al., 1988). Interpretation of these cases suggests that unilateral right lesions may cause a transient disturbance in recognizing familiar faces but does not prove that permanent prosopagnosia will result.

Several authors (Damasio et al., 1982; De Renzi, 1986; Landis et al., 1986) propose that the extent of damage and/or the amount of disconnected brain tissue might be the decisive variable for prosopagnosia after unilateral lesions. The case reported here demonstrates that structural damage sufficiently extensive to obliterate the entire right posterior brain, right posterior parietal area and posterior-medial parts of the right temporal lobe did not produce prosopagnosia. In contrast, severe and persistent inability to recognize familiar faces occurred immediately after an additional, much less extensive infarct involving the left posterior brain.

While a single case cannot be confidently accepted as a base for anatomical/behavior correlation, the absence of prosopagnosia despite massive right posterior hemisphere damage and its immediate and dramatic appearance following involvement of the other (left)

posterior visual cortical network provides a strong example in which bilateral pathology was needed for the production of persistent prosopagnosia.

ABSTRACT

A 54-year-old, right-handed male suffered three sequential infarcts. The first two destroyed much of the right posterior parietal area, the posterior-medial portion of the right temporal lobe and virtually the entire right occipital lobe producing left homonymous hemianopsia and left visual neglect but no prosopagnosia. A third vascular accident involved the left parieto-occipital lobe and immediately produced prosopagnosia that has persisted. The sequential correlations of lesion and symptomatology in this case demonstrate that development of persistent prosopagnosia occurred only after bilateral damage.

REFERENCES

- ALBERT, M.S., BUTTERS, N., and LEVIN, J. Temporal gradients in the retrograde amnesia of patients with alcoholic Korsakoff's disease. *Archives of Neurology*, 36: 211-216, 1979.
- ASSAL, G. Regression des troubles de la reconnaissance des physiognomies et de la memoire topographique chez un malade opéré d'un hematome intracerebral parieto-temporal droit. *Revue Neurologique*, 121: 184-185, 1969.
- ASSAL, G., FAVRE, C., and ANDERES, J.P. Non-reconnaissance d'animaux familiers chez un paysan. *Revue Neurologique*, 140: 580-584, 1984.
- BENTON, A.L., HAMSHER, K., VARNEY, N.R., and SPREEN, O. *Contributions to Neuropsychological Assessment*. New York: Oxford University Press, 1983.
- BRUYER, R., LATERRE, C., SERON, X., FEYEREISNE, P., STRYPSTEIN, E., PIERRARD, E., and RECTEM, D. A case of prosopagnosia with some preserved covert remembrance of familiar faces. *Brain and Cognition*, 2: 257-284, 1983.
- DAMASIO, A.R. Disorders of complex visual processing: Agnosias, achromatopsia, Balint's syndrome and related difficulties of orientation and construction. In M.M. Mesulam (Ed.), *Principles of Behavioral Neurology*. Philadelphia: Davis, 1985, pp. 259-288.
- DAMASIO, A.R., DAMASIO, H., and VAN HOESEN, G.W. Prosopagnosia: Anatomical basis and behavioral mechanism. *Neurology*, 32: 331-341, 1982.
- DE RENZI, E. Prosopagnosia in two patients with CT scan evidence of damage confined to the right hemisphere. *Neuropsychologia*, 24: 385-389, 1986.
- FARAH, J.F. *Visual Agnosia*. Cambridge, Mass.: The MIT Press, 1990, pp. 129-132.
- GOODGLASS, H., and KAPLAN, E. *Assessment of Aphasia and Related Disorders*. Philadelphia: Lea and Febiger, 1972.
- HALSTEAD, W.C., and WEPMAN, J.M. The Halstead-Wepman aphasia screening test. *Journal of Speech and Hearing Disorders*, 14: 9-15, 1959.
- HÉCAEN, H., ANGELERGUES, R., BERNHARDT, C., and CHIAVELLI, J. Essai de distinction des modalités cliniques de l'agnosie des physiognomies. *Revue Neurologique*, 96: 125-144, 1957.
- HÉCAEN, H., PENFIELD, W., BERTRAND, W., and MALMO, R. The syndrome of apractagnosia due to lesions of minor cerebral hemisphere. *Archives of Neurology and Psychiatry*, 75: 400-434, 1956.
- LANDIS, T., CUMMINGS, J.L., CHRISTEN, L., BOGEN, J.E., and IMHOF, A. Are unilateral right posterior cerebral lesions sufficient to cause prosopagnosia? Clinical and radiological findings in six additional patients. *Cortex*, 22: 243-252, 1986.
- LANDIS, T., REGARD, M., BLIESTLE, A., and KLEIHNS, P. Prosopagnosia and agnosia for non-canonical views: An autopsied case. *Brain*, 111 (Pt. 6): 1287-1297, 1988.
- LHERMITTE, F., and PILLON, B. La prosopagnosie. Role de l'hémisphère droit dans la perception visuelle. *Revue Neurologique*, 131: 791-812, 1975.
- MALONE, D.R., MORRIS, H.H., KAY, M.C., and LEVIN, H.S. Prosopagnosia: A double dissociation between the recognition of familiar and unfamiliar faces. *Journal of Neurology, Neurosurgery, and Psychiatry*, 45: 820-822, 1982.
- MEADOWS, J.C. The anatomical basis of prosopagnosia. *Journal of Neurology, Neurosurgery, and Psychiatry*, 37: 489-501, 1974.
- MICHEL, F., PERENIN, M.T., and SIEROFF, E. Prospagnosie sans hémianopsie après lésion unilatérale occipito-temporale droite. *Revue Neurologique*, 142: 545-549, 1986.
- NARDELLI, E., BUONANNO, F., COCCIA, G., FIASCHI, H., TERZIAN, H., and RIZZUTO, N. Prosopagnosia. *European Neurology*, 21: 289-297, 1982.

- RUSSEL, E.W. Renorming Russel's version of the Wechsler Memory Scale. *Journal of Clinical and Experimental Neuropsychology*, 10: 235-249, 1988.
- SERGENT, J., and VILLEMURE, J.G. Prosopagnosia in a right hemispherectomized patient. *Brain*, 112: 975-995, 1989.
- SPREEN, O., and BENTON, A.L. *Neurosensory Center Comprehensive Examination for Aphasia*. Victoria, BC: Neuropsychological Laboratory Dept. of Psychology, University of Victoria, 1969.
- WECHSLER, D. *Wechsler Adult Intelligence Scale - Revised*. New York: Psychological Corporation, 1981.
- WHITELEY, A.M., and WARRINGTON, E.K. Prosopagnosia: A clinical, psychological, and anatomical study of three patients. *Journal of Neurology, Neurosurgery, and Psychiatry*, 40: 395-403, 1977.

T.M. Ettlin, M.D., Neurologische Universitätsklinik, CH-4031 Basel, Switzerland.