

Hemorrhagic Stroke in a Child With Protein S and Factor VII Deficiencies

Katherine Lietz, MD, PhD*,
Stephanie E. Kuehling, MD[†], and
Joan B. Parkhurst, MD*

A 12-year-old previously healthy male, with a family history of protein S deficiency, presented with confusion, aphasia, and right upper extremity weakness after a 10-day febrile illness. Imaging studies revealed sinovenous thrombosis and left parietal hemorrhagic stroke. On further investigation he was found to have both protein S and factor VII deficiencies. © 2005 by Elsevier Inc. All rights reserved.

Lietz K, Kuehling SE, Parkhurst JB. Hemorrhagic stroke in a child with protein S and factor VII deficiencies. *Pediatr Neurol* 2005;32:208-210.

Introduction

Strokes in children are rare, with an estimated incidence ranging from 0.7 to 2.5 cases per 100,000 children [1-3]. Whereas hypertension and atherosclerosis are often associated with stroke in adults, causes in the pediatric population are diverse. In fact, analysis of individual cases often reveals more than one risk factor. The most common underlying conditions include congenital heart disease, sickle cell disease, infection-mediated or immune-mediated vasculitis, nephrotic syndrome, central venous catheters, and the congenital thrombophilias [1-4].

This report describes a case of a 12-year-old male, admitted with symptoms of confusion and aphasia secondary to a sinus venous thrombosis and hemorrhagic stroke. On evaluation he was found to have both protein S and factor VII deficiencies.

Case Report

A previously healthy 12-year-old male presented with a 10-day history of fever and pharyngitis. On the day of admission he was somnolent and reportedly had difficulty finding words while conversing with his family. Later he became confused and agitated and was brought to the emergency room.

In the emergency room, he had fever (38.5°C) and mild tachycardia. Physical examination revealed moderate dehydration, pharyngitis, and cervical adenopathy. He was disoriented to time, place, and person and manifested significant expressive and minor receptive aphasia. Cranial nerves were intact but there was significant right upper extremity weakness.

Computed tomography and magnetic resonance imaging of the brain documented an acute hemorrhage in the left temporal/occipital region, measuring 3 × 6 cm in size (Fig 1). A magnetic resonance venogram disclosed extensive venous sinus thrombosis involving the left sigmoid sinus and left transverse sinus (Fig 2). An extensive evaluation for infectious causes was negative apart from bilateral maxillary sinusitis observed on plain films, computed tomography, and magnetic resonance imaging.

Family history on the paternal side was significant for deep venous thrombosis in several family members and for a stroke in an uncle in early adulthood. Only one relative, an aunt with multiple episodes of deep venous thrombosis related to pregnancy, had an evaluation for genetic factors and had been demonstrated to be a heterozygote for protein S deficiency.

An extensive thrombophilia evaluation of the patient indicated that he was also a heterozygote for a type II protein S deficiency. Although total protein S antigen level was normal at 63%, protein S function was significantly decreased at 21% (normal: 60-145%). Tests for protein C deficiency, antithrombin III deficiency, and hyperhomocysteinemia were negative. DNA testing failed to reveal mutations for factor V Leiden or the prothrombin gene mutation. Although the patient had an antinuclear antibody titer of 1:120, further testing did not yield significant titers of anticardiolipin antibodies.

Because of persistently prolonged prothrombin times, in the range of 14.7-15.3 seconds, a factor VII level was checked several days into his hospital course and was found to be significantly low at 21%, indicating heterozygosity for factor VII deficiency.

Anticoagulation was not initiated in this patient, because of the hemorrhagic nature of his stroke and the perceived risk of exacerbating intracranial bleeding. After 2 weeks of intensive physical therapy and speech therapy, the expressive aphasia and right-sided upper extremity weakness had almost totally resolved, although serial magnetic resonance venograms demonstrated little change. The patient continued to do well for 3 months after discharge but has since been lost to follow-up.

Discussion

Strokes in the pediatric population are rare and therefore not always immediately recognized. Published work by the Canadian group has done much to stimulate interest in this area. The first Canadian Registry report in the mid-

From the Departments of *Pediatric Hematology/Oncology and [†]Radiology, Oklahoma University Health Sciences Center, Oklahoma City, Oklahoma.

Communications should be addressed to:
Dr. Parkhurst; Dept. of Pediatric Hematology/Oncology; Children's Hospital; 940 NE Thirteenth Street (Rm 3308);
Oklahoma City, OK 73104.
Received March 4, 2004; accepted August 17, 2004.

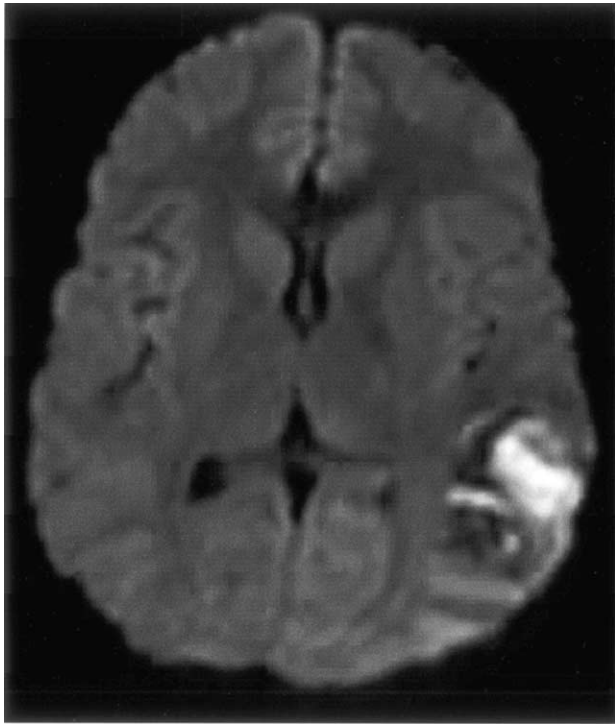

Figure 1. Diffusion-weighted magnetic resonance imaging depicts a hemorrhagic venous infarct in the left cerebral hemisphere.

1990s revealed that arterial ischemic strokes, often secondary to congenital heart disease, made up the majority (78%) of their cases [3]. Sinovenous thrombosis was less common (22%) in that series but historically may have been underdiagnosed before the routine use of magnetic resonance venography. The most extensive review of sinovenous thrombosis in children (160 cases) was the subject of a more recent publication by DeVeber and the Canadian group in 2001 [5].

The causes of stroke in children are often multifactorial. In fact, DeVeber et al. reported in their earlier publication that 65% of their patients had two risk factors with 40% having ≥ 3 risk factors [3]. These can include dehydration, infections of the head and neck, and inherited thrombophilia conditions. In that respect our patient was classic, in that he had sinusitis, dehydration, and a documented protein S deficiency.

It is reported that 15-21% of adults with sinovenous thrombosis have a congenital or acquired prothrombotic condition [6,7]. The true incidence of thrombophilia conditions in children with sinovenous thrombosis remains unclear, because retrospective series draw a substantial percentage of their patients from a time when routine testing for factor V Leiden and the prothrombin 20210A mutation was unavailable. In the 2001 Canadian series [5], testing for prothrombotic disorders was performed in 77% of patients. Evidence of congenital or acquired thrombophilia was present in 39% of those tested, with anticardiolipin antibodies the most frequently reported predisposing factor. It seems likely that the number would be higher in a prospective study carried out today.

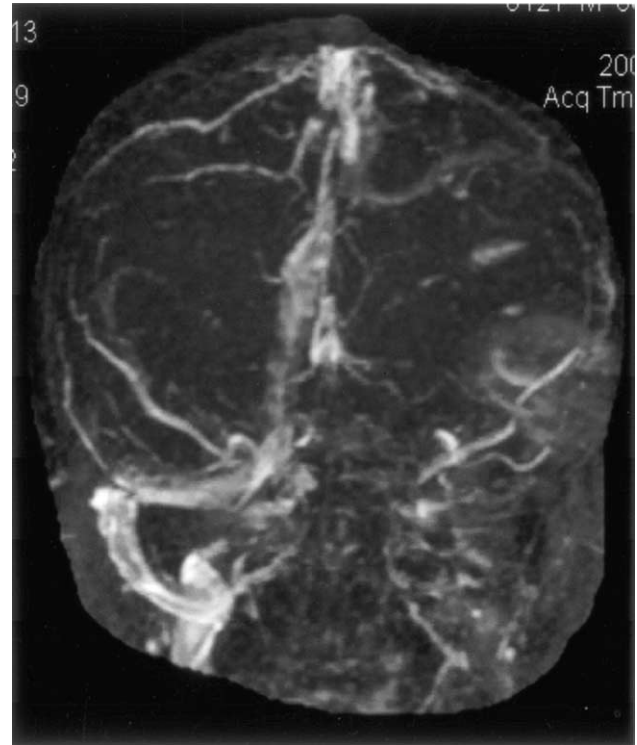


Figure 2. A magnetic resonance venogram reveals absence of the left transverse and sigmoid venous sinuses compared with the normal right-sided venous structures.

Not all patients with sinus venous thrombosis develop a “stroke.” Andrew et al. postulate that infarction after sinovenous thrombosis is caused by the sequence of increased venous pressure, increased intracranial pressure, and decreased perfusion [8]. In the Canadian series, parenchymal infarcts were observed in 41% of the cases [5]. Accompanying hemorrhage was actually observed in 68% of those who had had a parenchymal infarction (28% of the total patient number). Other authors have observed a much lower rate of hemorrhage. Only one of the 17 pediatric patients with cerebral sinovenous thrombosis recently reported from Virginia had a concomitant bleed [9].

Guidelines for the treatment of sinovenous thrombosis and stroke in children have not been well established. Most medical management has been based on adult studies or nonrandomized trials. In adults, the case for anticoagulant therapy for sinovenous thrombosis rests mainly on the results of two trials [10,11]. One of these reported better rates of recovery and fewer neurologic sequelae in patients treated with heparin vs placebo. Patients with hemorrhage were included on both arms. New hemorrhages and extensions of existing hemorrhages were observed in both the heparin and the placebo groups. In the other study, a blinded placebo controlled trial of nadroparin, a low molecular weight heparin, no significant intracranial bleeding was observed. However, the outcomes were poor overall with $>30\%$ death rate in both groups. The treated group had slightly better results, but the difference did not reach statistical significance.

In recent years, pediatric centers have become bolder in the use of anticoagulants. However, the use of anticoagulation in the face of hemorrhage remains controversial because of the risk of potentially catastrophic bleeding. In the recent report from Virginia [9], 15 of the 17 patients with sinovenous thrombosis received anticoagulants (without bleeding complications). However, the one patient with an intraparenchymal bleed did not. It is also interesting that both the patients who were not anticoagulated had resolution of their thrombi without treatment. In their 2001 publication [5], the Canadian group reports that some form of "antithrombotic" therapy was administered to 53% of their patients, but they do not comment on whether the 28% with hemorrhage were among those treated.

Factor VII deficiency is a rare autosomal condition. With his level of 21%, the patient reported here was clearly a heterozygote rather than a homozygote. It is well established that such patients may have significant bleeding manifestations when challenged. In the face of a preexisting bleed and a documented partial deficiency of factor VII, our patient was treated conservatively.

Although previous cases of combined deficiency of vitamin K dependent factors with hemorrhage have been cited in the literature [12,13], our patient may be the first with isolated deficiencies of protein S and factor VII and the first where both thrombosis and hemorrhage have occurred together. The two proteins are coded for on different chromosomes (chromosome 13 for factor VII with the gene for its regulatory protein on chromosome 8; chromosome 3 for protein S), so this is not likely to represent a linked mutation and is likely to be a rare combination. However, it does raise the question concerning whether patients with sinovenous thrombosis and hemorrhage should have further investigation before treatment. Also, the good outcome of this patient, and of other pediatric patients who did not receive anticoagulation, again raises the question of whether treatment for children can validly be extrapolated from adult data.

The question of long-term treatment after stroke for children known to have one of the thrombophilia conditions is also an area of some controversy. Likely there

would be generalized agreement that a full evaluation to exclude other concomitant prothrombotic conditions is necessary, because children with more than one contributing condition are likely to be at substantially higher risk of recurrence. Our patient tested negative for anticardiolipin antibodies and for the other congenital thrombophilia conditions. However, his partial factor VII deficiency impinges significantly on possible treatment in that it almost certainly increases the risk of hemorrhage with anticoagulation.

References

- [1] Broderick J, Talbot GT, Prenger E, Leach A, Brott T. Stroke in children within a major metropolitan area: The surprising importance of intracerebral hemorrhage. *J Child Neurol* 1993;8:250-5.
- [2] Shoenberg BS, Mellinger JF, Schoenberg DG. Cerebrovascular disease in infants and children: A study of incidence, clinical features, and survival. *Neurology* 1998;28:763-8.
- [3] DeVeber G. Canadian Pediatric Ischemic Stroke Registry [Abstract]. *Canadian J Neurol Sci* 1995;22:S24.
- [4] Riela AR, Roach SR. Etiology of stroke in childhood. *J Child Neurol* 1993;8:201-20.
- [5] DeVeber G, Andrew M; Canadian Pediatric Ischemic Stroke Study Group. Cerebral sinovenous thrombosis in children. *N Engl J Med* 2001;345:417-23.
- [6] Zuber M, Toulon P, Marnet L, Mas JL. Factor V Leiden mutation in cerebral venous thrombosis. *Stroke* 1996;27:1721-3.
- [7] Martinelli I, Sachi E, Landi G, Taioli E, Duca F, Mannucci PM. High risk of cerebral vein thrombosis in carriers of prothrombin gene mutation and in users of oral contraceptives. *N Engl J Med* 1998;338:1793-7.
- [8] Andrew M, Monagle P, Booker L. Stroke. In: Decker BC, editor. *Thromboembolic complications during infancy and childhood*. Hamilton and London: B.C. Decker, 2000;201-29.
- [9] Johnson MC, Parkerson N, Ward S, de Alarcon PA. Pediatric sinovenous thrombosis. *J Pediatr Hematol Oncol* 2003;25:312-5.
- [10] Kay R, Wong KS, Yu YL, et al. Low-molecular-weight heparin for the treatment of acute ischemic stroke. *N Engl J Med* 1995;333:1588-93.
- [11] Saxena R, Lewis S, Berge E, Sandercock PA, Koudstaal PJ. Risk of early death and recurrent stroke and effect of heparin in 3169 patients with acute ischemic stroke and atrial fibrillation in the International Stroke Trial. *Stroke* 2001;32:2333-7.
- [12] Brenner B, Tavori S, Zivelin A, et al. Hereditary deficiency of all vitamin K-dependent procoagulants and anticoagulants. *Br J Haematol* 1990;75:537-42.
- [13] Thomas A, Stirling D. Four factor deficiency [Abstract]. *Blood Coagul Fibrinolysis* 2003;14:S55-7.