

6. Minami M, Hanakita J, Suwa H, Suzui H, Fujita K, Nakamura T. Solitary metastasis of lung cancer to the cerebellopontine angle. A case report. *Neuro Med Chir* 1996; 36: 172–174.
7. Tu AS, Wang H, Harris-McCorkle L, Saunders Jr JR. Bilateral involvement of the cerebellopontine angles by malignant melanoma metastasis: a case report. *Md Med J* 1994; 43: 967–970.
8. Bono P, Bartoloni SOF. A rare case of bilateral metastasis in the cerebellopontine angle. *Pathologica* 1994; 86: 324–328.
9. Wronski M, Arbit E, Burt M, Galicich JH. Survival after surgical treatment of brain metastases from lung cancer: a follow-up study of 231 patients treated between 1976 and 1991. *J Neurosurg* 1995; 83: 605–616.
10. Largerwaard FJ, Levendag PC, Nowark PJ, Eijkenboom WM, Hanssens PE, Schmitz PI. Identification of prognostic factors in patients with brain metastases: a review of 1292 patients. *Tnt J Radiat Oncol Biol Phys* 1999; 43: 795–803.

Cerebral venous thrombosis in a gentleman presenting with fever, convulsion and frontotemporal haemorrhages

K.H. Chan MBBS MRCP, R.T.F. Cheung PHD FRCP,
W.M. Liu MBBS FRCS, W. Mak MBCHB MRCP, S.L. Ho MD FRCP

Division of Neurology, University Department of Medicine, Queen Mary Hospital, Pokfulam, Hong Kong

Summary Cerebral venous thrombosis (CVT) is an uncommon but serious type of stroke. Thrombosis may involve the cortical or deep veins or the venous sinuses. The presenting clinical features are non-specific. We report a 48-year-old man with CVT who presented with fever, bitemporal throbbing headache, and generalised convulsion. Computed tomography (CT) of the brain revealed acute haemorrhages over right anterior frontal and posterior temporal regions with surrounding oedema and right anterior temporal subcortical oedema. The initial diagnosis was herpes simplex encephalitis. Absence of venous flow over the right transverse and sigmoid sinuses during the venous phase of digital subtraction angiography (DSA) revealed CVT. He was anti-coagulated for 6 months. An underlying cause of CVT was not detected. A high index of suspicion is required when risk factors of CVT are present. CT brain may be normal or showing non-specific findings. Magnetic resonance imaging plus venography, CT venography, or DSA is diagnostic.

© 2004 Elsevier Ltd. All rights reserved.

Journal of Clinical Neuroscience (2005) 12(2), 186–188
0967-5868/\$ - see front matter © 2004 Elsevier Ltd. All rights reserved.
doi:10.1016/j.jocn.2004.03.013

Keywords: anti-coagulation, cerebral haemorrhage, cerebral venous thrombosis, digital subtraction angiography, viral encephalitis

Received 26 November 2003

Accepted 17 March 2004

Correspondence to: Dr. Raymond T.F. Cheung PHD FRCP, Division of Neurology, University Department of Medicine, University of Hong Kong, 4th Floor Professorial Block, Queen Mary Hospital, Pokfulam, Hong Kong.
Tel.: +852-2855-3315; Fax: +852-2974-1171;
E-mail: rtcheung@hkucc.hku.hk

INTRODUCTION

Although cerebral venous thrombosis (CVT) is a serious and potentially fatal type of stroke, it is uncommon with an annual

incidence of 3.4/100,000 per year in our population.^{1–3} Thrombosis may involve the cortical or deep cerebral veins or the straight, sagittal, transverse, sigmoid, and/or cavernous sinus and produce venous hypertension, raised intracranial pressure (ICP), cerebral ischaemia, and/or venous infarction. Patients may present with focal and/or non-focal clinical features, such as diffuse or localised headache, features of raised ICP, focal or generalised seizures, lethargy or coma, non-specific visual obscurations, transient visual loss, and alternating hemiparesis or paraparesis.^{1–4} These non-specific clinical features can be attributed to other disorders such as idiopathic intracranial hypertension, viral encephalitis, dural arteriovenous fistula, and other causes of cerebral infarcts or intracerebral haemorrhages.^{1–3,5} Here, we report a case of CVT presenting with fever, headache, convulsion, and frontotemporal haemorrhages mimicking viral encephalitis.

CASE REPORT

A 48-year-old gentleman was admitted because of generalised tonic-clonic convulsion for 2 min. He did not have any history of febrile convulsion and his past health was good. He did not take any regular medication or recreational drug. He had fever with bitemporal throbbing headache plus flu-like symptoms for about 1 week before admission. The headache was worse in the morning or with straining. There was no neck pain, neck stiffness, visual symptom, photophobia, or phonophobia. After recovery from post-ictal drowsiness, examination revealed low grade fever (axillary temperature 37.2 °C), normal orientation, and coherent speech. There was no neck rigidity or Kernig's sign. Fundoscopy revealed bilateral papilloedema and cranial nerves were intact. The rest of neurological examination was normal. His blood pressure was 118/68 mmHg and examination of other systems was normal.

Complete blood counts, liver and renal function tests were normal. Erythrocyte sedimentation rate was 10 mm per hour. Computed tomography (CT) brain scan revealed acute haemorrhages over right anterior frontal and posterior temporal regions with adjacent oedema, and right anterior temporal subcortical oedema (Fig. 1(a)–(c)). He was empirically treated as herpes simplex encephalitis with intravenous acyclovir and sodium valproate. Digital subtraction angiography (DSA) was performed to identify any vascular abnormalities that may underlie his multifocal intracerebral haemorrhages. The cerebral arteries were normal, but absence of venous flow over the right transverse and sigmoid sinuses during the venous phase revealed CVT (Fig. 1(d)). Anti-nuclear antibody, anti-extractable nuclear antigen antibody, anti-neutrophil cytoplasmic antibody, and C3 and C4 complement levels were negative or normal. Anti-cardiolipin IgG and IgM antibody were not raised. He was treated with low-molecular-weight heparin (Fraxiparine at 10,000 I.U. subcutaneously every 12 h) followed by oral warfarin. His headache subsided one week after commencement of anti-coagulation. Warfarin was continued for 6 months with the international normalised ratio kept between 1.8 and 2.5. Subsequent screening of thrombophilia was negative for deficiency in protein C, protein S, or anti-thrombin III as well as for activated protein C resistance. He did not have recurrent seizure and sodium valproate was stopped 4 months after his presentation.

DISCUSSION

Early diagnosis of CVT and prompt treatment with anti-coagulation are crucial, since delayed treatment is associated with an unfavourable prognosis.^{1,2,6} As a differential diagnosis, patients with CVT were sometimes managed as viral encephalitis in the

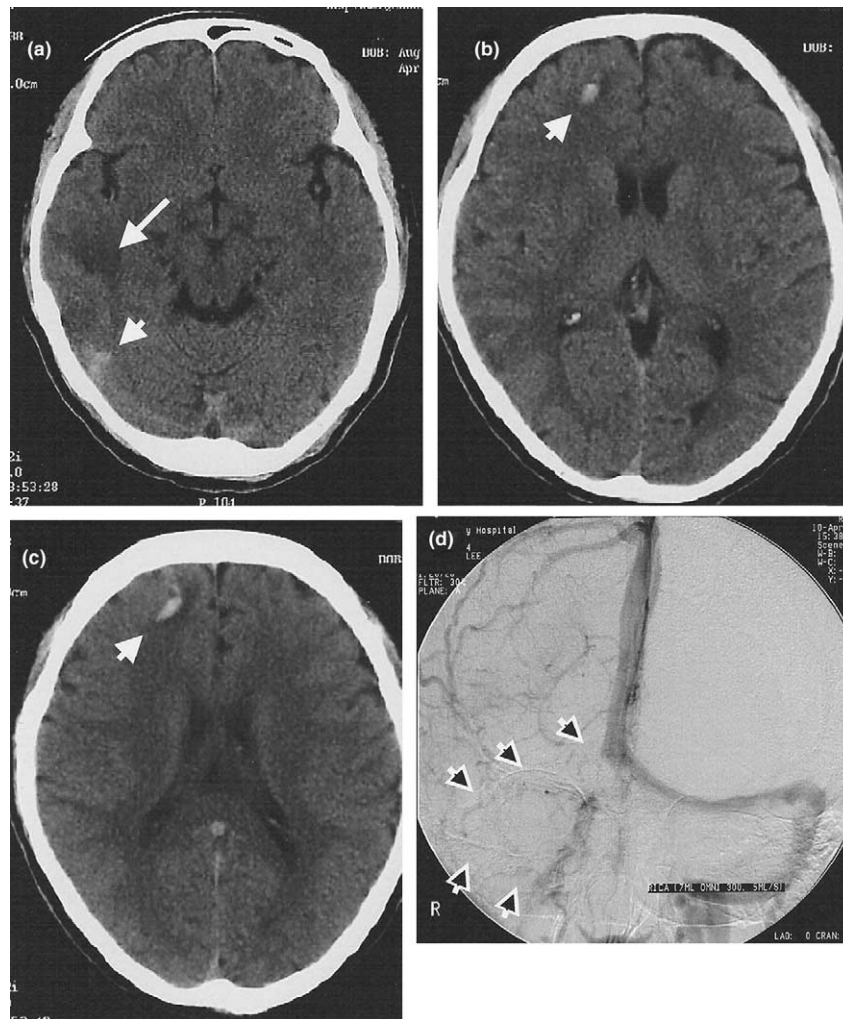


Fig. 1 Plain computed tomography of the brain revealed acute haemorrhages (short arrows) over right anterior frontal (b, c) and posterior temporal (a) regions with adjacent oedema and right anterior temporal subcortical oedema (long arrow; a). Digital subtraction angiography showing absence of venous flow over the right transverse and sigmoid sinuses (arrows) during the venous phase to reveal cerebral venous thrombosis (d).

beginning.⁷ A combination of fever, headache, convulsion, and CT findings of frontotemporal haemorrhages plus oedema was suggestive of herpes simplex encephalitis. Nevertheless, CVT should be considered in patients with unexplained intracerebral or subarachnoid haemorrhages.

Regarding neuroimaging findings of CVT, plain CT of the brain may be normal or reveal the 'cord sign' (i.e., a linear area of increased density due to the clot in a deep vein or venous sinus), and/or bilateral or multifocal cerebral oedema with or without haemorrhages involving both the grey and white matters to indicate venous infarcts.⁸ Contrast enhanced CT may show the 'empty delta sign' due to enhancing engorged collateral venous channels surrounding the clot within the dural sinus. CT venography, a new dynamic CT technology, has been shown to be at least as good as magnetic resonance venography (MRV) in the visualisation of CVT.⁸ Magnetic resonance imaging (MRI) or MRV has proven validity when compared to DSA or conventional angiography. MRI is more sensitive than CT in revealing cerebral parenchymal changes, intravenous contrast is not required, and there is no ionising radiation.⁸ Conventional angiography or DSA is now rarely required. Angiographic features include direct signs, such as lack of contrast opacification in the veins or sinuses, or indirect signs, such as delayed venous emptying and abnormal collateral venous circulation.⁸ Owing to its invasive nature, angiography is reserved for the rare case of isolated cortical vein thrombosis or indecisive results from non-invasive tests.

In developing countries, generalised or local infection is a common aetiology.¹⁻³ Common local infections include facial and orbital sepsis, otitis media, mastoiditis, spheno-ethmoidal sinusitis, bacterial meningitis, rhino-cerebral and oto-cerebral mucormycosis, petrositis and gingivitis. No infective agent is specifically implicated in CVT. In contrast, non-infectious causes are common in developed countries. These include hypercoagulable states (e.g., nephrotic syndrome, hereditary deficiency of protein C, protein S or anti-thrombin III, activated protein C resistance, hyperfibrinogenaemia, and anti-phospholipid antibody syndrome), haematological disorders (e.g., sickle cell trait, polycythaemia, erythrocytosis, diffuse intravascular coagulation, paroxysmal nocturnal haemoglobinuria, thrombocythaemia, leukaemia, and lymphoma), chronic inflammatory diseases (e.g., ulcerative colitis, sarcoidosis, Behcet's disease, systemic lupus erythematosus, and Wegener's granulomatosis), systemic or local neoplastic conditions, dehydration or flow disorders, drug or hormonal use (e.g., oral contraceptives, L-asparaginase, methotrexate, 6-mercaptopurine, and danazol), pregnancy, postoperative state, and head trauma.¹⁻³ Behcet's disease can cause both encephalitis and CVT.⁹

Anti-coagulation is beneficial and safe even in the presence of intracerebral haemorrhage.^{1,6,10} Either intravenous conventional heparin or subcutaneous LMWH can be commenced to achieve immediate anticoagulation, and warfarin with regular monitoring is used for prolonged anti-coagulation. Anti-coagulation is

continued for 3–6 months. Patients with recurrent CVT (occurring in about 12% of cases) or a persistent prothrombotic state may require life-long anti-coagulation. Other treatment options include transvenous thrombolysis, endovascular clot removal via a suction device, consideration of use of anticonvulsants, control of markedly raised ICP, other supportive measures, and management of the underlying cause.^{1–3,10} Most patients improved with appropriate management, and the overall mortality rate of CVT is about 10%; poor prognostic factors are delay in treatment and markedly impaired consciousness upon presentation. About 14% of survivors suffered from permanent neurological impairment, including focal deficits in 7%, epilepsy in 5%, optic atrophy in 3%, and rarely dural arteriovenous fistula.⁶

In conclusion, a high index of suspicion is required when risk factors of CVT are present, and plain CT of the brain may be normal or showing non-specific findings. MRI, MRV, CT venography, or DSA is required to confirm the diagnosis.

ACKNOWLEDGEMENTS

The authors thank Miss Jess Chan for her clerical assistance.

REFERENCES

1. Bousser MG, Chiras J, Borias J, Castaigne P. Cerebral venous thrombosis. A review of 38 cases. *Stroke* 1985; 16: 199–213.
2. Mak W, Mok KY, Tsoi TH, Cheung RT, Ho SL, Chang CM. Cerebral venous thrombosis in Hong Kong. *Cerebrovasc Dis* 2001; 11: 282–283.
3. Breteau G, Mounier-Vehier F, Godefroy O et al. Cerebral venous thrombosis 3-year clinical outcome in 55 consecutive patients. *J Neurol* 2003; 250: 29–35.
4. Ameri A, Bousser MG. Cerebral venous thrombosis. *Neurol Clin* 1992; 10: 87–111.
5. Chan KH, Cheung RT, Mak W, Au-Yeung KM, Ho SL. Cerebral venous thrombosis presenting as unilateral headache plus visual blurring in a man with nephrotic syndrome. *Hosp Med* 2004; 65: 54–55.
6. Preter MP, Tzourio C, Ameri A, Bousser MG. Long-term prognosis in cerebral venous thrombosis: follow-up of 77 patients. *Stroke* 1996; 27: 243–246.
7. Silburn PA. Deep cerebral venous thrombosis presenting as an encephalitic illness. *Postgrad Med J* 1996; 72: 355–368.
8. Connor SE, Jarosz JM. Magnetic resonance imaging of cerebral venous sinus thrombosis. *Clin Radiol* 2002; 57: 449–461.
9. Huss GP, Mattle H, Wessel K, Mumenthaler M. Neuro-Behcet's syndrome: encephalitis and cerebral venous thrombosis—clinical aspects and neuroradiology of 5 cases. *Nervenarzt* 1992; 63: 352–358.
10. Einhaupl KM, Villringer A, Meister W et al. Heparin treatment in sinus venous thrombosis. *Lancet* 1991; 338: 597–600.

Vertically acquired neonatal citrobacter brain abscess – case report and review of the literature

Deepak Agrawal MCh, Ashok Kumar Mahapatra MCh

Department of Neurosurgery, Neurosciences Center, All India Institute of Medical Sciences, New Delhi 110029, India

Summary Vertically acquired citrobacter meningitis in the neonate is very rare and carries a very high mortality and morbidity. Overall, approximately 30% of neonates with *Citrobacter* meningitis die and 50% sustain some damage to the CNS. The authors describe a case of a newborn with *Citrobacter koseri* meningitis with multiple brain abscesses, with a successful outcome following multiple burr-hole aspirations and prolonged antibiotic therapy. An aggressive surgical

approach combined with intravenous antibiotics (including imipenems, to which the organism is very sensitive) for a minimum of 4 weeks appears to improve the outcome of infection with this virulent organism.

© 2004 Elsevier Ltd. All rights reserved.

Journal of Clinical Neuroscience (2005) 12(2), 188–190
0967-5868/\$ - see front matter © 2004 Elsevier Ltd. All rights reserved.
doi:10.1016/j.jocn.2004.03.010

Keywords: neonatal meningitis, citrobacter, vertical transmission, brain abscess, imipenem

Received 16 September 2003

Accepted 15 March 2004

Correspondence to: Prof. A.K. Mahapatra, Department of Neurosurgery, All India Institute of Medical Sciences, New Delhi 110029, India.

Tel.: +91-11-6594577; Fax: +91-11-6862663;

E-mail: akmahapatra_22000@yahoo.com

INTRODUCTION

Neonatal meningitis due to *Citrobacter koseri* (previously *C. diversus*) has a poor prognosis because of the ability of the organism to produce brain abscesses. *C. koseri*, a gram-negative bacillus of the family Enterobacteriaceae, may be found as a commensal in the female genitourinary tract and gastrointestinal tract, and has been found to have virulence factors that enable it to invade and survive in epithelial cells, possibly contributing to its propensity to cause abscesses.¹ This phenomenon may also make effective antibiotic therapy for *C. koseri* meningitis problematic, resulting in extremely high morbidity and a mortality of around 30%. We describe a case of a newborn with *C. koseri* meningitis with multiple brain abscesses, with a successful outcome following multiple burr-hole aspirations and prolonged antibiotic therapy. The pertinent literature is reviewed and pathogenesis and management of such abscesses discussed.

CASE REPORT

Our patient was a male baby born after 35 weeks gestation with a birth weight of 1500 g. Delivery was complicated by rupture of membranes with persistent leak for 30 h and non-progression of labor. At birth the Apgar score was 7 and 10 at 1 and 5 min. The child was tachypneic initially and became lethargic as well as febrile within 24 h. CSF analysis was suggestive of meningitis. Blood and CSF both grew *C. koseri* sensitive to imipenem and cilastatin combination, which was started in appropriate dosage. He responded well to the therapy and received intravenous antibiotics for two weeks, followed by oral antibiotics for a further period of one week.

At three weeks of age, the child was reviewed by a pediatrician and was found to have a bulging fontanelle. An ultrasound examination of the head revealed multiple fluid filled cavities in both hemispheres. CT head with contrast was suggestive of multiple brain abscesses (Figs. 1A and B), the largest of which was in the right parietal region (Fig. 1B). He was subsequently referred to our center for further management. At admission, he was lethargic, with a bulging fontanelle. The head circumference was 33.5 cm and there was no focal neurological deficit. The child underwent ultrasound-guided aspiration of the right parietal abscess cavity and around 30 ml of yellow colored sero-sanguineous fluid was aspirated. He was again started on imipenem and cilastatin in view of the previous culture report. As he remained lethargic in the postoperative period, and as a repeat CT revealed an increase in size of the right temporal abscess with only moderate decrease in the size of the parietal abscess (Fig. 2), ultrasound guided aspiration of the temporal and parietal abscesses was