

Novel Mitochondrial DNA ND5 Mutation in a Patient With Clinical Features of MELAS and MERRF

Ali B. Naini, PhD; Jiesheng Lu, MD; Petra Kaufmann, MD, MSc; Richard A. Bernstein, MD, PhD; Michelangelo Mancuso, MD; Eduardo Bonilla, MD; Michio Hirano, MD; Salvatore DiMauro, MD

Background: The mitochondrial DNA gene encoding subunit 5 of complex I (ND5) has turned out to be a hot spot for mutations associated with mitochondrial encephalomyopathy with lactic acidosis and stroke-like episodes (MELAS) and various overlap syndromes.

Objective: To describe a novel mutation in the ND5 gene in a young man with an overlap syndrome of MELAS and myoclonus epilepsy with ragged-red fibers.

Design: Case report.

Patient: A 25-year-old man had recurrent strokes, seizures, and myoclonus. His mother also had multiple

strokes. A muscle biopsy specimen showed no ragged-red fibers but several strongly succinate dehydrogenase-reactive blood vessels.

Results: Biochemical analysis showed isolated complex I deficiency and molecular analysis revealed a novel heteroplasmic mutation (G13042A) in the ND5 gene.

Conclusions: These data confirm that ND5 is a genetic hot spot for overlap syndromes, including MELAS and stroke-like and myoclonus epilepsy with ragged-red fibers.

Arch Neurol. 2005;62:473-476

MITOCHONDRIAL ENCEPHALOMYOPATHY with lactic acidosis and stroke-like episodes (MELAS) and myoclonus epilepsy with ragged-red fibers (MERRF) are the 2 most common clinical phenotypes associated with mitochondrial DNA point mutations. About 80% of patients with MELAS harbor the A3243G mutation in the transfer RNA^{Leu(UUR)} gene,¹ whereas in MERRF, the 2 most common mutations (A8344G and T8356C) are in the transfer RNA^{Lys} gene.² Leber hereditary optic neuropathy is invariably associated with missense mutations in genes encoding complex I subunits.³ However, in the past decade increasing numbers of mutations in the gene encoding subunit 5 of complex I (ND5) have been associated with MELAS⁴⁻⁶ or with various overlap syndromes, including MELAS and Leigh syndrome,^{7,8} MELAS, and Leber hereditary optic neuropathy,⁹ and even MELAS, Leigh syndrome, and Leber hereditary optic neuropathy.⁶

Herein, we report a novel missense mutation (G13042A) in the ND5 gene in a pa-

tient with MELAS and MERRF overlap syndrome.

REPORT OF A CASE

PATIENT

A 25-year-old man reportedly was born after an uncomplicated pregnancy and delivery and had had normal psychomotor development. He was healthy and athletic until the age of 17 years, when he had a tonic-clonic seizure during sleep. At the age of 20 years, he had a first stroke, characterized by sudden difficulty speaking and walking, urinary incontinence, and loss of sensation in the left side of the body. After prolonged rehabilitation, he regained independence but did not return to his baseline status. He has had 2 similarly severe and several less severe episodes of neurological dysfunction, usually characterized by the inability to speak. He also had frequent partial seizures, with shaking of the arms, loss of tone, and urinary incontinence, but without complete loss of consciousness or the tonic component.

Author Affiliations:

Department of Neurology, Columbia University College of Physicians and Surgeons, New York, NY (Drs Naini, Lu, Kaufmann, Mancuso, Bonilla, Hirano, and DiMauro); and the Ken and Ruth Davee Department of Neurology, Feinberg School of Medicine, Northwestern University, Chicago, Ill (Dr Bernstein).

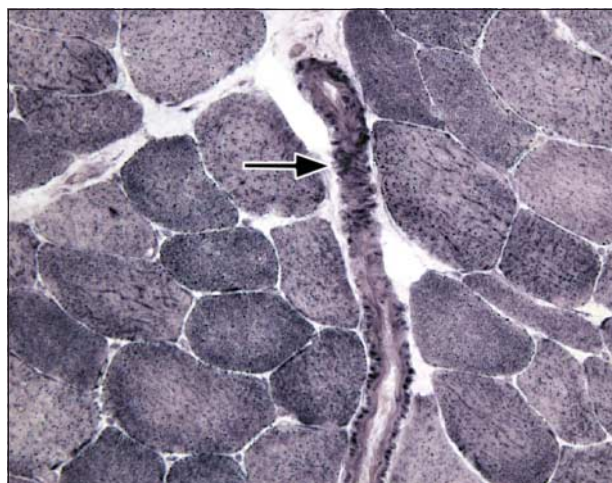


Figure 1. Succinate dehydrogenase (SDH) histochemistry shows no ragged-red fibers but a strongly succinate dehydrogenase–reactive blood vessel in longitudinal section (arrow) (original magnification, $\times 250$).

The patient further reported memory loss and occipital migrainelike headaches with nausea and photophobia. He also described frequent myoclonic jerks, exercise intolerance with premature fatigue, and neck pain. He has osteoporosis and fractured vertebrae at the level of C5 through C7 vertebrae.

Family history showed that the patient's 50-year-old mother had suffered from multiple strokes and seizures starting in her 30s. We could not examine her, but she is apparently ambulatory and does not have myoclonus. She also suffers from migraine headache and mild hearing loss. She has 3 other sons from 2 different marriages: they are 28, 14, and 13 years old and are apparently in good health. The mother's 75-year-old mother and numerous siblings could not be examined but are reportedly healthy.

Physical examination of our patient disclosed cold hands and feet with Raynaud phenomenon. He was in a wheelchair with his head bent forward and had a decreased range of motion in his neck. Findings from a neurological examination showed flat affect and marked dysarthria. There was mild weakness of neck extension, proximal weakness of the arms and legs, and tightness of the left heel cord. He could not stand up from sitting without assistance. He could walk unassisted but had poor arm swing and a wide base. Reflexes were brisk, more so on the left side, and there was 1 beat of ankle clonus on the left side. Findings from a cerebellar examination showed bilateral dysmetria; results of a sensory examination showed decreased vibration in the toes bilaterally.

Laboratory test results included a normal venous lactate level. There was a lactate peak on brain magnetic resonance spectroscopy in a voxel placed over a lateral ventricle, but not on a voxel placed over the basal ganglia. On brain magnetic resonance imaging, there were several foci of fluid-attenuated inversion recovery hyperintensity in the left internal capsule and bilateral parietal lobes.

MITOCHONDRIAL DNA ANALYSES

Total DNA was extracted from muscle homogenate and from blood using a kit (PUREGENE; Gentra Systems, Inc, Minne-

Table. Activities of Mitochondrial Respiratory Chain Enzymes in Muscle Extracts From the Patient and Control Subjects*

Complex†	Patient	Control Subjects
I	10	68 \pm 24
I and III	59	103 \pm 38
II and III	60	71 \pm 20
IV	379	283 \pm 50

*Control values (n = 69) are means \pm SD. All complex activities are expressed as nanomoles per minute per citrate synthase units.

†Complex I indicates reduced nicotinamide adenine dinucleotide (NADH)–coenzyme Q (CoQ) oxidoreductase; complexes I and III, an NADH cytochrome *c* reductase; complexes II and III, succinate–cytochrome *c* reductase; and complex IV, cytochrome *c* oxidase. All complex activities are expressed as nanomoles per minute per citrate synthase units.

apolis, Minn) according to the manufacturer's instructions. Polymerase chain reaction and restriction fragment length polymorphism methods were used to screen for the most common mutations associated with MELAS and MERRF.

Direct sequencing of the mitochondrial complex I subunit 5 (ND5) gene was performed with the BigDye terminator cycle sequencing methodology on an ABI PRISM 310 Genetic Analyzer (Applied Biosystems, Foster City, Calif) with a pair of primers (forward, 5'-AACAAACATGGCTTTCTCAAC; and reverse 5'-GGTTGAACATTGTTTGTGG). Restriction fragment length polymorphism with radioactive (deoxyadenosine triphosphate [dATP] labeled with phosphate 32)-labeling technique was used to assess the degree of heteroplasmy. The region spanning codon 236 in the ND5 gene was polymerase chain reaction–amplified (forward, 5'-TCCAACATCATGAGACCCACA, and reverse 5'-GGTGAAGCGATGAGTAAG), and the 217–base pair polymerase chain reaction product was labeled and cut with *DdeI* restriction enzyme. The G13042A mutation eliminates 1 of the 2 restriction sites that can be detected by restriction fragment length polymorphism analysis. After digestion, fragments were resolved on a 12% native acrylamide gel and analyzed in a phosphorimager (Bio-Rad, Hercules, Calif) to calculate the heteroplasmy level.

RESULTS

Muscle biopsy findings showed only atrophy of some fibers, punctuate succinate dehydrogenase staining, and several strongly succinate dehydrogenase–reactive blood vessels (**Figure 1**). Mitochondrial respiratory chain enzyme activities in muscle extracts were referred to the activity of citrate synthase, a matrix enzyme and a good marker of mitochondrial abundance. The activity of complex I was decreased, both when measured as reduced nicotinamide adenine dinucleotide (NADH)–cytochrome *c* reductase (57% of the normal mean) and— even more so—when measured as NADH–coenzyme Q reductase (15% of the normal mean), whereas the activities of other respiratory chain complexes were normal (**Table**).

Sequence analysis of the ND5 gene revealed a single change, a G-to-A transition at nucleotide position 13042 (**Figure 2A**). This transition, which predicts the substitution of an alanine by a threonine at codon 236 of the ND5 subunit, was heteroplasmic in both muscle (90%) and blood cells (50%) from the patient (**Figure 2B**). This codon is highly conserved across different species (**Figure 2C**).

The clinical presentation of this patient had features common to MELAS (recurrent and partially reversible strokes; migraine; seizures)¹ and MERRF (myoclonus epilepsy).² However, the most common mutations associated with MELAS (G3243A; T3271C) and with MERRF (A8344G; T8356C) were not present. Southern blot analysis excluded the presence of mitochondrial DNA rearrangements, which can occasionally cause strokes.¹⁰

The key to the molecular diagnosis came from the biochemical analysis of muscle extracts that showed isolated and severe complex I deficiency. This, together with clinical evidence of maternal inheritance, prompted us to sequence all mitochondrial genes encoding subunits of complex I. We found a heteroplasmic G-to-A transition at nucleotide 13042 of mitochondrial DNA, which predicts the substitution of an alanine with a threonine at position 236 (Ala236Thr) of the ND5 subunit. The degree of heteroplasmy was 90% in muscle and 50% in blood.

Interestingly, a missense mutation in an adjacent codon (M237L) of the ND5 gene was identified in the patient with a 3-way overlap syndrome (MELAS, Leber hereditary optic neuropathy, and Leigh syndrome).⁶ Surprisingly—and in contrast to our findings—complex I activity in muscle from that patient was only mildly reduced.

The pathogenicity of the G13042A mutation is suggested by the following canonical criteria: (1) it has never been reported as a polymorphism and we did not find it in 150 normal individuals or in 50 patients with other mitochondrial disorders; (2) it is heteroplasmic, as most other deleterious mitochondrial DNA mutations; (3) it is associated with an encephalomyopathy similar to others caused by mutations in the same gene; and (4) it causes an amino acid change that must be functionally important because it is evolutionarily conserved. It would have been interesting to correlate degrees of heteroplasmy with clinical phenotypes in the mother and in the apparently asymptomatic maternal half brothers, but this study was vetoed by the estranged mother. The lack of abundant ragged-red fibers did not allow us to correlate degrees of heteroplasmy and mitochondrial pathology in single fibers.

This new heteroplasmic mutation in a patient with MELAS-MERRF overlap syndrome supports the view that the ND5 gene should be added to the transfer RNA^{Leu(UUR)} gene as another hot spot for MELAS mutations.⁶ This gene should be sequenced in MELAS patients without the A3243G mutation, especially if muscle biochemistry shows isolated complex I deficiency.

Accepted for Publication: June 15, 2004.

Correspondence: S. DiMauro, MD, 4-420 College of Physicians & Surgeons, 630 W 168th St, New York, NY 10032 (sd12@columbia.edu).

Author Contributions: Study concept and design: Naini, Lu, and DiMauro. Acquisition of data: Naini, Lu, Kaufmann, Bernstein, Mancuso, and Bonilla. Analysis and

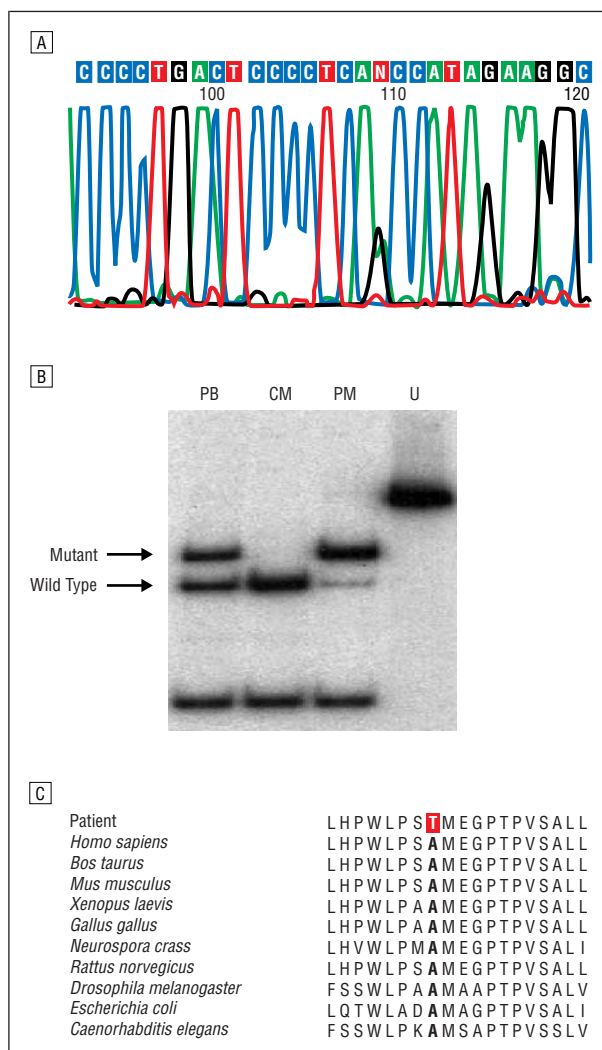


Figure 2. Molecular genetic analysis of the ND5 gene. A, Electropherogram of the mitochondrial DNA region encompassing the G13042A mutation (denoted by N). B, Polymerase chain reaction–restriction fragment length polymorphism analysis of the G13042A mutation. PB indicates patient's blood; CM, control muscle; PM, patient's muscle; and U, uncut. C, Comparison of the ND5 polypeptide region encompassing Ala236Thr change (bold) among several species.

interpretation of data: Naini, Lu, Kaufmann, Mancuso, Bonilla, Hirano, and DiMauro. Drafting of the manuscript: Naini, Lu, Bernstein, Mancuso, Hirano, and DiMauro. Critical revision of the manuscript for important intellectual content: Kaufmann, Bonilla, Hirano, and DiMauro. Statistical analysis: Naini and Lu. Administrative, technical, and material support: Naini, Lu, Kaufmann, Bernstein, Bonilla, Hirano, and DiMauro. Study supervision: Kaufmann, Mancuso, Bonilla, and DiMauro.

Funding/Support: This study was supported by grants NS11766 and P01HD32062 from the National Institutes of Health, Bethesda, Md; by the Marriott Mitochondrial Disorder Clinical Research Fund, New York, NY; and by a grant from the Muscular Dystrophy Association, Tucson, Ariz. Dr Mancuso is supported by the Department of Neurosciences, University of Pisa, Pisa, Italy.

REFERENCES

1. DiMauro S, Hirano M. MELAS. In: Gene Reviews at Gene Tests: Medical Genetics Information Resource [database online]. Seattle: University of Washington. Available at: <http://www.genetests.org>. Accessed July 11, 2004.
2. DiMauro S, Hirano M, Kaufmann P, et al. Clinical features and genetics of myoclonic epilepsy with ragged red fibers. In: Fahn S, Frucht SJ, eds. *Myoclonus and Paroxysmal Dyskinesia*. Philadelphia, Pa: Lippincott Williams & Wilkins; 2002: 217-229.
3. Carelli V. Leber's hereditary optic neuropathy. In: Schapira AH, DiMauro S, eds. *Mitochondrial Disorders in Neurology 2*. Boston, Mass: Butterworth-Heinemann; 2002:115-142.
4. Santorelli FM, Tanji K, Kulikova R, et al. Identification of a novel mutation in the mtDNA *ND5* gene associated with MELAS. *Biochem Biophys Res Commun*. 1997; 238:326-328.
5. Penisson-Besnier I, Reynier P, Asfar P, et al. Recurrent brain hematomas in MELAS associated with an *ND5* gene mitochondrial mutation. *Neurology*. 2000;55:317-318.
6. Liolitsa D, Rahman S, Benton S, Carr LJ, Hanna MG. Is the mitochondrial complex I *ND5* gene a hot-spot for MELAS causing mutations? *Ann Neurol*. 2003; 53:128-132.
7. Crimi M, Galbiati S, Moroni I, et al. A missense mutation in the mitochondrial *ND5* gene associated with a Leigh-MELAS overlap syndrome. *Neurology*. 2003; 60:1857-1861.
8. Chol M, Lebon S, Benit P, et al. The mitochondrial DNA *G13513A* MELAS mutation in the NADH dehydrogenase 5 gene is a frequent cause of Leigh-like syndrome with isolated complex I deficiency. *J Med Genet*. 2003;40:188-191.
9. Pulkes T, Eunson L, Patterson V, et al. The mitochondrial DNA *G13513A* transition in *ND5* is associated with a LHON/MELAS overlap syndrome and may be a frequent cause of MELAS. *Ann Neurol*. 1999;46:916-919.
10. Zupanc ML, Moraes CT, Shanske S, Langman CB, Ciafaloni E, DiMauro S. Deletion of mitochondrial DNA in patients with combined features of Kearns-Sayre and MELAS syndromes. *Ann Neurol*. 1991;29:680-683.