

Clelia Marchetti
David Carey
Sergio Della Sala

Crossed right hemisphere syndrome following left thalamic stroke

Received: 28 August 2003
Received in revised form: 12 July 2004
Accepted: 23 July 2004
Published online: 22 March 2005

C. Marchetti
Department of Neurology
Neuropsychology Unit
Salvatore Maugeri Foundation IRCCS
Rehabilitation Institute of Veruno (NO),
Italy

D. Carey
School of Psychology
University of Aberdeen, Scotland

S. Della Sala (✉)
Human Cognitive Neuroscience –
Psychology
University of Edinburgh
7 George Square
Edinburgh EH8 9JZ, Scotland
E-Mail: sergio@ed.ac.uk

■ **Abstract** In most right-handed people, language and motor functions are more reliant on systems of the left hemisphere while several non-linguistic visuo-spatial and attentional processes depend more on the right hemisphere. The rare exceptions to these rules provide important clues as to what functions co-lateralise, and are thus crucial for models of cerebral specialization. Here we report on the case of a patient, who, after a lesion restricted to the left thalamic region, showed signs normally associated with right hemispheric injury including motor impulsiveness, visuo-spatial dysfunction and poor comprehension of facial

expression. Language abilities were spared and no signs of apraxia were present, in spite of his right hand, foot and eye preference, a pattern normally associated with conventional cerebral dominance. In spite of his other right hemispheric signs, the patient showed no signs of hemispatial neglect. The patient's pattern of spared and impaired abilities is compared and contrasted with other rare cases of crossed right hemisphere syndrome.

■ **Key words** thalamus · cerebral lateralisation · visuo-spatial deficits · right hemisphere

Introduction

The leading role of the left hemisphere in language and praxis control is well established. Similarly, there is general consensus that visuo-spatial abilities rely more heavily upon the right hemisphere in people with conventional dominance. Further evidence suggests an important role of the right hemisphere in prosody, in particular in controlling the emotional tone of speech production (e.g. Ross 1981) and the discrimination of facial expressions (e.g. Borod et al. 1986). The right hemisphere may also be specialised for sustaining attention (e.g. Mesulam 1981; Woods and Knight 1986).

Exceptions to this general rule of cerebral dominance have been reported for the functions supposedly subserved by the left hemisphere in right-handed people. This was typically the case in “crossed” aphasia (i.e.

aphasia following right hemisphere lesions in right-handers, for reviews see Castro-Caldas 1987; Laiacina et al. 1996; Mariën et al. 2001) and crossed apraxia (Marchetti and Della Sala 1997; Raymer et al. 1999).

The opposite dissociation (i.e. left hemisphere control of visuo-spatial functions normally associated with the right hemisphere) has been reported in right-handers much less frequently (Hund-Georgiadis et al. 2001; Kellar and Levick 1985; Fischer et al. 1991; Posteraro and Maravita 1995). These reports may be few because cases of crossed “right-hemisphere syndrome” are actually rare or because most of them are overlooked (Geschwind and Galaburda 1985).

The report of such exceptional cases may add to our understanding of how different functions are represented in the two hemispheres and how they are related to one another within the same hemisphere. In this paper a right-handed patient is described who showed

signs and symptoms of right hemisphere impairment (visuo-spatial and constructive deficits, affective disorders, defective global attention and motor impersistence) following a left thalamic haemorrhage. The case reported is an example of the "crossed right-hemisphere syndrome" (Judd 1989).

Case report

The patient was a man with five years of formal education and was 64-year old at the time of testing. His past medical history was unremarkable except for hypertension in the previous six years, irregularly treated with ACE-inhibitors. He had shown sudden onset of right-sided weakness 50 days before examination. CT (Fig. 1) performed immediately after the onset and fifty days later revealed a left thalamic haemorrhage impinging upon the anterior nuclei. No lesion was apparent in the right hemisphere. MRI performed 30 months later showed the sequelae of the left thalamic haemorrhage, and did not disclose any other brain lesion (Fig. 2). SPECT analysis (Fig. 3) confirmed this finding by demonstrating a circumscribed perfusion deficit compatible with a left thalamic lesion. The SPECT did not show signs of cortical hypoperfusion.

The patient was alert, cooperative and well-oriented to time and space. He made no errors in answering questions concerning his life and relatives, though the tone of his voice was flat and monotonous. However, he was not overtly depressed according to DSM IV criteria (American Psychiatric Association 1994). He rarely produced any hand gestures, and his facial expression lacked animation. Neurological examination showed mild spastic

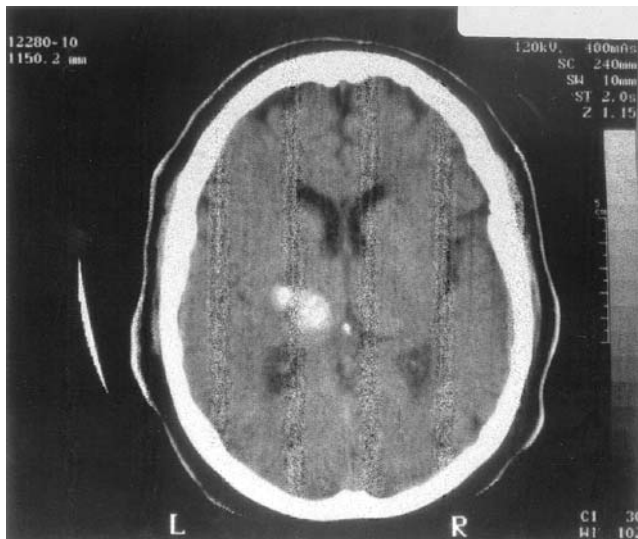


Fig. 1 CT scan showing the left thalamic lesion of the patient here reported, performed 50 days after insult. Left side of the brain shown on left side of the figure

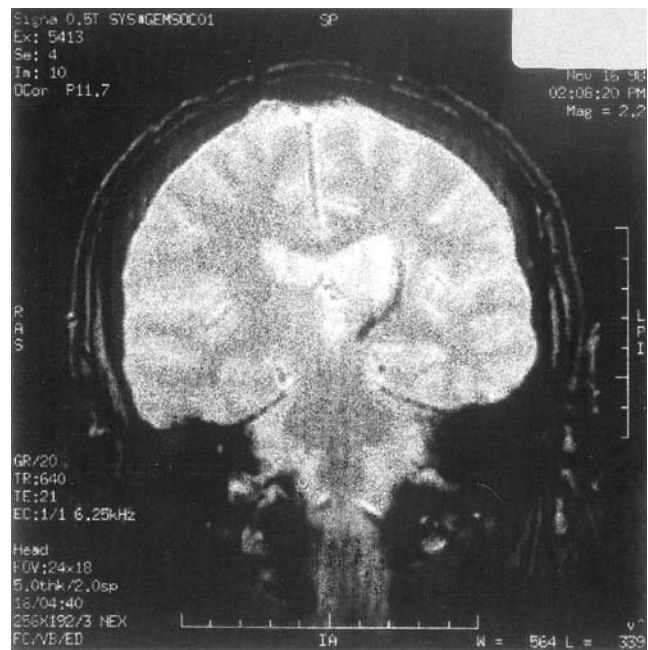


Fig. 2 Coronal MRI scan performed two and a half years after stroke showing the sequelae of the lesion (hemosiderin laden scar) encroaching upon the left thalamus. Left side of the brain shown on the right side of the figure

right hemiparesis with increased tendon reflexes and muscle weakness on the right half of the face; sensation was decreased on the right side of the body. Motor impersistence (Fisher 1956; Kertesz 1985; De Renzi et al. 1986) was also apparent. No visual field defect was demonstrable on a confrontation test. No frontal disinhibition signs (Tweedy et al. 1982) were present.

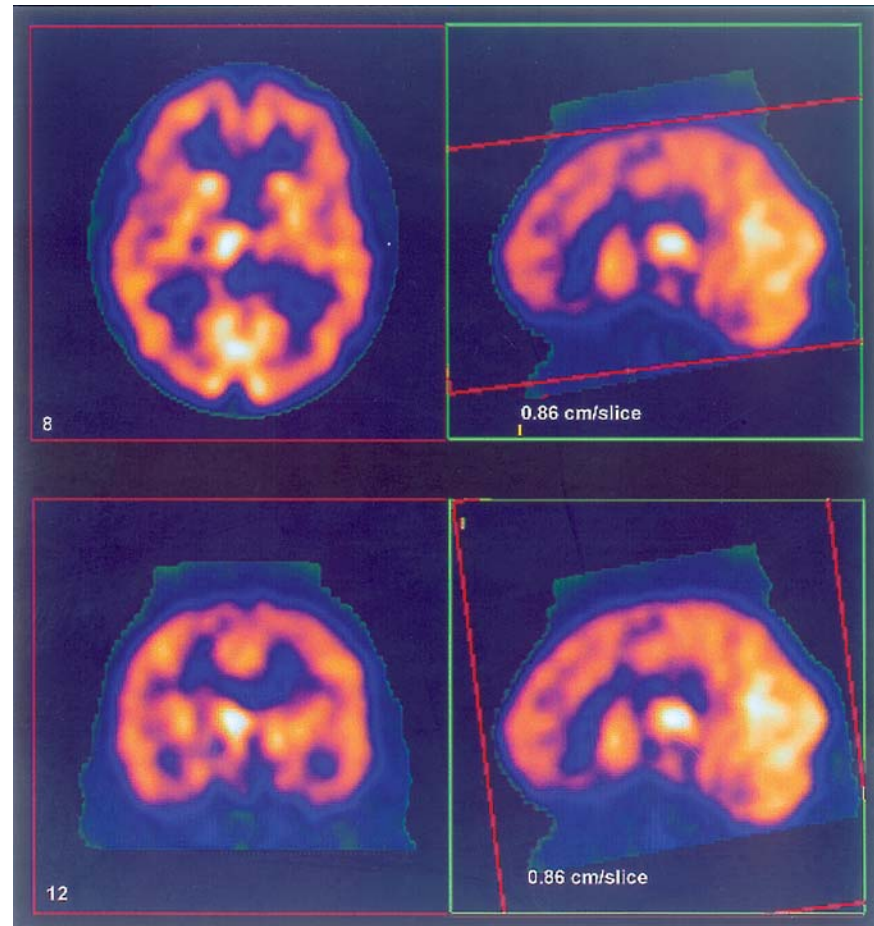
During the follow-up period the patient needed progressively less assistance in performing daily activities. Thirty months after onset he only showed a very mild right paresis with enhanced tendon reflexes, motor impersistence could still be observed, though less frequently than before.

He was strongly right-handed, scoring 100% on the Edinburgh Handedness Questionnaire (Oldfield 1971), and denied a family history of left-handedness. Moreover, he confirmed that he had always used his right foot to kick a ball and that he would peep through a keyhole with his right eye. Such consistent right-sidedness of hand, foot and eye is considered predictive of conventional cerebral dominance (Annett 1999, 2002; Elias and Bryden 1998; McManus et al. 1999). He had no history of early brain injury or seizures.

■ Neuropsychological examination

We tested the patient formally three times with a comprehensive battery of neuropsychological tasks, two

Fig.3 SPECT scan using 99m-Tc HMPAO tracer showing the left thalamic hypoperfusion and the lack of any sign of cortical diaschisis (performed two and a half years after stroke)



months after his stroke, 30 months and 76 months later (see Table 1). His raw scores have been adjusted for the influence of age, education and gender and compared with norms (Spinnler and Tognoni 1987).

His performance on tests assessing general non-verbal intelligence such as the Raven's Progressive Matrices (Basso et al. 1987) and the Weigl Card Sorting Test (Weigl 1947) was well within the normal range. The patient's performance on the Digit Cancellation Test (Della Sala et al. 1992), a time-constrained task meant to measure selective attention, was rather poor (see Table 1); however, his errors were all omission errors mainly due to his slowness in completing the test which could hardly account for his other manifest visuo-spatial deficits (Suzuki et al. 2003). He produced no false alarms. He also scored normally in tests of verbal short-term and long-term memory.

The patient's spontaneous language was free of aphasic errors. His speech sounded somewhat slowed, primarily because of its regularized cadence with few inflections. The flat, monotonic and aprosodic characteristics of his speech were consistent with those associated with right hemisphere lesions in patients with con-

ventional cerebral dominance not showing crossed aphasia (Ross et al. 1997; Mariën et al. 2004). His performance in a naming task was flawless, he performed above cut-off in the Token Test, a test of language comprehension (De Renzi and Faglioni 1978), and a standard language examination, the Aachen Aphasia Test (Luzzatti et al. 1987), did not disclose any deficits in spontaneous speech or writing. His relatives and friends did not notice any problems in his language communication skills after his stroke; however, they were baffled by his lack of prosody. The patient, tested with his left hand, performed well above the cut-off score on a standard task of ideomotor apraxia (De Renzi et al. 1980).

Furthermore, his imitation of twenty meaningful gestures (Cubelli et al. 2000) was flawless; the execution of the same gestures on verbal command (range 0–40, cut-off 24) was incorrect in seven cases but the total score (27) still within the normal limits. Asked to show the use of twenty common objects, he performed well with nineteen items. However, when he was asked to choose the picture showing the correct use of the same objects among three distractors (wrong orientation, wrong handling, used as different object) he failed on

Table 1 The patient's performance on neuropsychological tests, with normative data

	Adjusted scores 1 st assessment	Adjusted scores 2 nd assessment	Controls' inferential 5 th centile
Selective attention			
Digit Cancellation test (0–50)	21.8*	21.8*	24
Intelligence and executive functions			
Raven Progressive Matrices (0–36)	25.5	27.5	18
Weigl Sorting Test (0–15)	9.75	8.75	4.50
Memory			
Verbal Forward Span (0–inf)	4.25	4.25	3
Spatial Forward Span (0–10)	4	4	3.5
Learning of Word Pairs (0–22.5)	10.5	8.75	6.5
Supra-Span Spatial Learning (Corsi's blocks) (0–29.16)	8.74	9.37	6.75
Language			
Token Test (0–36)	26.5	–	26.5
Pictures denomination (0–32)	31.5	29.5	28.25
Praxis			
Ideo-motor Apraxia Test (0–72)	68	65	53
Spatial cognition			
Lines Orientation Judgement (0–30)	13*	14*	17
Constructional Apraxia (0–14)	7.25*	4.25*	7.75
Discrimination of Segments Length (0–32)	18	17*	18
Visual Forms Discrimination (0–32)	19*	20*	23
Visual perception			
Face Recognition Test (0–54)	45	42	38

* pathological score, i. e. below the 5th centile of normal distribution

five items, in three cases his errors were of orientation. He had no face apraxia on the formal imitation test proposed by De Renzi et al. (1966).

The patient never showed visuo-spatial neglect; this was confirmed by his performance on a number of tests. He did not omit any stimuli in a line cancellation test (Albert 1973) and in crossing out small stars (Halligan et al. 1989). Neither did neglect emerge in copying pictures, reading single letters, single words or whole phrases. Moreover, there was no evidence of visual, acoustic or tactile extinction formally assessed (tested with procedures reported by Cocchini et al. 1999).

In the absence of any signs of neglect or extinction, remarkably the patient failed several tests requiring visuo-spatial ability: Judgement of Line Orientation (Benton et al. 1978) and Visual Form Discrimination (Benton et al. 1983), and he showed signs of constructional apraxia (Arrigoni and De Renzi 1964). Recognition of facial expression (Pizzamiglio et al. 1983) was accurate only in nine cases out of eighteen. On the other hand he could name famous people spotted in magazines or in newspapers (famous faces were not formally tested) and recognised nurses and doctors, thus he showed no sign of prosopagnosia. His performance in matching unfamiliar faces (Benton et al. 1968) was also normal although he scored below cut-off in the last assessment (see Table 1).

On segment length discrimination and on spatial

short-term and long-term memory (Corsi's blocks, Milner 1971) his score was borderline.

The patient's performance on follow-up neuropsychological assessments was on the whole consistent with the previous one (see Table 1) and confirmed the impairment in spatial perception and visual discrimination in the absence of other deficits. The patient's verbal output was still clear and lacked prosodic fluctuations. We eventually retested the patient four years later: his performance on Judgement of Line Orientation (Benton et al. 1978), Visual Form Discrimination (Benton et al. 1983) and Unfamiliar Faces Recognition was still pathological.

Discussion

After a left thalamic lesion, our patient presented with good performance on tests taxing the left hemisphere's functions whilst he failed most of the tasks more sensitive to right hemisphere damage. This pattern points to a "crossed right-hemisphere syndrome". In particular, he showed impaired processing skills in visuo-spatial tasks, face expression problems and poor visuo-spatial memory coupled with motor impersistence, dysprosody and apathy, with no signs of contralateral visuo-spatial neglect or extinction. These deficits are normally associated with right cortical damage, but have also been re-

ported after right thalamic lesions (e.g., Watson and Heilman 1979; Stuss et al. 1988; Della Sala et al. 1997; Van der Werf et al. 2000).

The patient did not present with any sign of mental deterioration (though he did show some slowness in target detection) and showed no evidence of cognitive impairment associated with left hemisphere dysfunction; he showed little sign of language deficits, normal praxis and verbal memory.

The pattern of deficits shown by our patient was consistent in time; the assessments in the acute and chronic stages of his disease yielded similar outcomes. By contrast, in many cases of crossed aphasia the resultant language disturbances have been transient (Mariën et al. 2001).

In most instances neuropsychological deficits following thalamic stroke are associated with cortical hypometabolism (Verstichel 2003). We found no evidence of cortical diaschisis in the right hemisphere with SPECT. One possibility is that SPECT scanning does not have sufficient resolving power to detect relatively small blood flow decreases, which can be as small as 5% (Metter 1993). Nevertheless, neuropsychological signs following a thalamic lesion in the absence of diaschisis have been reported (Ferro et al. 1993).

This case restates the issue of lateralisation of different cognitive functions that is both of theoretical and practical interest. Some investigators have argued for lateralisation of visuo-spatial functions to the hemisphere contralateral to the language-dominant side of the brain. In other words, individuals with typical cerebral dominance have right-hemisphere visuo-spatial functions because large regions of the left hemisphere are required for speech, language, praxis and related functions (what Bryden refers to as the "casual complementary" model, Bryden 1990; Elias et al. 1999). Of course other alternatives include the idea that lateralization of different functions occurs independently of one another, or that anatomical asymmetries can drive functional lateralisation of both speech and visuo-spatial and/or emotional processing towards a single hemisphere in some cases (Annett 2004; Bryden 1990; Elias et al. 1999). Evidence from neurologically-intact participants selected for crossed lateral preferences (the most likely group to show unusual patterns of cerebral lateralisation) has been used to suggest that dominance of a single hemisphere for both speech (typically left dominant) and prosody (typically right dominant) is slightly more common than reversed laterality (left dominance for prosody and right dominance for language; Elias et al. 1999). Nevertheless, early arguments from the clinical literature and the data from our patient tend to support the casual complementary model (see also Hunt-Georgiadis et al. 2001). The consistent right-sided preferences of our patient make the crossed right hemisphere syndrome all the more remarkable, although the

Annett model does predict that consistent right sided preferences could emerge in individuals in the absence of conventional dominance, simply by chance (Annett 2002).

Since the observations of the first cases of crossed aphasia (Farge 1877; Bramwell 1899) it has become apparent that the rules of cerebral dominance, with language invariably linked to the left hemisphere, were far from uncomplicated. These cases suggested the possibility that not only language, but other functions as well could be sometimes represented in the "wrong" hemisphere. Brown and Wilson (1973) maintained that in crossed aphasics the left hemisphere should be dominant for visuo-spatial material. They put forward the hypothesis that representations of visuo-spatial functions are invariably located in the hemisphere contralateral to the one dominant for language. On the contrary, Alexander et al. (1989) posited that one third of crossed aphasics show impairments typical of right hemisphere damage, which would indicate right dominance for both language and visuo-spatial functions. However, most descriptions of patients with crossed aphasia only report language-related data; rarely have deficits of functions linked to the right hemisphere been properly investigated, with the partial exception of neglect.

Careful investigations of cases showing atypical cerebral dominance would allow us to better interpret the laws regulating lateralisation of cognitive functions. In particular, the issue of whether functions migrate in clusters (Castro-Caldas et al. 1987), or follow strict predetermined rules giving rise to predictable patterns of functional "situs inversus" (Kellar and Levick 1985) is still a matter of debate. A perusal of the literature on crossed aphasics seems to indicate that right and left hemisphere signs coexist in some patients (Haaland and Miranda 1982), and that several dissociations are possible, not necessarily mapping onto the predicted pattern of complete lateralisation. Indeed, cases of patients have been reported showing crossed limb or oral apraxia but not aphasia following a right hemisphere lesion (Alexander and Annett 1996; Marchetti and Della Sala 1997; Papagno and Della Sala 2000; Bizzozero et al. 2000).

Whether it is possible for right hemisphere functions to be represented in clusters rather than as a whole, and whether these clusters are consistent across patients are questions that could be tackled by examining patients with crossed right hemisphere syndrome. The neuropsychological profiles of the cases we could glean from the literature are summarized in Table 2, together with the current case.

This table does not encompass cases frequently quoted as presenting crossed right hemisphere syndrome if these could be accounted for by more strict interpretations. For example Taylor and Solomon's (1979) case H. B. had also a lesion in his right fronto-temporal

Table 2 Reported cases of crossed right hemisphere syndrome

Author(s)	Lesion locus	Interval	Mood	Denial	Attention deficits	Aphasia	Apraxia	Neglect	Constructive deficits	Visuo-spatial deficits	Dysprosody
Hunt-Georgiadis et al. 2001	LFTP	2 m	nr	no	nr	no	no	nr	nr	yes	nr
Han and Foo 1983	LFTP	12 w	nr	nr	nr	no	nr	yes	nr	nr	yes
Kellar et al. 1985	LFTP	nr	apathy	nr	nr	no	nr	yes	yes	yes	yes
Junqu� et al. 1986	LFTP	8 w	apathy	yes	no	no	yes	yes	yes	nr	yes
Judd 1989	LFP	4 w	apathy	yes	yes	no	yes	yes	yes	nr	yes
Lanoe et al. 1990	LFTP	nr	nr	no	nr	no	yes	yes	yes	nr	yes
Fischer et al. 1991 (c1)	LFTP	6 w	apathy	nr	yes	no	no	yes	yes	mild	yes
Fischer et al. 1991 (c2)	LFTP	6 w	apathy	yes	yes	no	yes	yes	yes	yes	yes
Fischer et al. 1991 (c3)	LP/LD	7 w	apathy	nr	yes	no	yes	yes	yes	yes	yes
Fischer et al. 1991 (c4)	LT	6 w	apathy	yes	yes	no	no	yes	yes	yes	yes
Cohen et al. 1991	LTP	3 w	nr	yes	nr	no	no	yes	nr	nr	yes
Selnes et al. 1991	LFTP	4 w	nr	yes	yes	no	yes	yes	nr	nr	nr
Posteraro et al. 1996	LFTP	nr	nr	nr	nr	no	no	yes	yes	nr	nr
Alexander et al. '96 (c1)	LFTP	11 w	nr	nr	yes	no	no	yes	yes	yes	yes
Alexander et al. '96 (c2)	LTP	8 w	nr	nr	yes	no	yes	yes	yes	yes	yes
Current case	LTh	7 w	no	no	yes	no	no	no	yes	yes	yes

Nr not reported; LFP left fronto-parietal; LFTP left fronto-temporo-parietal; LT left temporal; LTP left temporo-parietal; LP left parietal; LD left deep; m months; w weeks

region, which could not be ruled out as a contributor to his clinical picture. The patient reported by Cambier (1985) was most probably left-handed, while Heilman et al. (1974) did not report the precise locus of the lesion in their patient.

From Table 2 it appears that all patients, except the case here reported, presented with neglect. Moreover, they all showed constructive deficits, aprosodic speech and some mood modification (apathy). Visuo-spatial processing abilities have been less extensively tested but never reported as normal.

Some of the patients showing crossed right-hemisphere syndrome (Fischer et al. 1991 cases 1 and 4; Cohen et al. 1991; Posteraro et al. 1996) were neither aphasic nor apraxic despite a very large left hemisphere lesion. These may be regarded as having a complete inverse localisation (i.e. atypical dominance, Padovani et al. 1992). However, the lack of observed impairment within a given domain in patients with signs of crossed lateralisation does not necessarily imply that these functions be represented contralaterally to the lesioned hemisphere. Delreux et al. (1989) performed the Wada test on their patient with crossed aphasia; when his left hemisphere was inactivated, his performance on ideomotor apraxia tests was still flawless. One patient (Kellar et al. 1985) did not show aphasia while apraxia was not tested. In the remaining cases (Junqu  et al. 1986; Judd 1989; Lanoe et al. 1990; Fischer et al. 1991 cases 2 and 3) right hemisphere syndrome was associated with apraxia but not with aphasia. This pattern of deficits points to a right hemisphere dominance for language

and a left hemisphere control of "right" functions and praxis. This pattern confirms the possibility of an independence of praxis and language (Selnes et al. 1982; Marchetti and Della Sala 1997) and suggests the profile of "anomalous" dominance (Padovani et al. 1992) in our patient. The consistency of the absence of aphasia in cases reported in Table 2 has not to be regarded as the sign of a stronger left dominance for language than for praxis. These patients would probably not have been extensively tested on many other functions had they been aphasic as expected from their lesion site. Therefore, cases with crossed right hemisphere syndrome associated with aphasia might be overlooked.

Castro-Caldas et al. (1987) found an association between aphasia and ideomotor apraxia only in 17 % of 66 of cases with crossed aphasia. Alexander et al. (1989) reported a similar figure (i.e., 11 %). In contrast, from Table 2 it emerges that the crossed right hemisphere syndrome is more homogeneous. When tested, all the functions known to be controlled by the right hemisphere have been found to be impaired (with the exception of neglect in the current case). This result supports the idea put forward by Fischer et al. (1991) that "the traditional right hemisphere functions seem more robustly linked together than language and praxis or even than written and spoken language are to each other" (p 259).

The patient described here shows constructive and visuo-spatial deficits, aprosody, apathy, but not spatial neglect. He was also not anosognosic: he was also well aware of his illness and never denied his mild motor difficulties. The absence of neglect might be due to the rel-

atively long delay between his stroke and testing time. Neglect tends to improve in the first weeks after the stroke (Hier et al. 1983; Bisiach and Vallar 1988; Stone et al. 1991). Although not explicitly mentioned in the medical records, our patient might have shown neglect in the acute stages following the stroke. Alternatively the lack of neglect could be accounted for by the fact that his lesion was entirely subcortical with no diaschisis. Denial of illness is seldom mentioned in the description of cases reported in Table 2 and therefore it is quite possible that it was not often present. Therefore, the patient's pattern of spared and impaired functions might be consistent with that of the other cases. Alternatively, it is possible to interpret the observed discrepancies as an indicator of a possible dissociation between the different signs of the right hemisphere syndrome.

Some proposed theories of hemispheric lateralisation could account for the anomalies characterising crossed right hemisphere syndrome. Geschwind and Galaburda (1985) suggested that many factors (genetic or developmental or hormonal) might converge in generating a normal or atypical pattern of cerebral dominance. They refer to the right hemisphere as the ontogenetically older: this implies that it is less prone to disrupting influences. Hence, patients with right hemisphere crossed syndrome would be less numerous than those showing signs of some crossed left hemisphere functions. For the same reason, right hemisphere functions would be more strongly related to one another than language and praxis; consequently, the syndrome of crossed right hemisphere should present as all-en-

compassing more frequently than the left (Hécaen and Sauguet 1971; Alexander et al. 1989; Fischer et al. 1991).

Heilman et al. (1974) and Cohen et al. (1991) proposed that all cognitive functions could be lateralised independently from one another. If this were the case one would expect to find "anomalies" more frequently than Table 2 shows.

Castro-Caldas et al. (1987) stated that there are some different clusters of functions that could be located in either the right or the left hemisphere but several reported cases challenge this hypothesis. The cluster labelled "handedness and limb praxis" cannot account for the cases reported by Marchetti and Della Sala (1997) and by Raymer et al. (1999) who were both right-handed and both had a severe crossed apraxia. The cluster named "language and bucco-facial praxis" cannot accommodate the 48% of patients with crossed aphasia but with no signs of face apraxia reported by the authors themselves. The third cluster, which includes "visual neglect and other visuo-perceptive dysfunctions", is challenged by the case here reported.

In summary, this patient showed a clear presentation of a crossed right hemisphere syndrome, with deficits in prosody, visuo-construction and visuo-spatial tasks and no apraxia, aphasia or verbal memory deficits which are normally associated with left thalamic lesions (cf Johnson and Ojemann 2000; Karussis et al. 2000). The absence of left hemisphere hypometabolism, clear restriction of the lesion to the left thalamic region by both CT and MRI, and confirmed right hand, foot and eye preference make this case a particularly strong example.

References

1. Albert ML (1973) A simple test of visual neglect. *Neurology* 23:658–664
2. Alexander MP, Annett M (1996) Crossed aphasia and related anomalies of cerebral organization: Case reports and a genetic hypothesis. *Brain Lang* 55:213–239
3. Alexander MP, Fischette MR, Fischer RS (1989) Crossed aphasias can be mirror image or anomalous. Case reports, review and hypothesis. *Brain* 112:953–973
4. American Psychiatric Association (1994) Diagnostic and statistical manual of mental disorders 4th ed (DSM-IV). Washington DC: APA
5. Annett M (2002) Handedness and Brain Asymmetry: The Right Shift Theory. Hove, East Sussex: Psychology Press
6. Annett M (1999) Eye dominance in families predicted by the right shift theory. *Laterality* 4:167–172
7. Annett M (2000) Predicting combinations of left and right asymmetries. *Cortex* 36:485–505
8. Annett M (2004) Perceptions of the right shift theory. *Cortex* 40:143–150
9. Arrigoni C, De Renzi E (1964) Constructional apraxia and hemispheric locus of lesion. *Cortex* 1:170–197
10. Basso A, Capitani E, Laiacina M (1987) Raven's coloured progressive matrices: normative values on 305 adult normal controls. *Funct Neurol* 2:189–194
11. Basso A, Capitani E, Laiacina M, Zanolio ME (1985) Crossed aphasia: one or more syndromes? *Cortex* 2:25–54
12. Benton AL, Hamsher KK, Varney NR, Spreen O (1983) Contributions to Neuropsychological Assessment. A Clinical Manual. Oxford University Press, New York
13. Benton AL, Van Allen MW (1968) Impairment in facial recognition in patients with cerebral disease. *Cortex* 4:344–358
14. Benton AL, Varney NR, Hamsher K de S (1978) Visuospatial judgement: a clinical test. *Arch Neurol* 35:364–367
15. Benton AL, Hamsher K de S, Varney NR, Spreen O (1983) Contributions to Neuropsychological Assessment. New York: Oxford University Press
16. Bisiach E, Vallar G (1988) Hemineglect in humans. In: Boller F, Grafman J (eds) *Handbook of Neuropsychology*. Amsterdam: Elsevier, Vol. pp. 195–222
17. Bizzozero I, Costato D, Della Sala S, Papagno C, Spinnler H, Venneri A (2000) Upper and lower face apraxia: role of the right hemisphere. *Brain* 123: 2213–2230
18. Borod JC, Koff E, Perman-Lorch M, Nicholas M (1986) The expression and perception of facial emotion in brain-damaged patients. *Neuropsychologia* 24:169–180
19. Bramwell B (1899) On "crossed" aphasia and the factors which go to determine whether the "leading" or "driving" speech shall be located in the left or in the right hemisphere of the brain. *Lancet* 3:1473–1479

20. Brown JW, Wilson FR (1973) Crossed aphasia in a dextral. A case report. *Neurology* 23:907-911
21. Bryden MP (1990) Choosing sides: the left and the right of the normal brain. *Can Psychol* 31:297-309
22. Cambier J, Masson M, Guillot M, Robine R (1985) Négligence droite avec hémiasomatognosie, confusion mentale, apraxie et agraphie sans aphasie. *Rev Neurol (Paris)* 141: 802-806
23. Castro-Caldas A, Confraria A, Poppe P (1987) Non-verbal disturbances in crossed aphasia. *Aphasiology* 1: 403-413
24. Cocchini G, Cubelli R, Della Sala S, Beschin N (1999) Neglect without extinction. *Cortex* 35:285-313
25. Cohen L, Rémy P, Leroy A, Gèny C, Degos JD (1991) Minor hemisphere syndrome following left hemispheric lesion in a right handed patient. *J Neurol Neurosurg Psychiatry* 54:842-843
26. Cubelli R, Marchetti C, Boscolo G, Della Sala S (2000) Cognition in action: Testing a model of limb apraxia. *Brain Cogn* 44:144-165
27. Della Sala S, Laiacona M, Spinnler H, Ubezio C (1992) A cancellation test: its reliability in assessing attentional deficits in Alzheimer's disease. *Psychol Med* 22:885-901
28. Della Sala S, Spinnler H, Venneri A (1997) Persistent global amnesia following right thalamic stroke: an 11-year longitudinal study. *Neuropsychology* 11:90-103
29. Delreux V, de Partz MP, Kevers L, Callewaert A (1989) Aphasie croisée chez un droitier. *Rev Neurol (Paris)* 145: 725-728
30. De Renzi E, Gentilini M, Bazolli C (1986) Eyelid movement-disorders and motor impersistence in acute hemisphere disease. *Neurology* 36:414-418
31. De Renzi E, Faglioni P (1978) Normative data and screening power of a shortened version of the Token Test. *Cortex* 14:41-49
32. De Renzi E, Pieczuro A, Vignolo AL (1966) Oral apraxia and aphasia. *Cortex* 2:50-73
33. De Renzi E, Motti F, Nichelli P (1980) Imitating gestures: A quantitative approach to ideomotor apraxia. *Arch Neurol* 37:6-18
34. Elias LJ, Bryden MP (1998) Footedness is a better predictor of language lateralization than handedness. *Laterality* 3:41-51
35. Elias LJ, Bryden MP, Bulman-Fleming MB (1998) Footedness is a better predictor of emotional lateralization than is handedness. *Neuropsychologia* 36: 37-43
36. Elias LJ, Bulman-Fleming MB, Guylee MJ (1999) Complementarity of cerebral function among individuals with atypical laterality profiles. *Brain Cogn* 40:112-115
37. Farge E (1877) Hémiplegie gauche avec aphasie, observation suivie de quelques réflexions sur la gaucherie cérébrale. *Gazette Hebdomadaire de Médecine et de Chirurgie* 31:488-490
38. Ferro J, Cantinho G, Levy A, Godinho F (1993) Subcortical neglect: is cortical diaschisis relevant? In: Vallar G, Cappa S, Wallesch C-W (eds) *Neuropsychological disorders associated with subcortical lesions*. Oxford: Oxford University Press, pp 427-436
39. Fischer RS, Alexander M, Gabriel C, Gould E, Milione J (1991) Reversed lateralization of cognitive functions in right handers. Exceptions to classical aphasiology. *Brain* 114:245-261
40. Fisher M (1956) Left hemiplegia and motor impersistence. *J Nerv Ment Dis* 123:201-218
41. Geschwind N, Galaburda AM (1985) Cerebral lateralization. Biological mechanisms, associations and pathology: I. A hypothesis and a program for research. *Arch Neurol* 42:428-458
42. Haaland KY, Miranda F (1982) Psychometric and CT scan measurements in a case of CA in dextral. *Brain Lang* 17:240-260
43. Halligan PW, Marshall JC, Wade DT (1989) Visuospatial neglect: underlying factors and test sensitivity. *Lancet* 2:908-911
44. Han M, Foo S-H (1983) Negative evidence for language capacity in the right hemisphere: Revised lateralisation of cerebral function. In: Perecman E (ed) *Cognitive processing in the right hemisphere*. New York: Academic Press, pp 193-211
45. Hécaen H, Sauguet J (1971) Cerebral dominance in left-handed subjects. *Cortex* 7:19-48
46. Heilman KM, Gonyea EF, Geschwind N (1974) Apraxia and agraphia in a right-hander. *Cortex*, pp 284-288
47. Hier DB, Mondlock J, Caplan LR (1983) Recovery of behavioral abnormalities after right hemisphere stroke. *Neurology* 33:345-350
48. Hunt-Georgiadis M, Zysset S, Weih K, Guthke T, von Cramon Y (2001) Crossed nonaphasia in a dextral with left hemispheric lesions: A functional magnetic resonance imaging study of mirrored brain organization. *Stroke* 32:2703-2707
49. Joannette Y, Puel M, Nespoulous JL, Rascol A, Roch Lecours A (1982) Aphasie croisée chez les droitiers (Crossed aphasia in dextrals). *Rev Neurol (Paris)* 138:575-586
50. Johnson MD, Ojemann GA (2000) The role of the human thalamus in language and memory: evidence from electrophysiological studies. *Brain Cogn* 42:218-230
51. Judd T (1989) Crossed "right hemisphere syndrome" with limb apraxia: A case study. *Neuropsychology* 3: 159-173
52. Junqué C, Litvan I, Vendrell P (1986) Does reversed laterality really exist in dextrals? A case study. *Neuropsychologia* 24:241-254
53. Karussis D, Leker RR, Abramsky O (2000) Cognitive dysfunction following thalamic stroke: a study of 16 cases and a review of the literature. *J Neurol Sci* 172:25-29
54. Kellar LA, Levick SE (1985) Reversed hemispheric lateralization of cerebral functions: a case study. *Cortex* 21: 469-476
55. Kertesz A, Nicholson I, Cancelliere A, Kassa K, Black S (1985) Motor impersistence: A right hemisphere syndrome. *Neurology* 35:662-666
56. Laiacona M, Capitani E, Stangalino C, Lorenzi L (1996) Crossed aphasia. II: Why are deep lesions overrepresented with respect to standard aphasia? *Behav Neurol* 9:163-170
57. Lanoë Y, Liger C, Fabry B, Lanoë A, Sahloul MR, Benoit T, Ghnassi R (1990) Right hemiplegia and spatial neglect with apraxia and agraphia without aphasia in a right-handed patient. *Rev Neurol (Paris)* 146:368-371
58. Luzzatti C, Willmes K, Bisiacchi P, de Bleser R, Mazzucchi A, Posteraro L, Taricco M, Faglia L (1987) L'Aachener Aphasia Test (AAT). II. Qualità psicometriche della versione italiana del test (Psychometrics of the Italian version of the AAT). *Archiv Psychologia, Neurol Psychiatr* 48:480-519
59. Marchetti C, Della Sala S (1997) On crossed apraxia. Description of a right-handed apraxic patient with right supplementary motor area damage. *Cortex* 33:341-354
60. Mariën P, Engelborghs S, Vignolo LA, De Deyn PP (2001) The many faces of crossed aphasia in dextrals: report of nine cases and review of the literature. *Eur J Neurol* 8:643-658
61. Mariën P, Paghera B, De Deyn PP, Vignolo LA (2004) Adult crossed aphasia in dextrals revised. *Cortex* 40:41-74
62. McManus IC, Porac C, Bryden MP, Boucher R (1999) Eye-dominance, writing hand, and throwing hand. *Laterality* 4:173-192
63. Mesulam MM (1981) A cortical network for directed attention and unilateral neglect. *Ann Neurol* 10:309-325

64. Metter EJ (1993) Brain glucose metabolism in subcortical dementias. In: Vallar G, Cappa S, Wallesch C-W (eds) *Neuropsychological disorders associated with subcortical lesions*. Oxford: Oxford University Press, pp 242–260
65. Milner B (1971) Interhemispheric differences in the localization of psychological process in man. *Br Med Bull* 27:272–277
66. Novelli G, Papagno C, Capitani E, Laiconi M, Cappa S, Vallar G (1986) Tre test clinici di memoria verbale a lungo termine. Taratura su soggetti normali. *Archiv Psicologia, Neurol Psichiatria* 2:278–296
67. Oldfield RC (1971) The assessment and analysis of handedness: the Edinburgh inventory. *Neuropsychologia* 9:97–113
68. Padovani A, Pantano P, Frontoni M, Iacobini M, Dipiero V, Lenzi GL (1992) Reversed laterality of cerebral functions in a non-right-hander. *Neuropsychological and SPECT findings in a case of atypical dominance*. *Neuropsychologia* 30:81–89
69. Papagno C, Della Sala S (2000) Crossed face apraxia. *J Neurol Neurosurg Psychiatry* 69:694–695
70. Pizzamiglio L, Zoccolotti P, Mammucari A, Cesaroni R (1983) The independence of face identity and facial expression recognition mechanisms: relationship to sex and cognitive style. *Brain Cogn* 2:176–188
71. Posteraro L, Maravita A (1996) A new case of atypical cerebral dominance. *Ital J Neurol Sci* 17:237–240
72. Raymer AM, Merians AS, Adair JC, Schwartz RL, Williamson DJG, Rothi LJG, Poizner H, Heilman KM (1999) Crossed apraxia: implication for handedness. *Cortex* 35:183–199
73. Ross ED (1981) The aprosodias. Functional-anatomic organization of the affective components of language in the right hemisphere. *Arch Neurol* 38:561–569
74. Ross ED, Thompson RD, Yenkosky J (1997) Lateralisation of affective prosody in brain and the callosal integration of hemispheric language functions. *Brain Lang* 56:27–54
75. Selnes OA, Pestronk A, Hart J, Gordon B (1991) Limb apraxia without aphasia from a left sided lesion in a right handed patient. *J Neurol Neurosurg Psychiatry* 6:804–808
76. Selnes OA, Rubens AB, Risse GL, Levy RS (1982) Transient aphasia with persistent apraxia: uncommon sequela of massive left-hemisphere stroke. *Arch Neurol* 39:122–126
77. Spinnler H, Tognoni G (1987) Taratura e standardizzazione italiana di test neuropsicologici (Italian norms for a battery of neuropsychological tests). *Ital J Neurol Sci* 6:1–120
78. Stone SP, Wilson BA, Wroot A, Halligan PW, Lange LS, Marshall JC, Greenwood RJ (1991) The assessment of visuospatial neglect after acute stroke. *J Neurol Neurosurg Psychiatry* 54:345–350
79. Stuss DT, Guberman A, Nelson R, Larochelle S (1988) The neuropsychology of paramedian thalamic infarction. *Brain Cogn* 8:348–378
80. Suzuki K, Otsuka Y, Endo K, Ejima A, Saito H, Fujii T, Yamadori A (2003) Visuospatial deficits due to impaired visual attention: investigation of two cases of slowly progressive visuospatial impairment. *Cortex* 39:327–342
81. Tweedy J, Reding M, Garcia C, Schulman P, Deutsch G, Antin S (1982) Significance of cortical disinhibition signs. *Neurology* 32:169–173
82. Van der Werf YD, Witter MP, Uylings HBM, Jolles J (2000) Neuropsychology of the infarction in the thalamus: a review. *Neuropsychologia* 38:613–627
83. Verstichel P (2003) Mise au point. *Aphasie thalamique*. *Rev Neurol (Paris)* 159:947–957
84. Watson RT, Heilman KM (1979) Thalamic neglect. *Neurology* 29:690–694
85. Weigl E (1927) On the psychology of so-called processes of abstraction (translated) *J Abnorm Soc Psychol* 36:3–33
86. Woods DL, Knight RT (1986) Electrophysiologic evidence of increased distractibility after dorsolateral prefrontal lesions. *Neurology* 36:212–216