

West Nile virus presenting as opsoclonus-myoclonus cerebellar ataxia

Jaswinder S. Khosla, MD; Martin J. Edelman, MD;
Nancy Kennedy, RN, BSN; and Stephen G. Reich, MD

West Nile virus (WNV) first appeared in the Western hemisphere in 1999 with an outbreak in the New York City area causing meningitis, encephalitis, and muscular weakness.¹ To our knowledge, there has been only one other reported case of opsoclonus-myoclonus cerebellar ataxia due to WNV infection.²

Case report. A 62-year-old man with stage IV non-small cell lung cancer presented with 1 week of fever and lethargy. There was no headache. On admission he had a temperature of 101.4 °F. There was mild neck stiffness and a morbilliform rash on the trunk and neck. He was alert and fully oriented with a normal neurologic examination. An MRI of the brain was normal. CSF had 130 WBCs (68% lymphocytes, 28% PMNs, 8% monocytes with some plasma cells), protein 167 mg/dL, and glucose 72 mg/dL. He was treated for possible bacterial meningitis and herpes encephalitis. Over the next several days he became mildly encephalopathic and developed truncal and limb ataxia, myoclonus, and opsoclonus/ocular flutter (see the video on the *Neurology* Web site at www.neurology.org). By this time, WNV IgM antibodies in the serum and CSF were positive at 1:560 (Specialty Laboratories, Inc., Santa Monica, CA). Paraneoplastic antibodies anti-Yo, Hu, and Ri were negative. He improved with supportive care only. Two months after admission his mental status was near normal, the opsoclonus and myoclonus had resolved, and the ataxia had improved. He remained neurologically stable but his lung cancer recurred and he died 14 months after presentation with WNV.

Discussion. West Nile is a flavivirus transmitted naturally among birds by mosquitoes. Traditionally, humans were considered dead end hosts, unable to transmit the virus. Recently, however, WNV has been observed to transmit through blood transfusions, organ donation, and placenta. Most individuals infected with WNV remain asymptomatic, outnumbering symptomatic illness by at least 100:1. Susceptibility increases with age, chronic illness, and immunosuppression.³

Since 1999, the virus has spread rapidly throughout the United States. In 2003, there were 9,862 cases reported to the CDC, of which 2,866 were neuroinvasive, with 264 deaths. As of September 24, there were 1,657 reported cases in 2004, including 594 neuroinvasive, and 53 deaths.⁴ Neuroinvasive is the term used by the CDC to include meningitis and meningoencephalitis.⁴ WNV also causes acute flaccid paralysis,⁵ as well as focal parenchymal involvement of the cerebellum, brainstem, rhombencephalon, or spinal cord. Additional manifestations include hyperkinetic movement disorders such as tremor and myoclonus, parkinson-

ism, cranial neuropathy, and optic neuritis.³ There is only one other report of WNV presenting as opsoclonus-myoclonus ataxia.²

Opsoclonus, also called "saccadomania," belongs to the category of eye movements known as saccadic intrusions, which are unwanted saccades that interrupt steady fixation.⁶ When the saccades occur in multiple planes, without an intersaccadic interval, they are referred to as opsoclonus and when in only one plane, usually horizontal, are called ocular flutter. Both opsoclonus and ocular flutter are often accompanied by myoclonus and ataxia. The most common causes of opsoclonus include viral brainstem encephalitis, paraneoplastic, and drugs.⁶

The pathogenesis of opsoclonus/ocular flutter is unknown but it has been proposed to result from dysfunction of the brainstem omnipause neurons thus removing their normal tonic inhibition on saccadic burst neurons.⁶ Yet this has been challenged by the finding of spared omnipause neurons in paraneoplastic opsoclonus. Instead, opsoclonus may be generated by disinhibition of the oculomotor region of the fastigial nucleus (FOR) by processes that interfere with inhibitory projections from the Purkinje cells of the deep cerebellar nuclei to the FOR.⁷

We considered the possibility of paraneoplastic opsoclonus-myoclonus ataxia in our patient but thought it unlikely due to the histology of his lung cancer (non-small cell), the acute presentation with fever, marked CSF pleocytosis with PMNs, negative paraneoplastic antibodies, and especially the spontaneous improvement. The presence of IgM antibodies in the CSF and serum support the diagnosis of WNV as the cause of opsoclonus-myoclonus ataxia.

From the Department of Neurology (Drs. Khosla and Reich) and Greenebaum Cancer Center (Dr. Edelman and N. Kennedy), The University of Maryland School of Medicine, Baltimore, MD.

Received October 1, 2004. Accepted in final form November 19, 2004.

Address correspondence and reprint requests to Dr. Stephen G. Reich, Department of Neurology, The University of Maryland School of Medicine, 22 South Greene Street, N4W46, Baltimore, MD 21201; e-mail: sreich@som.umaryland.edu

Copyright © 2005 by AAN Enterprises, Inc.

References

1. Nash D, Mostashari F, Fine A, et al. 1999 West Nile Outbreak Response Working Group. The outbreak of West Nile virus infection in the New York City area in 1999. *N Engl J Med* 2001;344:1807-1814.
2. Sayao AL, Suchowersky O, Al-Khathaami A, et al. Calgary experience with West Nile virus neurological syndrome during the late summer of 2003. *Can J Neurol Sci* 2004;31:194-203.
3. Tyler K. West Nile virus infection in the United States. *Arch Neurol* 2004;61:1190-1195.
4. Centers for Disease Control and Prevention, Division of Vector-Borne Diseases. West Nile Virus. Available at: http://www.cdc.gov/ncidod/dvbid/westnile/surv&controlCaseCount03_detailed.htm.
5. Sejvar JJ. West Nile virus and poliomyelitis. *Neurology* 2004;63:206-207.
6. Leigh RJ, Zee DS. The neurology of eye movements, third ed. New York: Oxford University Press, 1999:451-456.
7. Wong AMF, Musallam S, Tomlinson RE, Shannon P, Sharpe JA. Opsoclonus in three dimensions: oculographic, neuropathologic and modeling correlates. *J Neurol Sci* 2001;189:71-81.

Additional material related to this article can be found on the *Neurology* Web site. Go to www.neurology.org and scroll down the Table of Contents for the March 22 issue to find the title link for this article.

Visual field defect and intracerebral hemorrhage associated with use of vardenafil (Levitra)

Hall T. McGee, MD; Robert A. Egan, MD;
and Wayne M. Clark, MD

One case of ischemic stroke¹ and two cases of intracerebral hemorrhage (ICH)^{2,3} have been reported in association with sildenafil. We report a patient with ICH following vardenafil ingestion.

Case report. A 66-year-old healthy Caucasian man had erectile dysfunction and had used sildenafil successfully in the past. He had recently used 10 mg of vardenafil without effect, so on the night prior to onset of his symptoms, he took 20 mg at once, the maximum recommended dose. He achieved an erection and had sexual intercourse approximately 6 hours later. He developed a mild headache after ingestion of medication that moderately worsened after intercourse. He was otherwise asymptomatic for any

other neurologic symptoms prior to sleeping. Upon awakening the next morning with an inability to see to the left and imbalance and continuing headache, he went to the emergency room. He also reported intermittent vertical diplopia. He was not using any medications legally or illegally, including over-the-counter agents, herbal supplements, or stimulants. Past medical history was negative, including hypertension, dementia, bleeding diatheses, hypercholesterolemia, and alcohol and tobacco use. There was also no history of prior stroke or head trauma.

Physical examination on admission revealed a blood pressure of 107/66 mm Hg. He had a left homonymous hemianopia by gross confrontation testing and a slow and unsteady gait. There were no other findings and no ocular motor disturbance. Prothrombin and partial thromboplastin times were normal, and a toxicology screen was not performed. CT scan of the head without contrast material revealed a right posterior parietal primary ICH. Cerebral angiography showed no evidence of arteriovenous malformation, aneurysm, or other irregularity to explain the hemorrhage. Likewise, MRI with and without gadolinium performed on the day of presen-

tation and repeated 6 weeks later revealed no evidence of underlying neoplasm or vascular lesion or any prior hemorrhages. Eight weeks after the event, his left hemianopia improved to a small relative left homonymous inferior sectoranopia. His blood pressure was 110/70 mm Hg.

Discussion. More than 16 million men have used sildenafil since its introduction, and there have been two reported cases of ICH associated with its use.^{2,3} Vardenafil recently entered the market and has not yet had the degree of exposure that sildenafil has had. We reviewed the database of the World Health Organization (WHO; September 2004) and found 14 cases of cerebral infarction reported with sildenafil use and 1 case reported with tadalafil. None have been reported to date with vardenafil. There have been 17 cases of visual field defect reported with sildenafil use only, but some of these may be related to those cases reported in association with anterior ischemic optic neuropathy, as this has been reported in the medical literature previously.^{4,6} The WHO does not recognize ICH in their database so the prevalence of ICH associated with any drug cannot be ascertained.

We do not know the role of vardenafil in the causation of ICH. Phosphodiesterase 5 inhibitors are not known to cause either elevation of blood pressure or abnormalities in the coagulation system. Also, sexual intercourse is probably not associated with an increased risk of ICH as we are aware of only one reported case.⁷ It is possible that altered cerebral autoregulation occurred that led to ICH in our patient, but there are no corroborating data. Despite the lack of a pathogenic mechanism of action, the timing of the onset of his symptoms relative to ingestion of the medication is suggestive of a possible association.

From the Casey Eye Institute (Drs. McGee and Egan), Department of Ophthalmology, Department of Neurology (Dr. Clark), and Department of Neurosurgery (Dr. Egan), Oregon Health and Science University, Portland.

Supported by an unrestricted grant from Research to Prevent Blindness, New York, NY.

This study conformed to the protocol of our institutional review board (IRB) and did not require approval by our IRB.

Received October 14, 2004. Accepted in final form November 19, 2004.

Address correspondence and reprint requests to Dr. R.A. Egan, Casey Eye Institute, 3375 S.W. Terwilliger Blvd., Portland, OR 97201; e-mail: eganr@ohsu.edu

Copyright © 2005 by AAN Enterprises, Inc.

References

1. Morgan JC, Alhatou M, Oberlies J, Johnston KC. Transient ischemic attack and stroke associated with sildenafil (Viagra) use. *Neurology* 2001;57:1730–1731.
2. Monastero R, Pipia C, Camarda LK, Camarda R. Intracerebral haemorrhage associated with sildenafil citrate. *J Neurol* 2001;248:141–142.
3. Buxton N, Flannery T, Wild D, Bassi S. Sildenafil (Viagra)-induced spontaneous intracerebral haemorrhage. *Br J Neurosurg* 2001;15:347–349.
4. Pomeranz HD, Smith KH, Hart WM Jr, Egan RA. Sildenafil-associated nonarteritic anterior ischemic optic neuropathy. *Ophthalmology* 2002; 109:584–587.
5. Boshier A, Pambakian N, Shakir SA. A case of nonarteritic ischemic optic neuropathy (NAION) in a male patient taking sildenafil. *Int J Clin Pharmacol Ther* 2002;40:422–423.
6. Egan R, Pomeranz H. Sildenafil (Viagra) associated anterior ischemic optic neuropathy. *Arch Ophthalmol* 2000;118:291–292.
7. Finelli PF. Coital cerebral hemorrhage. *Neurology* 1993;43:2683–2685.

Extreme spindles: A distinctive EEG pattern in *Mycoplasma pneumoniae* encephalitis

Chad R. Heatwole, MD; Michel J. Berg, MD;
J. Craig Henry, MD; and Jamika L. Hallman

Extreme spindles are diffuse, continuous, high voltage, frontocentral, 8- to 15-Hz spindles thought to be an unusual exaggeration of normal sleep spindles.¹ Historically, this EEG pattern was described and termed extreme spindles by Gibbs and Gibbs in 1962.¹ Extreme spindles typically occur in children aged 1 to 12 years. They have been associated with such conditions as cerebral palsy, residual brain damage, undefined infections, infantile neuroaxonal dystrophy, Menkes' kinky-hair syndrome, and congenital muscular dystrophy.²⁻⁴ There is one case report of extreme spindles in a 4-year-old Japanese boy during a subacute phase of mycoplasma encephalitis.⁵ We report a previously healthy child with an acute *Mycoplasma pneumoniae* encephalitis whose early EEG demonstrated extreme spindles before the pneumonia diagnosis was confirmed by mycoplasma antibodies.

Case report. An 11-year-old boy presented with a new onset seizure. He was in good health when he developed a nonpurulent cough, a sore throat, and fatigue. Over a week's time his daily sleep increased from 8 hours to 14 hours a day with frequent naps after school. On the day of admission he was noted by his mother to have a generalized seizure lasting 5 minutes. At a local hospital, the patient's temperature was 40.4 °C. For airway protection he was intubated and started on vancomycin, ceftriaxone, dexamethasone, and phenytoin. A CT scan of the head was normal. A chest X-ray showed a right upper lobe airspace opacity, and a lumbar puncture had 22,000 WBC per mm³, with 100% lymphocytes, a glucose of 125 mg/dL, and a protein of 95 mg/dL. On examination the patient was somnolent, but had an intact cranial nerve, motor, and sensory examination. He had bilateral Babinski signs with diffuse hyperreflexia. Crackles were heard at his right upper lung field.

An EEG on hospital day 2 demonstrated diffuse high voltage, continuous, 12-Hz spindle activity in the frontocentral regions consistent with extreme spindles (figure). Additionally, the EEG had high voltage delta activity without epileptiform discharges, paroxysmal features, or interhemispheric asymmetries.

The patient clinically improved throughout his hospital stay, and on hospital day 3 was extubated. Serum, sputum, and CSF (viral, bacterial, and fungal) cultures were normal. His brain was

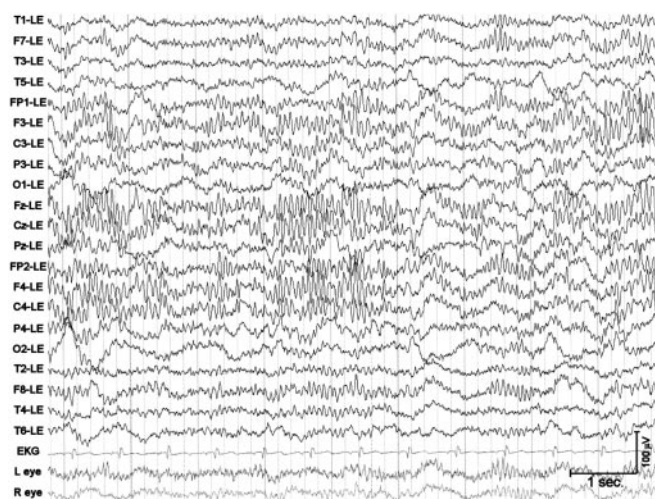


Figure. Extreme spindles in an 11-year-old boy with an acute mycoplasma encephalitis.

normal on an MRI of the head. On hospital day 4, the patient was found to be at his normal baseline, and was discharged home. Given the negative culture data, he was switched from broad-spectrum antibiotics to a 14-day regimen of doxycycline for a suspected atypical pneumonia and meningoencephalitis.

One day after discharge, the patient's serum antibodies for *M pneumoniae* returned with a positive serum titer of 2.74 (normal range < 0.95). The patient completed his antibiotic course for mycoplasma pneumonia with meningoencephalitis, and has not had any adverse sequelae.

Discussion. Mycoplasma pneumoniae is one of the most common causes of atypical pneumonia in the world.⁶ Of hospitalized patients with mycoplasma pneumonia, 7% develop CNS symptoms including aseptic meningitis, meningoencephalitis, seizures, peripheral neuropathy, transverse myelitis, and cerebellar ataxia.^{6,7} There is 8% mortality in this group, and 23% have serious sequelae.⁷

The presence of extreme spindles in our case and the one previously reported in a subacute case of mycoplasma encephalitis

Neurology®

Visual field defect and intracerebral hemorrhage associated with use of vardenafil (Levitra)

Hall T. McGee, Robert A. Egan and Wayne M. Clark

Neurology 2005;64;1095-1096

DOI 10.1212/01.WNL.0000154468.11834.41

This information is current as of March 21, 2005

Updated Information & Services

including high resolution figures, can be found at:
<http://www.neurology.org/content/64/6/1095.2.full.html>

References

This article cites 7 articles, 2 of which you can access for free at:
<http://www.neurology.org/content/64/6/1095.2.full.html#ref-list-1>

Citations

This article has been cited by 1 HighWire-hosted articles:
<http://www.neurology.org/content/64/6/1095.2.full.html#otherarticles>

Subspecialty Collections

This article, along with others on similar topics, appears in the following collection(s):
All Cerebrovascular disease/Stroke
http://www.neurology.org/cgi/collection/all_cerebrovascular_disease_stroke
All Toxicology
http://www.neurology.org/cgi/collection/all_toxicology
Intracerebral hemorrhage
http://www.neurology.org/cgi/collection/intracerebral_hemorrhage

Permissions & Licensing

Information about reproducing this article in parts (figures, tables) or in its entirety can be found online at:
<http://www.neurology.org/misc/about.xhtml#permissions>

Reprints

Information about ordering reprints can be found online:
<http://www.neurology.org/misc/addir.xhtml#reprintsus>

Neurology® is the official journal of the American Academy of Neurology. Published continuously since 1951, it is now a weekly with 48 issues per year. Copyright . All rights reserved. Print ISSN: 0028-3878. Online ISSN: 1526-632X.

