

Primary Cerebral Angiitis Containing Marked Xanthoma Cells With Massive Intraparenchymal Involvement

—Case Report—

Eiichi ISHIKAWA, Koji TSUBOI, Shingo TAKANO, Hiroshi KIMURA,
Tsukasa AOKI, Ryota MASHIKO, and Michio NAGATA*

Department of Neurosurgery, Institute of Clinical Medicine, and *Department of Pathology,
Institute of Basic Medical Sciences, University of Tsukuba, Tsukuba, Ibaraki

Abstract

A 27-year-old woman was referred to our hospital with mild disorientation, bilateral abducens nerve palsy, and mild left hemiparesis. Magnetic resonance (MR) imaging revealed diffuse mass lesions resembling malignant glioma in the right frontal intraparenchymal region, with enhancement of multiple meningeal and intraparenchymal nodules. Partial resection of the frontal lesion was performed. Histological examination revealed that the specimens consisted of brain tissue, with marked perivascular infiltration of histiocytes and sheets of xanthomatous cells. The diagnosis was primary cerebral angiitis containing marked xanthoma cells. Steroid therapy was administered over 1 week. MR imaging showed that the remaining lesions resolved gradually, and had disappeared 2 years after surgery. No neurological symptoms or recurrence of the tumor has been observed during the 6-year period since the operation.

Key words: complete resolution, granulomatous angiitis of the central nervous system, granulomatous lesion, vasculitis, xanthogranuloma, xanthoma cell

Introduction

Cerebral angiitis/granulomatous angiitis are general pathological diagnoses based on several findings including inflammatory/granuloma cells in the vascular walls. Cerebral angiitis/granulomatous angiitis have multiple causes, including infectious agents, sarcoidosis, autoimmune disease, and idiopathic vasculitis. Primary (or idiopathic) cerebral angiitis/granulomatous angiitis is very rare. Most cases of primary cerebral angiitis/granulomatous angiitis are categorized into some distinct clinicopathological entities. Granulomatous angiitis of the central nervous system (GACNS) is characterized by granulomatous change with infiltration of giant cells and other variable inflammatory cells into the walls of the leptomeningeal and/or parenchymal vessels.^{4,8,9,18,19} Primary angiitis of the central nervous system (PACNS) is clinically characterized by vasculitis confined to the CNS and exclusion of other diseases.^{13,15} Similar pathological conditions have been described as isolated angiitis of the CNS,

granulomatous giant cell angiitis of the CNS, and benign focal cerebral vasculitis.^{1,13,15} All these diseases are closely related.^{13,15} “Non-infectious granulomatous encephalitis” also manifests as granulomatous change and perivascular/intraparenchymal inflammation.¹¹ The magnetic resonance (MR) imaging appearance of primary cerebral angiitis/granulomatous angiitis is variable, sometimes as mass lesions resembling brain tumors with a diffuse pattern,^{9,13,16,17} or meningeal enhancement manifesting as multiple nodules.¹⁸

Here we describe a very rare case of primary cerebral angiitis with typical xanthoma cells, which resembled glioblastoma multiforme on neuroimaging.

Case Report

A 27-year-old woman was admitted to a regional hospital with morning headache. One week before admission, her family had noticed a change in her personality and mild disorientation. She had suffered a head injury during a traffic accident 6 months before admission, the details of which were

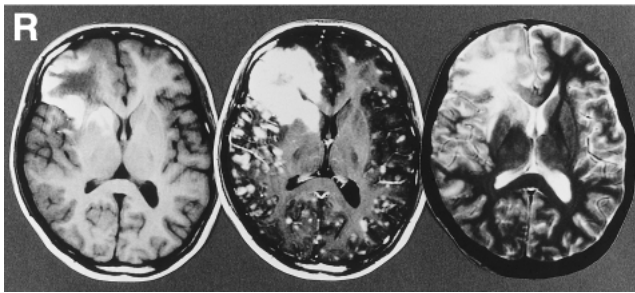


Fig. 1 T₁- (left) and T₂-weighted (right) magnetic resonance (MR) images showing mixed intense lesions without clear margins in the right frontal lobe. T₁-weighted MR image after gadolinium administration (center) showing intense enhancement of the right frontal lesion and multiple nodules in the meningeal/intraparenchymal regions.

obscure because of disturbance in consciousness and absence of medical treatment. She had no history of specific infectious disease or autoimmune disease.

Physical examination revealed no abnormality on her skin or body. Neurological examination revealed mild disorientation, bilateral abducens nerve palsy, and mild weakness of the left arm and foot. All blood chemistry findings, including white blood cell count, C-reactive protein, neutral fat, and total cholesterol levels, and various tests for autoimmune diseases, were normal. Lumbar tapping obtained watery clear cerebrospinal fluid (CSF) with a slightly increased cell count (8 cells/ μ l, all monocytes). Other findings of the CSF, including protein concentration and sugar concentration, were normal. Cultures of the CSF for fungus and bacteria were all negative. The viral antibody titers (cytomegalovirus, varicella-zoster virus, mumps virus, herpes simplex virus, coxsackie A7, enterovirus 71) of the CSF were also negative.

Computed tomography with contrast agent revealed a diffuse lesion in the right frontal lobe. MR imaging also revealed mixed intense lesions without clear margins on both T₁- and T₂-weighted images. Median structures containing the interhemispheric cistern were shifted to the left. Gadolinium administration caused intense enhancement of the right frontal lesion and multiple nodules in the meningeal and intraparenchymal regions (Fig. 1). The initial diagnosis was intra-axial malignant tumor, such as glioblastoma multiforme.

Three weeks after admission, right frontal craniotomy and resection of the right frontal lobe were performed. During surgery, mild thickening of

the arachnoid membrane and xanthous change of the frontal cortex were observed. Partial resection of the frontal lesion was performed. The margins of the mass lesions were not clear, and no obvious nodular lesions were found compatible with the MR imaging findings. Histological examination revealed that the specimens consisted of edematous brain tissue with perivascular and transmural focal infiltrations of small lymphocytes and histiocytes in the leptomeningeal/parenchymal small vessels (Fig. 2 upper row), and necrosed tissue produced by the occlusion of small vessels. Infiltration with sheets of CD68-positive foamy cells as well as perivascular proliferation of small histiocytes and other infiltrating cells were observed in the damaged brain tissue (Fig. 2 lower row). No giant cells of the Touton type were observed. Immunohistochemical staining for glial fibrillary acidic protein (GFAP), S-100 protein, and lysozyme was negative. Silver staining found no indications of demyelinating disease. Electron micrography revealed foamy cells with small nuclei and plump cytoplasm containing lipid droplets, which corresponded to so-called xanthoma cells. The histological diagnosis was primary cerebral angiitis containing marked xanthoma cells.

The patient was treated with intravenous administration of 16 mg dexamethasone per day, which was tapered rapidly and completed within 1 week of the operation. The postoperative course was uneventful, with full recovery from disorientation and all neurological disturbances. MR imaging showed spontaneous gradual shrinkage of the mass lesions, and absence of residual lesions 2 years later (Fig. 3). Several tiny spots were detected along the margins of the surgical defect in the right frontal and the left high frontal lesions, but no recurrence was observed during the 6-year period since the operation.

Discussion

Our patient presented with a history of a head injury 6 months before admission, and multiple intraparenchymal diffuse lesions mimicking glioblastoma which resolved completely within 2 years of surgery. The histological features of the present case were granulomatous tissue containing xanthoma cells, marked perivascular inflammation, absence of giant cells of the Touton type, and diffuse progression with destruction of brain tissue. The initial diagnosis was malignant brain tumor such as glioblastoma. Retrospectively, there were some discrepancies in the clinical findings with a diagnosis of rapidly growing tumor. The patient presented with only mild disorientation and headache despite the very large mass lesion in the right frontal lobe. The

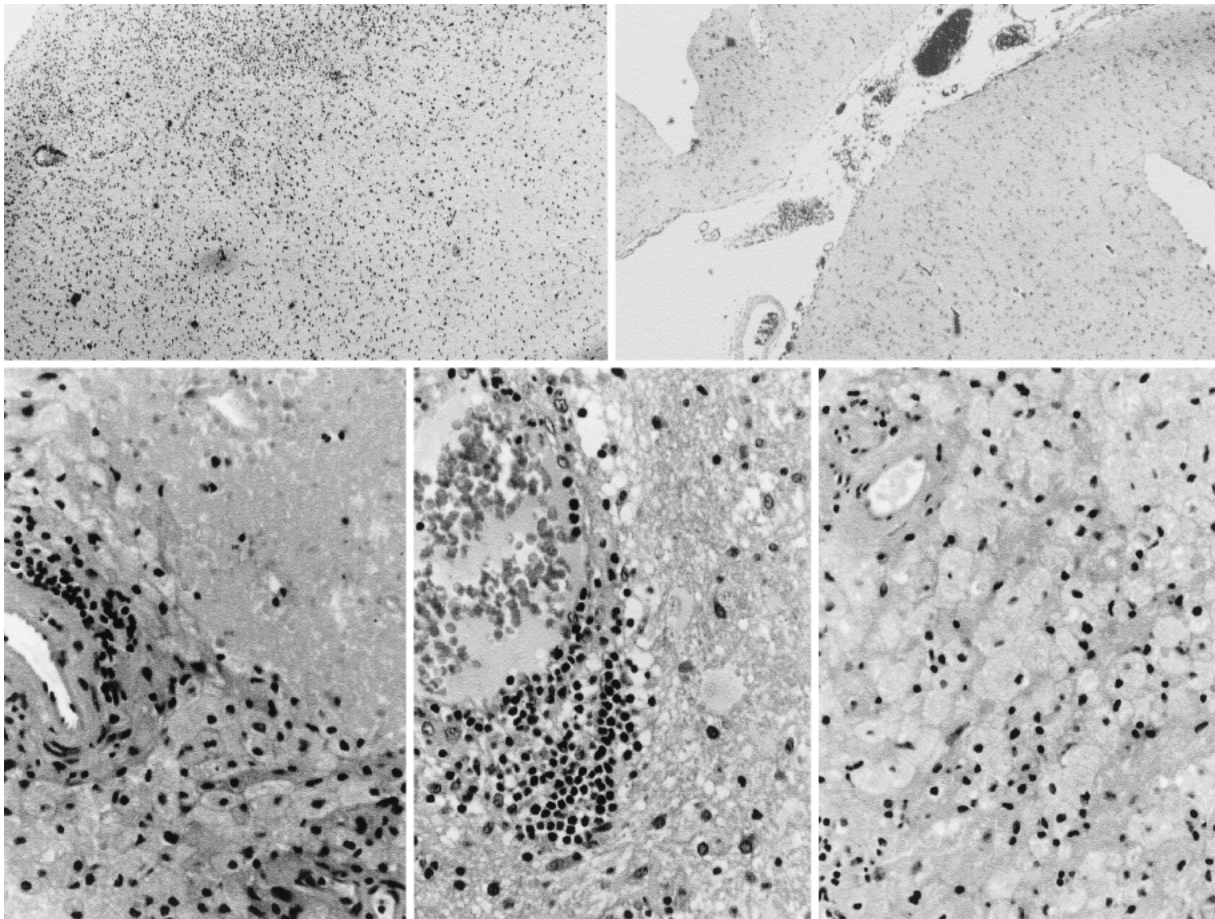


Fig. 2 upper row: Photomicrographs showing edematous brain tissue with perivascular and transmural focal infiltrations of small lymphocytes and histiocytes in the meningeal and parenchymal small arteries with marked thickening of the intima. lower row: Photomicrographs revealing sheets of foamy cells as well as perivascular inflammation of small histiocytes and other infiltrating cells. Hematoxylin and eosin stain, upper row: $\times 100$ and lower row: $\times 400$.

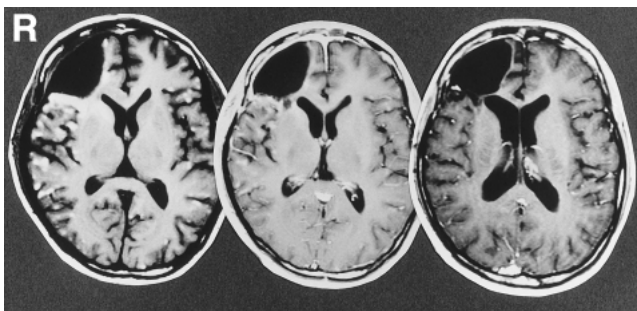


Fig. 3 Axial T_1 -weighted magnetic resonance images with gadolinium just after the operation (left), 1 month after the operation (center), and 6 months after the operation (right) showing rapid disappearance of the lesions.

peripheral hyperintense lesion on T_2 -weighted MR imaging and the midline shift were too slight for ordinary glioblastoma. The actual volume of brain tissue with severe pathological abnormality was much smaller than expected based on the MR images. Furthermore, the lesions resolved rapidly after the administration of dexamethasone. Retrospectively, biopsy of the lesion and steroid therapy should have been considered as a therapeutic strategy. However, we speculate that the most destructive lesion containing many xanthoma cells would not be improved without radical resection.

In the present case, it was essential to exclude inflammatory diseases other than primary cerebral angiitis. The tissue specimen yielded no evidence of any organism associated with tubercle bacillus, sarcoidosis, or parasites such as *Toxoplasma gondii*. Langerhans cell histiocytoses, malignant histiocyto-

ses, and several neoplasms such as meningiomas and gliomas could be excluded based on the clinical course and the immunohistochemical studies using GFAP and S-100 protein. Demyelinating diseases were also eliminated by silver staining.

Xanthogranuloma was considered because the present case featured xanthoma cells. Xanthoma cell is considered to be a subtype of activated macrophages/histiocytes, and occurs not only in xanthogranulomas but also in other conditions including several diseases associated with myelin breakdown and special conditions of brain neoplasms.¹⁰⁾ The histological diagnosis of intracranial xanthogranulomas is based on the presence of proliferation of histiocytic cells, collection of xanthoma cells, multinucleated giant cells of the Touton type, and inflammatory cells.^{2,10)} Xanthogranuloma usually occurs as solitary lesion, but is known to disseminate into multiple intracranial regions.^{5,7)} Some xanthogranulomas originate from the intraventricle choroid plexus or the subdural space, but intraparenchymal xanthogranulomas are extremely rare.^{3,6,12,14)} In addition, most xanthogranulomas are space-occupying lesions with fibrous capsules. Only one case of a small intraparenchymal mass lesion was not sharply demarcated from the surrounding parenchyma.¹⁴⁾

The histological features of the present case were not exactly compatible with typical xanthogranulomas because of the marked perivascular inflammation, absence of giant cells of the Touton type, and diffuse progression with destruction of brain tissue, or with typical GACNS/PACNS because of the marked inflammation caused by xanthoma cells. Therefore, the final diagnosis was primary cerebral angiitis containing marked xanthoma cells, closely related (but not exactly compatible) with GACNS/PACNS. Although the precise mechanism of the histogenesis of xanthoma cells in our case is not known, macrophages/histiocytes located in the perivascular inflammation may have undergone secondary changes to become characteristic xanthoma cells after infiltration and proliferation.

The clinical courses of patients with primary cerebral angiitis/granulomatous angiitis are variable, but patients treated with steroids with/without cyclophosphamide have had relatively good overall outcomes.^{13,19)} Our patient recovered well with disappearance of the MR imaging lesions after steroid therapy.

The present case of primary cerebral angiitis containing marked xanthoma cells mimicking glioblastoma had pathological characteristics unlike those of previous cases. The mass showed rapid progression on MR imaging, but was reversible and

resolved completely with very good outcome. Inflammatory diseases should be considered in the differential diagnosis of such multiple enhanced masses.

Acknowledgments

We are very grateful to M. Noguchi of the Department of Pathology, Institute of Basic Medical Sciences, University of Tsukuba, Y. Nakazato of the First Department of Pathology, Gunma University School of Medicine, Maebashi, Gunma, and K. Nagashima of the Department of Pathology, Hokkaido University School of Medicine, Sapporo, Hokkaido, for their comments on the pathological findings.

References

- 1) Berger JR, Romano J, Menkin M: Benign focal cerebral vasculitis. *Neurology* 45: 1731-1734, 1995
- 2) Bostrom J, Janssen G, Messing-Junger M, Felsberg JU, Neuen-Jacob E, Engelbrecht V, Lenard HG, Bock WJ, Reifenberger G: Multiple intracranial juvenile xanthogranulomas. Case report. *J Neurosurg* 93: 335-341, 2000
- 3) Freyer DR, Kennedy R, Bostrom BC, Kohut G, Dehner LP: Juvenile xanthogranuloma: Forms of systemic disease and their clinical implications. *J Pediatr* 129: 227-237, 1996
- 4) Fukasawa I, Mitsuka S, Nukui H, Yoshida Y, Koizumi H, Yamazaki H, Wakao T, Segawa H: Granulomatous angiitis of the central nervous system — case report. *Neurol Med Chir (Tokyo)* 33: 386-390, 1993
- 5) Goto T, Kitazawa K, Tada T, Tanaka Y, Hongo K, Kobayashi S: Surgical dissemination of intracranial xanthogranulomas. *J Neurosurg* 95: 537, 2001
- 6) Gutnik H, Dolenc-Strazar Z, Popovic M: September 2000: 15 year old girl with intracranial lesion. *Brain Pathol* 11: 123-125, 2001
- 7) Hammound RR, Mackenzie IR: Xanthoma dissemination with massive intracranial involvement. *Clin Neuropathol* 14: 314-321, 1995
- 8) Iwata K, Misu N, Nara Y: Granulomatous angiitis of the central nervous system — a case with recurrent intracerebral hemorrhage. *Neurol Med Chir (Tokyo)* 32: 834-838, 1992
- 9) Johnson M, Maciunas R, Dutt P: Granulomatous angiitis masquerading as a mass lesion. *Surg Neurol* 31: 49-53, 1989
- 10) Kepes JJ: Xanthomatous lesions of the central nervous system: definition, classification and some recent observations. *Prog Neuropathol* 4: 179-213, 1979
- 11) Lasner TM, Sutton LN, Rorke LB: Multifocal noninfectious granulomatous encephalitis in a child. Case report. *J Neurosurg* 86: 1042-1045, 1997
- 12) Okubo T, Okabe H, Kato G: Juvenile xanthogranulo-

- ma with cutaneous and cerebral manifestations in a young infant. *Acta Neuropathol (Berl)* 90: 87-92, 1995
- 13) Ozawa T, Sasaki O, Sorimachi T: Primary angiitis of the central nervous system: report of two cases and review of the literature. *Neurosurgery* 36: 173-179, 1995
- 14) Schultz KD Jr, Petronio J, Narad C, Hunter SB: Solitary intracerebral juvenile xanthogranuloma. *Pediatr Neurosurg* 26: 315-321, 1997
- 15) Shoemaker EI, Lin ZS, Rae-Gant AD: Primary angiitis of the central nervous system: unusual MR appearance. *AJNR Am J Neuroradiol* 15: 331-334, 1994
- 16) Takahashi I, Kaneko S, Asaoka K, Harada T, Matsumoto R, Nakamura N: [Two cases of what was regarded as cerebral vasculitis]. *No Shinkei Geka* 22: 863-866, 1994 (Jpn, with Eng abstract)
- 17) Valavanis A, Friede R, Schubiger O: Cerebral granulomatous angiitis simulating brain tumor. *J Comput Assist Tomogr* 3: 536-538, 1979
- 18) Vollmer T, Guarnaccia, Harrington W: Idiopathic granulomatous angiitis of the central nervous system. Diagnostic challenges. *Arch Neurol* 50: 925-930, 1993
- 19) Zimmerman RS, Young HF, Hadfield MG: Granulomatous angiitis of the central nervous system: a case report of long-term survival. *Surg Neurol* 33: 206-212, 1990

Address reprint requests to: K. Tsuboi, M.D., Department of Neurosurgery, Institute of Clinical Medicine, University of Tsukuba, 1-1-1 Tennodai, Tsukuba, Ibaraki 305-8575, Japan.
e-mail: tsuboi@md.tsukuba.ac.jp