


This article was downloaded by: [University of Leeds]

On: 08 November 2014, At: 17:46

Publisher: Routledge

Informa Ltd Registered in England and Wales Registered Number: 1072954 Registered office: Mortimer House, 37-41 Mortimer Street, London W1T 3JH, UK



Neurocase: The Neural Basis of Cognition

Publication details, including instructions for authors and subscription information:
<http://www.tandfonline.com/loi/nncs20>

Changes in Spatial Position of Hands Modify Tactile Extinction but not Disownership of Contralesional Hand in Two Right Brain-Damaged Patients

Valentina Moro ^a, Massimiliano Zampini ^b & Salvatore M. Aglioti ^d

^a Dipartimento di Psicologia e Antropologia Culturale, University of Verona

^b Dipartimento di Scienze Neurologiche e della Visione, University of Verona

^c Department of Experimental Psychology, University of Oxford

^d Dipartimento di Psicologia, University of Roma, "La Sapienza"

^e Centro Ricerche di Neuropsicologia, IRCCS, Fondazione Santa Lucia, Italy

Published online: 17 Aug 2010.

To cite this article: Valentina Moro, Massimiliano Zampini & Salvatore M. Aglioti (2004) Changes in Spatial Position of Hands Modify Tactile Extinction but not Disownership of Contralesional Hand in Two Right Brain-Damaged Patients, *Neurocase: The Neural Basis of Cognition*, 10:6, 437-443, DOI: [10.1080/13554790490894020](https://doi.org/10.1080/13554790490894020)

To link to this article: <http://dx.doi.org/10.1080/13554790490894020>

PLEASE SCROLL DOWN FOR ARTICLE

Taylor & Francis makes every effort to ensure the accuracy of all the information (the "Content") contained in the publications on our platform. However, Taylor & Francis, our agents, and our licensors make no representations or warranties whatsoever as to the accuracy, completeness, or suitability for any purpose of the Content. Any opinions and views expressed in this publication are the opinions and views of the authors, and are not the views of or endorsed by Taylor & Francis. The accuracy of the Content should not be relied upon and should be independently verified with primary sources of information. Taylor and Francis shall not be liable for any losses, actions, claims, proceedings, demands, costs, expenses, damages, and other liabilities whatsoever or howsoever caused arising directly or indirectly in connection with, in relation to or arising out of the use of the Content.

This article may be used for research, teaching, and private study purposes. Any substantial or systematic reproduction, redistribution, reselling, loan, sub-licensing, systematic supply, or distribution in any form to anyone is expressly forbidden. Terms & Conditions of access and use can be found at <http://www.tandfonline.com/page/terms-and-conditions>

Changes in Spatial Position of Hands Modify Tactile Extinction but not Disownership of Contralesional Hand in Two Right Brain-Damaged Patients

Valentina Moro¹, Massimiliano Zampini^{2,3} and Salvatore M. Aglioti^{4,5}

¹Dipartimento di Psicologia e Antropologia Culturale, University of Verona, ²Dipartimento di Scienze Neurologiche e della Visione, University of Verona, ³Department of Experimental Psychology, University of Oxford, ⁴Dipartimento di Psicologia, University of Roma, "La Sapienza", ⁵Centro Ricerche di Neuropsicologia, IRCCS, Fondazione Santa Lucia, Italy

Abstract

Somatic misperceptions and misrepresentations, like supernumerary phantom limb and denial of ownership of a given body part, have typically been reported following damage to the right side of the brain. These symptoms typically occur with personal or extrapersonal neglect and extinction of left-sided stimuli, suggesting that all these different symptoms may be linked to the same neural substrate. In the present research, we tested two right brain-damaged (RBD) patients to find out whether changing the position of the hands in space influences tactile extinction and denial of ownership to the same extent. Results showed that manipulation of the spatial position of the hands reduces tactile extinction but leaves denial of ownership of the left hand unaffected. Such a dissociation suggests that delusional misperceptions may be independent from somatic neglect and that representation of hands in space and attribution of ownership are dynamically mapped in at least partly separate neural substrates.

Introduction

Different types of sensory inputs are coded in the brain by using different spatial representations. While auditory, visual, and olfactory stimuli are typically located in the extrapersonal space, either near or far from the body, and processed according to allocentric reference frames, somatic and gustatory stimuli are typically processed according to egocentric coordinate systems (Buxbaum *et al.*, 2004; Parton *et al.*, 2004). Cerebral lesions involving the right side of the brain typically impair perception and exploration of extrapersonal and personal space and allocation of attention in space. Indeed, right parietal lesions may induce hemispatial neglect and/or a series of related spatial deficits such as extinction of the contralesional stimulus under double stimulation conditions (Head and Holmes, 1912; Vallar, 1998; Buxbaum *et al.*, 2004; Parton *et al.*, 2004). Spatial deficits may selectively affect near or far extrapersonal space (Halligan and Marhsall, 1991; Cowey *et al.*, 1994) and/or personal space (Guariglia and Antonucci, 1992; Peru and Pinna, 1997; Marangolo *et al.*, 2003). Patients with personal neglect present with a severe representational deficit of the contralesional side of the body. They may forget, for example, to shave their left cheek, or omit pulling on their left shirt sleeve (Bisiach *et al.*, 1986; Beschin *et al.*, 2000; McIntosh *et al.*, 2000). Importantly, a clear dissociation between deficits in body exploration in

the complete absence of visual neglect has been reported (Guariglia and Antonucci, 1992).

Tactile extinction is an attentional disorder in which patients are unaware of being touched on their contralesional limb if they are touched simultaneously on their ipsilesional limb (Driver and Vuilleumier, 2001). Alterations in perception and awareness of one's own body following brain damage, such as a severe representational deficit of the contralesional side of the body or hallucinatory percepts of having supernumerary limbs, occur most often after right-sided lesions (Berlucchi and Aglioti, 1997).

Since one's own body and others' bodies are typically perceived in space, the question arises as to whether impairments of spatial and body-specific representations always co-occur. Previous studies in brain-damaged patients indicate disturbances of body image when hemispatial neglect is present. Coslett (1998), for example, asked brain-damaged patients to judge whether pictures of hands were left or right and found that only patients affected by neglect identified pictures of left (contra-lesional) hands significantly less reliably than pictures of right hands. Since the laterality judgment of hands appears to be based on matching stimuli with an on-line mental representation of one's body, the author concluded that neglect may be associated with specific

body schema damage. Temporary remission of extrapersonal neglect, in both its attentional and representational form, has been obtained by means of vestibular stimulation (Rubens, 1985; Cappa *et al.*, 1987). Relevant to the present study is that vestibular stimulation may induce changes of both personal and extrapersonal neglect and somatoparaphrenic delusions (Bisiach *et al.*, 1990; Rode and Perenin, 1994), suggesting an extremely tight link between spatial and body-related impairments.

However interestingly, a mild form of denial of ownership in the absence of spatial disorders has been reported in non brain-damaged patients who underwent regional anaesthesia (Paqueron *et al.*, 2003). The present study was aimed at assessing whether selective changes in hemispacial deficits and body image disorders may be induced. We capitalize on our previous studies in patients with tactile extinction which showed that locating the left hand in a position coded as right with respect to the corporeal midline or to the right hand may improve the detection of stimuli delivered to the left hand (Smania and Aglioti, 1995; Aglioti *et al.*, 1999; Tinazzi *et al.*, 2000). Although this effect has been only partially replicated (Bartolomeo *et al.*, 2004), we tested whether a dissociation between somatic delusions, such as disownership of a hand and tactile extinction, can be induced by simply changing the spatial position of the hands.

Materials and Methods

Patients

Two right brain-damaged patients (A.F. and S.B.), selected for the presence of disownership of the left hand, participated in the study after giving their informed consent. They were informed that the study was not part of their rehabilitation program and were not informed of the experimental aims. The experimental procedures were approved by the Local Ethical Committee.

Patient A.F. is a right-handed, 62-year-old missionary sister, with 13 years of schooling, who suffered from a hemorrhagic stroke that affected the right side of her brain. Fig. 1 shows the site and extent of her lesion.

When we met the patient for the first time, seven months after the stroke, she was alert and well oriented in time and

space. She performed within the normal range on the Mini-Mental State Examination (Folstein *et al.*, 1975) by scoring 26/30 (cut-off= 24/30). A complete left hemianopia was detected by means of a standard confrontation test in which the patient was asked to detect movements of the examiner's index finger located in different spatial positions. She was unable to actively move her left arm or leg. Her sense of position and passive motion were impaired in her left fingers, wrist, elbow and shoulder, but were normal in her left lower limb. The patient was unable to detect the presence of an object put in her hand and to discriminate cold (about 10°C) from hot (about 39°C) test tubes. Moreover, the patient was unable to perceive tactile stimuli or pinpricks delivered to the left part of her body.

Visual and representational extrapersonal neglect was assessed by using a series of clinical tests, namely Albert's cancellation test, a reading test, a sentence copying test, and drawing from a copy and from memory tasks (Peru *et al.*, 1996; Peru *et al.*, 1997). Signs of left-sided neglect were evidenced on all of these tests (Table 1).

Personal neglect was assessed by the modified version of the Comb and Razor test (McIntosh *et al.*, 2000), which proved quite sensitive for detecting deficits in exploration of the side of the body contralateral to the brain lesion. The patient was requested to comb her hair for 30 sec. The number of strokes made on the left or the right side of the head and the number of ambiguous scores were recorded. Patient A.F. showed personal neglect by presenting a bias of (0.35 % (cut-off \leq -0.11%). On a preliminary standard test for assessing tactile extinction (Aglioti *et al.*, 1999), patient A.F. missed all single and double left-sided stimuli. Relevant to the purposes of the present study, patient A.F. presented with florid disturbances of her body image insofar as she vehemently denied that the plegic left hand belonged to her. When directly questioned, the patient recognized her left shoulder and elbow as her own but denied ownership of her left wrist and hand. Moreover, she reported a clear perception of a third arm on the left side of her body. When requested to name body parts on her own or on the examiner's body, the patient made no errors. She was able to construct a human figure puzzle and to draw from memory a sketchy prototype of a human figure. Remarkably, she drew her own body image with three question marks corresponding to her left hand.

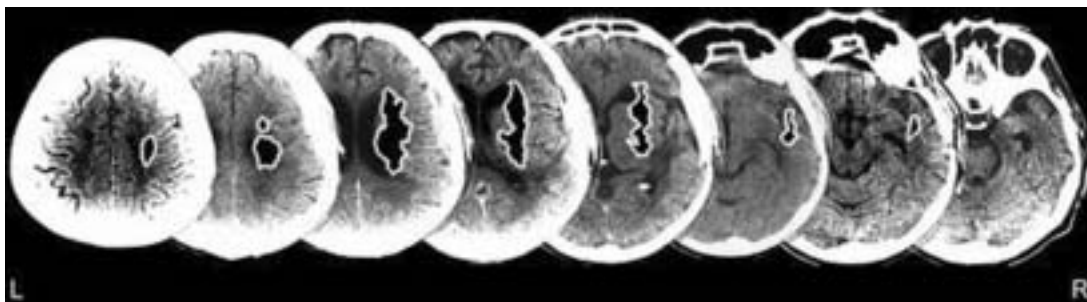


Fig. 1. Selected CT scan cuts showing site and extension of patient AF's lesions involving fronto-temporo-parietal areas of right hemisphere.

Table 1. Extinction and neglect tests in the two patients

	Alb.	Read.	Writ.	Copy	Mem.	Comb. (%)	P.N.	T.E.	V.E.
AF	13/28	3/7	-	0/3	-	-0.35	8/10	0/10	0/10
SB	28/28	5/7	-	0/3	+	-0.30	9/10	0/10	0/10

Legend: Alb. = cancellation test, Read = reading test, Writ. = sentence copying test, Copy = drawing from copy, Mem = drawing from memory, Comb = comb and razor test (cut-off= $<-0.11\%$) P.N. = personal neglect, T.E.=tactile extinction, V.E. = visual extinction.

A.F. was fully conscious of the abnormality of her somatoparaphrenic percepts and when directly inquired about them, she showed great anxiety. Although she was reluctant to talk about these percepts, from a number of video-recorded conversations lasting several hours, we were able to learn that she felt her third arm originating from her left shoulder in a position posterior to the plegic arm. Moreover, the supernumerary limb was not plegic but could be voluntarily moved. Interestingly, disownership phenomena involved the plegic and not the supernumerary limb. These reports were consistent in different interviews carried out on different days over a five-week period.

During the interviews, subjects were asked to report on the feeling of non-belonging of their paralyzed upper arm. The hand was in different positions, namely, it was lying on the table, on the ipsilateral knee, or on the abdomen. Moreover, the hand could be passively moved by an examiner. None of these manipulations changed the patients' report.

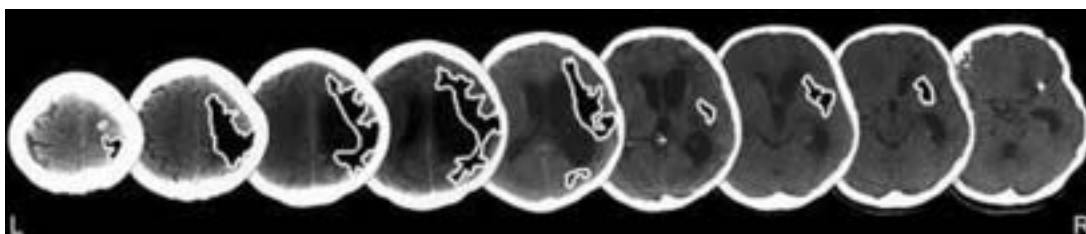
Patient S.B. is a 66-year-old, right-handed man with 5 years of schooling, who suddenly suffered from motor weakness and loss of somatic functions on the left side of his body. A computerized tomography (CT) scan (performed 33 days after the stroke) showed a cortico-subcortical lesion involving the right side of the brain (Fig. 2).

When we first met this patient, three months after the stroke, he appeared well oriented in time and place and performed the Mini-Mental State Examination (Folstein *et al.*, 1975) within normal limits (score 25/30, cut-off= 24/30). No visual field deficits were detected on a standard clinical confrontation test.

The patient presented with a severe left-sided hemiplegia and was unable to move his left upper and lower arm. A severe sensory hemisindrome was also present. Indeed, the

patient was unable to detect left-sided touches, pinpricks, or thermic stimuli. Moreover, a dense proprioceptive deficit was observed in this patient who was unable to detect even fast passive arm or leg movements. Patient S.B. performed correctly on Albert's Test, but he failed on all others tests assessing extrapersonal visual neglect, representational neglect, and visual extinction (Peru *et al.*, 1996) (Table 1). Moreover, the patient showed left personal neglect, presenting a bias of -0.3% on the modified version of the Comb and Razor Test (McIntosh *et al.*, 2000). Patient S.B. resolutely denied ownership of his left hand and insisted that the doctors had given him the arm of another patient who was admitted to the hospital on the same day by mistake. Interestingly, the patient reported the following, "I was troubled the day this hand appeared. I said, 'it isn't mine' and the doctors said, 'why?' but I didn't feel it and when I saw it, I asked myself, 'where's it been until now?'" Moreover, on several occasions S.B. reported the existence of two or three phantom legs that he attempted to get rid of by pushing them out of the bed with his right, intact lower limb. His knowledge of prototypical human figures was preserved, as inferred from his accurate verbal description. In his drawing of his own body, the head is very large and full of details; the trunk doesn't exist and the two upper arms originate from the face. S.B. pointed at the right hand, which was larger than the left, clearly stating that only that one belonged to him. The disownership sensation faded away when he closed his eyes and reappeared suddenly when he opened them. No other body parts were disowned at any time. Although S.B. was aware that left upper and lower arms were affected by paralysis, all he complained about were an aching left shoulder and hip joints he could not move. The patient had no difficulty in naming the different parts of his body or in pointing to any body part on a drawing or on the examiner's body.

The main aim of this work was to test whether changing the spatial position of the left hand would influence signs of somatic neglect and disownership phenomena in a different way. Thus, the two subjects were asked to detect single or double tactile stimuli and, in separate blocks of trials, to report the intensity of their feeling of non-belonging, while keeping their hands in different spatial positions. Since the two patients were not available for the same number of testing sessions, a different number of experimental blocks was administered to each one. Following a procedure used in previous studies (Aglioti *et al.*, 1998, 1999), tactile stimuli

**Fig. 2.** Selected CT scan cuts showing site and extension of patient SB's cortical and subcortical fronto-temporo-parietal lesions.

were delivered to the dorsal surface of one or both hands by means of one or two flexible nylon sticks. Each stick, 25 cm long, had a rounded tip approximately 3 mm in diameter. By bending the stick to obtain the same curvature, it was possible to deliver touches of approximately 35 grams. Touch stimuli lasted approximately 0.5 seconds. Five catch trials (i.e., trials in which no stimulus was delivered but the patient was asked to report what was felt) in each block were interspersed among the experimental stimulus, according to a fixed, pseudorandom sequence. In these trials, no stimulus was presented, but the patients were asked if they felt any tactile sensations. Neither of the patients made any false alarms, suggesting they did not adopt an a-priori response criterion.

Changes in the feeling of non-belonging contingent upon spatial manipulations were assessed in both patients by asking them to rate ownership of the left hand while it was aligned with the corporeal midline or positioned in the left or the right hemisphere. A 7-point Likert Scale was used to provide a sort of quantitative measure of the patients' attitude towards their disownership phenomena. The patients were instructed that the different scores corresponded to the following: patients used scores 1, 2, and 3 for indicating that they were absolutely sure, sure, and almost sure that the left hand did not belong to them; they used score 4 for indicating that they were unable to decide about ownership of their left hand; they used scores 5, 6, 7 for indicating that they were almost sure, sure, and absolutely sure, that the left hand belonged to them.

Results

Patient A.F.

Three experimental blocks, each consisting of 20 single (10 left and 10 right) and 20 double touches, were delivered. While the right hand was always kept on the table about 5° in the right hemisphere, the position of the left hand was about 5° in the left hemisphere (block 1), 70° in the right hemisphere (block 2) and 70° in the left hemisphere (block 3). The view of the hands was obstructed by a cartoon screen held by an examiner so that the hands were hidden from view. Changes in the position of the left hand in each block are schematically represented in Fig. 3.

Detection of single and double stimuli for the left and the right hand in the different blocks is shown in Fig 3. Accuracy in detecting stimuli delivered to the left hand in the center, left-hemisphere and right-hemisphere conditions was assessed in a series of χ^2 comparisons. A family-wise adjustment of the alpha level of significance was made by means of the Bonferroni correction. A clear modulation of accuracy in detecting stimuli delivered to the left hand was observed in both single and double stimulation conditions. Although accuracy was 0% when the left hand was positioned in the center and in the left hemisphere, correct detections reached 100% when the left hand was in the right hemisphere (Fisher's exact value $p < 0.0001$ both in single and double stimulation conditions). In this patient, the spatial position of the right hand

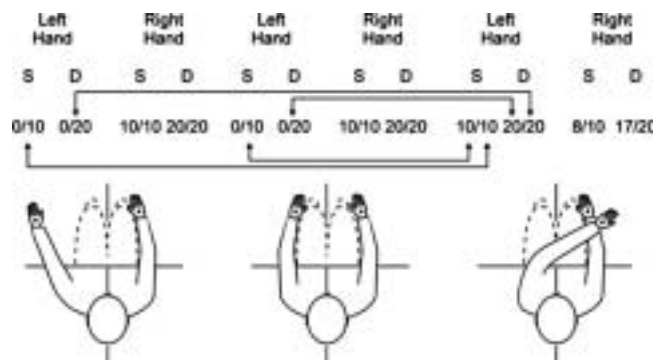


Fig. 3. Patient AF's accuracy in detecting single and double tactile stimuli in the different stimulation blocks. Legend: Correct detections and total number of trials are reported on the numerator and denominator respectively. S= single; D= double.

was the same in the three testing blocks. However, theoretically, accuracy in detecting stimuli delivered to the right hand could have been influenced by spatial changes of the left hand.

Right hand accuracy was lower when the left hand was in the right rather than the left hemisphere (Fig 3; Fisher's exact value $p = 0.03$).

Remarkably, in the blocks in which the left hand was located in the right hemisphere, stimuli were detected in all trials even though the hand was still felt as belonging to another person. Specifically asked about how it was possible to perceive stimuli delivered to another's hand, the patient reported that "many strange things can happen in life." Particularly relevant to the aims of the present study is that placing the left hand in the different spatial positions corresponding to the three experimental blocks of tactile extinction task did not influence feelings of non-belonging of the contralesional hand. Indeed, on all the trials, patient A.F.'s score for the left hand was 1 (resolute denial of ownership) and for the right hand 7 (no doubts about proper attribution of ownership).

Patient S.B.

Six experimental blocks were carried out. They mainly differed for the position of each hand in space and with respect to the other hand. Each block consisted of 10 single left, 10 single right, and 20 double simultaneous tactile stimuli that were delivered according to a random sequence. Five catch trials per block were interspersed among the experimental stimuli. On each trial, the patient was asked to report the number and the side of single or double touches delivered on the dorsal surface of the hands. The order of the six experimental blocks was randomized across two different testing sessions separated by a one-day interval. Each block lasted about 20 minutes. A 3-4 minute pause was made within each block. Accuracy in detecting stimuli delivered to the left hand was markedly influenced by the spatial position of the hands (Fig 4).

When the hands were located across the corporeal midline, accuracy in detecting left-sided stimuli was significantly

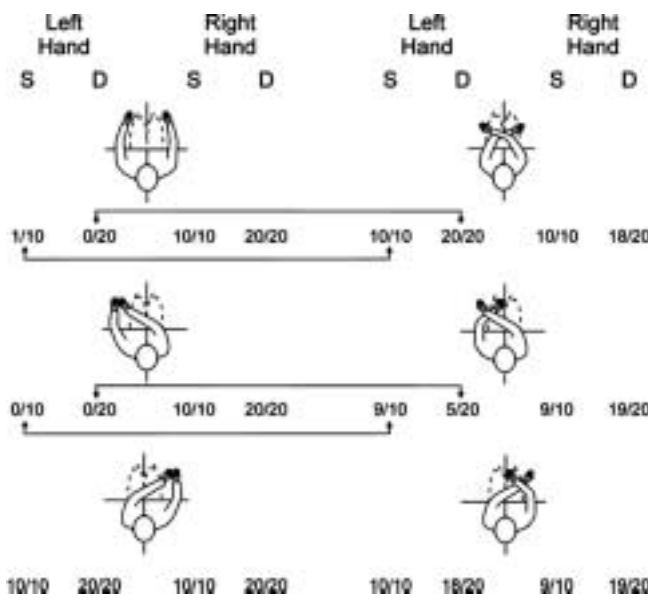


Fig. 4. Patient SB's accuracy in detecting single and double tactile stimuli in the different stimulation blocks. Legend: Correct detections and total number of trials are reported on the numerator and denominator, respectively. S= single; D= double.

higher in the crossed than in the anatomical position under both double and single stimulation conditions (Fisher's exact values $p < 0.0001$). A similar picture emerged when the hands were located within the left, contralesional hemisphere (in the central section of the figure). Indeed, detection of left-sided stimuli was higher in the crossed than in the anatomical position under both double (Fisher's exact values $p = 0.023$) and single (Fisher's exact values $p < 0.0001$) stimulation conditions. When the hands were located in the right hemisphere, performance was good in all conditions, indicating that extinction phenomena are less evident or even absent for stimuli delivered in the intact hemisphere. To sum up, crossing the hands across the corporeal midline or in the contralesional space ameliorated detection of left touches under both single and double stimulation. Changes in the spatial position of the hands influenced the ability to detect tactile stimuli delivered to the ipsilesional right hand (Fig 4). Indeed, right hand accuracy was higher (Fisher's exact values $p = 0.014$) when the left hand was in anatomical (100% of the trials, 30 single and 60 double) than in crossed position (93.3 % of the trials, 28 single and 56 double).

In about 50% of the trials on the tactile detection task, the patient was also specifically asked to report disownership of the left hand and also, occasionally, to report whether he felt his right hand was his own. It turned out that the patient disowned his left hand no matter where it was located. By contrast, he judged questions concerning the ownership of his right hand as rather silly and said, "it would be strange to feel others' body parts as one's own." Subsequently, the issue concerning the possible influence of the spatial location of the hand on disownership phenomena was investigated in greater detail by delivering a block of sixty trials to the

patient. S.B. was requested to score (on a 1–7 point Likert Scale) the degree of disownership of the left hand as soon as the examiner touched it. On each trial, the hand could be aligned with the corporeal midline or located 15° to the left or the right of his corporeal midline according to a random sequence. His right hand was always located at about 5° in its homonymous hemisphere. In this way, we obtained 20 responses for each position. Mean ownership scores for the left hand in the three spatial positions were as follows: left space 4.86 (mode and median: 4.9; range: 3.5–6.3); aligned with the body midline 4.91 (mode and median: 4.9; range: 4.2–6.3); right space 4.93 (mode and median: 4.9; range: 4.2–6.3).

With the aim of checking that appropriate ownership of the right hand was not influenced by its position in space, an additional block of trials was performed. The patient's left hand was located 5° inside the left hemisphere and his right hand was aligned with his corporeal midline or located 15° left or right of his corporeal midline according to a random sequence. On each trial, the patient was asked to score ownership of his right hand. Ten trials were run for each position of the right hand. Ownership scores amounted to 7 in all trials, indicating that the changes in the spatial position of his hands did not influence disownership phenomena.

Discussion

Body image disorders, such as anosognosia for motor or sensory defects, feelings of non-belonging, denial of ownership of a body part, misoplegia and supernumerary phantom limbs are typically reported in patients with severe neglect following large right hemisphere lesions (Halligan *et al.*, 1993; Halligan and Marshall 1995; House and Hodges, 1998; Sellal *et al.*, 1996; Nightingale, 1982). Yet, there is also evidence that disorders of bodily awareness can exist in the absence of spatial deficits. Dissociations between personal and extrapersonal space, for example, have been reported (Guariglia and Antonucci, 1992; Peru and Pinna 1997; Marangolo *et al.*, 2003). The presence of a supernumerary 'ghost' limb in the absence of motor and sensory deficits and spatial disorders was reported in a patient with an infarction of the right frontal lobe and partial callosal disconnection (Hari *et al.*, 1998). Moreover, a patient was described who reported a supernumerary phantom limb without signs of neglect three years after an ischaemic stroke (Mazzoni *et al.*, 1997). In keeping with the notion of dissociation is the result that illusory sensations of movement of the plegic hand evoked in brain-damaged patients by movements of the intact hand correlated with body image disorders but not with neglect (Zampini *et al.*, 2004). In the two patients of the present study, personal and extrapersonal neglect and clear signs of body image disorders co-occurred. This picture suggests that all these symptoms may be linked to the same set of mechanisms.

The dramatic improvement of left-sided tactile imperception and the slight but significant deterioration of right-sided accuracy found in our patients is in keeping with the notion that higher order spatial variables may modulate processing

of sensory inputs. The novelty of our research is that detection of somatic stimuli delivered to the contralesional hand and disownership phenomena were influenced differentially by manipulation of sensory and spatial variables. The amelioration of tactile imperception in the complete absence of changes in disownership phenomena indicates that these two sets of phenomena may be related at least partly to independent mechanisms and neural bases. Even more interesting is the suggestion that the interplay between space, body perception, and body-related beliefs is much more dynamic than previously held. Indeed, if awareness of one's own body is related essentially to attentional and spatial neural networks, one should expect the same spatial manipulation to induce identical changes in tactile extinction and in denial of belonging of the left hand. These networks appear crucial for the tactile extinction that is influenced not only by somatotopic coordinates, but also by hemispatial body-centered frames of references. On the contrary, the correct attribution of ownership to the left plegic hand is probably associated with more complex systems linking somatic information, action cues, and the specific ability to integrate input and output signals in order to maintain a dynamic internal representation of the self and to allow for self-recognition (Van Den Bos and Jeannerod, 2002). An important role in sensorimotor integration seems to be played by the superior parietal lobe (Wolpert *et al.*, 1998) which, in this way, could maintain an internal representation of one's own body. It is worth noting here that parietal lobe structures involved in mental transformations of the body-in-space (Bonda *et al.*, 1995) may play a crucial role in maintaining internal representations.

The partial independence of mechanisms and neural substrates underlying personal neglect and bodily awareness disorders suggested by our results supports the conceptual distinction of at least three types of representations underlying knowledge of the human body (Cosslet *et al.*, 2002). Indeed, while disownership of the contralesional hand may have to do with body image, tactile imperception may reflect body structural description disorders.

Our data seem at odds with studies suggesting that the neglect syndrome and bodily disorders rely on common basic substrates and mechanisms. Indeed, changes in afferent information sent to the brain, as in the case of vestibular stimulation, modify both somatoparaphrenic delusions (Bisiach *et al.*, 1991; Rode *et al.*, 1992) and extrapersonal and personal neglect (Rode and Perenin, 1994). This apparent discrepancy may be accounted for at least partially by the fact that vestibular stimulation induces much more intensive and extensive stimulation than the mere change of arm location in space. Thus, we posit that the stronger stimulation increases the probability of influencing different body-related representations that rely on contiguous neural substrates.

It is worth noting that a recent report of a right-brain damaged patient with hemiplegia, extrapersonal, and personal neglect, anosognosia and somatoparaphrenia suggests that detection of tactile stimuli may also be influenced by higher order manipulations such as linguistic instructions aimed at

changing false beliefs concerning ownership of body parts (Bottini *et al.*, 2002). This patient, who was convinced that her contralesional limbs belonged to her niece, was unable to detect tactile stimuli delivered to her contralesional hand. Notably, the patient's imperception dramatically recovered when she was instructed to feel stimuli delivered to her niece's hand as though using the preserved image of another's body partially compensated for the disruption of self-related representations.

Acknowledgements

This research was supported by grants from FIRB (2001) and MIUR (2003), Italy to S.M.A. Thanks are due to Dr. Chiara Guerrini for her help in reconstructing the lesions, and Mr. Marco Veronese for preparing the figures.

References

- Aglioti S, Peru A, Smania N. Frames of references for mapping tactile stimuli in brain-damaged patients. *J Cogn Neurosci*. 1999; 11:67–79.
- Aglioti S, Smania N, Moro V, Peru A. Tactile salience influences extinction. *Neurology*. 1998; 50:1010–14.
- Bartolomeo P, Perri R, Gainotti G. The influence of limb crossing on left tactile extinction. *J Neurol Neurosurg Psychiatry* 2004; 75:49–55.
- Berlucchi G, Aglioti SM. The body in the brain: neural bases of corporeal awareness. *Trend Neurosc*. 1997; 20(12):560–4.
- Beschin N, Basso A, Della Sala S. Perceiving left and imagining right: dissociation in neglect. *Cortex*. 2000; 36:401–14.
- Bisiach E, Perani D, Vallar G, Berti A. Unilateral neglect: personal and extrapersonal. *Neuropsychologia*. 1986; 24:759–67.
- Bisiach E, Rusconi ML, Vallar G. Remission of somatoparaphrenic delusion through vestibular stimulation. *Neuropsychologia*. 1991; 29:1029–31.
- Bonda E, Petrides M, Frey S, and Evans A. Neural correlates of mental transformations of the body in space. *Proc Natl Acad Sci USA*. 1995; 92: 11180–11184.
- Bottini G, Bisiach E, Sterzi R, Vallar G. Feeling touches in someone else's hand. *Neuroreport*. 2002; 13:249–52.
- Buxbaum LJ, Ferraro MK, Veramonti T, Farne A, Whyte J, Ladavas E, Frassinetti F, Coslett HB. Hemispatial neglect: Subtypes, neuroanatomy, and disability. *Neurology*. 2004; 62:749–56.
- Cappa S, Sterzi R, Vallar G, Bisiach E. Remission of hemineglect and anosognosia during vestibular stimulation. *Neuropsychologia*. 1987; 25:775–82.
- Coslett HB. Evidence for a disturbance of the body schema in neglect. *Brain and Cognition*. 1998; 37:527–44.
- Coslett HB, Saffran EM, Schwoebel J. Knowledge of the human body. A distinct semantic domain. *Neurology*. 2002; 59:357–63.
- Cowey A, Small M, Ellis S. Left visuo-spatial neglect can be worse in far than in near space. *Neuropsychologia*. 1994; 32(9):1059–66.
- Driver J, Vuilleumier P. Perceptual awareness and its loss in unilateral neglect and extinction. *Cognition*. 2001; 79:39–88.
- Folstein MF, Folstein SE, McHugh PR. Mini-Mental State: A practical method for grading the state of patients for the clinician. *J Psychiatr Res*. 1975; 12:189–198.
- Guariglia C, Antonucci G. Personal and extrapersonal space: a case of neglect dissociation. *Neuropsychologia* 1992; 30:1001–9.
- Halligan PW, Marshall JC. Left neglect for near but not far space in man. *Nature* 1991; 350:498–500.
- Halligan PW, Marshall JC, Wade DT. Three arms: a case study of supernumerary phantom limb after right hemisphere stroke. *Journal of Neurology, Neurosurgery, and Psychiatry* 1993; 56:159–66.
- Halligan PW, Marshall JC, Wade Dt. Unilateral somatoparaphrenia after right hemisphere stroke: a case description. *Cortex* 1995; 31:173–82.
- Hari R, Hänninen R, Mäkinen T, Veikko J, Forss N, Seppä M, Salonen O. Three hands: fragmentation of human bodily awareness. *Neuroscience Letters* 1998; 240:131–4.
- Head H, Holmes G. Sensory disturbances from cerebral lesions. *Brain* 1912; 34:102–54.

- House A, Hodges J. Persistent denial of handicap after infarction of the right basal ganglia: a case study. *Journal of Neurology, Neurosurgery, and Psychiatry* 1988; 51:112–5.
- Kerkhoff G. Spatial hemineglect in humans. *Prog Neurobiol* 2001; 63:1–27.
- Marangolo P, Piccardi L, Rinaldi MC. Dissociation between personal and extrapersonal neglect in a crossed aphasia study. *Neurocase* 2003; 9:414–20.
- Mazzoni M, Lucchini C, Meucci G, Vista M, Moretti P, and Sartucci F. Supernumerary phantom limb after ischaemic stroke. *Neurocase* 1997; 3:223–30.
- McIntosh RD, Brodie EE, Beschin N, Robertson IH. Improving the clinical diagnosis of personal neglect: a reformulated comb and razor test. *Cortex* 2000; 36:289–92.
- Nightingale S. Somatoparaphrenia: a case report. *Cortex* 1982; 18:463–7.
- Paqueron X, Leguen M, Rosenthal D, Coriat P, Willer JC, Danziger N. The phenomenology of body image distortions induced by regional anaesthesia. *Brain* 2003; 126:702–12.
- Parton A, Malhotra P, Husain M. Hemispacial neglect. *Journal of Neurology, Neurosurgery, and Psychiatry* 2004 75:13–21.
- Peru A, Pinna G. Right personal neglect following a left hemisphere stroke. A case report. *Cortex* 1997; 33:585–90.
- Peru A, Moro V, Avesani R, Aglioti S. Overt and covert processing of left side information in unilateral neglect investigated with chimeric drawings. *Journal of Clinical and Experimental Neuropsychology* 1996; 18:1–10.
- Peru A, Moro V, Avesani R, Aglioti S. Influence of perceptual and semantic conflicts between the two halves of chimeric stimuli on the expression of visuo-spatial neglect. *Neuropsychologia* 1997; 35:583–89.
- Rode G, Charles N, Perenin MT, Vighetto A, Trillet M, Aimard G. Partial remission of hemiplegia and somatoparaphrenia through vestibular stimulation in a case of unilateral neglect. *Cortex* 1992; 28:203–8.
- Rode G, Perenin MT. Temporary remission of representational hemineglect through vestibular stimulation. *Neuroreport* 1994; 5:869–72.
- Rubens AB. Caloric stimulation and unilateral visual neglect. *Neurology* 1985; 35:1019–24.
- Sellal F, Renaseau-Leclerc C, Labrecque R. L'homme a six bras. 1996; *Revue neurologique (Paris)*. 1996; 152:190–5.
- Smania N, Aglioti S. Sensory and spatial components of somaesthetic deficits following right brain damage. *Neurology* 1995; 45:1725–30.
- Tinazzi M, Ferrari G, Zampini M, Aglioti SM. Neuropsychological evidence that somatic stimuli are spatially coded according to multiple frames of reference in a stroke patient with tactile extinction. *Neuroscience Letters* 2000; 287:133–6.
- Vallar G. Spatial hemineglect in humans. *Trends in Cognitive Science* 1998; 2:87–97.
- Van Den Bos E, and Jeannerod M. Sense of body and sense of action both contribute to self-recognition. *Cognition* 2002; 85:177–87.
- Wolpert DM, Goodbody SJ, Husain M. Maintaining internal representations: the role of the human superior parietal lobe. *Nature Neuroscience* 1998; 1:529–33.
- Zampini M, Moro V, Aglioti SM. Illusory movements of the contralesional hand in patients with body image disorders. *Journal of Neurology, Neurosurgery, and Psychiatry* 2004; 75:1626–28.