

# Multiple Visual Hallucinations and Pseudohallucinations in One Individual Patient: When the World Is Turning Upside Down and the Television Keeps Falling to the Ground while Dwarfs Are Parading on the Ceiling

H.E. Killer<sup>a</sup> U.W. Buettner<sup>b</sup>Departments of <sup>a</sup>Ophthalmology and <sup>b</sup>Neurology, Kantonsspital Aarau, Aarau, Switzerland

## Key Words

Visual hallucinations · Visual pseudohallucinations · Peduncular hallucinosis · Palinopsia · Oblique vision

## Abstract

We report on a patient who experienced visual hallucinations and pseudohallucinations comprising palinopsia, peduncular hallucinosis, and oblique vision. The most probable etiologies of these phenomena are discussed with respect to clinical presentation and findings on computed tomography and magnetic resonance imaging.

Copyright © 2005 S. Karger AG, Basel

## Introduction

Visual hallucinations are troublesome both for the patient as well as for the physician. In order to distinguish between a psychiatric disorder and an organic disease, a multidisciplinary approach, including an ophthalmologist, a neurologist, and a psychiatrist, is often mandatory. A careful history and a thorough ophthalmologic and neurologic workup, including neuroimaging, are essential for proper treatment. The different phenomena are termed

according to presentation and presumed pathophysiology, e.g., peduncular hallucinosis, palinopsia, oblique vision, and/or out-of-body experience.

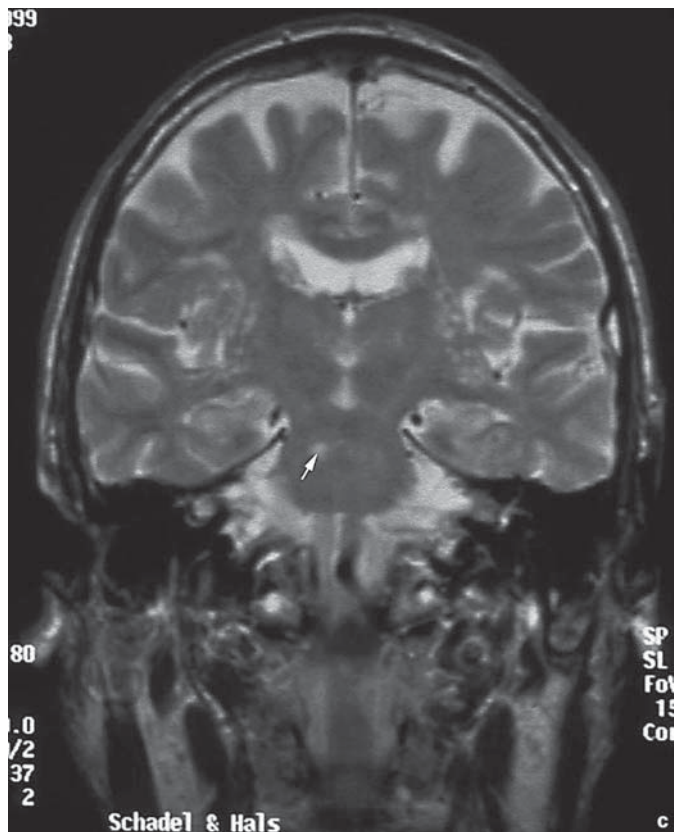
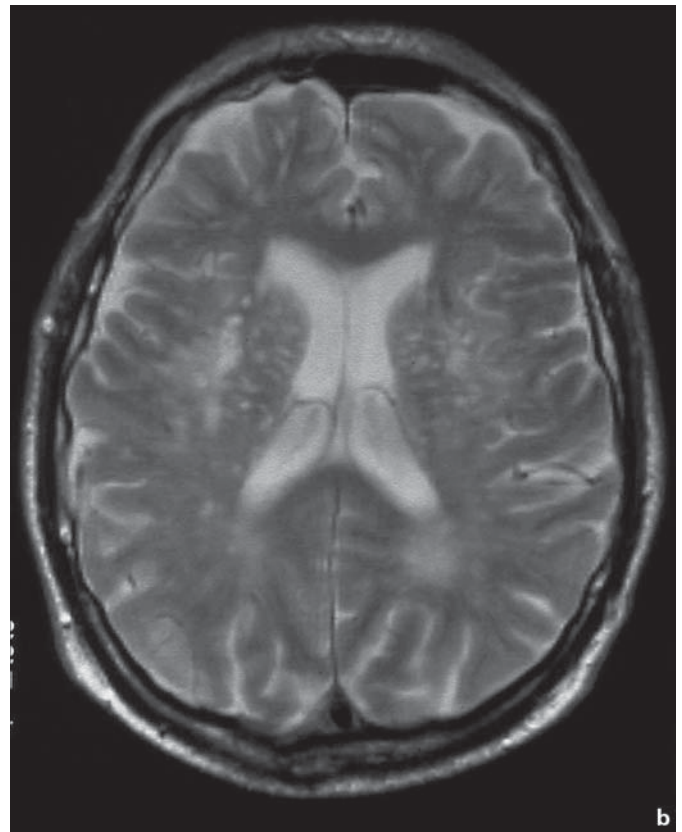
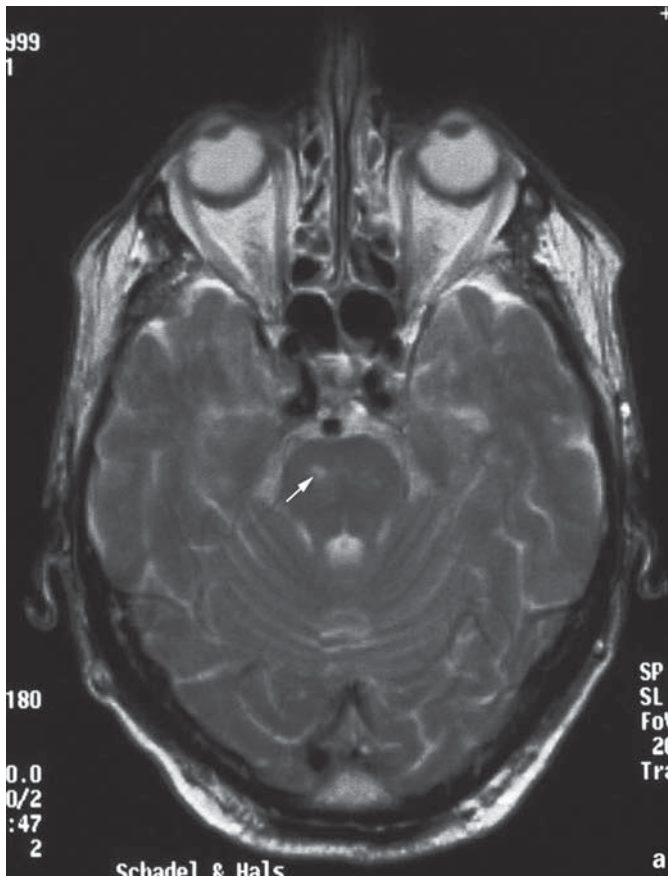
## Case Report

In 1992, a 71-year-old previously healthy man sustained an acute attack of speech disorder that lasted for about 10 min. According to his wife, the speech flow was drastically reduced, and the patient was unable to produce the words required to express himself, while he had no difficulties understanding what another person was saying. This episode was accompanied by a dull nonpulsating headache. The following day, there was numbness in the distal half of the right hand, lasting approximately 1 h, and a few days later, there was moderate weakness in the right hand lasting about 2 h. Alarmed by these symptoms, the patient consulted a neurologist. Except for preexisting anosmia that occurred in association with a viral infection 12 years ago, the neurological examination was unremarkable. Doppler sonography of the extracranial vessels was normal. Computed tomography and magnetic resonance imaging of the brain revealed lesions in the subcortical white matter and in the basal ganglia, compatible with mild vascular encephalopathy. Based on the history and the results of the neurologic examination, the diagnosis of transient ischemic attacks was made, and aspirin was prescribed.

In August 1998, the internist diagnosed tachycardia and prescribed digoxin. In November of the same year, the patient complained of fluctuating visual disturbances while watching television and described blurring of the faces on the television screen. At the

## KARGER

Fax +41 61 306 12 34  
E-Mail [karger@karger.ch](mailto:karger@karger.ch)  
[www.karger.com](http://www.karger.com)© 2005 S. Karger AG, Basel  
0030-3755/05/2192-0115\$22.00/0Accessible online at:  
[www.karger.com/oph](http://www.karger.com/oph)H.E. Killer, MD  
Augenklinik  
Kantonsspital Aarau  
CH-5001 Aarau (Switzerland)  
Tel. +41 62 838 5003, Fax +41 62 838 5022, E-Mail [killer@ksa.ch](mailto:killer@ksa.ch)



**Fig. 1.** Axial (a, b) and coronary (c) T2-weighted magnetic resonance images clearly demonstrating predominantly small-vessel disease with lacunar lesions in the right pons (arrows in a and c) and bilaterally in the subcortical insular cortex and to a lesser extent in the periventricular white matter. The size of the ventricles and the extent of atrophy do not exceed age-related normal values.

same time, he started to see unicolored yellowish points and stripes throughout the visual field of both eyes, concomitant with a slight dull headache and memory loss. On ophthalmologic examination, visual acuities measured 20/30 in both eyes. The slitlamp examination was unremarkable, except for early cataracts. Dilated funduscopy revealed normal optic disks, well-structured maculae, and normal retinal vessels. The neurological examination was repeated and found to be normal. There was no deficiency of cognitive functions (not formally tested). Digoxin toxicity was suspected to account for the patient's symptoms; however, the digitalis serum levels were within normal limits.

In January 1999, a drastic change in the patient's behavior was noted by members of his family. While eating dinner, the patient showed progressive alterations of his mental state. His wife reported an episode of aphasia. The patient left the dinner table and walked aimlessly around the living room. He seemed disturbed and not fully aware of what he was doing. The patient was admitted to

the hospital that same evening. On admission, he was fully oriented, and the neurological examination was unremarkable. Computed tomography of the head showed signs of subcortical encephalopathy, but no evidence of an ischemic or hemorrhagic stroke. The patient was anticoagulated (intravenous heparin and upon discharge oral anticoagulation) in order to prevent a possible stroke following recurrent transient ischemic attacks. While in hospital, the patient recorded the visual phenomena that he experienced as follows:

'The wall is bulging forward towards me. The wallpaper flutters like a curtain in the wind. Small men and women, all nicely dressed, some of them with bicycles or carriages, are moving on the ceiling. Their size measures about 7 mm. The television set keeps falling to the ground, over and over again. The whole room is rotated by 90°. In the corridor it snows confetti. There are thousands of gnats flying around. Sometimes the room is filled with fog.'

On discharge from the hospital, the patient was free from symptoms. No further neurological symptoms manifested while oral anticoagulation was continued. A magnetic resonance image of the head exhibited bilateral hemispheric subcortical vascular encephalopathy (fig. 1a) as well as encephalopathy of the basal ganglia and the pons (fig. 1b, c), with predominance in the right tegmentum.

## Discussion

This patient experienced severe multiple visual phenomena, all of them most likely due to microvascular encephalopathy of the right and the left hemispheres, the basal ganglia, and the pons. These visual hallucinations can be classified into two major groups: (1) real hallucinations and (2) pseudohallucinations. Although some authors appropriately argue that there is no clear-cut distinction between these two groups, this classification seems to be justified for the purpose of clarity. In contrast to hallucinations that are 'real' to the patient, the hallucinatory character of pseudohallucinations is evident to the patient and, therefore, usually not frightening.

The real visual hallucinations experienced by this patient included oblique vision, also termed tilt of the subjective vertical. The patient suffered several episodes during which the room he was in was tilted by 90°, while he felt as if he were standing on the wall, looking down at the bed and the floor from above. During some of these episodes, oblique vision was coupled with palinopsia (visual perseveration) [1, 2]. The patient noted that the television set turned to the floor on either side by 90°. The pathophysiology of oblique vision is thought to be associated with a disturbance of the otolithic input into the thalamic nuclei, in this case possibly due to the lacunar lesion within the right pons [3–5] (fig. 1b, c).

The otolithic pathway from the vestibular nuclei travels rostrally, presumably through the ascending tract of

Deiters which in this patient may have been affected. The fact that this patient, in some instances, perceived himself standing on the wall, and in other instances the television set falling sideways, suggests a disturbed visual-vestibular interaction. In contrast to the phenomena termed autoscopia and out-of-body experience [6], this patient described never having experienced a view onto himself.

Visual-vestibular interaction is known to take place at several levels within the brain. The first level is at the vestibular nuclei, and the presumed second level is in the thalamus, where visual and vestibular input as well as somatosensory inputs converge at the single-neuron level.

The pseudohallucinations experienced by this patient comprise yellowish pictures that initially suggested the possibility of digitalis toxicity. The patient subsequently noted objects covered by grids and points, and he experienced some scenic events mostly with dwarfs and animals as well as moving walls, veils, and curtains. Part of these phenomena may be classified as peduncular hallucinosis, a term that was introduced originally by Lhermitte [7] in his description of a patient having a rostral brainstem lesion. A series of patients with peduncular hallucinosis have been published since then, some of them suffering from lesions in substantia nigra pars reticulata, thalamic pulvinar, and cerebral peduncles [8]. The substantia nigra pars reticulata receives input from the serotonergic raphe neurons and the cholinergic cells of the pedunculopontine tegmental nucleus [9]. Peduncular hallucinosis frequently is characterized by vivid colors, animals, and human beings, sometimes in miniature (as in the present case). The images may be static or moving. The pathophysiology of peduncular hallucinosis is unclear, but is thought to be extracortical [10]. The probable pathophysiology is an abnormality of cholinergic and serotonergic pathways due to lacunar lesions in the brainstem.

The differential diagnosis of peduncular hallucinosis includes delirium tremens, Parkinson's disease, Lewy body dementia, focal epilepsy, and Charles Bonnet syndrome [11, 12]. Since the ophthalmological examination was normal in this patient, the diagnosis of Charles Bonnet syndrome is highly unlikely. It has been considered that migraine aura (one episode followed by dull headache), idiopathic occipital epilepsy, or a retinal abnormality (age-related macular degeneration) might have been the underlying cause of the elementary pseudohallucination [13]. These diagnoses, however, were not present in this patient. Although an EEG was not performed in this patient, the diagnosis of epilepsy is unlikely, since com-

plex hallucinations (palinopsia, peduncular hallucinosis, and oblique vision) were the prominent features in this patient. Additionally, blindness as reported in some instances of idiopathic occipital epilepsy was not present.

In conclusion, a variety of visual hallucinations and pseudohallucinations (peduncular hallucinosis, palinopsia, and oblique vision) were experienced by a single patient with multiple lacunar lesions in brainstem, basal ganglia, and both cerebral hemispheres. The ophthalmological

examination was normal. Peduncular hallucinosis, the most prominent clinical feature in this case, may have occurred on the basis of abnormalities of the cholinergic and serotonergic pathways. Oblique vision in this case might be attributed to a right brainstem lesion, affecting the otolithic pathway through the ascending tract of Deiters. It is postulated that the majority of the cases of pseudohallucinosis may be explained on the basis of subtle brainstem lesions, such as presented in our case.

## References

- 1 Pomeranz HD, Lessell S: Palinopsia and polyopia in the absence of drugs or cerebral disease. *Neurology* 2000;54:855–859.
- 2 Bender MB, Feldman M, Sobin AJ: Palinopsia. *Brain* 1968;91:321–338.
- 3 Larmande P, Missoum A, Tayoro J, Belin C: L'illusion visuelle d'oblique. *Rev Neurol (Paris)* 1994;150:388–390.
- 4 River Y, Ben Hur T, Steiner I: Reversal of vision metamorphopsia: Clinical and anatomical characteristics. *Arch Neurol* 1998;55:1362–1368.
- 5 Pötzel O: Über Verkehrtsehen. *Zentralbl Gesamte Neurol Psychiatr* 1943;104:780–792.
- 6 Blanke O, Landis T, Spinelli L, Seeck M: Out-of-body experience and autoscopia of neurological origin. *Brain* 2004;127(Pt 2):243–258.
- 7 Lhermitte J: Syndrome de la calotte du pédoncule cérébral: les troubles psychosensoriels dans les lésions du mésencéphale. *Rev Neurol (Paris)* 1922;38:1359–1365.
- 8 McKee AC, Levine DN, Kowall NW, Richardson EP Jr: Peduncular hallucinosis associated with isolated infarction of the substantia nigra pars reticulata. *Ann Neurol* 1990;27:500–504.
- 9 Beckstead RM: Long collateral branches of substantia nigra pars reticulata axons to thalamus, superior colliculus and reticular formation in monkey and cat: Multiple retrograde neuronal labeling with fluorescent dyes. *Neuroscience* 1983;10:767–779.
- 10 Manford M, Andermann F: Complex visual hallucinations: Clinical and neurobiological insights. *Brain* 1998;121(Pt 10):1819–1840.
- 11 Ffytche DH, Howard RJ: The perceptual consequences of visual loss: 'Positive' pathologies of vision. *Brain* 1999;122(Pt 7):1247–1260.
- 12 Santhouse AM, Howard RJ, Ffytche DH: Visual hallucinatory syndromes and the anatomy of the visual brain. *Brain* 2000;123(Pt 10):2055–2064.
- 13 Panayiotopoulos CP: Elementary visual hallucinations, blindness, and headache in idiopathic occipital epilepsy: Differentiation from migraine. *J Neurol Neurosurg Psychiatry* 1999;66:536–540.