

Schizencephaly: Case Report of Familial Incidence

Mark A. Hosley, MD*,
Israel F. Abrams, MD†, and
Ronald L. Ragland, MD‡

Two half-siblings with schizencephaly are presented. They have the same mother who had a normal cerebral imaging study. Only one other kindred was found in which 2 siblings had this cerebral lesion. In the present patients, autosomal inheritance from the mother is possible, but other explanations should include familial, as well as genetic, factors. Family counseling should stress the sporadic nature of this entity but a recurrence in the same sibship is possible. Details of the clinical and magnetic resonance imaging studies are presented.

Hosley MA, Abrams IF, Ragland RL. Schizencephaly: Case report of familial incidence. *Pediatr Neurol* 1992;8:148-50.

Introduction

Schizencephaly is a term first used by Yakovlev and Wadsworth [1,2] to characterize a developmental defect previously described by Kundrat [3] and Wilmarth [4] as "symmetric clefts in the cerebral mantle during neuronal migration." Yakovlev and Wadsworth categorized schizencephaly clefts as having fused lips (Type I) or unfused lips accompanied by hydrocephalus (Type II) [2]. With the advent of magnetic resonance imaging (MRI), this abnormality has been more widely recognized. The defect is generally found in the region of the Rolandic fissure and is frequently associated with local pachygyria, polymicrogyria, or lissencephaly. Gray matter heterotopia, absence of the septum pellucidum, and hypoplasia of the optic nerves have also been associated with schizencephaly [5-7]. The concurrence of schizencephaly with septo-optic dysplasia may represent a common etiology occurring at 30-60 days of gestation [7-9]. Clinically, schizencephaly is associated with intellectual retardation, epilepsy, microcephaly, generalized spasticity, hypertonia, or hypotonia

[10,11]. The incidence was 1:1,650 in patients examined by computed tomography (CT) in one study and is invariably a sporadic event without familial recurrence [12]. There is one case report of siblings with schizencephaly [13]. We report two half-siblings both of whom have been diagnosed as having schizencephaly.

Case Reports

The two patients are half-siblings, genetically related through their mother, each of whom has a clinically normal full-brother. The two fathers are not related.

Patient 1. This patient, a 15-year-old female, is the older half-sister of Patient 2. She was the product of a spontaneous vaginal delivery at 5½ weeks past the mother's due date. The pregnancy was uneventful but the mother drank 1-2 glasses of wine periodically during this gestation. She did not smoke, report any illnesses, or take drugs during the pregnancy. Soon after birth our patient had been diagnosed as having suffered a "stroke" because of left-sided weakness. The patient, however, has reached normal developmental milestones, achieved average or above average grades in school, been active in sports, and has a mild left hemiparesis. She was admitted to our service because of the onset of generalized clonic seizures at age 15 years. The examination revealed normal mental status and signs of mild spastic left hemiparesis. Her waking electroencephalogram (EEG) was normal 2 weeks later. Her seizures are controlled by carbamazepine.

Neuroradiology. Unenhanced CT revealed a unilateral right hemispheric schizencephaly, generalized mild to moderate ventricular enlargement, and absence of the septum pellucidum (Figs 1A,1B). Unenhanced MRI was performed in the axial, coronal, and sagittal planes. This study again revealed unilateral, closed-lip, right hemispheric schizencephaly (Fig 1C). The characteristic thickened gray matter lining of the schizencephalic cleft was best visualized on the axial second echo T₂ sequence. Further, an adjacent periventricular gray matter heterotopia was clearly identified. Again, ventricular prominence and absence of the septum pellucidum were observed.

Patient 2. This patient is the 13-year-old half-brother of Patient 1, diagnosed as having moderate asymmetric (right predominant) quadriparetic "cerebral palsy" at 1 year of age. The patient was born after a 44 week gestation complicated only by vaginal spotting during the last week. Again, the mother drank 1-2 glasses of wine occasionally during the pregnancy, but she took no drugs, had no illnesses, and did not smoke. Cesarean section was required following failure of induction of labor and fetal bradycardia after 14 hours of labor. Birth weight was 4.5 kg. The patient had significant developmental delays, moderate mental retardation, and diagnosis of a seizure disorder at 2 years of age. The seizures were generalized clonic, more marked on the right side, well-controlled on combined therapy of valproic acid and carbamazepine. This patient is currently in a 5-pupil classroom, receives ongoing occupational and physical therapy, and takes adaptive physical education. He had a surgical lengthening of the right Achilles tendon at age 2 years. A recent EEG demonstrated poorly developed background rhythms with frontal intermittent rhythmic theta and delta activity.

Family history revealed a 36-year-old mother with a normal neurologic examination and a normal cranial MRI. The maternal grandmother died secondary to a rupture of a cerebral aneurysm at age 56 years and a first cousin of the mother required clipping of a cerebral aneurysm. The mother of our patients has 4 normal siblings and both husbands have 2 and 5 siblings, respectively, all of whom are neurologically normal.

From the Departments of *Neurology, †Pediatrics, and ‡Radiology; University of Massachusetts Medical Center; Worcester, Massachusetts.

Communications should be addressed to:
Dr. Abrams; University of Massachusetts Medical Center;
Department of Pediatrics; 55 Lake Avenue North;
Worcester, MA 01655.
Received July 18, 1991; accepted November 13, 1991.

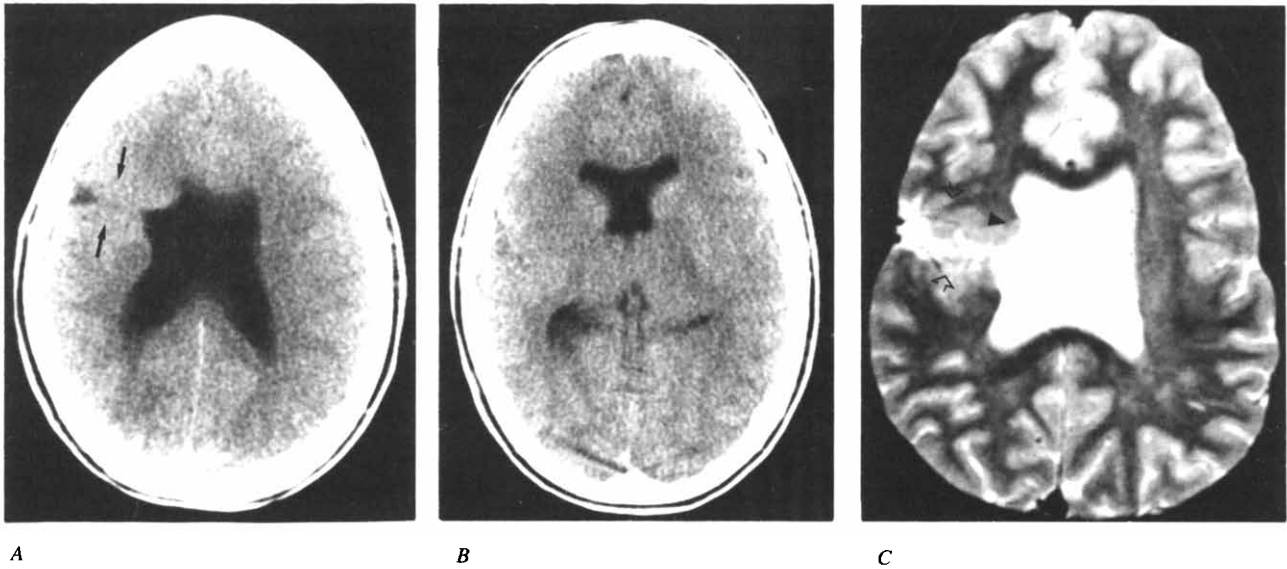


Figure 1. Patient 1. (A) Axial CT at the ventricular bodies reveals a unilateral right-sided schizencephaly of the closed-lip variety. There is subtle high density (gray matter density) that lines the schizencephalic cleft (arrows). (B) Axial CT at the frontal horns reveals an absence of the septum pellucidum. (C) Axial second echo T₂ MRI at the level of the ventricular bodies again discloses the unilateral right-sided schizencephalic cleft which is lined by gray matter intensity (open arrows). An arrowhead has been placed on a focus of heterotopic periventricular gray matter.

Neuroradiology. The CT and MRI results of Patient 2 disclosed more severe abnormalities which correlated with his greater degree of functional impairment. Unenhanced CT performed in the axial plane revealed bilateral schizencephalic defects. The right-sided defect was smaller and of the closed-lip variety and the larger left-sided schizencephalic defect was the opened-lip type. As in the older sibling, there was absence of the septum pellucidum. There is also marked focal enlargement of the left ventricular body and frontal horn. On MRI, the second echo T₂ sequence demonstrated abnormal gray matter lining the schizencephalic clefts (Figs 2A-2C).

Discussion

Prior to the neuroimaging technology now available, schizencephaly was a rare diagnosis made at autopsy [12]; however, with the advent of intrauterine ultrasound imag-

ing of the brain, as well as CT and MRI after birth, the recorded incidence has dramatically increased [14-16]. This report is the first to present the only known half-siblings with schizencephaly and, to our knowledge, the second instance of familial occurrence of schizencephaly [13]. Because the two patients were genetically related only through their mother – who is neurologically normal and has a normal cranial MRI – the mode of inheritance is possibly autosomal dominant; a cytosomal mitochondrial defect is highly unlikely because two other children of this mother are normal. Autosomal recessive inheritance is also possible but the two fathers were not related. Sex-linked inheritance is unlikely because of the first patient's being a female. One cannot exclude nongenetic, familial, or en-

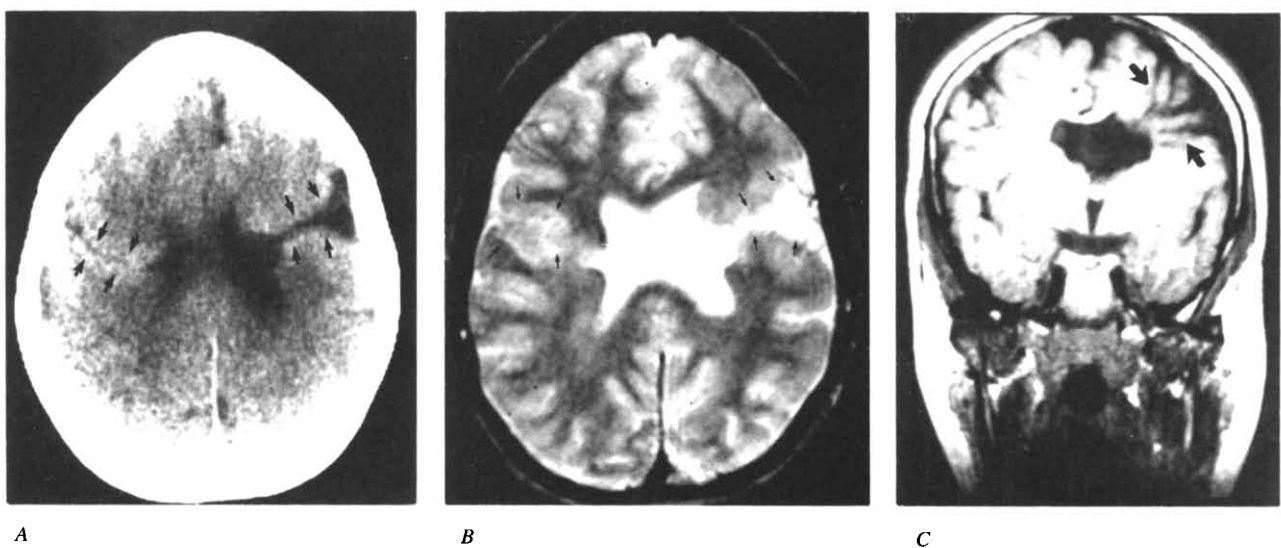


Figure 2. Patient 2. (A) Axial CT at the ventricular bodies demonstrates a smaller right hemispheric closed-lip schizencephaly (arrows) and a larger left hemispheric opened-lip schizencephaly (arrows). (B) Axial second echo T₂ MRI at the ventricular bodies demonstrates to better advantage the gray matter lining of the bilateral schizencephalic clefts (arrows). (C) Coronal T₁ MRI through the frontal horns reveals the gaping left hemispheric cleft (arrows) as well as an absence of the septum pellucidum and focal dilatation of the left frontal horn ventricular body.

vironmental causes, such as intrauterine infection or a toxic etiology, but no local uterine abnormality was present to explain these cerebral lesions.

There are two theories concerning the pathogenesis of schizencephaly. The first, proposed by Yakovlev and Wadsworth, suggests a localized failure of induction of neuronal migration from the ependymal cells lining the primitive ventricle before the time of primary sulcation which would have to occur between 30-60 days of gestation [7-9] and can be unilateral and asymmetric [5,8,12].

The second theory proposes an early destructive lesion involving this segment of the hemisphere, perhaps due to a localized vascular occlusion, followed by disordered and excessive cortical overgrowth; therefore, this process would lead to a limited destructive porencephaly [17].

A familial incidence of congenital porencephaly itself has been described, but is rare [18]. This entity is believed to be due to a destructive encephalopathy in most instances rather than a marked hemispherical dysgenesis.

Encountered at our own institution are several cases of schizencephaly associated with septo-optic hypoplasia (Demorsier's syndrome) and several reports confirm this association [7-9,19]. The latter entity is very rarely familial [20] and may also be due to a destructive process [21].

In view of this report, families with a child with schizencephaly should be advised that although most cases are sporadic in occurrence, rarely, a second child may also have this cerebral lesion. Furthermore, the etiology could be familial or environmental yet not genetic in origin. Similar advice may be pertinent with the entities of congenital porencephaly and septo-optic hypoplasia.

We would like to express our gratitude to Beth A. Ellis for secretarial support and patience during the preparation of this manuscript.

References

[1] **Yakovlev PI, Wadsworth RC.** Schizencephalies: A study of the congenital clefts in the cerebral mantle, I. Clefts with fused lips. *J Neuropathol Exp Neurol* 1946;5:116-30.

[2] **Yakovlev PI, Wadsworth RC.** Schizencephalies: A study of congenital clefts in the cerebral mantle, II. Clefts with hydrocephalus and lips separated. *J Neuropathol Exp Neurol* 1946;5:169-206.

[3] **Kundrat H.** Die porencephalie. Eine anatomische studie. Graz: Lenschuss & Lubensky, 1882;8:1-126.

[4] **Wilmarth WA.** Presentation to the Philadelphia Neurological Society. *J Nerv Ment Dis* 1887;14:395-407.

[5] **Bird CR, Gilles FH.** Type I schizencephaly: CT and neuropathologic findings. *AJNR* 1987;8:451-4.

[6] **Jacobson M.** Developmental neurobiology. New York: Plenum Press, 1978;57-114.

[7] **Marchal G, Andermann F, Tampieri D, et al.** Generalized cortical dysplasia manifested by diffusely thick cerebral cortex. *Arch Neurol* 1989;46:430-4.

[8] **Barkovich AJ, Norman D.** MR imaging of schizencephaly. *AJNR* 1982;9:297-302.

[9] **Chamberlain MC, Press GA, Bejar RF.** Neonatal schizencephaly: Comparison of brain imaging. *Pediatr Neurol* 1990;6:382-7.

[10] **Miller GM, Stears JC, Guggenheim MA, Wilkening GN.** The clinical and computerized tomographic spectrum of schizencephaly in six patients. *Neurology* 1982;32:A218-9.

[11] **Aniskiewicz AS, Frumkin NL, Brady DE, Moore JB, Pera A.** Magnetic resonance imaging and neurobehavioral correlates in schizencephaly. *Arch Neurol* 1990;47:911-6.

[12] **Miller GM, Stears JC, Guggenheim MA, Wilkening GN.** Schizencephaly: A clinical and CT study. *Neurology* 1984;34:997-1001.

[13] **Tilton AH, Krywanio M, Greene C, Nadell JM, Posas H.** Schizencephaly: Familial occurrence. *Neurology* 1988;38(Suppl 1):398.

[14] **Byrd SE, Osborn RE, Bohan TP, Naidich TP.** The CT and MR evaluation of migrational disorders of the brain, part I. Lissencephaly and pachygyria. *Pediatr Radiol* 1989;19:151-6.

[15] **Klingensmith WC III, Cioffi-Ragan DT.** Schizencephaly: Diagnosis and progression in utero. *Radiology* 1986;159:617-8.

[16] **Lituanica M, Passamonti U, Cordone MS, Magnano GM, Toma P.** Schizencephaly: Prenatal diagnosis by computed sonography and magnetic resonance imaging. *Prenat Diagn* 1989;9:649-55.

[17] **Lyon G, Evrard P.** *Neuropadiatrie.* Paris: Masson, 1987;54-7.

[18] **Gross H, Simanyi M.** Porencephaly. In: Vinken PJ, Bruyn GW, eds. *Handbook of clinical neurology.* Amsterdam: Elsevier/North Holland, 1977;30:681-92.

[19] **Barkovich AJ, Norman D.** Absence of the septum pellucidum: A useful sign in the diagnosis of congenital brain malformations. *Am J Roentgenol* 1989;152:353-60.

[20] **Benner JD, Preslan MW, Gratz E, Joslyn J, Schwartz M, Kelman S.** Septo-optic dysplasia in two siblings. *Am J Ophthalmol* 1990;109:632-7.

[21] **Landrieu P, Evrard P.** La dysplasie septo-optique: Etude clinique et elements d'un conseil genetique. *J Genet Hum* 1979;27:329-41.