

Note

A 3-year follow-up study of ‘orientation agnosia’

Naomi Fujinaga^a, Taro Muramatsu^{b,*}, Misao Ogano^a, Motoichiro Kato^b^a Department of Rehabilitation, Nozomi Hospital, Komuro 3170, Ina-machi, Kita-adachi-gun, Saitama 362-0806, Japan^b Department of Neuropsychiatry, Keio University School of Medicine, Shinanomachi 35, Shinjuku-ku, Tokyo 160-8582, Japan

Received 6 May 2004; received in revised form 6 October 2004; accepted 28 October 2004

Abstract

Dissociation between the ability to recognize misoriented objects and to determine their orientation has been reported in a small number of patients, but the long-term course of this deficit has not been reported so far. Here, we describe the case of a 32-year-old female who had bilateral occipito-temporal damage caused by a cerebrovascular accident. Neuropsychological assessment performed at 6 months after the occurrence of the cerebrovascular accident revealed that she was almost generally agnostic for object orientation. The patient was then re-tested 3 years later, when she showed apparently striking recovery in her ability to determine object orientation. However, closer examination revealed that she still displayed the same impairment, although at this time, it was only for objects presented in non-cardinal angles. Moreover, she had problems mostly discriminating orientations that differed by small amounts. The ability of patients to discriminate a variety of orientations should be further tested in future investigations in this field.

© 2004 Elsevier Ltd. All rights reserved.

Keywords: Visual recognition; Brain damage; Human

1. Introduction

It has been reported that certain patients with some neurological disorders are able to achieve object recognition while lacking knowledge of the orientation of the object, which means that the ability to judge the spatial attributes of an object, including the orientation, is dissociated from the ability to recognize and name the object. Turnbull et al. have offered the most detailed account of this phenomenon, which they term “agnosia for object orientation”. They have described three cases in which a clear dissociation was noted between a preserved ability to identify objects presented in different orientations and the ability to correctly recognize the presented orientation of the object (Turnbull, Beschin, & Della Sala, 1997; Turnbull, Laws, & McCarthy, 1995). The disorder is especially intriguing with regard to object recognition from multiple viewpoints, which has been a matter of long debate in experimental psychology as well as computa-

tional vision science (Deneve & Pouget, 2003; Riesenhuber & Poggio, 2000). It is a remarkable feature of our visual system that it allows us to recognize objects, regardless of the viewpoints they are seen from. The basis for this ability is a subject of much controversy in the visual recognition literature. One proposal is that the representation of objects in the long-term memory codes features in a manner that is independent of the object orientation. According to this theory, incoming stimuli are similarly described using representations that do not encode the viewpoints, and are therefore termed “viewpoint-independent” (Corballis, 1988; Marr & Nishihara, 1978). On the other hand, a “viewpoint-dependent” theory has been put forth, which hypothesizes that objects are represented in long-term memory in typical orientations, and misoriented stimuli are aligned by a process of analogue imagery transformation (such as mental rotation) (De Caro, 1998; Jolicoeur, 1988; Tarr & Pinker, 1989). Turnbull and colleagues speculated that the orientation agnosia in their cases reflects the existence of an orientation-independent (viewpoint-independent) route to object recognition, thus lending support to the viewpoint-independent theory of object recognition.

* Corresponding author. Tel.: +81 3 3353 1211; fax: +81 3 5379 0187.
E-mail address: muramats@sc.itc.keio.ac.jp (T. Muramatsu).

Karnath, Ferber, & Bulthoff (2000), however, argued against this viewpoint-independent hypothesis based on the observations in their patient KB, who made no errors in her orientation judgement when the items were upright, but whose response accuracy dropped to chance levels when the items were presented in non-upright orientations. The authors concluded that this visual recognition disorder was caused by the failure of a neural system that codes orientation information. They contended that upright orientations, by virtue of their stronger representation, were more robust against neuronal damage. Based on such evidence, Karnath et al. suggested that these patients do not have an “agnosia for object orientation”, but rather “a disability in determining the orientation predominantly of those objects that had a non-upright orientation”. They further refuted, based on the same consideration, the claim that the findings in the patients can be interpreted as suggesting that object structure is coded in an orientation-invariant (viewpoint-independent) way.

In turn, Turnbull, Della Sala, & Beschin (2002) argued against the above contention of Karnath et al. by reporting the finding that in reaction time tasks using rotated objects, patients recognized items at 0° no faster than rotated items and made as many errors in recognizing objects at 0° as they did in recognizing those rotated at 120°. They argued, therefore, that their patients’ disorder did indeed represent ‘orientation agnosia’, and supported the claim that objects are typically recognized using a mechanism that is viewpoint-independent. On the other hand, in a study on Alzheimer’s disease patients, Turnbull et al. demonstrated that recognition errors were greater for objects that were rotated than for those that were at 0°, and acknowledged mixed support for Karnath et al.’s theory (Caterini, Della Sala, Spinnler, Stangalino, & Turnbull, 2002).

More recently, an alternative view was put forward by Harris et al., which they call “a failure to find the axis”. In their report, patient EL, a case of probable Alzheimer’s disease, displayed a profound inability to judge the orientation of non-upright objects, but remarkably retained intact knowledge of the upright orientation. Strikingly, his orientation judgement was also more accurate for upside-down objects (i.e., 180°) than for other orientations (Harris, Harris, & Caine, 2001). Harris et al. interpreted these results as evidence that judgement of object orientation is facilitated when the orientation of the principal axis of the object matches that of an internal representation. Thus, they propose that this disorder is related to a failure to locate an object’s principal axis.

In this paper, we report a new patient who showed apparent dissociation between a knowledge of object identity and that of object orientation after suffering a cerebrovascular accident. The availability of neuropsychological data from this patient 3 years after the occurrence of the cerebrovascular accident draws special interest in this case. While the data initially suggested striking recovery from the earlier deficit, more detailed testing revealed that the patient still exhibited some residual deficit related to orientation judgement.

2. Case report

RU was a 32-year-old right-handed female patient who was found to have multiple brain infarctions when she recovered from consciousness disturbance caused by antihypertensive drug overdose. She was admitted to the neurological unit with right hemiparesis, right spatial neglect and alexia. MRI revealed bilateral lesions in the occipito-parietal cortex (Fig. 1). After 2-months’ conservative treatment, when she recovered from the aforementioned neurological deficits, the patient was admitted to a rehabilitation center. While an inpatient at the rehabilitation center from December 2000 to February 2001, she was assessed on a subset of the WAIS-R and scored a verbal IQ of 77. However, she was unable to complete any items on the Performance Scale due to severe perceptual and spatial difficulties. In view of this poor performance, her perceptual ability was investigated in greater detail and she was found to have associative visual agnosia at 3 months after the occurrence of the cerebrovascular accident (she had difficulty recognizing a variety of visually presented objects and drawings, but could successfully match pairs of visual stimuli as being the same or different). While she had almost recovered from this deficit at 6 months after the occurrence of the cerebrovascular accident, it was found that she still could not judge line orientation correctly. In addition, impairment of object orientation recognition was also seen in daily life, e.g., she could not read the time from the positions of the hands on a clock.

In order to further investigate and quantify this deficit in our patient, we conducted a series of experiments to test her ability to detect object at two time-points, namely at 6 months and at 3 years after the onset. Three healthy subjects (two females and one male; mean age 33.3 ± 1.2) also participated as normal subjects, obtaining an accuracy of 100% in each task unless stated otherwise.

2.1. Investigation at 6 months after the onset

Because the clinical impression was of ‘orientation agnosia’, a series of tasks to confirm this condition according to the protocols in previously published literature were given to RU. Line drawings used for the experiments were selected from the Snodgrass and Vanderwart corpus (Snodgrass & Vanderwart, 1980). The drawings were selected so that they represented objects in unambiguous canonical upright orientations.

2.1.1. Task 1: Object recognition versus knowledge of the object’s canonical orientation

In this experiment, RU’s ability at object recognition was compared with her knowledge of the same object’s canonical orientation. Thirty-five pictures of objects were presented individually on a total of four occasions, each time in one of the four different cardinal orientations (0°, 90°, 180°, 270°). RU was first required to name the item as it was presented, and then to judge the correct orientation of the object.

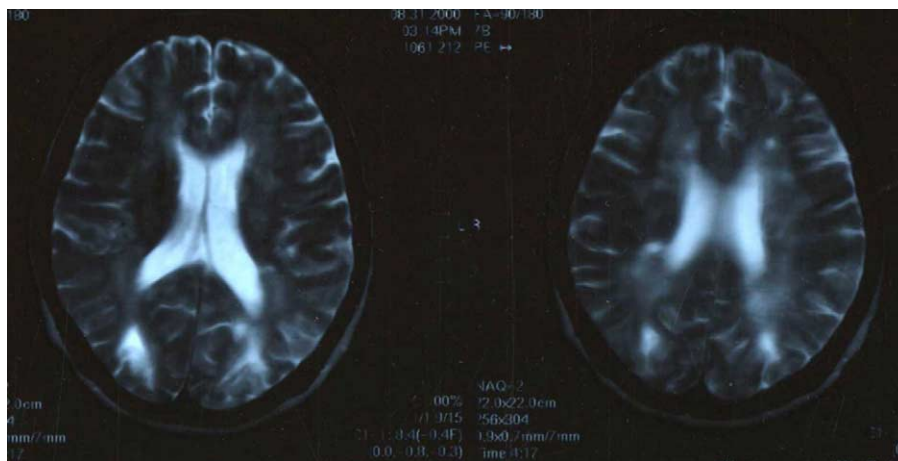


Fig. 1. MRI scan 2 months post onset (left brain on right side). Bilateral lesions visualized in the occipito-parietal cortex.

RU correctly named all the 35/35 items with ease. In contrast to her excellent recognition of the objects that were presented in different orientations, RU showed profound impairment in her ability to judge the object's orientation; she could correctly judge the orientation of only 5/35 items. In fact, she got all the upright objects correct; she said that they all looked upright. These results suggested that RU exhibited distinct dissociation between her ability at object recognition and her ability to correctly judge the same object's canonical orientation.

2.1.2. Task 2: Knowledge of the object's canonical orientation

Pictures of 35 objects, each printed on a separate card, were prepared. RU was asked to rotate the cards so as to bring the pictures of the objects to their canonical upright position. She was instructed to indicate to the examiner when the 'upright orientation' of the object was reached (Karnath et al., 2000).

RU correctly performed the task for only 5/35 items. The task was essentially the same as that presented by Karnath et al. to their patient KB, who successfully performed this task with ease. Based on the performance of their patient, Karnath et al. argued that the disorder did not represent "agnosia for object orientation", but rather "a disability to determine the orientation predominantly of those objects that have a non-upright orientation". In contrast, RU in our study showed severe deficit in correctly determining even the upright orientation of the stimuli. Thus, RU seemed to have a poor knowledge of the canonical upright orientation of the objects presented to her.

2.1.3. Task 3: Orientation discrimination (matching)

Four copies of each selected drawing were printed in four different orientations (0° , 90° , 180° , 270°) on a square card. RU's task was to match the sample stimulus with the figure of the same orientation on the square card.

RU could not match any of the drawings (0/6). Because she did not have simultanagnosia, her performance indicated that RU had severe difficulty in matching the orientations of the objects.

2.1.4. Task 4: Copying misoriented drawings

The same drawings as those used in Task 3 were used. The stimuli were rotated to 0° , 90° , 180° and 270° , and reproduced on square cards. The drawings of the objects in each of the four different cardinal orientations were presented to RU, who was required to copy the objects at the presented orientation.

RU copied all of the forms with reasonable accuracy, but copied the rotation of 7/10 items incorrectly. She drew all 10 objects in their canonical upright position. The result implied that RU had some knowledge of the canonical upright orientation of the objects.

2.2. Investigations at 3 years after the onset

Tasks 1–3 described below were essentially the same as those given to the patient at 6 months, except for Task 3, in which orientation discrimination was tested in greater detail.

2.2.1. Task 1: Object recognition versus knowledge of the object's canonical orientation

This task was identical to Task 1 presented to the patient at 6 months after the occurrence of the cerebrovascular accident.

RU correctly named, as well as judged the orientation, of all the 35/35 items with ease. Thus, she performed with maximum accuracy, giving 100% correct responses.

2.2.2. Task 2: Knowledge of the object's canonical orientation

This task was also identical to Task 2 presented to the patient at 6 months.

RU performed correctly in 100% of the items. Together with the results in Task 1, one can reasonably conclude that

at this time-point, RU had perfect knowledge of the object's canonical orientation.

2.2.3. Task 3: Orientation discrimination (matching) (cardinal or non-cardinal orientations)

RU was presented with pairs of identical objects and was asked to determine whether they were in the same or in different orientations. Tasks 3a–3c (20 trials each) tested her ability at discrimination of unambiguous cardinal orientations (3a, 0° versus 180°; 3b, 0° versus 90°; 3c, 90° versus 270°), while Task 3d, consisting of 30 trials, tested her ability to discriminate non-cardinal orientations (discrepancies in the orientations of two objects positioned at various angles between 20° and 170°).

RU's performance was strikingly different across orientations. In Tasks 3a–3c, RU was easily able to discriminate the orientations of the two objects. In contrast, in Task 3d, her performance was worse than that in Tasks 3a–3c (23/30, 77% correct; controls performed 97.7% correct). Six out of the seven incorrect responses in Task 3d were for pairs whose discrepancies in orientation were less than 90°. These results showed that RU could successfully discriminate between two misoriented items only when the items were presented at cardinal (0°, 90°, 180°, 270°) orientations.

3. Discussion

RU, who had bilateral occipito-parietal damage after a cerebrovascular accident, showed normal object recognition but an impaired ability to judge object orientation. This disorder became evident at 6 months after the occurrence of the cerebrovascular accident, when her ability to establish the canonical upright orientations of individual objects (Tasks 1 and 2), to match the cardinal orientations of object drawings (Task 3), and to copy rotated drawings (Task 4) was investigated. Her performance was not consistent with the performance of Karnath's case, KB, who had perfectly preserved knowledge of the upright orientation, but was more similar to that of Turnbull et al.'s three key cases, who were labeled as having 'orientation agnosia'. However, that RU could draw objects in their upright canonical orientation suggested that she had some knowledge of the upright orientation. Thus, at this stage, our results led us, as also conceded by Turnbull et al. to offer mixed support for Karnath et al.'s hypothesis. Our observations at 6 months therefore just placed on record another case with so-called 'orientation agnosia'.

Because all of the earlier descriptions of related cases reported so far have been based on relatively short-term observations, the availability of neuropsychological data from our patient 3 years after the onset made her a case of special interest. Our patient showed a striking recovery of her ability for orientation judgement; that is, in the conventional orientation judgment tasks (Tasks 1–3c), RU performed with maximum accuracy, giving 100% correct responses.

However, closer investigation revealed that she still had some impairment of orientation judgement, i.e., in the matching task (Task 3), although she was able to determine object orientation perfectly when the item was presented at cardinal angles (0°, 90°, 180°, 270°), her judgement accuracy dropped strikingly when the items were rotated in non-cardinal angles. Moreover, she had problems mostly discriminating orientations that differed by small amounts (less than 90°, Task 3d), which suggested that her residual deficits only really apply to these finer discriminations. Therefore, even by 3 years after the onset, RU's ability for orientation judgement had not fully recovered. In none of the previous studies were such detailed tests performed over the long-term, hence it remains unclear whether the other reported cases also had the same type of impairment as that exhibited by our case.

The fundamental impairment underlying the dissociation between the ability to recognize misoriented objects and the ability to determine their orientation seen in certain neurological patients has still not been elucidated, owing, at least in part, to the heterogeneity of performance of different reported cases: each case's ability to determine object orientation differed depending on the presented orientation of the stimulus (Harris et al., 2001; Karnath et al., 2000; Turnbull et al., 1995, 1997). While the differences may reflect the distinctiveness of each case, they may also be a reflection of the severity of each case, or the stage of the disorder, i.e., the 'orientation agnosia' described by Turnbull et al. may represent the most severe form, and the deficit described by Harris et al. in EL may represent the least severe form. The observations in our case, RU, seem to support this latter view: her performance at 6 months after the onset was similar to that of the patients with the most severe deficit as described by Turnbull et al., and that at 3 years after the onset, the deficit was milder than the deficit described by Harris et al. in their patient.

This statement is a mere speculation based on RU's performance and those of other previously reported cases. Therefore, the propositions made here await further confirmation from future research. RU is the only case so far in whom recovery over the long-term has been observed. Moreover, our testing was limited, i.e., not fully structured, due to clinical considerations, and the process of recovery could not be investigated. However, given the rarity of the disorder and the significance of the object recognition theory, we believe that the present speculation merits attention.

As for the anatomical basis, the disorder has been investigated in the context of the 'two cortical visual systems' approach, that postulates the separation of the processes of object recognition from those involved in certain types of spatial coding: one route (the dorsal system) is dedicated to the control of actions and codes a viewer-centered representation. The other route (the ventral system) is concerned with object recognition and codes an object-centered representation (Goodale & Milner, 1992; Mishkin, Ungerleider, Macko, 1983). On this account, the proposition of 'orientation agnosia' would be consistent with the existence of the object-centered perceptual system, in the

absence of the viewer-centered system. This profile provides tentative support for the distinction between a ventral route to object recognition which is not orientation-dependent, but which probably also codes for the usual upright orientation of objects, and a more dorsally located neural mechanism for processing the orientation of objects for other purposes. Indeed, Turnbull et al. (1995) interpreted the observation of dissociation between normal object recognition and an impaired sense of object orientation as being mediated via the viewpoint-independent ventral stream in the absence of the dorsal stream that carries orientation information.

However, recent developments in vision science suggest that there is a continuum from viewpoint-independence to viewpoint-dependency, which is in part influenced by stimulus discriminability and the task at hand (Bar, 2001; Biederman & Bar, 1999; Edelman, 1995; Hayward & Tarr, 1997; Vanrie, Beatse, Wagemans, Sunaert, & Van Hecke, 2002). The debate around ‘orientation agnosia’ would certainly be more fruitful when it is discussed taking into consideration this continuum theory.

The present case, RU, exhibited so-called “orientation agnosia” 6 months after cerebrovascular accident; at face value this seemed to support the viewpoint-independent theory of visual recognition. At 3 years after the cerebrovascular accident, however, her orientation judgement was intact for cardinal orientation but disturbed for non-cardinal orientations, which could be interpreted as indicating that at least some viewpoint dependency existed in her ability to perceive object orientation, consistent with the continuum hypothesis.

We propose that to elucidate the basis of this rare disorder in some neurological patients who show an apparent dissociation between their knowledge of object identity and that of object orientation, experiments examining the patients’ ability to judge a variety of non-cardinal orientations should be planned and conducted in the future.

References

- Bar, M. (2001). Viewpoint dependency in visual object recognition does not necessarily imply viewer-centered representation. *Journal of Cognitive Neuroscience*, 13, 793–799.
- Biederman, I., & Bar, M. (1999). One-shot viewpoint invariance in matching novel objects. *Vision Research*, 39, 2885–2999.
- Caterini, F., Della Sala, S., Spinnler, H., Stangalino, C., & Turnbull, O. H. (2002). Object recognition and object orientation in Alzheimer’s disease. *Neuropsychology*, 16, 146–155.
- Corballis, M. C. (1988). Recognition of disoriented shapes. *Psychological Review*, 95, 115–123.
- De Caro, S. A. (1998). On the perception of objects and their orientations. *Spatial Vision*, 11, 385–399.
- Deneve, S., & Pouget, A. (2003). Basis functions for object-centered representations. *Neuron*, 37, 347–359.
- Edelman, S. (1995). Class similarity and viewpoint invariance in the recognition of 3-D objects. *Biological Cybernetics*, 72, 207–220.
- Goodale, M. A., & Milner, A. D. (1992). Separated visual pathways for perception and action. *Trends in Neurosciences*, 15, 20–25.
- Harris, I. M., Harris, J. A., & Caine, D. (2001). Object orientation agnosia: a failure to find the axis. *Journal of Cognitive Neurosciences*, 13, 800–812.
- Hayward, W. G., & Tarr, M. J. (1997). Testing conditions for viewpoint invariance in shaped recognition. *Journal of Experimental Psychology: Human Perception & Performance*, 23, 1511–1521.
- Jolicoeur, P. (1988). The time to name disoriented natural objects. *Memory and Cognition*, 13, 289–303.
- Karnath, H.-O., Ferber, S., & Bulthoff, H. H. (2000). Neuronal representation of object orientation. *Neuropsychologia*, 38, 1235–1241.
- Marr, D., & Nishihara, H. K. (1978). Representation and recognition of the spatial organization of three-dimensional shapes. *Proceedings of the Royal Society of London B*, 200, 269–294.
- Mishkin, M., Ungerleider, L. G., & Macko, K. A. (1983). Object vision and spatial vision: Two cortical pathways. *Trends in Neurosciences*, 6, 414–417.
- Riesenhuber, M., & Poggio, T. (2000). Models of object recognition. *Nature Neuroscience*, 3, 1199–1204.
- Snodgrass, J. G., & Vanderwart, M. (1980). A standardized set of 260 pictures: Norms for name agreement, image agreement, familiarity, and visual complexity. *Journal of Experimental Psychology: Human Perception and Performance*, 6, 174–215.
- Tarr, M. J., & Pinker, S. (1989). Mental rotation and orientation dependence in shape recognition. *Cognitive Psychology*, 21, 233–282.
- Turnbull, O. H., Beschin, N., & Della Sala, S. (1997). Agnosia for object orientation: Implications for theories of object recognition. *Neuropsychologia*, 35, 153–163.
- Turnbull, O. H., Della Sala, S., & Beschin, B. (2002). Agnosia for object orientation: Naming and mental rotation evidence. *Neurocase*, 8, 296–305.
- Turnbull, O. H., Laws, K. R., & McCarthy, R. A. (1995). Object recognition without knowledge of object orientation. *Cortex*, 31, 387–395.
- Vanrie, J., Beatse, E., Wagemans, J., Sunaert, S., & Van Hecke, P. (2002). Mental rotation versus invariant features in object perception from different viewpoints: an fMRI study. *Neuropsychologia*, 40, 917–930.