

L-2-Hydroxyglutaric Aciduria

Clinical, Neuroimaging, and Neuropathological Findings

Manuel Seijo-Martínez, MD; Carmen Navarro, MD; Maria Castro del Río, MD; Oscar Vila, MD; Miguel Puig, MD; Antonia Ribes, PhD; Mercedes Butron, MD

Background: L-2-Hydroxyglutaric aciduria is a rare, infantile-onset, autosomal recessive organic aciduria affecting exclusively the central nervous system. To our knowledge, only 1 complete report of the neuropathological findings in an adult has been published.

Objective: To present the clinical, neuroimaging, and neuropathological findings of L-2-hydroxyglutaric aciduria.

Design: Case report.

Setting: Complejo Hospitalario de Pontevedra, Pontevedra, Spain.

Patient: A 15-year-old boy who had early infantile-onset progressive psychomotor regression, mild choreo-dystonia affecting the distal part of the upper limbs, pyramidal signs, and epilepsy.

Results: The diagnosis of L-2-hydroxyglutaric aciduria was confirmed by the finding of highly elevated levels of L-2-hydroxyglutaric acid in the serum, urine, and cere-

brospinal fluid. The neuroimaging findings showed striking confluent subcortical white matter lesions and minimal basal ganglia (pallidum, thalamic, and putaminal) abnormalities. The patient died of a spontaneous mesenteric thrombosis. The postmortem neuropathological findings showed spongiosis and cystic cavitations in subcortical white matter, with minimal abnormalities of the basal ganglia. The dentate nucleus, a structure usually affected in neuroimaging studies, showed minimal neuronal loss but was surrounded by important spongiosis and microvacuolation with astrocytic proliferation.

Conclusions: This case reaffirms that L-2-hydroxyglutaric aciduria is a spongiform type of leukoencephalopathy with cystic cavitations predominating in the subcortical areas. Although the neuroimaging findings are highly characteristic of the disease, in this patient cerebellar abnormalities were minimal and dentate signal abnormalities were not present.

Arch Neurol. 2005;62:666-670

Author Affiliations:

Departments of Neurology (Drs Seijo-Martínez and Castro del Río) and Radiology (Dr Puig), Complejo Hospitalario de Pontevedra, Pontevedra, Spain; Department of Neuropathology, Hospital Meixoeiro, Vigo, Spain (Dr Navarro); Department of Radiology, Instituto Galego de Medicina Técnica (Dr Vila), and Pathology (Dr Butron), Hospital Xeral-Cies, Vigo; and Instituto de Bioquímica Clínica, Corporació Sanitaria Clínic, Barcelona, Spain (Dr Ribes).

FIRST DESCRIBED BY DURAN et al¹ and later characterized by Barth et al², L-2-hydroxyglutaric aciduria (L-2-HGA) is a rare, autosomal recessive organic aciduria affecting exclusively the central nervous system. This disease manifests mental retardation and psychomotor regression, motor dysfunction with ataxia, pyramidal and extrapyramidal signs, and epilepsy. Although the disease is usually of early infantile onset, recent reports indicate that it may be diagnosed in adults with a somewhat milder phenotype.^{3,4} The neuroimaging findings are very specific and affect the central white matter, basal ganglia, and cerebellum.⁵⁻⁸

Biochemically, L-2-HGA is characterized by increased concentrations of L-2-hydroxyglutaric acid (L-2-HG) in serum, urine, and cerebrospinal fluid. The basic metabolic defect and the pathogenesis are still obscure.

Approximately 75 cases of L-2-HGA have been diagnosed worldwide,⁹ and, to our knowledge, only 2 complete reports of neuropathological findings have been published, 1 of which referred to a neonate.^{10,11} In this study, we present the clinical, neuroimaging, and neuropathological findings of a patient with L-2-HGA, constituting the first report of this condition in Spain, to our knowledge.

REPORT OF A CASE

A 15-year-old boy was examined because of a well-controlled epileptic syndrome. The family history was noncontributory and his parents were not consanguineous. Pregnancy and labor had been uneventful. A slight psychomotor delay had been evident in the first few months of life, although the patient had been able to stand up and walk with aid. Although he did not develop complete language ability, he did

develop effective communicating ability. He had experienced a generalized seizure at the age of 18 months. At 18 to 24 months, his gait had worsened, with limb clumsiness, language regression, and progressive intellectual deterioration. The epileptic seizures recurred with variable frequency, and he was treated with phenobarbital; seizures did not recur after the age of 7 to 8 years.

At the age of 15 years, when first examined in our Neurology Service, the patient was wheelchair bound and completely dependent, even for feeding. He had severe mental retardation, dysphasia, pseudobulbar signs, bilateral optic atrophy, strabismus, hypoacusis, spastic tetraparesis, and choreodystonia in the upper limbs. Right plantar reflex was flexor and the left, extensor. The cranial perimeter measured 55.5 cm.

Routine biochemical serum measures were normal, as were results of other specific biochemical analyses including creatine kinase, calcium, ammonium, lactate, ceruloplasmin, prothrombin time, international normalized ratio, partially activated thromboplastin time, hexosaminidase A and B activity, β -mannosidase activity, and phytanic acid. Blood smear did not show acanthocytes. The cerebrospinal fluid was acellular with normal protein and glucose levels. An electrocardiogram, echocardiogram, plain chest radiograph, muscle biopsy specimen, electromyogram, and results of nerve conduction studies were all normal. Auditory and somatosensory evoked potentials were highly abnormal.

Organic acid studies showed increased concentrations of 2-HG in serum (23 $\mu\text{mol/L}$; control value, undetectable), urine (942 mmol/mol of creatinine; control value, <2.5 mmol/mol), and cerebrospinal fluid (30 $\mu\text{mol/L}$; control value, undetectable), which was proved to be L-2-HG by C. Jakobs, PhD (Metabolic Unit, Department of Clinical Chemistry, Free University, Amsterdam, the Netherlands).

Computed tomography of the brain showed generalized atrophy with diffuse hypodense lesions in subcortical white matter (**Figure 1**). Brain magnetic resonance imaging (**Figure 2**) showed generalized atrophy, atrophy of the corpus callosum, and extensive white matter hyperintense signals on T2-weighted and proton-density images, without cerebellar or thalamic lesions.

Folic acid supplementation at a dosage of 10 mg/d was started 6 months after the diagnosis. Ten months after the initial evaluation, while at school, the patient experienced spontaneous abdominal pain and lower gastrointestinal tract bleeding. An emergency laparotomy confirmed a massive mesenteric thrombosis. He died a few days later of multiorgan failure. Permission for postmortem examination was obtained, and the examination was performed a few hours after death.

On pathological examination, lesions were observed in various organs. Transmural necrosis affected the total length of the small intestine, with massive thrombosis in mesenteric vessels. Foci of hepatic infarcts were present. Slight atherosclerotic changes were seen in the abdominal aorta. Bilateral bronchopneumonia was present.

Neuropathological examination showed an unfixed brain weighing 1250 g. Gross examination showed thin gyri with a pseudomicrogyral pattern, clear leptomeninges, and discrete venous congestion. The cerebellum presented an increased consistency with widening of the cerebellar sulci.

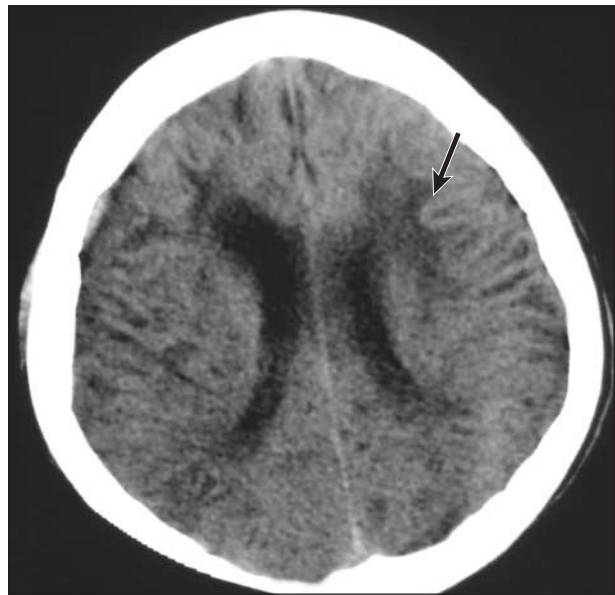


Figure 1. Computed tomographic image of the brain. Brain atrophy is present with hypodense bilateral subcortical white matter lesions. Note the sharp delimitation of the corticosubcortical junction (arrow).

The anterior aspect of the brainstem was moderately atrophic, especially at the level of the bulbar pyramids.

Coronal hemispheric sections disclosed severe and diffuse changes in the white matter with a lardaceous, grayish appearance and a soft consistency. Cystic cavities were seen in the peripheral subcortical areas (**Figure 3**). These changes were fairly symmetric in distribution. The ventricular system was not dilated.

The corpus callosum was thin but appeared well myelinated, as did the anterior commissure. There were no macroscopic abnormalities in the basal ganglia. On section, the cerebellum white matter was firm.

Histologically, there was slight cortical neuronal loss (**Figure 4**), with intense subpial gliosis, spongiosis, and vacuolation of the neuropil. The corticosubcortical areas presented notable gliosis that was well demonstrated with glial fibrillary acidic protein immunohistochemistry. The white matter was severely demyelinated, with cystic cavitations as recorded. With myelin staining, myelin sheaths were preserved in the corpus callosum, optic nerves, and chiasma, although there was myelin pallor and spongiosis. Fascicular oligodendroglia were lost in the most affected areas. Hyperplastic astrocytes, enhanced with glial fibrillary acidic protein, were numerous and regularly distributed within the white matter.

The basal nuclei showed spongiosis and patchy gliosis, especially in the areas adjacent to the internal capsule, which was markedly demyelinated and gliotic.

In the cerebellum, neuronal loss was discrete and affected mainly granular cells. The cerebellar white matter was better preserved than was hemispheric white matter, with the presence of myelin and no cavitations. The dentate nucleus showed minimal neuronal loss but was surrounded by important spongiosis and microvacuolation with astrocytic proliferation.

The periaqueductal white matter and the floor of the fourth ventricle were severely gliotic with spongiosis. The cranial nerve nuclei were not affected.

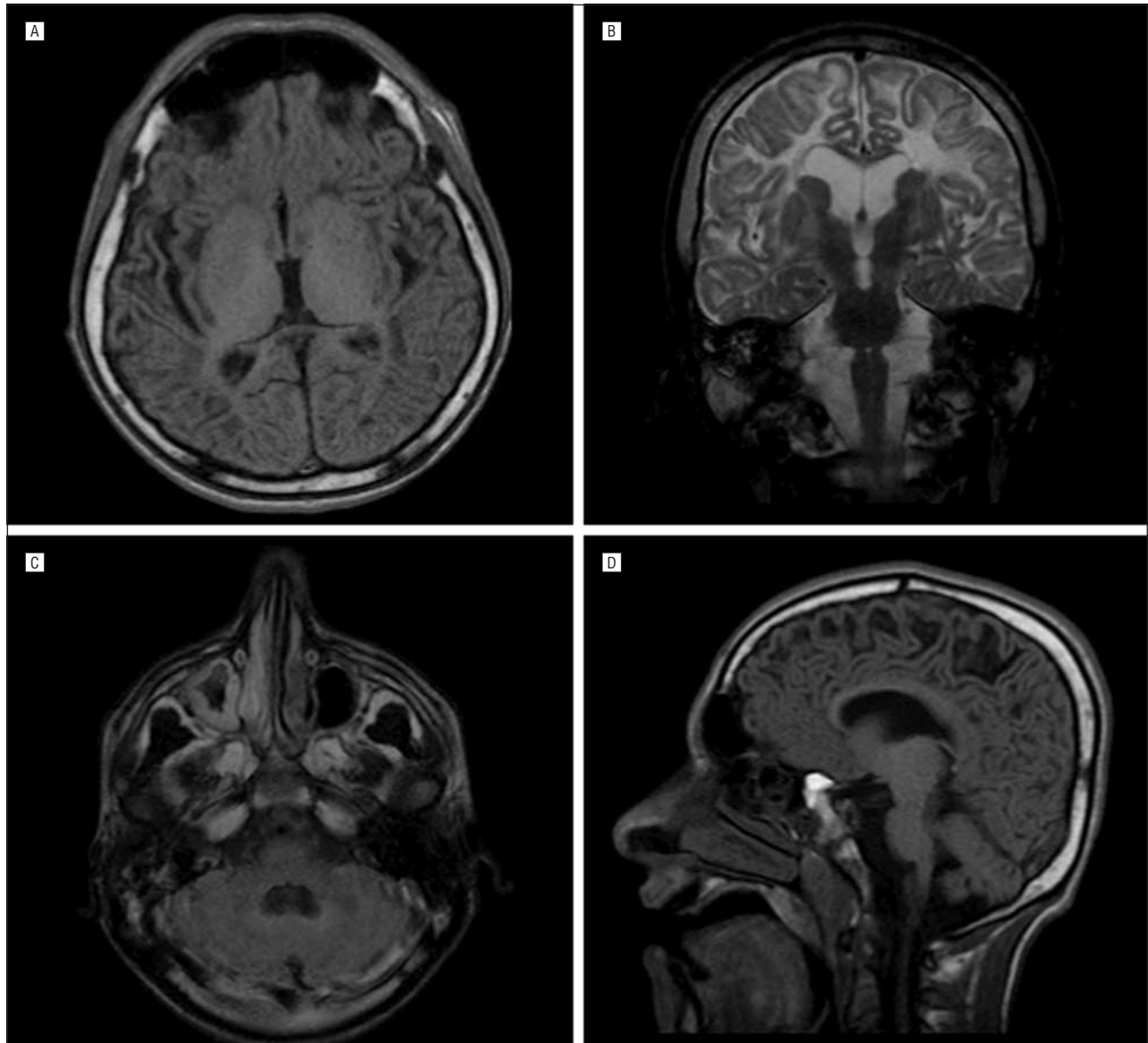


Figure 2. Magnetic resonance images of the brain. A, Axial T1-weighted image showing hypointense signals in subcortical white matter sparing the cortical rim. The thalamus shows a normal signal intensity. B, Coronal T2-weighted image showing hyperintense T2-weighted signal in bihemispheric white matter, prominent in the subcortical, peripheral white matter and with relative sparing of the internal capsule. No abnormal signal is observed in the caudate, putamen, pallidum, and thalami. Brain atrophy is evident, with bilateral ventricular dilation. C, Axial fluid-attenuated inversion recovery image. Posterior fossa shows normal signal intensity of the dentate nuclei. Cerebellar atrophy is not apparent, although slight dilation of the fourth ventricle is evident. D, Sagittal T1-weighted image showing hypointense signals in peripheral subcortical white matter.

COMMENT

This patient's condition was diagnosed on the basis of highly elevated levels of L-2-HG in urine, serum, and cerebrospinal fluid. The clinical presentation of L-2-HGA, in this case, was similar to those previously described with early infantile-onset progressive psychomotor regression, mild choreodystonia affecting the distal part of the upper limbs, pyramidal signs, and epilepsy. However, optic atrophy, an unusual manifestation not previously noted in this disease, was present.

The neuroimaging findings of L-2-HGA are considered highly suggestive of the diagnosis.⁵⁻⁸ The structures mainly affected are the white matter, cerebellum, and basal ganglia. The subcortical white matter abnor-

malities are extensive, multifocal or confluent, with involvement of the extreme and external capsules; they characteristically fade in a centripetal distribution.⁵ The corpus callosum and brainstem are usually spared. Typically, the cerebellum is atrophic and the dentate nuclei show abnormally high T2-weighted signals on magnetic resonance images. The findings in this case showed striking confluent subcortical white matter lesions and minimal basal ganglia (pallidum, thalamic, and putaminal) abnormalities. The caudate nucleus was not affected. Cerebellar abnormalities were minimal, without dentate signal abnormalities or cerebellar atrophy.

Neuropathological reports of this disease are scarce.¹⁰⁻¹² The only complete report describing an adult was that of a patient with a family history of L-2-HGA.¹⁰ He died

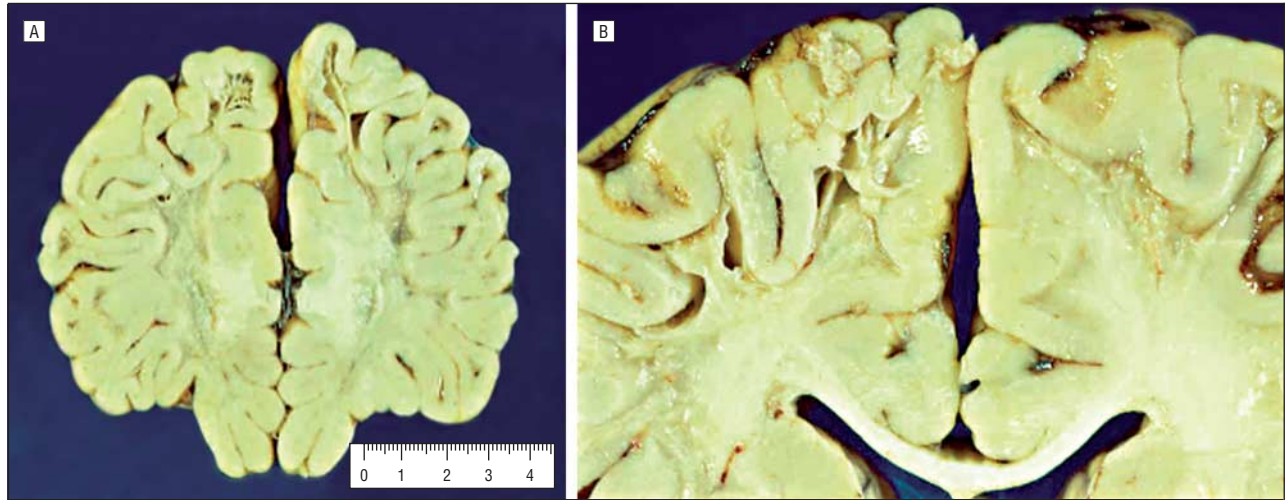


Figure 3. Sections of brain tissue. A, Frontal coronal section showing massive demyelination, with a bland aspect of the white matter and cystic formation in peripheral subcortical areas. The scale is in centimeters. B, Detail of the demyelinated areas in a parietal section. Note the slightly atrophic, otherwise relatively preserved, aspect of the corpus callosum.

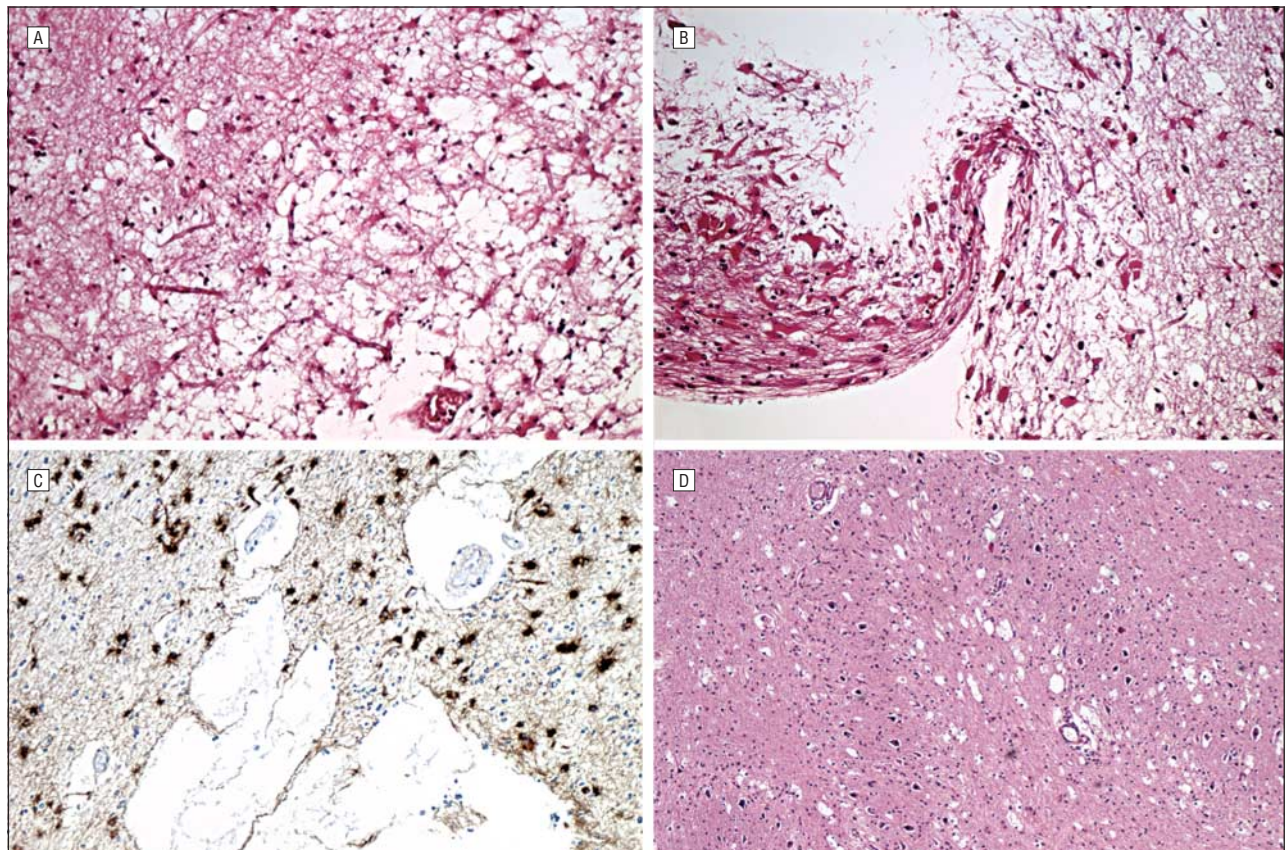


Figure 4. Microscopic views of brain tissue. A, Cortex and white matter, showing severe spongiosis of the latter with mild involvement of the cortex (hematoxylin-eosin, original magnification $\times 10$). B, Cystic areas surrounded by numerous hyperplastic astrocytes (hematoxylin-eosin, original magnification $\times 10$). C, Immunodetection with glial fibrillary acidic protein. An elevated number of positive hyperplastic astrocytes surround the microcysts in the white matter (glial fibrillary acidic protein, original magnification $\times 20$). D, Low-power image of the dentate nucleus. There is minimal neuronal loss, but spongiosis and vacuolation are present in the periphery of the nucleus (hematoxylin-eosin, original magnification $\times 5$).

suddenly, with fever, but the cause of death was not mentioned. The pathological study was limited to the brain and showed diffuse demyelination, spongiosis, and cystic cavitations in the subcortical regions. Severe cell loss and spongiosis were present in the dentate nucleus and pallidum, with less severe involvement of the striatum.

Myelin was normal in the corpus callosum, genu of the internal capsule, optic tract, and optic radiations. A second neuropathological report¹¹ described a neonate with cardiorespiratory problems at birth who died at the age of 28 days. The neuropathological findings of the brain showed pontocerebellar atrophy, olivopontocerebellar

neuronal loss, and gliosis in the brainstem white matter tracts. No significant changes were reported in the subcortical central white matter.

Our findings reaffirm the basic pathological substrate in L-2-HGA, namely, spongiosis and cystic cavitations in subcortical white matter.^{10,12} However, we found relatively few abnormalities in the basal ganglia and dentate nuclei. The minimal pathological involvement of the dentate nuclei is of interest, since magnetic resonance imaging signal abnormalities are usually present. Nonetheless, demyelination and spongiosis surrounded this structure. These neuropathological findings, along with the radiological manifestations, should be differentiated from other conditions with spongy degeneration, namely, Canavan disease, Kearns-Sayre syndrome, merosin-negative congenital muscular dystrophy, and other organic acidurias.⁷ The major consideration in the differential diagnosis is Canavan disease,⁸ which usually presents earlier in life and has a more rapid course. Although some organic acidurias manifest early encephalopathy syndromes leading to early diagnosis, others cause nonspecific symptoms such as psychomotor delay and epilepsy,¹³ which may be well controlled, as occurred with our patient.

The origin of L-2-HG is still unknown.⁹ A number of loading and fasting studies have been conducted, without conclusive results.² It is speculated that L-2-HG can be produced by reduction of 2-ketoglutarate,¹⁴ but so far no definite clues to the metabolic block involved have been found. The pathogenesis of L-2-HGA is also obscure, but it is probable that the accumulation of L-2-HG is toxic to the white matter, causing myelin vacuolation.⁷ Recent experimental evidence indicates that L-2-HG may directly provoke oxidative stress damage to lipids and proteins, besides reducing the brain's capacity to effectively modulate the enhanced production of free radicals.¹⁵ Accumulation of L-2-HG may also interfere with neuronal energy homeostasis by inhibiting creatine kinase activity¹⁶; this effect may underlie the cerebellar degeneration associated with L-2-HGA. The gene localization is still unknown, and there are no animal models.

Specific treatment is, unfortunately, not yet available for L-2-HGA. Because its structure is similar to that of glutamate, L-2-HG may competitively interfere with the addition of the glutamate "tail" to folic acid (pteroylmonoglutamate) (Hugo Moser, MD, e-mail, October 5, 2003). If the formation of folate-2-hydroxyglutarate occurs, it should not be active and may be excreted in the urine with secondary folic acid deficiency. For this reason, we treated the patient with folic acid supplementation during the 2 months until his death. An interesting aspect in this case is the cause of death, mesenteric thrombosis, which is very rare in the pediatric age group¹⁷ and was unexpected in this well-cared-for patient. The causes of death in previously described patients with L-2-HGA are not mentioned, and perhaps a prothrombotic state exists in some patients with this disease.

In summary, in contrast to previous reports, cerebellar imaging abnormalities were not observed in this case. The pathological findings evidenced massive demyelination of subcortical white matter and cystic cavitations in

a centrifugal distribution, cortical gliosis, and spongiosis, but with minimal involvement of the dentate nuclei.

Accepted for Publication: March 24, 2004.

Correspondence: Manuel Seijo-Martinez, MD, Neurology Service, Complejo Hospitalario de Pontevedra, 36.001 Pontevedra, Spain (msejom@meditex.es).

Author Contributions: Study concept and design: Seijo-Martínez. Acquisition of data: Seijo-Martínez and Navarro, Castro del Río, Puig, Ribes, and Butron. Analysis and interpretation of data: Seijo-Martínez, Navarro, and Vila. Drafting of the manuscript: Seijo-Martínez, Castro del Río, Puig, Ribes, and Butron. Critical revision of the manuscript for important intellectual content: Seijo-Martínez, Navarro, and Vila. Administrative, technical, and material support: Seijo-Martínez, Navarro, Castro del Río, Vila, Puig, Ribes, and Butron. Study supervision: Seijo-Martínez and Navarro.

Funding Support: This work was supported in part by grant 2003/REDG 054B from Fondo de Investigaciones Sanitarias, Madrid, Spain.

REFERENCES

1. Duran M, Kamerling JP, Bakker HD, van Gennip AH, Wadman SK. L-2-Hydroxyglutaric aciduria: an inborn error of metabolism? *J Inherit Metab Dis*. 1980;3:109-112.
2. Barth PG, Hoffmann GF, Jaeken J, et al. L-2-hydroxyglutaric acidemia: a novel inherited neurometabolic disease. *Ann Neurol*. 1992;32:66-67.
3. Warmuth-Metz M, Becker G, Bendszus M, Solymosi L. Spinal canal stenosis in L-2-hydroxyglutaric aciduria. *Arch Neurol*. 2000;57:1635-1637.
4. Fujitake J, Ishikawa Y, Fujii H, et al. L-2-hydroxyglutaric aciduria: two Japanese adult cases in one family. *J Neurol*. 1999;246:378-382.
5. D'Incerti L, Farina L, Moroni I, Uziel G, Savoirdo M. L-2-Hydroxyglutaric aciduria: MRI in seven cases. *Neuroradiology*. 1998;40:727-733.
6. Moroni I, D'Incerti L, Farina L, Rimoldi M, Uziel G. Clinical, biochemical and neuroradiological findings in L-2-hydroxyglutaric aciduria. *Neurol Sci*. 2000;21:103-108.
7. Van der Knaap MS, Valk J, Barth PG, et al. Leukoencephalopathy with swelling in children and adolescents: MRI patterns and differential diagnosis. *Neuroradiology*. 1995;37:679-686.
8. Topcu M, Erdem G, Saatçi I, et al. Clinical and magnetic resonance imaging features of L-2-hydroxyglutaric acidemia: report of three cases in comparison with Canavan disease. *J Child Neurol*. 1996;11:373-377.
9. Struys EA, Verhoeven NM, Roos B, Jakobs C. Disease-related metabolites in culture medium of fibroblasts from patients with D-2-hydroxyglutaric aciduria, L-2-hydroxyglutaric aciduria and combined D/L-2-hydroxyglutaric aciduria. *Clin Chem*. 2003;49:1133-1138.
10. Larnaout A, Hentati F, Belal S, Ben Hamida C, Kaabachi N, Ben Hamida M. Clinical and pathological study of three Tunisian siblings with L-2-hydroxyglutaric aciduria. *Acta Neuropathol (Berl)*. 1994;88:367-370.
11. Chen E, Nyhan WL, Jakobs C, et al. L-2-Hydroxyglutaric aciduria: neuropathological correlations and first report of severe neurodegenerative disease and neonatal death. *J Inherit Metab Dis*. 1996;19:335-343.
12. Wilcken B, Pitt J, Heath D, Walsh P, Wilson G, Buchanan N. L-2-hydroxyglutaric aciduria: three Australian cases. *J Inherit Metab Dis*. 1993;16:501-504.
13. Hoffmann GF, Gibson KM, Trefz FK, Nyhan WL, Bremer HJ, Rating D. Neurological manifestations of organic acid disorders. *Eur J Pediatr*. 1994;153(suppl 1):S94-S100.
14. Kamoun P, Richard V, Rabier D, Saudubray JM. Plasma lysine concentration and availability of 2-ketoglutarate in liver mitochondria. *J Inherit Metab Dis*. 2002;25:1-6.
15. Latini A, Scussiato K, Borba Rosa R, et al. Induction of oxidative stress by L-2-hydroxyglutaric acid in rat brain. *J Neurosci Res*. 2003;74:103-110.
16. da Silva CG, Bueno AR, Schuck PF, et al. L-2-hydroxyglutaric acid inhibits mitochondrial creatine kinase activity from cerebellum of developing rats. *Int J Dev Neurosci*. 2003;21:217-224.
17. Oguzkurt P, Senocak ME, Ciftci AO, Tanyel FC, Buyukpamukcu N. Mesenteric vascular occlusion resulting in intestinal necrosis in children. *J Pediatr Surg*. 2000;35:1161-1164.