

Pituitary apoplexy: An unusual cause of frontal lobe syndrome

A Bhansali,¹ P Dutta,¹ N Khandelwal,² A Pathak³ and RK Vashisht⁴

Departments of ¹Endocrinology, ²Radiodiagnosis, ³Neurosurgery and ⁴Pathology, Postgraduate Institute of Medical Education and Research, Chandigarh, India

SUMMARY

Pituitary apoplexy presenting as frontal lobe syndrome is rare. Interestingly, in our patient the frontal lobe infarct was as a result of intense anterior cerebral artery spasm consequent to nonaneurysmal subarachnoid haemorrhage. The mechanisms of cerebral infarct associated with pituitary apoplexy are discussed.

Key words: anterior cerebral artery; cerebrovascular accident; pituitary apoplexy.

INTRODUCTION

Pituitary apoplexy is a rare but life-threatening disorder characterized by a series of clinical events in the form of acute onset of severe headache, visual impairment, ophthalmoplegia, meningism and altered sensorium.¹ These manifestations result from acute enlargement of the pituitary gland caused by infarction and/or haemorrhage leading to compression of the surrounding structures and/or extravasation of blood into the subarachnoid space.^{1,2} This usually occurs in an adenomatous gland and rarely in a normal pituitary gland.¹ Focal neurological deficits in the form of hemiplegia or frontal lobe syndrome in association with pituitary apoplexy have to date been reported.^{3–5} These manifestations are attributed to internal carotid artery or anterior cerebral artery occlusion and/or spasm consequent on the compression of vessels by an enlarging pituitary mass or vasospasm resulting from spillage of blood into the subarachnoid space. Rarely, internal carotid artery dissection may present with pituitary apoplexy and hemiplegia because of either accelerated hypertension or atherosclerosis.³

We report a patient who presented with frontal lobe syndrome as a result of anterior cerebral artery spasm consequent on a non-aneurysmal subarachnoid haemorrhage (SAH) as the first presenting manifestation of haemorrhage into a non-functioning pituitary tumour.

CASE REPORT

A 30-year-old man presented with sudden onset of headache, vomiting and complete loss of vision in the left eye and then the right eye for 10 days prior to admission. He was confused, disoriented and aggressive. However, he was obeying commands and opening his eyes on request. On examination, his blood pressure was 130/80 mmHg. He had complete loss of vision in both eyes with absence of perception of light, perception of rays and bilateral optic atrophy. Signs of meningeal irritation in the form of neck stiffness and Kernig's sign were positive. He had evidence of frontal disinhibition syndrome in the form of fluctuating mood, aggressive and abusive behaviour, disorientation with respect to time, place and person, and urinary incontinence. Other cranial nerves, motor and sensory systems and systemic examinations were normal. Lumbar puncture done before admission to this hospital revealed normal cerebrospinal fluid protein and glucose but plenty of red cells. Serum biochemistry showed serum sodium 130 mEq/L (normal: 128–135 mEq/L), potassium 3.6 mEq/L (normal: 3.5–5.2 mEq/L), glucose 3 mmol/L, T₃ 0.83 ng/mL (normal: 0.6–1.5 ng/mL), T₄ 65 ng/mL (normal: 60–150 ng/mL), thyrotropin 2.2 U/mL (normal: 0.5–4.6 U/mL), cortisol (random) 400 nmol/L (normal: >700 nmol/L in stress), prolactin (PRL) 18.9 ng/mL (normal: 5–16 ng/mL), leutinizing hormone 2.2 mIU/mL (normal: 5–15 mIU/mL), follicular

A Bhansali DM; P Dutta DM; N Khandelwal MD, DNB; A Pathak Mch; RK Vashisht MD, MRC Path.

Correspondence: Dr Anil Bhansali, Department of Endocrinology, Postgraduate Institute of Medical Education and Research, Chandigarh-160012, India. Email: anilbhansali_endocrine@rediffmail.com

Submitted 24 February 2003; resubmitted 7 October 2003; accepted 4 July 2004.

stimulating hormone 2.5 mIU/mL (normal: 5–15 mIU/mL) and testosterone 6 nmol/L (normal: 9–27 nmol/L).

Plain CT of the head revealed haemorrhage into a large pituitary adenoma, with subarachnoid extension and a left medial frontal lobe infarct (Fig. 1). Magnetic resonance imaging confirmed the same findings with a tumour size of 4 × 3 cm with suprasellar but no parasellar extension and haemorrhage into the tumour (Fig. 2a,b). There was a hyperintense wedge-shaped area in the left frontal region on MRI suggestive of infarct with subarachnoid haemorrhage in the anterior inter-hemispheric fissure. However, there was a suspicion of a

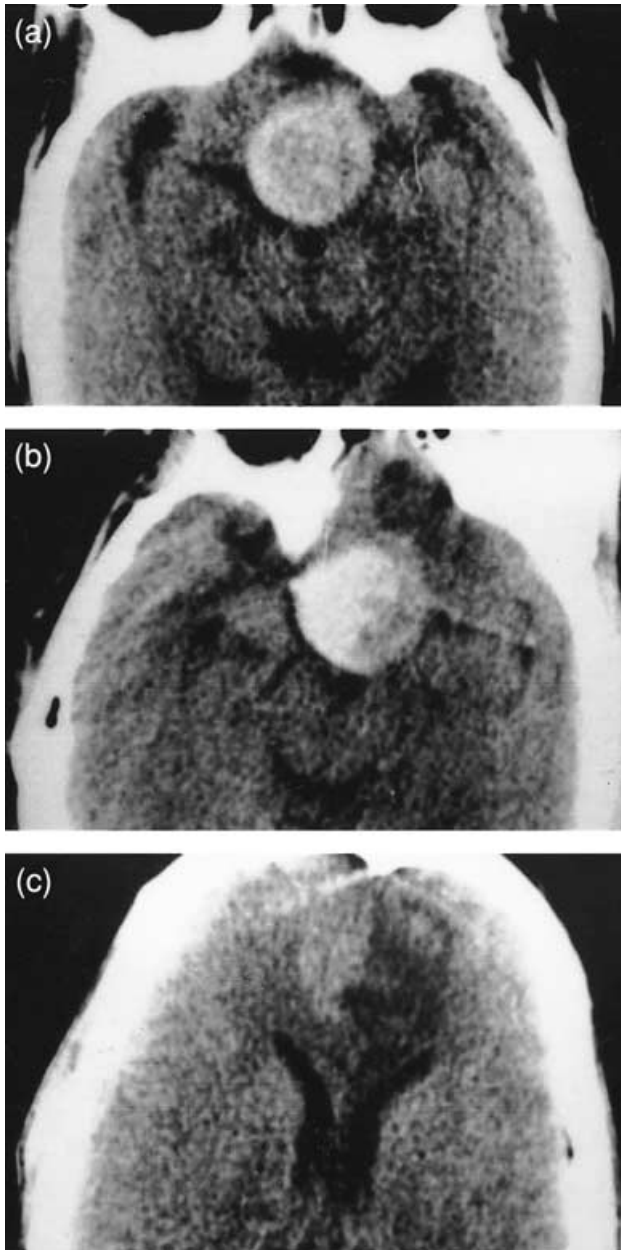


Fig. 1. (a) Plain CT shows a hyperdense mass in the suprasellar region. (b) Contrast-enhanced CT shows partial enhancement of the pituitary mass and (c) an anterior cerebral artery territory infarct on the left side.

vascular anomaly in the region of anterior communicating artery (ACOM). Digital subtraction angiography (DSA) was therefore performed. It showed typical features of a pituitary adenoma in the form of opening up of the carotid siphon and elevation of the A₁ segment of the anterior cerebral arteries. In addition, it revealed bilateral pencil-thin anterior cerebral arteries suggestive of vasospasm. There was no evidence of aneurysm or any major compression at circle of Willis (Fig. 2c).

The patient was managed with i.v. mannitol, dexamethasone and haloperidol. His sensorium improved, his agitation decreased and he was discharged after 2 weeks. Re-evaluation during follow up showed that he was euthyroid and eucortisolic on replacement doses of levothyroxine and prednisolone, respectively. Repeat DSA and CT angiogram during this period showed normal calibre and filling-in of the anterior cerebral arteries and circle of Willis. There was no evidence of aneurysm or dissection (Fig. 3). He underwent trans-sphenoidal surgery uneventfully and histopathology of the tumour showed a pituitary adenoma with haemosiderin pigment-laden macrophages suggestive of old haemorrhage (Fig. 4). Immunostaining for growth hormone and PRL were negative. The patient is doing well and his vision improved in left eye to 6/6, while his right eye did not show much improvement.

DISCUSSION

The diagnosis of pituitary apoplexy is usually clear when there is a known tumour. However, when the presenting features are suggestive of subarachnoid haemorrhage or stroke, the underlying diagnosis may be overlooked. Bilateral optic atrophy in this setting points towards pituitary adenoma undergoing apoplexy.¹ Our patient's aggressive and violent behaviour overshadowed his other manifestations but severe headache and progressive loss of vision with bilateral optic atrophy pointed towards pituitary apoplexy with a frontal lobe infarct.

The occurrence of hemiplegia or frontal lobe syndrome in patients with pituitary apoplexy is extremely unusual.^{3–5} These manifestations are the result of an ischaemic insult producing cerebral infarcts. Pituitary apoplexy can cause cerebral infarction by various mechanisms.⁴ These include compression of an intracranial vessel by an enlarging pituitary mass, associated subarachnoid haemorrhage leading to spasm in surrounding vessels because of the irritant effect of blood, artery-to-artery embolization and hypotension.⁴ Rarely, ischaemia or dissection of the internal carotid artery may be the primary event leading to infarction of the pituitary adenoma.^{3,5} Vasospasm as a result of the irritant effect of blood in the subarachnoid space was the most plausible explanation of frontal lobe infarct in our case at presentation. However, in view of the SAH, suspicion of a vascular anomaly in the ACOM region and previous reports of association of pituitary apoplexy with concomitant aneurysmal bleed,⁶ ACOM aneurysm with rupture was suspected. The demonstration of bilateral pencil-thin anterior cerebral arteries

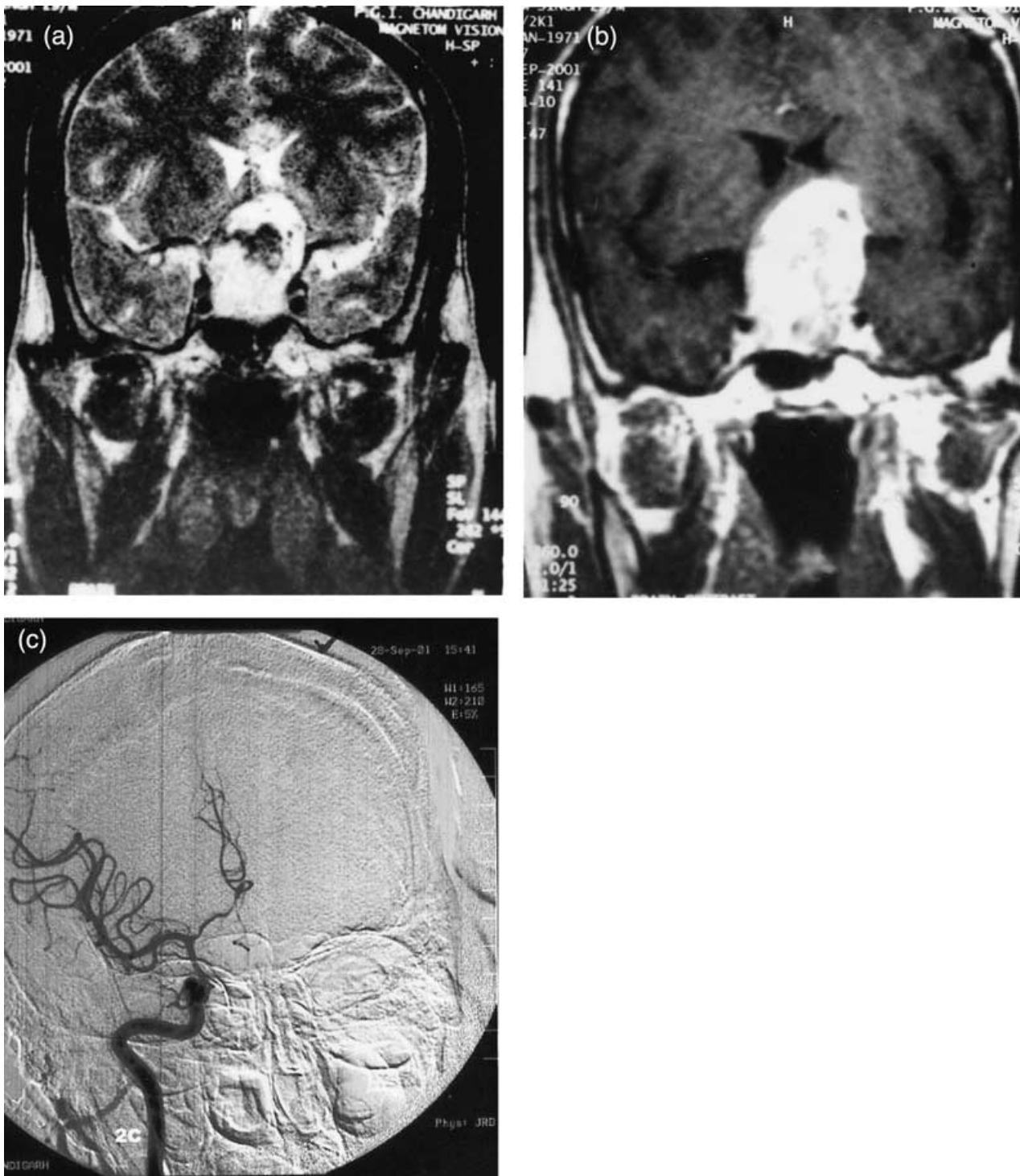


Fig. 2. (a) T2-weighted coronal section of MR shows hyperintense mass in the sellar and the suprasellar region showing central hypointensity suggestive of a subacute bleed. Note hyperintensity in the left cingulate region suggestive of infarct. (b) Contrast-enhanced MR shows enhancement of the pituitary gland with central non-enhancing portion. (c) Right carotid digital subtraction angiography at the time of presentation showed spasm of supraclinoid internal carotid artery and A₁ segment of the anterior cerebral artery (ACA associated with upward lifting of A₁ segment). Note loop of A₂ segment of the ACA.

on DSA supported the hypothesis of vasospasm as an explanation of his clinical syndrome. This vasospasm is felt to have been of sufficient magnitude to produce cerebral infarction. On

re-evaluation, the DSA and CT angiogram did not reveal any aneurysm or dissection, whereas normal calibre and filling-in of the anterior cerebral arteries and circle of Willis were seen.

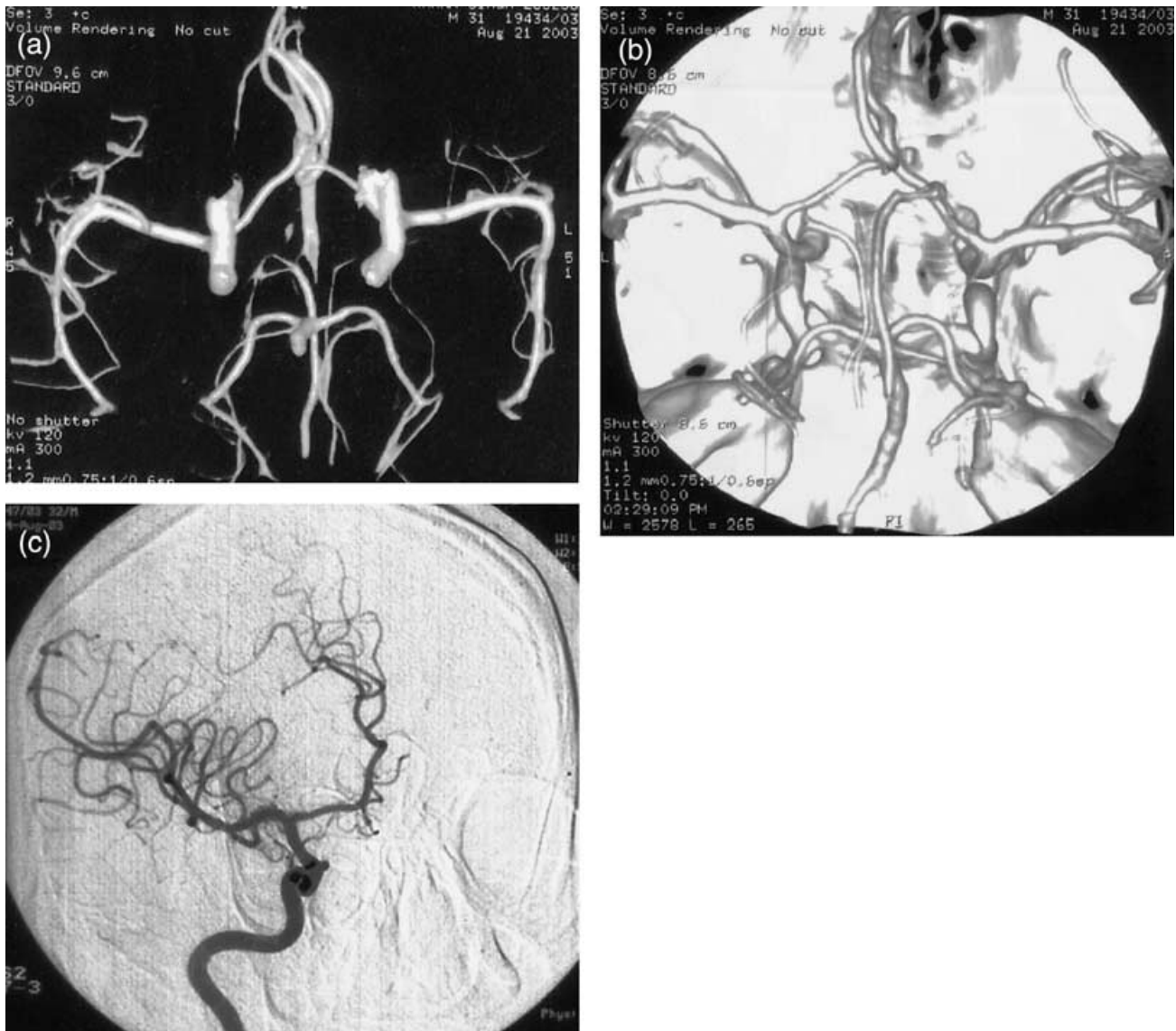


Fig. 3. (a, b) Computed tomography angiogram on follow up showed no evidence of aneurysm or dissection. Note the loop of A₂ segment of the anterior cerebral artery (ACA). (c) Follow-up right carotid digital subtraction angiography showed normal calibre of internal carotid artery and ACA.

This is also counter to the common belief that non-aneurysmal SAH is not usually associated with vasospasm.⁷ To our knowledge, there is a single instance of anterior cerebral artery territory infarct in association with pituitary apoplexy reported by Majchrzak *et al.* In their case, there was displacement of the carotid siphon and the A₁ segment was lifted up with probable subsequent clot formation.⁸

Though vasospasm in pituitary apoplexy with subarachnoid haemorrhage has been described by various authors,^{4,9} the exact pathophysiology is not known. The possible explanations are an irritant effect of subarachnoid blood, hypothalamic damage and, occasionally following pituitary surgery, release of undefined substances from damaged cells.¹⁰ Blood in subarachnoid space is known to be irritating to vessels and may

induce vasospasm as seen in our case. However, it depends on the amount of blood and the rapidity of extravasation into the subarachnoid space after apoplexy. Hypothalamic damage can result from compression by the expanded pituitary mass after apoplexy. Experimental evidence suggests that destruction of lateral hypothalamus might release some spasmogenic factors and facilitate the occurrence of vasospasm.¹⁰ Rarely, vasospasm can occur after pituitary surgery, and possibly humoral factors might be involved in such cases.⁸

Early surgical intervention in patients with pituitary apoplexy with stroke is debatable. It has been observed that there are increased chances of haemorrhage into infarcted or ischemic brain tissue leading to further deterioration.^{11,12} We did not undertake early surgery in our patient because he showed

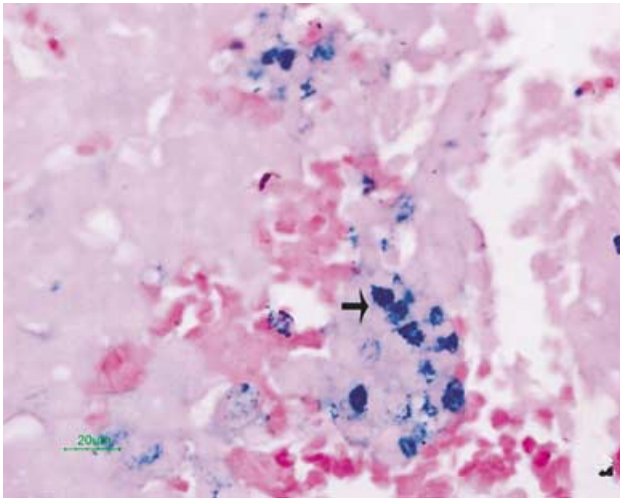


Fig. 4. Prussian blue staining showing blue-coloured haemosiderin granules (arrow) against the background of pituitary adenoma ($\times 440$).

clinical improvement with conservative management. After improvement in his neurological status, he underwent transphenoidal surgery uneventfully. Histopathology of the tumour tissue showed haemosiderin pigment, confirming old haemorrhage.

In conclusion, our patient presented with pituitary apoplexy as the first presenting manifestation of a non-functioning pituitary tumour. He had a frontal lobe syndrome as a result of an anterior cerebral artery infarct consequent to vasospasm caused by a non-aneurysmal SAH.

REFERENCES

- Cardoso ER, Peterson EW. Pituitary apoplexy: A review. *Neurosurgery* 1984; **14**: 363–73.
- Broughman M, Heusner AP, Adams RD. Acute degenerative changes in adenomas of the pituitary body with special reference to pituitary apoplexy. *J Neurosurg* 1950; **7**: 421–39.
- Lath R, Rajshekhar V. Massive cerebral infarction as a feature of pituitary apoplexy. *Neurol India* 2001; **44**: 191–3.
- Cardoso ER, Peterson EW. Pituitary apoplexy and vasospasm. *Surg Neurol* 1983; **20**: 391–5.
- Mukherjee S, Mazumdar A, Dattamunshi AK, Maji D. Ischemic stroke leading to left hemiparesis and autohypophysectomy in a case of pituitary macroadenoma. *J Assoc Physicians India* 1995; **43**: 801–2.
- Wakai S, Fukushima T, Furihata T, Sano K. Association of cerebral aneurysm with pituitary adenoma. *Surg Neurol* 1979; **12**: 503–7.
- Locksley HB, Sahs AL, Sandler R. Report on the cooperative study of intracranial and subarachnoid haemorrhage unrelated to intracranial aneurysm and arteriovenous malformation. A study of associated diseases and prognosis. *J Neurosurg* 1966; **24**: 1034–56.
- Majchrzak H, Wencel T, Dragan T, Bialas J. Acute haemorrhage into pituitary adenoma with SAH and anterior cerebral artery occlusion. *J Neurosurg* 1983; **58**: 771–3.
- Sanno N, Ishli Y, Sugigama M, Takasi R, Node Y, Teramoto A. Subarachnoid haemorrhage and vasospasm due to pituitary apoplexy after pituitary function test. *Acta Neurochir (Wien)* 1999; **141**: 1009–10.
- Shekhar LN, Ahn HS, Canfield D, Martinez J, Zorub DS. The role of the hypothalamus in the etiology of experimental vasospasm. In: Schwartz HG (ed.) *Abstracts from the 50th Meeting of the American Association of Neurological Surgeons*. American Association of Neurological Surgeons, Boston, April 5–9, 1981; 101–2.
- Gonzalez LL, Lewis CM. Cerebral haemorrhage following successful endarterectomy of internal carotid artery. *Surg Gynaecol Obstetrics* 1966; **122**: 773–7.
- Clark JD, Freer CE, Wheatly T. Pituitary apoplexy: An unusual cause of stroke. *Clin Radiol* 1987; **38**: 75–7.