

Pyogenic abscess complicating a resolving cerebral haematoma secondary to a cavernous haemangioma: Computed tomography and magnetic resonance imaging findings

AD Borsaru and P Naidoo

Department of Diagnostic Imaging, Monash Medical Centre, Melbourne, Victoria, Australia

SUMMARY

A case is discussed of a brain abscess complicating an intracerebral haemorrhage occurring in a cavernous haemangioma. A young child presented with focal seizures as a result of a large intracerebral haemorrhage, occurring in a cavernous haemangioma. The only clue to the underlying vascular malformation was the presence of an associated developmental venous anomaly. The case was complicated by the development of a brain abscess at the site of the intracranial haematoma. The CT and MRI findings are discussed.

Key words: *brain abscess; cavernous haemangioma; computed tomography; developmental venous anomaly; magnetic resonance.*

INTRODUCTION

Intracerebral cavernous haemangiomas are defined as well-circumscribed vascular malformations consisting of clusters of endothelial-lined sinusoidal spaces without any normal intervening brain tissue. Histologically, there is a great overlap with other vascular malformations, especially capillary telangiectasia, both representing two extreme forms of cerebral capillary malformations.¹ An association with developmental venous anomalies (DVA), especially venous angiomas, has been described.^{1–6}

Haemorrhage is a common complication of cavernous haemangioma. In 21% of cases, haemorrhage is the first presentation of a cavernous haemangioma. It is also now recognized that intracerebral haemorrhages in patients with DVA are most often secondary to the coexisting cavernous haemangioma. The risk of haemorrhage in a cavernous haemangioma is estimated at 13% per patient per year, or about 0.5–2% per lesion per year. A rare complication of vascular malformations is intracerebral abscess. These are generally associated with

trauma, surgery, or occur in prolonged septic states such as bacterial endocarditis or osteomyelitis.²

Metastatic brain abscesses associated with transient bacteraemia have only rarely been described, but they can occur and should be considered in the differential diagnosis of possible complications of intracerebral haemorrhage. This is a case of a pyogenic abscess complicating an intracerebral haematoma secondary to a cavernous haemangioma.

CASE REPORT

An 18-month-old girl, previously well, presented with a prolonged left focal seizure. Examination revealed an irritable child with mild left-sided weakness, increased tonus, and hyperreflexia, and an upgoing plantar reflex on the left. A contrast-enhanced CT was performed. The CT showed a 2-cm hyperdense nonenhancing lesion in the right frontal lobe with mild surrounding oedema, felt to be consistent with an acute intracerebral haemorrhage (Fig. 1a). Prominent contrast-enhancing vessels were identified close to the haematoma and

AD Borsaru MB BS; P Naidoo FRANZCR.

Correspondence: Dr P Naidoo, Department of Diagnostic Imaging, Monash Medical Centre, 246 Clayton Road, Clayton, Vic. 3168, Australia.

Email: p.naidoo@southernhealth.org.au

Submitted 1 November 2002; accepted 5 March 2003.

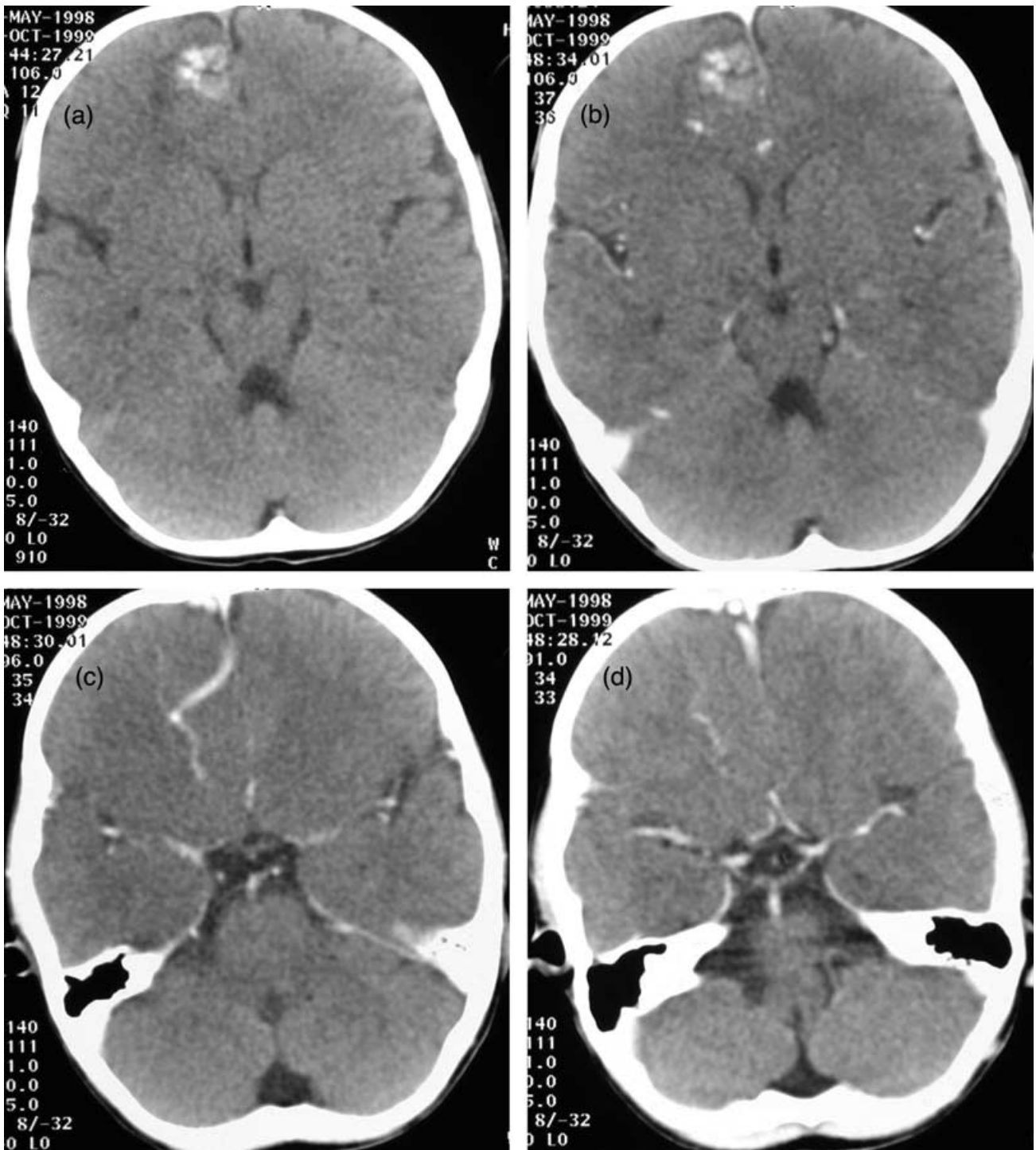


Fig. 1. (a) Axial non-contrast CT scan shows a 2-cm hyperdensity in the right frontal lobe with mild surrounding vasogenic oedema. (b–d) Post-contrast CT scans at the same level and below show enhancing vessels draining to a single large vein anteriorly.

the diagnosis of a small arteriovenous malformation was entertained (Fig. 1b–d). A MRI performed 2 days later confirmed the presence of a subacute haematoma in the right frontal lobe, with an enhancing structure nearby, typical of a DVA (Fig. 2). Given this finding, the diagnosis was revised

to be that of a haemorrhage secondary to a cavernous haemangioma.

The patient was treated conservatively, started on anti-convulsant medication and discharged home a few days later. She remained generally well for the next few weeks with the

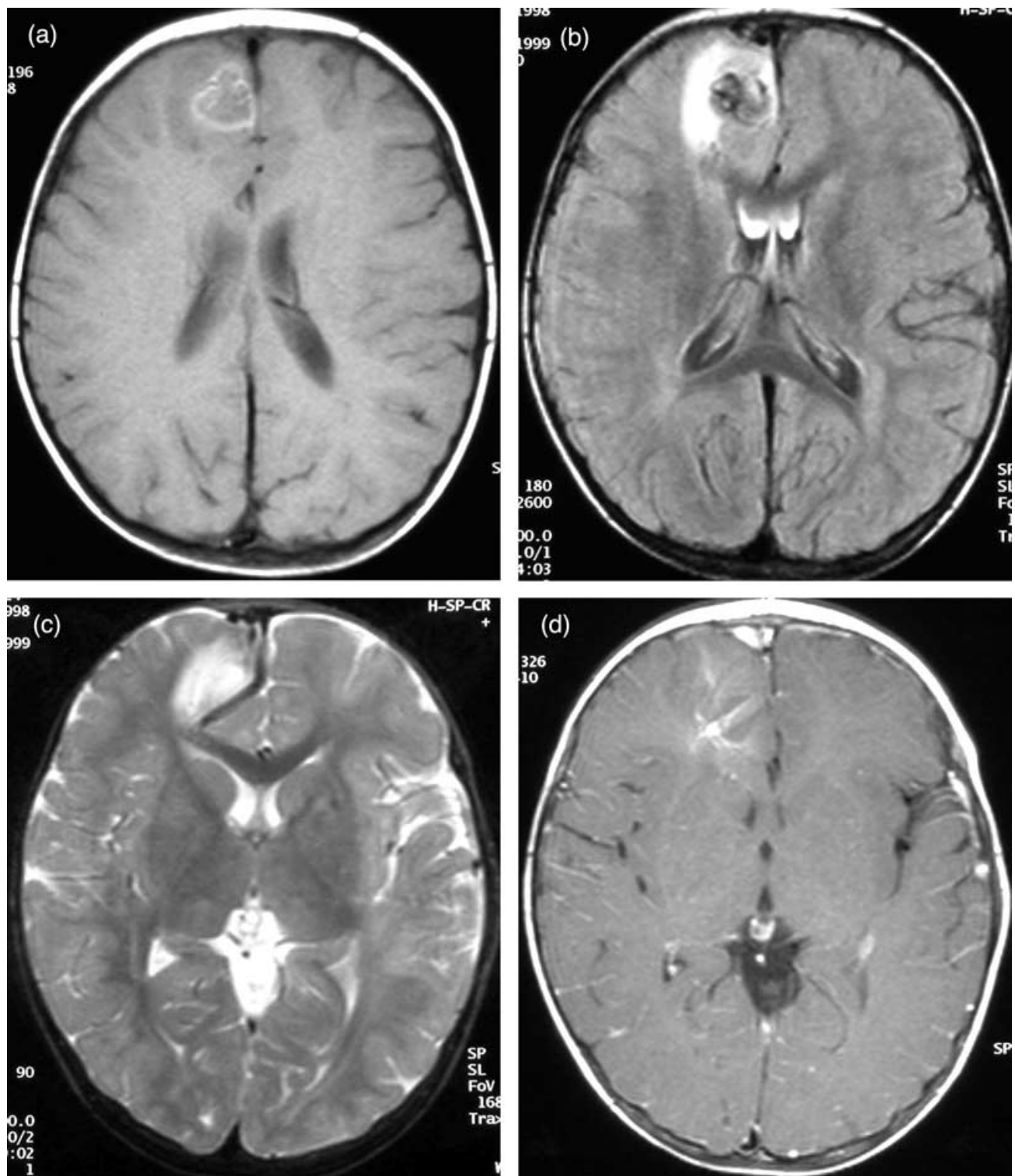


Fig. 2. (a) Axial fast spin echo (FSE) T1-weighted image and (b) axial fluid attenuated inversion recovery image show an early subacute right frontal lobe haematoma with marginal vasogenic oedema. (c) Axial FSE T2-weighted image at a slightly lower level shows a prominent flow void directed to a large draining cortical vein. (d) Axial gadolinium-enhanced FSE T1-weighted image at the level of the lesion shows an enhancing leash of vessels draining to a large vein situated inferior to the haematoma.

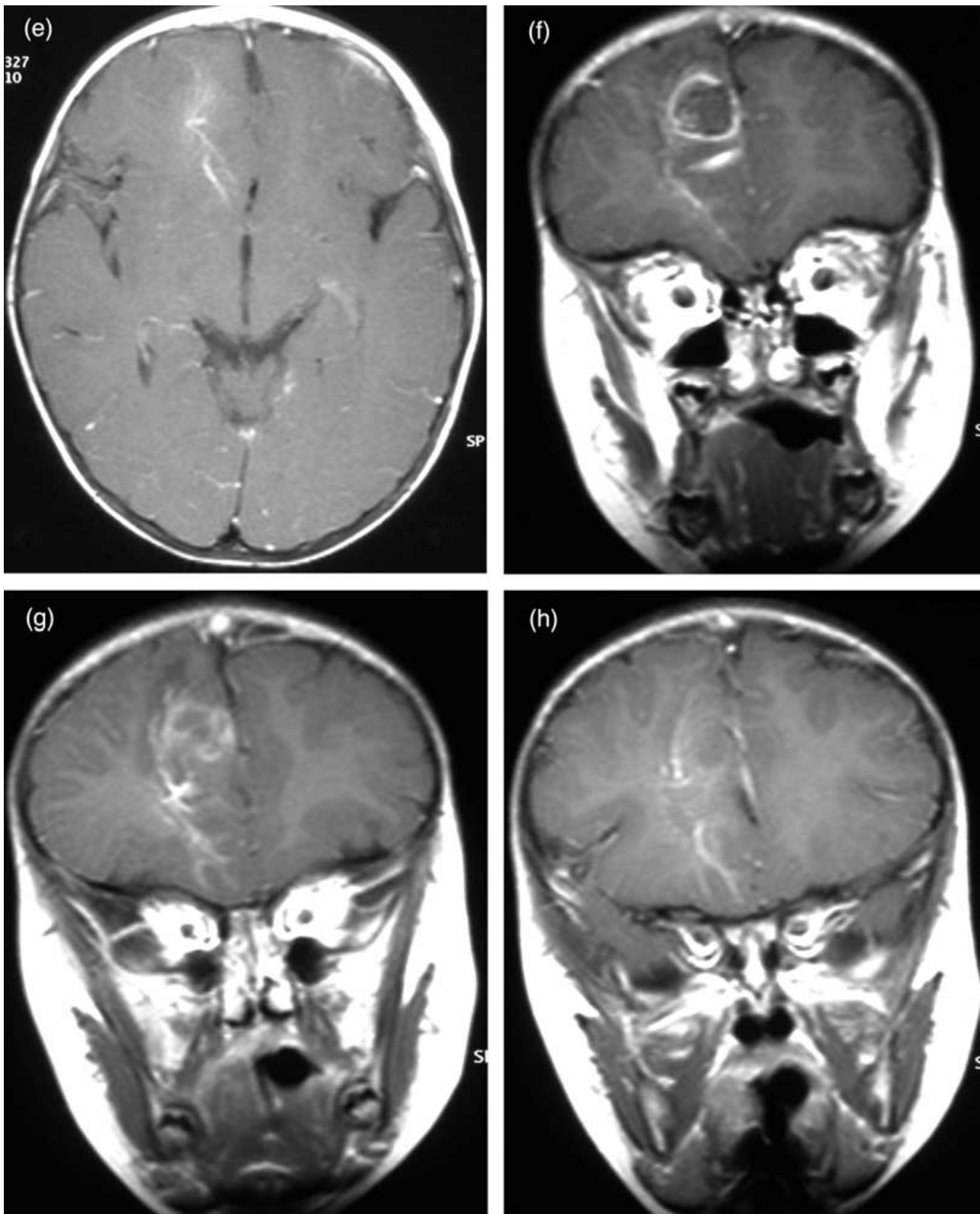


Fig. 2. (e) Axial and (f–h) coronal gadolinium-enhanced FSE T1-weighted images at the level of the lesion show an enhancing leash of vessels draining to a large vein situated inferior to the haematoma.

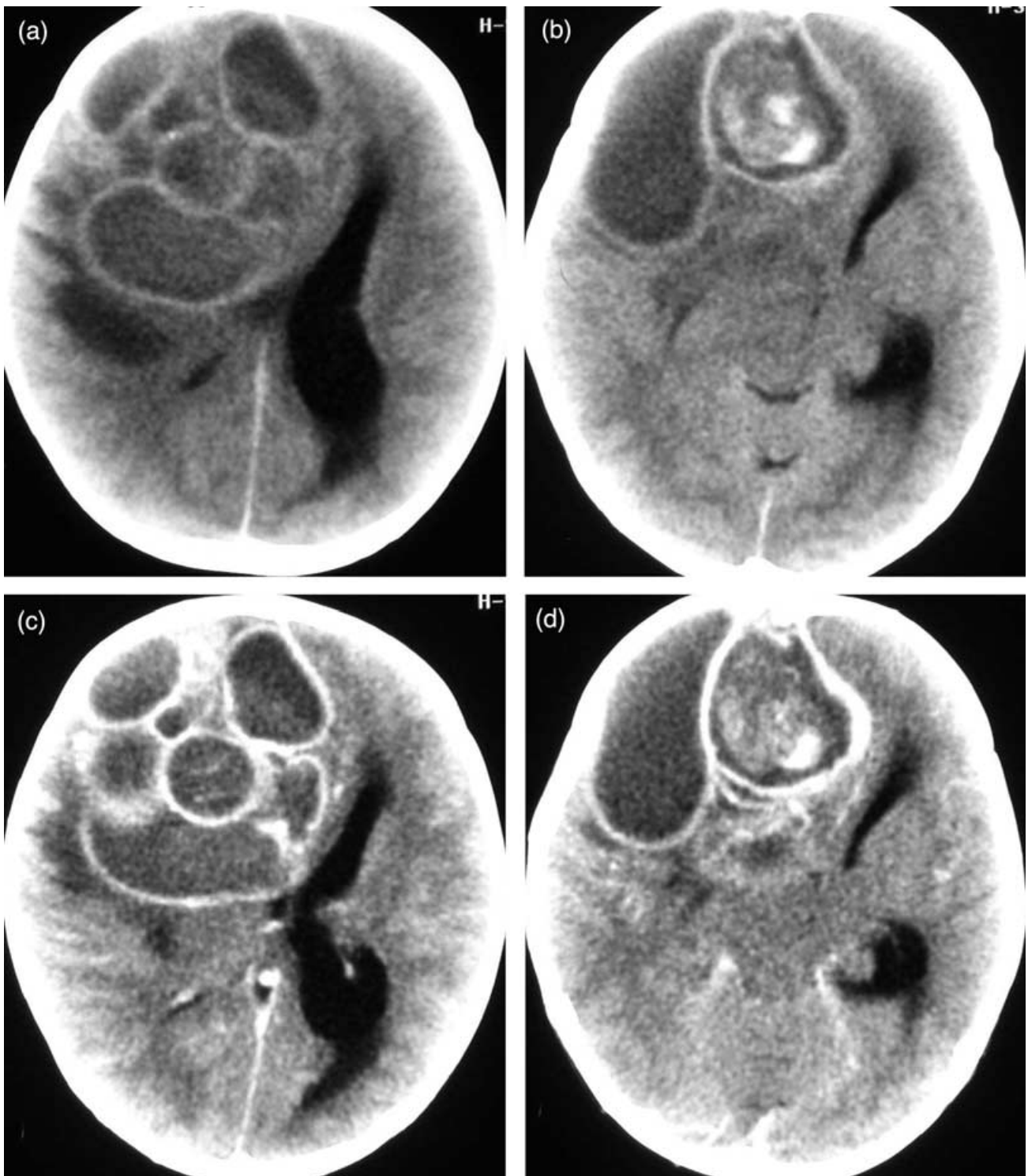


Fig. 3. (a,b) Pre-contrast-enhanced and (c,d) post-contrast-enhanced CT show the presence of a large multiloculated rim-enhancing lesion consistent with a large cerebral haematoma. Residual subacute haemorrhage in one of the cavities, marked surrounding oedema and evidence of impending subfalcine and transtentorial herniation are also present.

exception of short episode of gastroenteritis that was complicated by a *Staphylococcus aureus* bacteraemia.

Over the next few months, the patient presented three times to the emergency department with a febrile illness of unknown

origin, which was associated with increased irritability, poor appetite and drowsiness but no evidence of focal neurological signs. Septic screens performed at each presentation were negative and no clear pathology was detected until her fourth

presentation where she developed a sudden and severe neurological deterioration consisting of prolonged generalized tonic clonic seizures.

The emergency contrast-enhanced CT done at this stage showed a 7 × 7 × 8 cm multiloculated rim-enhancing lesion in the right frontal lobe, with evidence of subacute haemorrhage and marked surrounding vasogenic oedema (Fig. 3). There was significant mass effect associated with this lesion, with subfalcine herniation, contralateral ventricular enlargement and impending transtentorial herniation. An emergency frontal craniotomy and excision of the mass lesion was performed.

The pathology result confirmed the presence of a multiloculated cerebral abscess containing large quantities of *S. aureus*. The presence of groups of ectatic blood vessels confirmed the presence of a pre-existent cavernous haemangioma.

The child was treated with high-dose antibiotics for 6 weeks and made a complete recovery. All focal neurological signs had completely resolved by the time of her 4-week outpatient review.

DISCUSSION

Cavernous haemangiomas are the second most common intracerebral vascular malformation after arteriovenous malformations.¹ They have a suggested incidence of between 0.02 and 0.13% in large autopsy series, but would appear to be even more frequent according to newer studies (up to 0.4% reported in more recent MRI series^{7,8}).

They are classically described as well-defined, multiloculated, berry-like lesions containing blood in various stages of evolution. Histologically, they are clusters of endothelial-lined sinusoidal spaces without any intervening brain tissue. The majority are supratentorial, usually situated at the grey–white matter junction, or in the basal ganglia. Infratentorial lesions occur in 20% of cases. Multiple lesions occur in 20–50% of cases.²

They commonly present between 20 and 40 years of age with seizures, headaches, progressive neurological deficit or haemorrhage. Occult, recurrent haemorrhages are common and characteristic for cavernous haemangiomas. Large, clinically significant haemorrhage is less common, with an estimated risk of 0.5–2.0% per lesion per annum.² An association with DVAs is now well recognized and possibly implicated as a risk factor for haemorrhage.^{1–6} Reciprocally, it is now well recognized that haemorrhagic complications in patients with DVAs are usually secondary to the coexistent cavernous haemangioma. In our case, it was the presence of a typical DVA that suggested the presence of a cavernous haemangioma as a cause for the initial cerebral haemorrhage.

Computed tomography is generally considered a good modality for diagnosing cavernous haemangiomas, although the features can be sometimes non-specific. On non-contrast CT, cavernous haemangiomas appear as iso- or hyperdense

lesions with minimal (if any) surrounding oedema or mass effect. Calcification can also be present. Contrast enhancement is variable.⁹

The MRI appearance is somewhat more characteristic. A definite diagnosis can be made if a strongly contrast-enhancing, well-defined, popcorn-like lesion can be identified. The lesion has usually a heterogeneous core of mixed signal as a result of haemorrhagic residue in different stages of evolution and a hypointense peripheral rim of haemosiderin. The low-signal rim of haemosiderin is typical for the cavernous haemangioma and is responsive for the bloom phenomenon present on gradient echo T2-weighted imaging. Magnetic resonance angiography is invariably negative, but very occasionally a blush can be present in the late capillary phase on catheter angiography.¹⁰

The presence of acute haemorrhage may often obscure the typical features of the cavernous haemangioma.⁹ Persistent abnormalities on further subsequent scans after resolution of the haemorrhage or the presence of an associated DVA may be the only clues to the presence of an underlying cavernous haemangioma. Although haemorrhage alone is a common complication of vascular malformations, cerebral abscess complicating a non-traumatic haematoma is rare. Abscesses are commonly the result of direct seeding (traumatic or iatrogenic), or local extension from an adjacent infective site. Haematogenous spread is rare and usually associated with prolonged episodes of subacute infections such as endocarditis or osteomyelitis, but a few cases associated with short episodes of bacteraemia have been described. The most commonly found pathogens are streptococci and staphylococci. A 1993 study suggested that in the case of staphylococcal bacteraemia, metastatic foci occur in up to 27% of cases.¹¹ It is thought that haematomas may represent areas of impaired immunity and are therefore favourable sites of infection during bacteraemia.^{12,13}

Unfortunately, cerebral abscesses can be very difficult to diagnose clinically. As in previous cases described in the literature, the clinical presentation in our case was non-specific and virtually no neurological signs pointing towards an intracerebral source of infection manifested until very late in the course of the illness. Neurological deterioration was late, severe and very sudden. The definitive diagnosis was made postoperatively by histopathology.^{14–17}

CONCLUSION

Recurrent small intracerebral haemorrhages are well-recognized complications of cavernous haemangiomas, but when large haemorrhages occur they can often obscure the presence of an underlying cavernous haemangioma. The presented case is an example of haemorrhage complicating and obscuring a cavernous haemangioma, where the initial clue to the underlying lesion was the presence of an adjacent DVA. The case further illustrates a rare and, in this case, life-threatening

complication of a pre-existing intracerebral haematoma, namely a cerebral abscess.

REFERENCES

1. Savoiardo M, Strada L, Passerini A. Intracranial cavernous hemangiomas: Neuroradiological review of 36 operated cases. *AJNR* 1983; **3**: 945–50.
2. Sage MR, Blumberg PC. Cavernous haemangiomas (angiomas) of the brain. *Australas Radiol* 2001; **45**: 247–56.
3. Latchlaw RE, Truwit CL, Heros RC. Venous angioma, cavernous angioma and haemorrhage. *AJNR* 1994; **15**: 1255–7.
4. Aksoy FG, Gomori JM, Tuchner Z. Association of intracerebral venous angiomas and true arteriovenous malformation: A rare, distinct entity. *Neuroradiology* 2000; **42**: 455–7.
5. Abe T, Singer J, Marks MP, Norbash A, Crowley RS, Steinberg GK. Coexistence of occult vascular malformations and development venous anomalies in the central nervous system: MR evaluation. *AJNR* 1998; **19**: 51–7.
6. Rigamonti D, Spetzler RF. The association of venous and cavernous malformations: Report of four cases and discussion of the pathophysiological, diagnostic and therapeutic implications. *Acta Neurochir* 1988; **92**: 100–05.
7. Osborn AG. Intracranial vascular malformations. In: Osborn AG. *Diagnostic Neuroradiology*. Mosby, St Louis, 1994; 284–329.
8. Curling OP, Kelly DL, Elster AD, Craven TE. An analysis of the natural history of cavernous haemangiomas. *J Neurosurg* 1991; **75**: 702–8.
9. Ahmadi J, Miller CA, Segall HD, Park SY, Zee C, Becker R. CT patterns in histopathologically complex cavernous hemangiomas. *AJNR* 1985; **6**: 389–93.
10. Duchenne M, Caldas JC, Benoudiba F, Cerri GG, Doyon D. MRI sequences in the detection of cavernous angiomas. *J Radiol* 2002; **83**: 1843–6.
11. Bert F, Maubec E, Gardye C, Branger C, Lambert-Zechovsky N. Staphylococcal brain abscess following hematogenous seeding of an intracerebral haematoma. *Eur J Clin Microbiol Infect Dis* 1995; **14**: 366–7.
12. Biller J, Baker WH, Quinn JP, Shea JF. Intracranial haematoma with subsequent brain abscess after endarterectomy. *Surg Neurol* 1985; **23**: 605–8.
13. Kurihara H, Mitsui T, Kohno N. Brain abscess following intracerebral hematoma. *No Shinkei Geka* 1989; **17**: 1037–40.
14. Dong SL, Reynolds SF, Steiner IP. Brain abscess in patients with hereditary hemorrhagic telangiectasia: Case report and literature review. *J Emerg Med* 2001; **20**: 247–51.
15. Okami N, Kawamata T, Sasahara A, Yamasato M, Kawamura H. Brain abscess following thalamic hemorrhage: a case report. *No Shinkei Geka* 2000; **28**: 275–9.
16. Sumioka S, Kajikawa H, Yamamura K, Furuse M, Kajikawa M. Putaminal abscess occurring at the site of hemorrhage: a case report. *No Shinkei Geka* 1996; **24**: 859–63.
17. Biller J, Adams HP, Godersky JC, Johnson R. Preeclampsia complicated by cerebral haemorrhage and brain abscess. *J Neurol* 1985; **1**: 378–80.