

Gelastic Seizures in a Young Boy: Evaluation by Magnetic Resonance Imaging

Irfan Robbani^a Tariq Ahmed Bhat^b

Departments of ^aRadiodiagnosis and Imaging and ^bGeneral Medicine, Sher-i-Kashmir Institute of Medical Sciences, Srinagar, Kashmir, India

Key Words

Hysteric laughter · Gelastic seizures · Magnetic resonance imaging · Hamartoma · Tuber cinerium · Hypothalamus

Abstract

Objective: To present an interesting case of gelastic seizures in a child who had an underlying brain lesion. **Clinical Presentation and Intervention:** A 10-year-old boy presented with recurrent episodes of uncontrollable laughter since the age of 6 years. Computed tomography showed a well-defined mass in the region of suprasellar and interpeduncular cisterns. Magnetic resonance imaging revealed a lesion, most likely a hamartoma, arising from the region of tuber cinerium. The lesion was subsequently resected and a marked improvement in the frequency and intensity of seizures was noted. **Conclusion:** This report shows that neuroimaging should be performed on patients with gelastic seizures to exclude any underlying structural lesion of causal significance.

Copyright © 2005 S. Karger AG, Basel

Introduction

Gelastic epilepsy or hysteric laughter is characterized by unmotivated or automatic episodes of forced or natural laughter or pressure to laugh that may be associated

with a feeling of mirth. The condition may be idiopathic or associated with hypothalamic or temporal lobe lesions, dysraphic conditions and tumors of the cranial vertex [1–5].

Hypothalamic hamartomas are rare, congenital, non-neoplastic heterotopias that may present early in life with gelastic seizures [1]. Morphologically, they are attached to the posterior hypothalamus between the pituitary stalk and the mamillary bodies, in the region of tuber cinerium [6]. The lesions may be pedunculated or sessile, and their diameter could vary from 2 mm to more than 30 mm [6]. Histologically, these lesions are composed of neural tissue similar to that of the hypothalamus with neurons of variable size supported by normal complement of neuroglia [1].

We report an interesting case of gelastic seizures in a child, evaluated by computed tomography (CT) and magnetic resonance imaging (MRI).

Case Report

A 10-year-old boy presented with a history of uncontrollable laughter since the age of 6 years. These episodes would occur several times a day and each episode would last from several seconds to minutes. Some of these episodes would progress to generalized tonic-clonic seizures. Physical examination revealed normal height and weight for age. There was no evidence of precocious puberty; pubescent development corresponded to Tanner stage I.

A mild degree of behavioral and cognitive impairment with attention-deficit/hyperactivity disorder was observed, associated

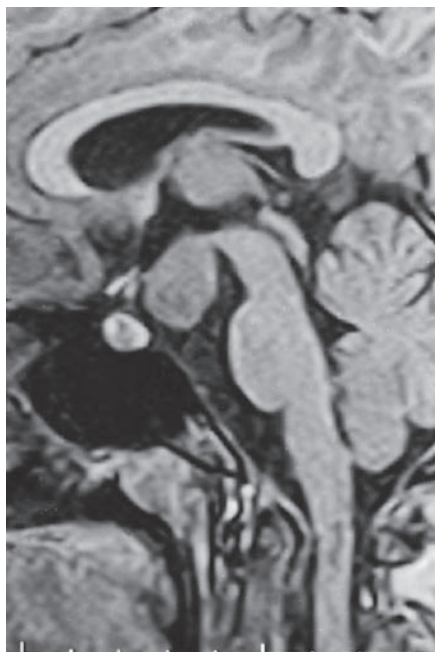


Fig. 1. MRI in sagittal plane (SPGR imaging sequence) showing a well-defined isointense mass in the region of tuber cinerium, distinctly separate from the pituitary gland and infundibular stalk.

with mood changes and learning impairment. Neurologic examination was otherwise normal.

CT scan of the head revealed a well-defined nonenhancing mass in the region of suprasellar and interpeduncular cisterns. The lesion was isodense with brain parenchyma. MRI was performed on a superconducting system operating at 0.5 tesla. T₁-weighted images, 500/20 (TR/TE) and T₂-weighted images, 5,000/75 (TR/TE) were obtained in axial and sagittal planes. In addition, fast FLAIR (fluid-attenuated inversion recovery) images, 460/22 (TR/TE) in coronal plane and thin sliced SPGR (spoiled gradient recall echo) images, 40/10 (TR/TE) in sagittal plane were also obtained.

MRI revealed a well-defined sessile lesion arising from the region of tuber cinerium and located in the interpeduncular cistern, measuring about 28 × 22 × 32 mm in size. The lesion was hyperintense on fast FLAIR and T₂-weighing and isointense on T₁-weighing and SPGR sequences (fig. 1). The mass did not show any appreciable enhancement. The lesion was causing subtle indentation of the third ventricular floor without causing any obstruction to the CSF outflow pathways. The pituitary gland, infundibular stalk and optic chiasm were normal and visibly clearly separate from the lesion. Midbrain and cerebral peduncles were normal.

Electroencephalography showed focal spikes and generalized spike-and-wave discharges. Serum testosterone levels were normal. Luteinizing cell-stimulating hormone test did not reveal any abnormality.

On the basis of clinical evaluation and neuroimaging a confident diagnosis of gelastic seizures secondary to hamartoma of the tuber

cinerium was made. The child was treated with antiepileptics, but showed no improvement. The mass was eventually resected by right temporoparietal craniotomy. On histology, the diagnosis of hamartoma of tuber cinerium was confirmed. Follow-up evaluation revealed a marked improvement in the frequency and intensity of seizures. Only very occasional episodes of brief and mild gelastic seizures were observed postoperatively. A significant improvement in the behavior and school performance of the child was also noted.

Discussion

Patients with hysteric laughter need proper evaluation before such episodes are dismissed as idiopathic or psychogenic. The hypothalamic hamartoma that may present early in life with gelastic seizures is seen on CT as a well-defined, nonenhancing, isodense mass in the interpeduncular cistern. The lesion is characterized by lack of invasiveness and stability in size over time [6]. However, in certain cases CT may fail to differentiate between hamartomas of tuber cinerium and other suprasellar masses in children such as craniopharyngiomas, pituitary adenomas, suprasellar germinomas, and optic chiasm gliomas. Moreover, CT may not be able to detect very small hamartomas [6]. In our patient CT revealed a large, well-defined, nonenhancing, isodense mass in the suprasellar and interpeduncular cisterns; however, the exact site of origin of the tumor could not be ascertained.

MRI has now become the imaging modality of choice in the evaluation of sellar and parasellar lesions. Hamartomas are typically isointense relative to gray matter on T₁-weighted images and hyperintense on T₂-weighted images [1, 6]. The lesions usually do not enhance on intravenous contrast administration. The multiplanar imaging capability of MRI and its superior resolution relative to CT helps in detection of smaller lesions and also in accurate identification and anatomic delineation of larger hamartomas [6]. In our case, MRI provided a confident diagnosis of hamartoma of tuber cinerium, on the basis of typical signal characteristics and exact anatomic mapping of the lesion, which was seen distinctly separate from the pituitary gland, infundibular stalk and the optic chiasm.

Patients with hypothalamic hamartomas have been arbitrarily divided into two clinical groups. The first and more common group presents with features of sexual precocity, presumably due to premature activation of the hypothalamic-pituitary axis [1, 6, 7]. This group is usually associated with pedunculated hamartomas less than 15 mm in diameter [1, 8]. The second group, in which

sexual precocity is absent, could present with seizures and ictal laughter associated with some degree of intellectual impairment [8, 9]. This group usually has sessile hamartomas more than 20 mm in diameter [1, 8]. The cause for ictal laughter may either be mechanical stimulation of the third ventricular floor by the tumor causing epileptic discharge from the hypothalamus, or some type of automatism or release phenomenon [10]. Hyperperfusion in the hypothalamopituitary areas has been reported during ictal ^{99m}Tc-hexamethyl-propyleneamine oxime single photon-emission computed tomography, suggesting that gelastic seizures associated with hypothalamic hamartomas are generated in the hypothalamus or in its neighboring regions [11]. The reason for intellectual impairment in these patients is still unclear, though remarkable im-

provement in the behavioral and cognitive functions is noted after surgical excision [12]. Based on the clinical findings and intervention, our patient belongs to the second group.

Conclusion

This report shows that in patients with gelastic epilepsy, neuroimaging is necessary to exclude the presence of an organic lesion that may be responsible for triggering seizures. MRI can provide exquisite morphological details of the hypothalamopituitary region and can help to confirm or exclude an underlying hamartoma of tuber cinerium with confidence.

References

- 1 Boyko OB, Curnes JT, Oakes WJ, Burger PC: Hamartomas of the tuber cinerium: CT, MR and pathologic findings. *Am J Neuroradiol* 1991;12:309–314.
- 2 Kurle PJ, Sheth RD: Gelastic seizures of neocortical origin confirmed by resective surgery. *J Child Neurol* 2000;15:835–838.
- 3 Coria F, Bahillo ME, Moral BM, Garcia GP, Ortiz S, Desanta MR: Late-onset isolated gelastic epilepsy secondary to entrapment of the right temporal horn. *Neurologia* 2000;15:204–207.
- 4 Sturm JW, Andermann F, Berkovic SF: 'Pressure to laugh': An unusual epileptic symptom associated with small hypothalamic hamartomas. *Neurology* 2000;54:971–973.
- 5 Garcia A, Gutierrez MA, Barrasa J, Herranz JL: Cryptogenic gelastic epilepsy of frontal lobe origin: A paediatric case report. *Seizure* 2000;9:297–300.
- 6 Burton EM, Ball WS Jr, Crone K, Dolan LM: Hamartoma of the tuber cinerium: A comparison of MR and CT findings in four cases. *Am J Neuroradiol* 1989;10:497–501.
- 7 Robben SG, Oostdijk W, Drop SL, Tanghe HL, Vielvoye GJ, Meradji M: Idiopathic isosexual central precocious puberty: Magnetic resonance findings in 30 patients. *Br J Radiol* 1995;68:34–38.
- 8 Hahn FJ, Leibrock LG, Huseman CA, Makos MM: The MR appearance of hypothalamic hamartoma. *Neuroradiology* 1988;30:65–68.
- 9 Frattali CM, Liow K, Craig GH, Korenman LM, Makhoul F, Sato S, Biesecker LG, Theodore WH: Cognitive deficits in children with gelastic seizures and hypothalamic hamartoma. *Neurology* 2001;57:43–46.
- 10 Berkovic SF, Andermann F, Melanson D, Ethier RE, Feindel W, Gloor P: Hypothalamic hamartomas and ictal laughter: Evolution of a characteristic epileptic syndrome and diagnostic value of magnetic resonance imaging. *Ann Neurol* 1988;23:429–439.
- 11 Arroyo S, Santamaria J, Sanmarti F, Lomena F, Catafau A, Casamitjana R, Setoain JF, Tolosa E: Ictal laughter associated with paroxysmal hypothalamopituitary dysfunction. *Epilepsia* 1997;38:114–117.
- 12 Rosenfeld JV, Harvey AS, Wrennall J, Zacharin M, Berkovic SF: Transcallosal resection of hypothalamic hamartomas with control of seizures in children with gelastic epilepsy. *Neurosurgery* 2001;48:108–118.