

SHORT REPORT

Mills' and other isolated upper motor neurone syndromes: in vivo study with ^{11}C -(R)-PK11195 PET

M R Turner, A Gerhard, A Al-Chalabi, C E Shaw, R A C Hughes, R B Banati, D J Brooks, P N Leigh

J Neurol Neurosurg Psychiatry 2005;76:871–874. doi: 10.1136/jnnp.2004.047902

^{11}C -(R)-PK11195 positron emission tomography (PET) was used to explore and delineate in vivo the cortical lesion in three clinically isolated upper motor neurone syndromes of similar presentation, with reference to the syndrome of progressive spastic hemiparesis first described by Mills. Three patients with isolated UMN syndromes underwent ^{11}C -(R)-PK11195 PET of the brain. One patient fulfilled criteria for PLS. Two others had clinical features similar to the cases described by Mills; one of these had a high cervical cord inflammatory lesion previously noted on magnetic resonance imaging. The patient with PLS showed focal increase in the binding of ^{11}C -(R)-PK11195, indicating microglial activation, in the motor cortex contralateral to the predominantly affected limbs. Of the other two patients, one demonstrated marked increases in binding in the superior frontal region (supplementary motor region) contralateral to the affected limbs. In contrast, no focal areas of increased binding were seen in the cerebral cortex of the third patient, who had a high cervical cord lesion and was presumed to have extra-cerebral inflammatory disease. ^{11}C -(R)-PK11195 PET demonstrates in vivo that active pathology may be detectable many years after the onset of symptoms, and that it can occur in disparate sites with clinically similar presentations. We conclude that Mills' syndrome is a purely clinical description that should be reserved for patients with a progressive spastic hemiparesis for which no other explanation can be found.

Primary lateral sclerosis (PLS) is a syndrome of progressive weakness and spasticity associated with selective degeneration of the corticospinal tracts.^{1–3} Typically there are no clinical signs of lower motor neurone involvement, but the disease may still form part of the spectrum of amyotrophic lateral sclerosis (ALS). A rare progressive unilateral upper motor neurone (UMN) syndrome was first described by Mills.⁴

The isoquinoline PK11195 is a selective ligand for the peripheral benzodiazepine receptor expressed by activated microglia. ^{11}C -(R)-PK11195 positron emission tomography (PET) is established as an in vivo marker of cerebral microglial activation.⁵ Such activation may contribute to the neuronal damage in ALS⁶, and there is evidence of cerebral microglial activation in motor pathways and other cortical regions.⁷ ^{11}C -(R)-PK11195 PET was used to study patients with pure UMN syndromes, one fulfilling criteria for PLS, and two with clinical features similar to those described by Mills.

METHODS

Subject details

Three patients underwent ^{11}C -(R)-PK11195 PET. One had PLS according to diagnostic criteria,¹ and two others

presented with unilateral UMN signs, one of whom was known to have a high cervical cord inflammatory lesion but normal cerebral magnetic resonance imaging (MRI). Table 1 summarises the patient characteristics. All gave informed consent and the study was approved by the Administration of Radioactive Substances Advisory Committee (ARSAC) and the ethics committees of the Institute of Psychiatry and the Hammersmith and King's College Hospitals NHS Trusts.

Positron emission tomography

PET was performed with an ECAT 953B PET scanner (CTI/Siemens, Knoxville, TN, USA) operated in three dimensional acquisition mode. At the onset of scanning, 10 mCi of ^{11}C -(R)-PK11195 were injected intravenously over 30 seconds. Dynamic data were collected over 60 minutes as 18 timeframes. A measured attenuation correction was computed with a 15 minute transmission scan obtained in two dimensional mode using an external rotating point source of ^{68}Ge acquired before the emission time frames. Scatter was measured and corrected by use of a dual low energy window method. Data were reconstructed using a ramp filter at Nyquist cut off. Parametric images of ^{11}C -(R)-PK11195 binding potential (BP) were generated with a basis function implementation of a simplified reference tissue model (see Turner *et al*⁷ and Banati⁵). Cluster analysis was used to define a population of voxels in each subject with ligand uptake kinetics similar to those derived from a healthy control population, in order to provide the reference input function (see Banati⁵).

Image assessment

Three dimensional T1 weighted MRIs (1.0 Tesla; Picker HPQ, OH, USA) were obtained and co-registered with the PET volume, using a colour scale to represent the magnitude of the BP (Analyze version 6.0; Biomedical Imaging Resource, Mayo Clinic, Rochester, MN, USA). Constitutive binding of ^{11}C -(R)-PK11195 within the skull bones and air sinuses (seen in previous studies^{7,8}) was removed for clarity via manual editing of the final images. A quantitative region of interest analysis was not performed as we had no a priori assumptions; the aim was to detect major "qualitative" differences between clinically similar phenotypes.

RESULTS

Results are shown in fig 1.

Patient 1 demonstrated increased ^{11}C -(R)-PK11195 BP in the region of the motor cortex (pre-central gyrus), more marked on the left side (contralateral to the predominantly weak side). There was also increased binding in the region of

Abbreviations: ALS, amyotrophic lateral sclerosis; BP, binding potential; CBD, corticobasal degeneration; PET, positron emission tomography; PLS, primary lateral sclerosis; UMN, upper motor neurone

Table 1 Patient characteristics

Variable	Patient 1	Patient 2	Patient 3
Age at presentation	73	60	42
Time from symptom onset to ¹¹ C]-PK11195 PET	3 years	20 years (severe head injury with apparent recovery 39 years prior)	3 years
Site of onset of weakness	RLL, spreading to LLL	RUL & RLL	LLL, spreading to LUL
Bladder/bowel symptoms	None	None	Mild urinary urgency and erectile delay at onset of leg weakness, fully resolved
Sensory symptoms	None	None	None
Cranial nerve examination	Normal	Normal	Normal
Wasting/fasciculation	None	None	None
Tone	Increased RLL > LLL	Increased RUL & RLL	Increased LLL
Power	Pyramidal weakness RLL>LLL	Distal pyramidal weakness RUL & RLL	Mild distal weakness LUL, pyramidal weakness LLL
Reflexes	+++ all limbs; Babinski +ve bilaterally	RUL +++ RUL & RLL; Babinski +ve RLL only	LLL +++ LUL & LLL; Babinski +ve LLL only
Additional history/examination	18 months after current study extrapyramidal features noted RUL (postural tremor, rigidity, bradykinesia, mild apraxia); normal cognition	Hypertensive; normal cognition; no apraxia	None
Previous imaging (at symptom onset, otherwise times from onset given in months or years)	MRI whole spine normal; T2 weighted MRI of head: several small subcortical foci of hyperintensity thought to be microvascular	CT head (2 years): mild cortical atrophy; MRI head (4 and 11 years): two foci altered signal, one left occipital horn lateral ventricle, one frontal lobe; MRI spine (11 years): mild non-compressive degenerative change C3-5; ¹⁸ FDG PET (10 years): generalised cortical hypometabolism	MRI whole spine/brain (1 year): C4 "abnormal signal", ?inflammatory, brain normal; MRI whole spine (1.5 years): C4 focus unchanged, non-compressive degenerative change L5/S1; MRI whole spine (2.5 years): C3 and T1 high intensity foci noted, brain normal; normal chest x ray.
Neurophysiology (at onset, otherwise times from onset given in months or years)	EMG: occasional fasciculations; RLL: no evidence of denervation; VEPs and BAEPs normal; delayed tibial SSEPs	VEPs (onset/10 years): normal; EEG (10 years): normal	EMG: (9 months): normal; repeated (16 months): occasional fasciculations left tibialis, anterior/extensor digitorum brevis; repeated (21 and 30 months): normal; CMCT (16 and 30 months): delayed LUL & LLL, normal on right; no conduction block; SSEPs (27 months): absent from legs, normal from arms; VEP (27 months): delayed on left; BAEP (27 months): normal
Cerebrospinal fluid (at onset)	Protein slightly raised (552 mg/l)	Protein slightly raised (650 mg/l)	Normal protein and ACE on two occasions, no OCBs
Trial of treatment	None	None	IV methylprednisolone: no effect

RUL, right upper limb; RLL, right lower limb; VEP, visual evoked potential; LUL, left upper limb; LLL, left lower limb; BAEP, brainstem evoked potential; MRI, magnetic resonance imaging; FDG, ¹⁸F-2-fluoro-2-deoxyglucose; SSEP, somatosensory evoked potential; EMG, electromyography; EP, evoked potential; CMCT, central motor conduction time; ACE, angiotensin converting enzyme; OCBs, oligoclonal bands; PET, positron emission tomography.

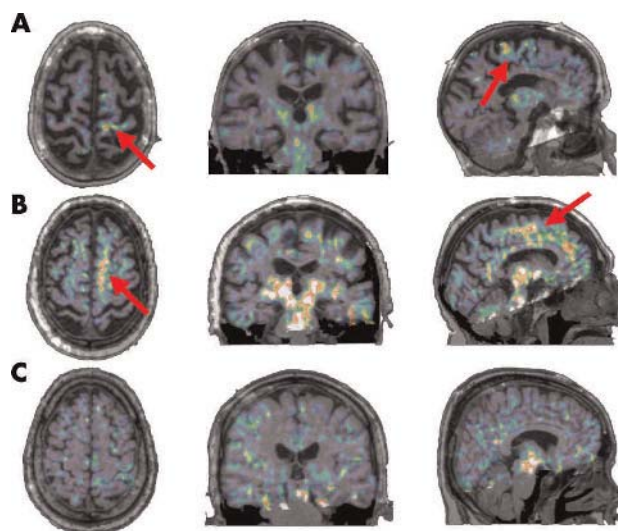


Figure 1 Transverse, coronal, and sagittal co-registered T1 MRI and ¹¹C-(R)-PK11195 PET images for the three cases. The predominant increased signal is within the contralateral motor cortex in patient 1 (A) and the superior frontal region in patient 2 (B) (indicated with arrows). There is no clear area of increased cortical signal in patient 3 (C).

the thalamus and pons bilaterally, and marked, generalised cortical atrophy.

Patient 2 showed a marked area of increased ¹¹C-(R)-PK11195 BP anterior to the pre-central gyrus, in the region of superior frontal lobe and over the medial internal surface of the left hemisphere (supplementary motor area), contralateral to the limbs with the presenting symptoms. The thalamic and pontine signals were similar on both sides, and there was significant generalised cortical atrophy.

Patient 3 showed no focal areas of high ¹¹C-(R)-PK11195 BP within the cortex, and only a small patch of signal in the upper pontine region. The cervical cord was not in the field of view.

DISCUSSION

These three cases all presented clinically with an isolated UMN syndrome, and none would satisfy criteria for ALS.⁹ One patient had bilateral signs and two had a progressive unilateral syndrome as described by Mills.⁴

Patient 3: extracerebral primary pathology

The absence of a significant focal increase in cortical ¹¹C-(R)-PK11195 BP in patient 3, combined with knowledge of a unilateral high cervical spinal cord lesion, strengthens the case that this probably represents an isolated demyelinating syndrome. In a series of patients with clinically definite multiple sclerosis, ¹¹C-(R)-PK11195 PET revealed extensive cerebral microglial activation.¹⁰ There was no evidence of

central white matter microglial activation in this study, although the left visual EP was delayed.

Patients 1 and 2: a primary cortical lesion

Patients 1 and 2 had evidence of a primary cortical lesion, accounting for their signs. This lesion was contralateral to the clinically most affected side in both cases, but in different regions. Microglial activation is found both in the area of primary neuronal damage and in connected brain regions. There is evidence that peripheral lesions can lead to retrograde activation.¹¹ In all three cases, increased uptake was seen in thalamus and pons. In our previous [¹¹C-(R)-PK11195 PET study of ALS patients, the thalamic BP was significantly increased compared with controls.⁷ As this structure has high cortical connectivity (including connectivity with the motor cortex¹²), this finding might well be attributed to retrograde microglial activation, or support a “dying back” axonal degenerative process from below. However, constitutive binding of [¹¹C-(R)-PK11195 within the thalamus and pons in healthy patients has been described in previous studies, and increases with age,^{7,8} so that the interpretation of the increased BP in these structures in this small group study remains cautious.

Patient 1: a true case of PLS?

The development of extrapyramidal features in patient 1 raises the possibility of an alternative diagnosis to PLS, such as corticobasal degeneration (CBD). Pyramidal signs are a feature of CBD,¹³ but the presenting symptom is usually asymmetrical with apraxia and cortical sensory loss, rather than weakness. Furthermore, there was no parietal lobe involvement, which has been described in other imaging studies in CBD.¹⁴ [¹¹C-(R)-PK11195 PET studies in CBD have demonstrated microglial activation in the pre-central gyrus but with consistently greater activation seen in the basal ganglia than here.¹⁵ Extrapyramidal involvement has been described in cases of ALS¹⁶ and in a case of PLS.¹⁷

An ascending pattern of weakness has been suggested as the unifying factor in cases of PLS,¹⁸ but that criterion alone would apply to all of our patients. The notion that the pathological process in PLS is located primarily in the motor cortex was supported by one clinicopathological study,² and the strikingly increased focal [¹¹C-(R)-PK11195 BP in the pre-central gyrus of patient 1 supports this. Such a focus was not consistently visible in our ALS study, although overall group comparison with controls showed a clear increase,⁷ possibly reflecting clinical heterogeneity. However, although diffusion tensor imaging demonstrated a significant decrease in fractional anisotropy within the internal capsule in PLS patients compared to controls, this was also less distinct in ALS.^{19,20}

A transcranial magnetic stimulation study supported the notion that the cortical lesion in PLS is different to that in ALS.²¹ Increased cortical atrophy has been noted in PLS compared to ALS cases,²² and it is widespread, progressing over time.²³ Both patients 1 and 2 demonstrated significant generalised cortical atrophy in the absence of cognitive impairment, but as they were also relatively elderly, this is of uncertain significance. The balance of presentation and results from this study supports a diagnosis of PLS in patient 1, but the development of mild extrapyramidal features remains unexplained.

Mills' syndrome: a descriptive clinical term only

The histories of the first of two Mills' syndrome cases described by Gastaut and Bartolomei²⁴ are remarkably similar to that of patient 3 in this study. Common themes emerge in this review, with the majority demonstrating an ascending pattern of weakness (as in this study), and many with

bilateral pyramidal signs. The postmortem findings in one of Mills' original cases even described lesions at the level of the brainstem and spinal cord, sparing the motor cortex (as in patient 3).²⁵

Patient 2 provides evidence for a distinct cortical process, implicating supplementary motor regions. The area of increased signal encompasses the cortical territory supplied by the anterior cerebral artery, raising the possibility of a vascular aetiology. Two foci of altered signal on MRI had been noted in the past, possibly representing lacunar infarcts, but only one was in the frontal lobe. The extent of increase in PET signal, and the gradual and progressive nature of the symptoms, makes a single vascular event an unlikely explanation. The possibility of the identified abnormalities being a chronic response to head injury cannot be entirely excluded.

CONCLUSION

Disparate sites of pathology can be associated with isolated progressive unilateral UMN syndromes, and “Mills' syndrome” is thus only a descriptive clinical term. [¹¹C-(R)-PK11195 PET has the potential to delineate similar clinical phenotypes in vivo, and activated microglia may be detectable many years after the onset of symptoms.

ACKNOWLEDGEMENTS

M R Turner is supported by a Wellcome Trust Clinical Research Fellowship. The King's MND Care & Research Centre (M R Turner, A Al-Chalabi, C E Shaw, P N Leigh) receives support from the Motor Neurone Disease Association (UK). A Al-Chalabi is an MRC Clinician Scientist. D J Brooks receives support from the MRC. We are indebted to the patients for their participation in this project. Thanks also to the radiographer A Blyth and PET technician L Scnorr.

Authors' affiliations

M R Turner, A Al-Chalabi, P N Leigh, Department of Neurology, Institute of Psychiatry, King's College London, UK

A Gerhard, D J Brooks, MRC Clinical Sciences Centre and Division of Neuroscience, Faculty of Medicine, Imperial College, Hammersmith Hospital, London, UK

C E Shaw, R A C Hughes, Guy's, King's & St. Thomas's School of Medicine, London, UK

R B Banati, Faculty of Health Sciences, University of Sydney, Australia

D J Brooks, Institute of Neurology, London, UK

Competing interests: There are no competing interests to declare.

Correspondence to: Dr M Turner, PO Box 41 (ANC), Institute of Psychiatry, De Crespigny Park, London SE5 8AF; m.turner@iop.kcl.ac.uk

Received 17 June 2004

Revised version received 17 August 2004

Accepted 21 September 2004

REFERENCES

- 1 Pringle CE, Hudson AJ, Munoz DG, et al. Primary lateral sclerosis. Clinical features, neuropathology and diagnostic criteria. *Brain* 1992;**115**:495–520.
- 2 Hudson AJ, Kiernan JA, Munoz DG, et al. Clinicopathological features of primary lateral sclerosis are different from amyotrophic lateral sclerosis. *Brain Res Bull* 1993;**30**:359–64.
- 3 Le Forestier N, Maisonobe T, Piquard A, et al. Does primary lateral sclerosis exist? A study of 20 patients and a review of the literature. *Brain* 2001;**124**:1989–99.
- 4 Mills CK. A case of unilateral progressive ascending paralysis, probably representing a new form of degenerative disease. *J Nerv Ment Dis* 1900;**27**:195–200.
- 5 Banati RB. Visualising microglial activation in vivo. *Glia* 2002;**40**:206–17.
- 6 McGeer PL, McGeer EG. Inflammatory processes in amyotrophic lateral sclerosis. *Muscle Nerve* 2002;**26**:459–70.
- 7 Turner MR, Cagnin A, Turkheimer FE, et al. Evidence of widespread cerebral microglial activation in amyotrophic lateral sclerosis: an [(11)C](R)-PK11195 positron emission tomography study. *Neurobiol Dis* 2004;**15**:601–9.
- 8 Cagnin A, Brooks DJ, Kennedy AM, et al. In-vivo measurement of activated microglia in dementia. *Lancet* 2001;**358**:461–7.

- 9 **Brooks BR**, Miller RG, Swash M, *et al*. El Escorial revisited: revised criteria for the diagnosis of amyotrophic lateral sclerosis. *Amyotroph Lateral Scler Other Motor Neuron Disord* 2000;**1**:293–9.
- 10 **Banati RB**, Newcombe J, Gunn RN, *et al*. The peripheral benzodiazepine binding site in the brain in multiple sclerosis: Quantitative in vivo imaging of microglia as a measure of disease activity. *Brain* 2000;**123**:2321–37.
- 11 **Banati RB**, Cagnin A, Brooks DJ, *et al*. Long-term trans-synaptic glial responses in the human thalamus after peripheral nerve injury. *Neuroreport* 2001;**12**:3439–42.
- 12 **Behrens TE**, Johansen-Berg H, Woolrich MW, *et al*. Non-invasive mapping of connections between human thalamus and cortex using diffusion imaging. *Nat Neurosci* 2003;**6**:750–7.
- 13 **Riley DE**, Lang AE. *Clinical diagnostic criteria. Corticobasal degeneration*. Philadelphia: Lippincott, Williams and Wilkins, 2000:29–34.
- 14 **Ukmar M**, Moretti R, Torre P, *et al*. Corticobasal degeneration: structural and functional MRI and single-photon emission computed tomography. *Neuroradiology* 2003;**45**:708–12.
- 15 **Gerhard A**, Watts J, Trender-Gerhard I, *et al*. In vivo imaging of microglial activation with [¹¹C](R)-PK11195 in corticobasal degeneration. *Mov Disord* 2004;**19**:1221–6.
- 16 **Desai J**, Swash M. Extrapyramidal involvement in amyotrophic lateral sclerosis: backward falls and retropulsion. *J Neural Neurosurg Psychiatry* 1999;**67**:214–16.
- 17 **Mochizuki A**, Komatsuzaki Y, Iwamoto H, *et al*. Frontotemporal dementia with ubiquitinated neuronal inclusions presenting with primary lateral sclerosis and parkinsonism: clinicopathological report of an autopsy case. *Acta Neuropathol (Berl)* 2004;**107**:377–80.
- 18 **Zhai P**, Pagan F, Statland J, *et al*. Primary lateral sclerosis: A heterogeneous disorder composed of different subtypes? *Neurology* 2003;**60**:1258–65.
- 19 **Ellis CM**, Simmons A, Jones DK, *et al*. Diffusion tensor MRI assesses corticospinal tract damage in ALS. *Neurology* 1999;**53**:1051–8.
- 20 **Ulug AM**, Grunewald T, Lin MT, *et al*. Diffusion tensor imaging in the diagnosis of primary lateral sclerosis. *J Magn Reson Imaging* 2004;**19**:34–9.
- 21 **Weber M**, Stewart H, Hirota N, *et al*. Corticomotoneuronal connections in primary lateral sclerosis (PLS). *Amyotroph Lateral Scler Other Motor Neuron Disord* 2002;**3**:190–8.
- 22 **Kuipers-Upmeyer J**, de Jager AE, Hew JM, *et al*. Primary lateral sclerosis: clinical, neurophysiological, and magnetic resonance findings. *J Neural Neurosurg Psychiatry* 2001;**71**:615–20.
- 23 **Smith CD**. Serial MRI findings in a case of primary lateral sclerosis. *Neurology* 2002;**58**:647–9.
- 24 **Gastaut JL**, Bartolomei F. Mills' syndrome: ascending (or descending) progressive hemiplegia: a hemiplegic form of primary lateral sclerosis? *J Neural Neurosurg Psychiatry* 1994;**57**:1280–1.
- 25 **Mills CK**, Spiller WG. A case of progressively developing hemiplegia later becoming triplegia resulting from primary degeneration of the pyramidal tracts. *J Nerv Ment Dis* 1903;**30**:385–97.

bmjupdates+

bmjupdates+ is a unique and free alerting service, designed to keep you up to date with the medical literature that is truly important to your practice.

bmjupdates+ will alert you to important new research and will provide you with the best new evidence concerning important advances in health care, tailored to your medical interests and time demands.

Where does the information come from?

bmjupdates+ applies an expert critical appraisal filter to over 100 top medical journals. A panel of over 2000 physicians find the few 'must read' studies for each area of clinical interest.

Sign up to receive your tailored email alerts, searching access and more...

www.bmjupdates.com