

Case Reports

Thrombolytic Therapy for Acute Stroke in Late Pregnancy With Intra-Arterial Recombinant Tissue Plasminogen Activator

David M. Johnson, MD; David C. Kramer, MD; Ezra Cohen, MD; Meredith Rochon, MD; Mara Rosner, MD; Jesse Weinberger, MD

Background and Purpose—The most common presentation of ischemic stroke related to pregnancy is arterial occlusion, occurring during the third trimester or postpartum. The authors present the first successful administration of intra-arterial cerebral tissue plasminogen activator to treat an embolic cerebral vascular accident in a 37-week parturient resulting in complete recovery of neurological function.

Methods—The patient presented with left hemiplegia, left-sided neglect, and aphasia. Right internal carotid artery cerebral angiogram showed occlusion of the mid-M1 segment of the middle cerebral artery (MCA). After 15 mg of tissue plasminogen activator was administered via intra-arterial route, there was greatly improved retrograde flow through the posterior communication artery and the MCA territory.

Results—A reduction in size of the MCA occlusion was noted with improvement of antegrade flow through the MCA. Three days after the procedure, the patient was induced successfully and delivered a healthy infant vaginally.

Conclusion—This report describes the use of intra-arterial tissue plasminogen activator in the setting of stroke in late pregnancy. (*Stroke*. 2005;36:e53-e55.)

Key Words: cerebral angiography ■ cerebral infarction ■ thrombolytic therapy ■ tissue plasminogen activator

The most common presentation of ischemic stroke related to pregnancy is arterial occlusion during the third trimester and postpartum.¹ Although arterial occlusive stroke associated with pregnancy is rare (3.5 to 10.7 per 100 000 deliveries), it may result in devastating morbidity.² Pregnancy is a prothrombotic state. The higher incidence of ischemic stroke during pregnancy¹ and immediately postpartum³ may be attributed to increased serum levels of prothrombin factors V, VIII, IX, X, and XI and decreased serum protein S.⁴

Recombinant tissue plasminogen activator (rtPA) has been used in myocardial infarction, pulmonary emboli, sagittal vein thrombosis, and stroke. Patients treated within 3 hours of a stroke with intravenous rtPA are 30% more likely to have minimal or no disability at 1 year after the event.⁵ TPA has been avoided in late pregnancy out of concern for maternal and fetus complications.⁶ It is a category C drug, and pregnancy is usually an exclusion criterion in studies using rtPA. Nevertheless, there are case reports of the use of intravenous rtPA to treat myocardial infarction,⁷ massive pulmonary emboli,^{8–12} and superior vena cava syndrome,¹³ and for the treatment of thrombosed valve prosthesis¹⁴ during pregnancy, as well as 2 reported cases of rtPA for the treatment of ischemic stroke in early pregnancy.^{15,16} There

are no clinical reports of its use in stroke during late pregnancy. Here we report the successful use of intra-arterial tPA for ischemic stroke in late pregnancy.

Case Report

The patient, a 39-year-old multipara at 37 weeks gestation presented with 40 minutes of decreased responsiveness and inability to move her left side. She had a history of chronic hypertension and was not prescribed antihypertensive medications. Her blood pressure was 200/100 and heart rate was 70 bpm. National Institutes of Health Stroke Scale (NIHSS) score at presentation was 20. Examination revealed left hemiplegia, left homonymous hemianopsia with left-sided neglect, dysarthria, and left facial droop.

Nonenhanced computed tomography of the brain revealed no hemorrhage. A 6 French femoral sheath was placed, and 4000 U of heparin was administered. Right internal carotid artery cerebral angiogram showed abrupt occlusion of the mid-M1 segment of the middle cerebral artery (MCA; Figure 1). Capillary and venous phases showed delayed retrograde filling of the superior and inferior M2 branches from leptomeningeal collaterals from the anterior cerebral artery. The M1 site of occlusion was crossed with a Prowler 10 micro-

Received March 15, 2005; accepted March 16, 2005.

From the Departments of Neurosurgery, Radiology, Anesthesiology, Neurology, Obstetrics, Gynecology, and Reproductive Science, Mount Sinai Medical Center, New York, NY.

Correspondence to David C. Kramer, Mount Sinai Medical Center, 1 Gustave L. Levy Place, Box 1136, New York, NY 10029-6574. E-mail dkrame01@msnyuhealth.org

© 2005 American Heart Association, Inc.

Stroke is available at <http://www.strokeaha.org>

DOI: 10.1161/01.STR.0000166203.27135.27

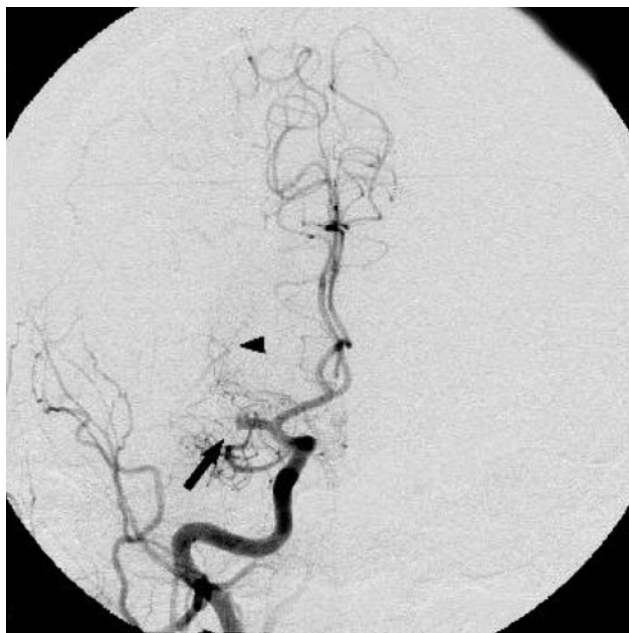


Figure 1. Angiogram, Right internal carotid artery (ICA) arterial phase. Posterior anterior, Right ICA angiogram shows complete occlusion of the mid-M1 segment (arrow). Several lenticulostriate arteries are seen (arrowhead).

catheter (Cordis Neurovascular) over an Agility 10 wire (Cordis Neurovascular). Five hours after the symptom onset, rtPA was administered. The distal MCA was laced with 2 mg rtPA. The catheter was then withdrawn into the thrombus, and 1 mg was administered. The catheter tip was positioned proximal to the occlusion, and an additional 1 mg was administered over 3 minutes.

After the first 4 mg rtPA, there was flow in a previously occluded posterior communicating artery, with improved collateral filling of the distal MCA branches, specifically from posterior cerebral artery collaterals. Minimal improvement was noted in the antegrade flow in the M2 branches. After 10 mg had been given, the patient was moving her left arm and leg spontaneously. When compared with flow after 4 mg of rtPA administration, no significant change in the occlusion of the M1 segment was noted after 10 mg and 15 mg (Figure 2). Multiple attempts at recrossing the M1 occlusion were unsuccessful, and the procedure was terminated. She was then transferred to the neurological intensive care unit.

At 9 hours after onset of symptoms, the patient's NIHSS score was 7. Neurological examination revealed fluent speech and mild left facial paralysis, with 4 of 5 strength on the left side, and the patient was able to follow all commands. The homonymous hemianopsia had resolved, and the patient had trace inattention to the left side.

Work-up investigating the etiology of the embolic event was noncontributory. The free protein S level was 11 mg/dL (normal 60 to 140 mg/dL), and total protein S level was 73 (normal 70 to 140 mg/dL). Six weeks after the event, the free protein S was 100 mg/dL.

The patient was induced on day 3, and a healthy male infant was delivered by forceps-assisted vaginal delivery

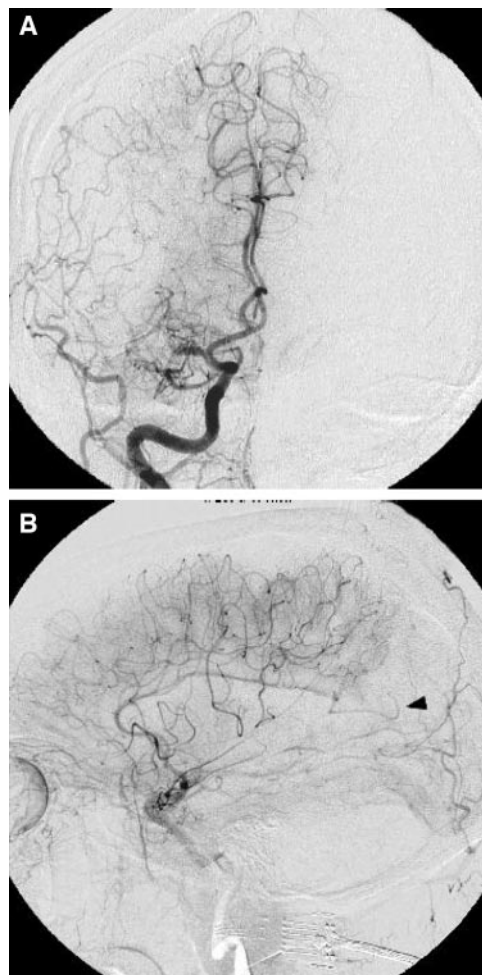


Figure 2. a and b, Angiogram. Right internal carotid artery (ICA) after 15 mg rtPA. Posterior anterior (a) and lateral (b) right ICA angiogram shows improved flow to the middle cerebral artery, with filling from posterior cerebral artery (arrowhead).

under epidural anesthesia. The patient was discharged on low-molecular weight heparin, with minimal facial and left-sided weakness. At 2-month follow-up, the child was doing well without sequelae, and the mother was neurologically normal without residual deficits.

Discussion

The clinical use of thrombolysis during pregnancy is not without consequences. Thrombolysis with streptokinase in pregnant women has an incidence of maternal death at 1.2%, maternal hemorrhage at 8.1%, and 5.8% incidence of fetal death.⁶

Despite these concerns, relatively good maternal outcomes have been reported after the use of rtPA for acute myocardial infarction (1 patient),⁷ pulmonary emboli (8 patients),⁸⁻¹² stroke (2 patients),^{15,16} prosthetic valve thrombosis (9 patients),¹⁴ deep venous thrombosis (1 patient),¹⁷ and superior vena cava syndrome (1 patient; Genentech, Inc., personal written communications, 2005). Complications included placental hematoma and uterine bleeding, as well as 1 case each of spontaneous abortion and intrauterine fetal death (Genentech, Inc., personal written communications, 2005).

There have been 2 reports of rtPA use for acute ischemic stroke during the first trimester of pregnancy.^{15,16} In 1 report, using intravenous rtPA, the mother's neurological status initially deteriorated;¹⁶ in the other, using arterial rtPA, maternal neurological status markedly improved.¹⁵ Both women delivered healthy infants.

This report is the first use of rtPA for treatment of stroke in late pregnancy. Thrombolysis with intra-arterial rtPA may prove to be a therapeutic alternative to conservative medical management for the treatment of stroke in late pregnancy.

References

1. Jaigobin C, Silver FL. Stroke and pregnancy. *Stroke*. 2000;31:2948–2951.
2. Rochat RW, Koonin LM, Atrash HK, Jewett JF. Maternal mortality in the United States: report from the Maternal Mortality Collaborative. *Obstet Gynecol*. 1988;72:91–97.
3. Kittner SJ, Stern BJ, Feeser BR. Pregnancy and the risk of stroke. *N Engl J Med*. 1996;335:768–774.
4. O'Riordan MN, Higgins JR. Haemostasis in normal and abnormal pregnancy. *Best Pract Res Clin Obstet Gynaecol*. 2003;17:385–396.
5. Kwiatkowski TG, Libman RB, Frankel M, Tilley BC, Morgenstern LB, Lu M, Broderick JP, Lewandowski CA, Marler JR, Levine SR, Brott T. Effects of tissue plasminogen activator for acute ischemic stroke at one year. *N Engl J Med*. 1999;340:1781–1787.
6. Turrentine MA, Braems G, Ramirez MM. Use of thrombolytics for the treatment of thromboembolic disease during pregnancy. *Obstet Gynecol Surv*. 1995;50:534–541.
7. Schumacher B, Belfort MA, Card RJ. Successful treatment of acute myocardial infarction during pregnancy with tissue plasminogen activator. *Am J Obstet Gynecol*. 1997;176:716–719.
8. Patel RK, Fasan O, Arya R. Thrombolysis in pregnancy. *Thromb Haemost*. 2003;90:1216–1217.
9. Ahearn GS, Hadjiliadis D, Govert JA, Tapson VF. Massive pulmonary embolism during pregnancy successfully treated with recombinant tissue plasminogen activator: a case report and review of treatment options. *Arch Intern Med*. 2002;162:1221–1227.
10. Behrendt P, Schwartzkofpp B, Perings S, Gerhardt A, Zotz RB, Strauer BE. Successful thrombolysis of St. Jude medical aortic prosthesis with tissue-type plasminogen activator in a pregnant woman: a case report. *Cardiol Rev*. 2002;10:349–353.
11. Nanas JN, Kontoyannis SA, Mitsibounas DN, Stamatiopoulos SF. Thrombolytic treatment for thrombosis of a mitral valve prosthesis during pregnancy. *Intensive Care Med*. 2001;27:1668–1669.
12. Aya AG, Saissi G, Eledjam JJ. In situ pulmonary thrombolysis using recombinant tissue plasminogen activator after cesarean delivery. *Anesthesiology*. 1999;91:578–579.
13. Barclay GR, Allen K, Pennington CR. Tissue plasminogen activator in the treatment of superior vena caval thrombosis associated with parenteral nutrition. *Postgrad Med J*. 1990;66:398–400.
14. Nassar AH, Abdallah ME, Moukarbel GV, Usta IM, Gharzuddine WS. Sequential use of thrombosed mitral prosthesis during pregnancy. *J Perinat Med*. 2003;31:257–260.
15. Daprich M, and Boessenecker W. Fibrinolysis with alteplase in a pregnant woman with stroke. *Cerebrovasc Dis*. 2002;13:290.
16. Elford K, Leader A, Wee R, Stys PK. Stroke in ovarian hyperstimulation syndrome in early pregnancy treated with intra-arterial rt-PA. *Neurology*. 2002;59:1270–1272.
17. Grand A, Ghadban W, Perret SP, Saboul R, Mosnier S, Douieb A, Fichter P, Huret JF. Iliofemoral venous thrombosis treated by tissue plasminogen activator in a pregnant woman. *Ann Cardiol Angeiol (Paris)*. 1996;9:517–522.