

Rescue Revascularization Therapy With a Stent-in-Stent Technique for Acute Intracranial Internal Carotid Artery Occlusion

—Case Report—

Toshiyuki OKAZAKI, Junichiro SATOMI, Koichi SATOH, Motohiro HIRASAWA,
and Shinji NAGAIRO

Department of Neurosurgery, School of Medicine, The University of Tokushima, Tokushima

Abstract

A 45-year-old woman presented with progressive stroke due to occlusion of the left internal carotid artery at the level of the cavernous portion (C₃/C₄). Revascularization was achieved by stent deployment following percutaneous transluminal angioplasty. Stent thrombosis occurred 7 days after primary stenting; it was successfully treated with the stent-in-stent technique. The patient was able to return to her independent life with no sequelae except for slight hemiparesis. In combination with appropriate antiplatelet treatment, the stent-in-stent technique should be considered as a rescue option in patients with re-occlusion of an intracranial stent.

Key words: acute internal carotid artery occlusion, intracranial stenting, stent-in-stent technique

Introduction

Interventional revascularization of acute major intracranial artery occlusions is rarely performed in patients with atherosclerotic lesions and several problems remain with respect to angioplasty and stent deployment in intracranial vessels.^{1,10,13,18)} On the other hand, in coronary intervention, angioplasty and stent deployment are often used and over 20 types of stents are currently available. In patients with acute coronary syndrome, stent placement combined with anti-platelet drug therapy contributes to safe revascularization without hemorrhagic complications or subacute coronary artery re-occlusion.^{2,6,16)}

We report a patient with intracranial internal carotid artery (ICA) occlusion who underwent successful revascularization with intracranial stent deployment in the acute stage, followed, in the subacute stage, by stent-in-stent deployment for re-occlusion of the ICA due to stent thrombosis.

Case Presentation

This 45-year-old woman with a history of diabetes mellitus, hypertension, and habitual alcohol consumption presented with difficulty in walking and numbness on the right. On admission, neurological examination revealed slight hemiparesis and paresthesia on the right. Magnetic resonance (MR) imaging demonstrated mismatched hemodynamic compromise as small infarcted areas on diffusion-weighted MR images; on T₂-weighted MR images there was a large misery perfusion area. MR angiography showed occlusion of the left ICA; the left middle cerebral artery was faintly visualized (Fig. 1).

Despite medical treatment, she suffered progressive stroke manifesting as expressive dysphasia and progressive weakness in addition to the pre-existing symptoms. Cerebral angiography demonstrated occlusion of the left ICA at the level of the cavernous portion (C₃/C₄). Recanalization was achieved by 20-second percutaneous transluminal angioplasty

Received April 21, 2004; Accepted November 22, 2004

Author's present address: J. Satomi, M.D., Department of Surgical Neurology, Research Institute for Brain and Blood Vessels-AKITA, Akita, Japan.

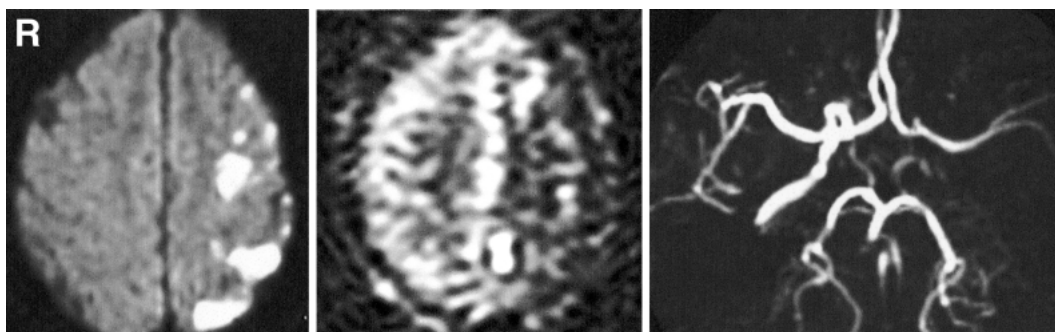


Fig. 1 *left*: Diffusion-weighted magnetic resonance (MR) image obtained at admission demonstrates high-intensity foci in the left frontoparietal cortex, indicative of fresh infarcts. *center*: Perfusion-weighted MR image demonstrating a diffuse low-intensity area in the left cerebral hemisphere, indicative of hypoperfusion of the left middle cerebral artery territory. *right*: MR angiogram demonstrating occlusion of the left internal carotid artery.

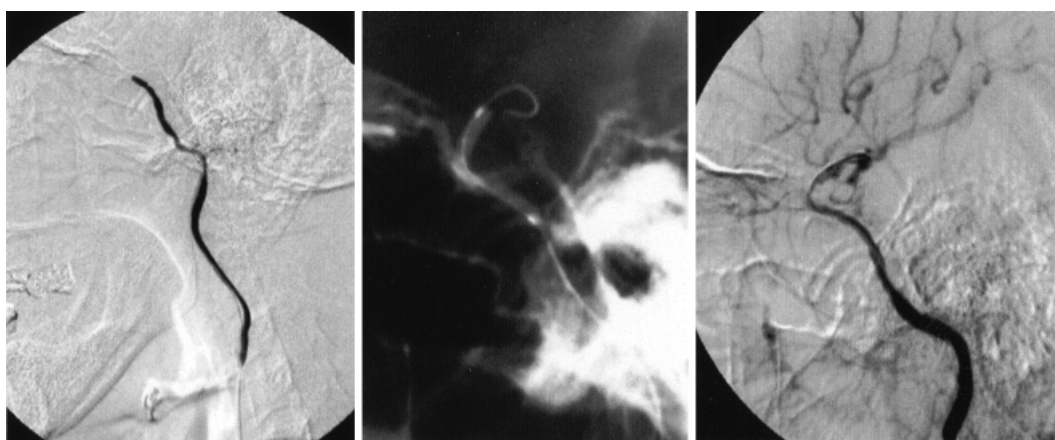

Fig. 2 *left*: Initial left carotid angiogram, lateral view, demonstrating occlusion of the left internal carotid artery (ICA) at the level of the cavernous portion (C₃). *center*: Lateral craniogram demonstrating percutaneous transluminal angioplasty (PTA) with a balloon catheter at the level of the cavernous portion of the left ICA. *right*: Left carotid angiogram, lateral view, obtained immediately after PTA demonstrating recanalization of the left ICA.

(PTA) using a 2.5×20 -mm coronary balloon catheter (Maverick; Boston Scientific, Natick, Mass., U.S.A.) inflated to 5 atm. Antegrade blood flow was obtained and the patient improved (Fig. 2). However, 4 hours later, she became stuporous. Cerebral angiography demonstrated re-occlusion of the portion treated by PTA. Following local intra-arterial fibrinolysis with urokinase (240,000 IU), a 3×18 -mm coronary stent (S670; Medtronic AVE, Minneapolis, Minn., U.S.A.) was deployed at 8 atm for 20 seconds in the irregularly stenosed portion of the affected vessel. Post-dilatation was performed with a 3.25×15 -mm coronary balloon catheter (Quantum Maverick Monorail; Boston Scientific) inflated to 9 atm for 10 seconds to address the

residual narrowing of the stented portion (Fig. 3). This procedure averted completion of the stroke.

Seven days after stent deployment, she deteriorated again despite medical treatment (heparin, thromboxane A₂ antagonist, ticlopidine). Cerebral angiography demonstrated re-occlusion of the stent, indicative of stent thrombosis. Stent thrombosis recurred despite several reopening efforts by PTA and the intraoperative intravenous administration of heparin and ozagrel sodium (thromboxane A₂ antagonist) (Fig. 4). Therefore, a 3.5×20 -mm self-expanding coronary stent (Radius; Boston Scientific) was deployed to overlap with 70% of the proximal portion of the pre-deployed S670 stent (stent-in-stent technique). Post-dilatation was again per-

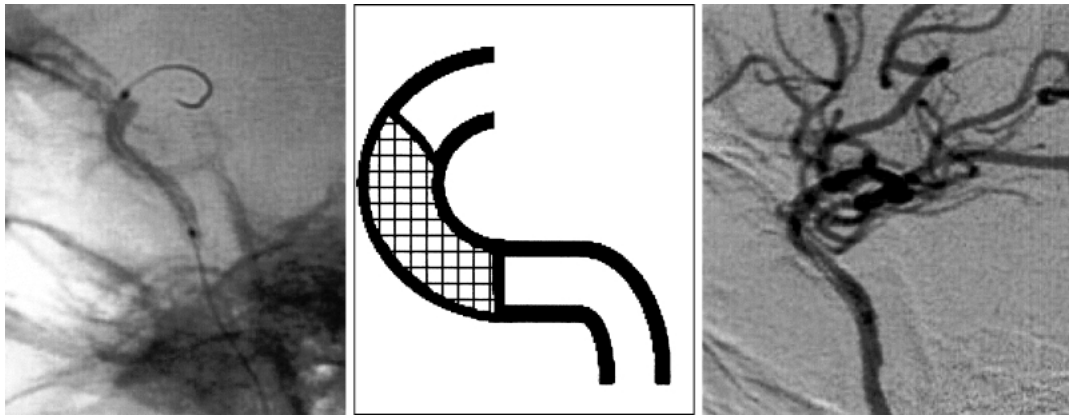


Fig. 3 *left*: Lateral craniogram demonstrating the balloon catheter expanding the stent (S670) in the cavernous portion (C_3) of the left internal carotid artery (ICA). *center*: Scheme indicating the stent (S670) as a cross-hatched area. *right*: Left carotid angiogram, lateral view, after the first stent deployment demonstrating the patency of the left ICA.

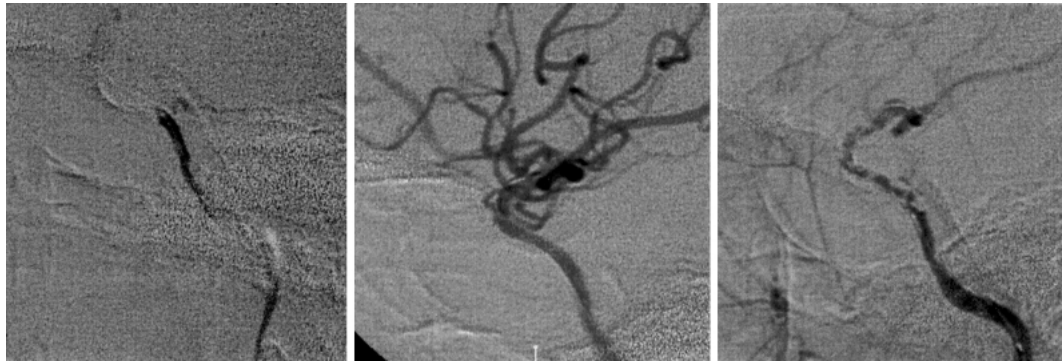

Fig. 4 *left*: Left carotid angiogram obtained 7 days after the first stenting demonstrating re-occlusion of the left internal carotid artery (ICA). *center*: Left carotid angiogram obtained immediately after percutaneous transluminal angioplasty (PTA) demonstrating recanalization of the left ICA. *right*: Left carotid angiogram, lateral view, obtained 15 minutes after PTA demonstrating faint filling of the left ICA. Note the wall irregularity indicative of progressive stent thrombosis.

formed using a 3.5×20 -mm coronary balloon catheter (Maverick) inflated to 6 atm for 10 seconds. Repeat angiography demonstrated patency of the affected artery (Fig. 5) and MR imaging showed no further cerebral infarcts (Fig. 6). Upon discharge, the patient was able to resume her previous independent life.

Discussion

In our patient, the initial radiological findings suggested that acute occlusion of the left ICA had aggravated progressive hemodynamic compromise, resulting in her symptoms. Recanalization of the occluded vessel in this situation may lead to distal

shower embolism or hemorrhagic transformation in the ipsilateral brain parenchyma and possibly worsen the patient's condition. We performed angioplasty because of her progressive symptoms. Although we considered surgical revascularization, e.g. extracranial-intracranial artery bypass, we were worried that there was not enough time for this procedure and that surgical bypass reconstruction could not deliver adequate compensatory blood flow to the entire ICA territory. It is also unclear whether post-craniotomy anticoagulants can be administered safely in the acute phase of stroke.

Following revascularization with PTA her symptoms improved remarkably for several hours, however, she suffered re-occlusion at the same por-

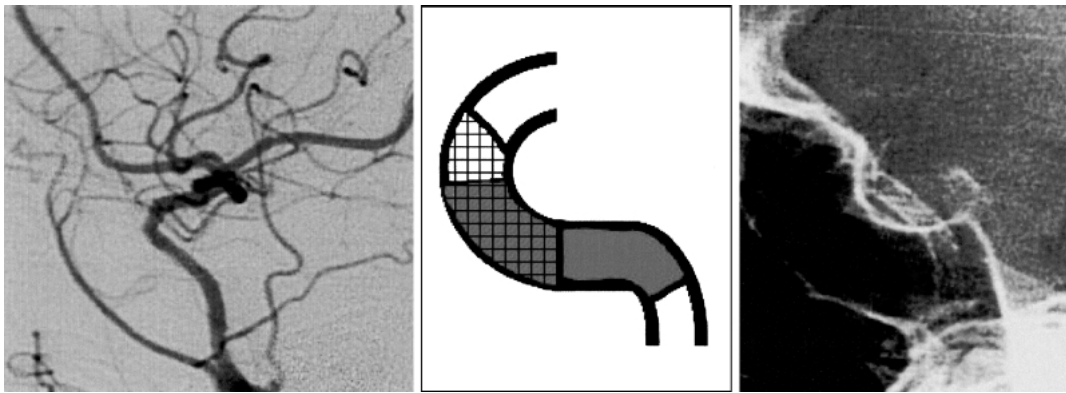


Fig. 5 *left*: Left carotid angiogram, lateral view, obtained 14 days after the stent-in-stent procedure demonstrating recanalization of the left internal carotid artery (ICA) without further thrombosis. *center*: Scheme indicating the first stent (S670) as the cross-hatched area and the second stent (radius) as the gray area. *right*: Plain craniogram demonstrating the stents deployed in the ICA.

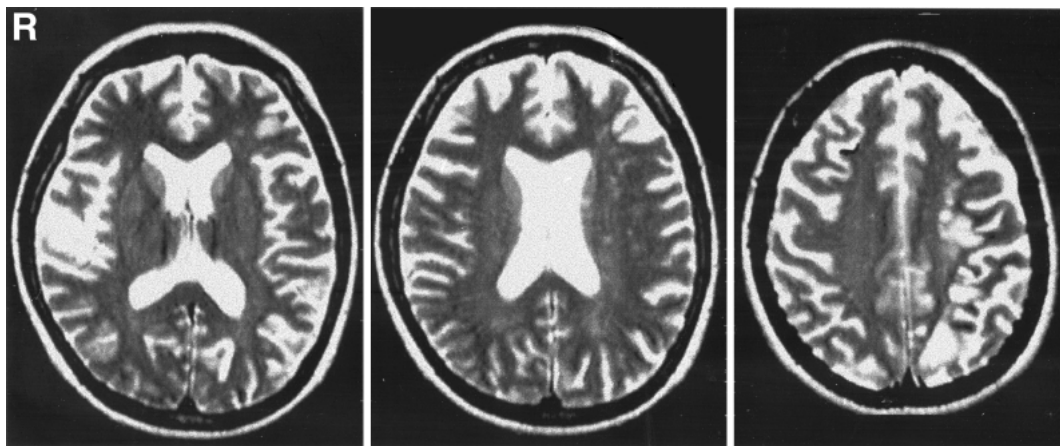


Fig. 6 Axial T₂-weighted magnetic resonance (MR) images obtained 8 days after the stent-in-stent procedure at the level of the basal ganglia (*left*), corona radiata (*center*), and centrum semiovale (*right*). The patient manifested no infarcts except for the abnormalities detected on diffusion-weighted MR imaging at the time of admission.

tion of the ICA. With respect to the PTA balloon catheter used, it is possible that its 2.5 mm diameter was too small and its 20-mm length too long to dilate the curved vessel. It was difficult to determine the appropriate catheter size. Compared to the straight petrous portion of the ICA, in the curved, cavernous part there is a higher risk that oversized or repeated PTA results in vessel dissection or rupture. We found that stent deployment was effective for achieving long-term patency of the affected vessel. We postulate that the repeat occlusion of the affected ICA 7 days after placement of the first stent was due to stent thrombosis because craniography confirmed that the deployed stent was not deformed.

Stent thrombosis occurs in approximately 0.7–2.4% of patients undergoing coronary intervention^{5,15} and may be more common in cases with emergency stent deployment.

Platelet hyperaggregability promotes stent thrombosis, which is characterized by two occurrence peaks: the first is within 24 hours of stent deployment (acute stage) and the 2nd is at 2–14 days post-deployment (subacute stage). The antiplatelet agent abciximab, a glycoprotein IIb/IIIa receptor antagonist, can reduce thrombogenic complications; it is commonly used in coronary stenting in North America and Europe.^{3,4,7–9,11,12,14,17} Unlike other antiplatelet agents, abciximab, which blocks the action

of fibrinogen and the von Willebrand factor at the glycoprotein IIb/IIIa receptor, acts quickly. However, as its use is not yet approved in Japan, we used ozagrel sodium (thromboxane A₂ inhibitor) and ticlopidine.

The stent thrombosis in our patient may be attributable to the poor fit of the stent introduced in the first procedure. We deployed a straight stent into the curved vessel. Furthermore, the diameter of the proximal portion of the stented vessel was different from the distal portion. This resulted in a gap between the stent and the intimal wall in the proximal portion. The diameter of the first stent (3 × 18 mm) may have been too small for the vessel wall and too long for covering the curved portion of the vessel. Our case is unusual in that ICA stent thrombosis was successfully treated with the stent-in-stent technique. In the 2nd procedure we introduced a self-expandable stent in the expectation that it would fit well against the vessel wall. Despite our satisfying result, it remains unclear what type of stent is most suitable in these cases.

The wider use of intracranial stenting demands awareness of potential procedure-related problems like stent thrombosis. The development of suitable therapeutic devices, including different types of stents to be used exclusively for intracranial vessels, and more experience with intracranial stenting are required. Especially in emergency cases, the stent-in-stent technique, combined with the administration of appropriate antiplatelet agents, should be considered as a possible treatment of stent thrombosis.

References

- 1) Al-Mubarak N, Gomez CR, Vitek JJ, Roubin GS: Stenting of symptomatic stenosis of the intracranial internal carotid artery. *AJNR Am J Neuroradiol* 19: 1949-1951, 1998
- 2) Bertrand ME, Rupprecht HJ, Urban P, Gershlick AH: Double-blind study of the safety of clopidogrel with and without a loading dose in combination with aspirin compared with ticlopidine in combination with aspirin after coronary stenting: the clopidogrel aspirin stent international cooperative study (CLASSICS). *Circulation* 102: 624-629, 2000
- 3) Brener SJ, Ellis SG, Schneider J, Apperson-Hansen C, Topol EJ: Abciximab-facilitated percutaneous coronary intervention and long-term survival—a prospective single-center registry. *Eur Heart J* 24: 630-638, 2003
- 4) The EPISTENT Investigators: Randomised placebo-controlled and balloon-angioplasty-controlled trial to assess safety of coronary stenting with use of platelet glycoprotein-IIb/IIIa blockade. Evaluation of Platelet IIb/IIIa Inhibitor for Stenting. *Lancet* 352: 87-92, 1998
- 5) Haude M, Erbel R, Issa H, Straub U, Rupprecht HJ, Treese N, Meyer J: Subacute thrombotic complications after intracoronary implantation of Palmaz-Schatz stents. *Am Heart J* 126: 15-22, 1993
- 6) Karrillon GJ, Morice MC, Benveniste E, Bunouf P, Aubry P, Cattani S, Chevalier B, Commeau P, Cribier A, Eiferman C, Grollier G, Guerin Y, Henry M, Lefevre T, Livarek B, Louvard Y, Marco J, Makowski S, Monassier JP, Pernes JM, Rioux P, Spaulding C, Zemour G: Intracoronary stent implantation without ultrasound guidance and with replacement of conventional anticoagulation by antiplatelet therapy. 30-day clinical outcome of the French Multicenter Registry. *Circulation* 94: 1519-1527, 1996
- 7) Karvouni E, Katritsis DG, Ioannidis JP: Intravenous glycoprotein IIb/IIIa receptor antagonists reduce mortality after percutaneous coronary interventions. *J Am Coll Cardiol* 41: 26-32, 2003
- 8) Kaul U, Gupta RK, Haridas KK, Ramesh SS, Sethi KK, Singh B, Agarwal R, Yadave RD, Ghose T, Sapra RR, Bajaj R, Shahi M, Bhagwat A, Kumar P, Mathews OP, Soni PK: Integrilin in Acute Myocardial Infarction (INAMI) Stenting Study Investigators: Platelet glycoprotein IIb/IIIa inhibition using eptifibatid with primary coronary stenting for acute myocardial infarction: a 30-day follow-up study. *Catheter Cardiovasc Interv* 57: 497-503, 2002
- 9) Kleiman NS: A risk-benefit assessment of abciximab in angioplasty. *Drug Saf* 20: 43-57, 1999
- 10) Lylyk P, Cohen JE, Ceratto R, Ferrario A, Miranda C: Angioplasty and stent placement in intracranial atherosclerotic stenoses and dissections. *AJNR Am J Neuroradiol* 23: 430-436, 2002
- 11) Mayes CE Jr, Kandzari DE, Goldschmidt-Clermont PJ, Phillips HR: The complementary use of glycoprotein IIb/IIIa inhibitors and drug-eluting stents in contemporary percutaneous coronary intervention. *J Invasive Cardiol* 14 Suppl E: 36E-47E, 2002
- 12) Moliterno DJ, Chan AW: Glycoprotein IIb/IIIa inhibition in early intent-to-stent treatment of acute coronary syndromes: EPISTENT, ADMIRAL, CADILLAC, and TARGET. *J Am Coll Cardiol* 41 (4 Suppl S): 49S-54S, 2003
- 13) Mori T, Kazita K, Chokyu K, Mima T, Mori K: Short-term arteriographic and clinical outcome after cerebral angioplasty and stenting for intracranial vertebrobasilar and carotid atherosclerotic occlusive disease. *AJNR Am J Neuroradiol* 21: 249-254, 2000
- 14) Murdock DK, Hoffman MT, Logemann TN, Kaufman JS, Engelmeier RS: Coronary artery stenting during acute myocardial infarction in patients treated with IIb/IIIa anti-platelet antibodies: early outcome results. *Wis Med J* 95: 867-871, 1996
- 15) Nath FC, Muller DW, Ellis SG, Rosenschein U, Chapekis A, Quain L, Zimmerman C, Topol EJ: Thrombosis of a flexible coil coronary stent: frequency, predictors and clinical outcome. *J Am Coll Cardiol* 21: 622-627, 1993

- 16) Sick P, Huttel T, Niebauer J, Thiele H, Lauer B, Hambrecht R, Hentschel B, Schuler G: Influence of residual stenosis after percutaneous coronary intervention with stent implantation on development of restenosis and stent thrombosis. *Am J Cardiol* 91: 148-153, 2003
- 17) Wohrle J, Grebe OC, Nusser T, Al-Khayer E, Schaible S, Kochs M, Hombach V, Hoher M: Reduction of major adverse cardiac events with intracoronary compared with intravenous bolus application of abciximab in patients with acute myocardial infarction or unstable angina undergoing coronary angioplasty. *Circulation* 107: 1840-1843, 2003
- 18) Yokote H, Terada T, Ryujin K, Konoshita Y, Tsuura M, Nakai E, Kamei I, Moriwaki H, Hayashi S, Itakura T: Percutaneous transluminal angioplasty for intracranial arteriosclerotic lesions. *Neuroradiology* 40: 590-596, 1998

Address reprint requests to: J. Satomi, M.D., Department of Surgical Neurology, Research Institute for Brain and Blood Vessels-AKITA, 6-10 Senshu-Kubota-machi, Akita 010-0874, Japan.
e-mail: satomi@akita-noken.go.jp