

NEURAL DAMAGE CAUSED BY CEREBRAL HYPERPERFUSION AFTER ARTERIAL BYPASS SURGERY IN A PATIENT WITH MOYAMOYA DISEASE: CASE REPORT

Kuniaki Ogasawara, M.D.

Department of Neurosurgery and Cyclotron Research Center, Iwate Medical University, Morioka, Japan

Nobukazu Komoribayashi, M.D.

Department of Neurosurgery and Cyclotron Research Center, Iwate Medical University, Morioka, Japan

Masakazu Kobayashi, M.D.

Department of Neurosurgery and Cyclotron Research Center, Iwate Medical University, Morioka, Japan

Takeshi Fukuda, M.D.

Department of Neurosurgery and Cyclotron Research Center, Iwate Medical University, Morioka, Japan

Takashi Inoue, M.D.

Department of Neurosurgery and Cyclotron Research Center, Iwate Medical University, Morioka, Japan

Keiko Yamadate, M.Sc.

Department of Neurosurgery and Cyclotron Research Center, Iwate Medical University, Morioka, Japan

Akira Ogawa, M.D.

Department of Neurosurgery and Cyclotron Research Center, Iwate Medical University, Morioka, Japan

Reprint requests:

Kuniaki Ogasawara, M.D., Department of Neurosurgery, Iwate Medical University, 19-1 Uchimaru, Morioka, Japan 020-8505. Email: kuogasa@iwate-med.ac.jp

Received, July 27, 2004.

Accepted, January 21, 2005.

OBJECTIVE AND IMPORTANCE: The prognosis of cerebral hyperperfusion syndrome after vascular reconstructive surgery, including extracranial-intracranial arterial bypass, is not poor unless intracerebral hemorrhage develops secondary to hyperperfusion.

CLINICAL PRESENTATION: A 48-year-old man with symptomatic moyamoya disease with misery perfusion in the right cerebral hemisphere underwent double right superficial temporal artery-to-middle cerebral artery bypasses. The postoperative course was uneventful until the patient developed headache and agitated delirium on the 4th postoperative day.

INTERVENTION: Perfusion computed tomographic imaging demonstrated hyperperfusion in the right temporal lobe. The symptoms resolved by institution of intensive blood pressure control. Positron emission tomography performed 2 months after surgery demonstrated a postoperative reduction of the cerebral metabolic rate of oxygen in the right temporal lobe, where brain atrophy was observed on magnetic resonance images 3 months postoperatively. Neuropsychological testing performed 3 months postoperatively showed worsening digit span, which adversely affected the patient's quality of life.

CONCLUSION: The current case suggests that cerebral hyperperfusion after vascular reconstructive surgery can cause irreversible neural damage, which results in cognitive impairment.

KEY WORDS: Arterial bypass, Cerebral hyperperfusion, Moyamoya disease

Neurosurgery 56:1380-1381, 2005

DOI: 10.1227/01.NEU.0000159719.47528.2E

www.neurosurgery-online.com

Extracranial-intracranial arterial bypass is the treatment of choice for patients with moyamoya disease and symptoms of cerebral ischemia (16, 23). However, cerebral hyperperfusion syndrome may occur after vascular reconstructive surgery, including extracranial-intracranial arterial bypass and carotid endarterectomy (4, 6, 8, 10, 12, 14, 18, 21, 34, 35). *Cerebral hyperperfusion* is defined as a major increase in ipsilateral cerebral blood flow (CBF) after surgical repair of arterial stenosis or occlusion, well above the metabolic demands of the brain tissue (26, 32). A rapid restoration of normal perfusion pressure after vascular reconstruction may result in regional hyperperfusion secondary to impaired autoregulation that occurs in the context of chronic ischemia (32). Whereas cerebral hyperperfusion syndrome is characterized by unilateral headache, face and eye pain, seizure, and focal symptoms, the prognosis of this syndrome is

not poor unless intracerebral hemorrhage develops secondary to hyperperfusion (4, 6, 11, 12, 18, 21, 26, 31, 32, 34, 35).

In this report, we describe a case of cerebral hyperperfusion syndrome without intracerebral hemorrhage after extracranial-intracranial arterial bypass in a patient with moyamoya disease. The cerebral hyperperfusion resulted in neural damage characterized by a decrease in cerebral metabolism, brain atrophy, and cognitive impairment.

CASE REPORT

A 48-year-old man was in his usual state of good health when he presented with new-onset blurred vision and was admitted to a local hospital for evaluation and treatment. The patient displayed left homonymous hemianopsia, and a computed tomographic (CT) scan of the head revealed a cerebral infarct in

the right temporo-occipital region. Cerebral angiography demonstrated severe stenosis involving the bilateral distal internal carotid arteries (ICAs), basal moyamoya vessels, and poor collateral circulation to the right middle cerebral artery (MCA) territory via a stenotic right posterior cerebral artery (Fig. 1, A–C). The diagnosis, according to the angiographic classification described by Suzuki and Kodama (33), was cerebral infarction owing to Stage 3 moyamoya disease, and antiplatelet medication was initiated. However, 2 months after symptom onset, the patient experienced a transient ischemic attack manifesting as left hemiparesis and was admitted to our hospital for specialized care and further evaluation.

Upon admission, a neurological examination revealed left homonymous hemianopsia. Neuropsychological testing, consisting of the Japanese translation of the Wechsler Adult Intelligence Scale Revised (WAIS-R) (28) and the Japanese translation of the Wechsler Memory Scale (WMS) (13), demonstrated impairment of performance intelligence quotient (Table 1). Magnetic resonance (MR) imaging revealed a cerebral infarct in the right temporo-occipitoparietal region (Fig. 2, A–C). A positron emission tomographic (PET) study using ^{15}O -labeled O_2 and CO inhalation and H_2O autoradiography (27) revealed a decreased cerebral metabolic rate of oxygen (CMRO_2) and a marked decrease in CBF, resulting in an increased oxygen extraction fraction (OEF) in the right temporal, frontal, and parietal lobes (Fig. 3, A and B, top row). Based on these results, the right cerebral hemisphere was considered to be in a misery perfusion state, and superficial

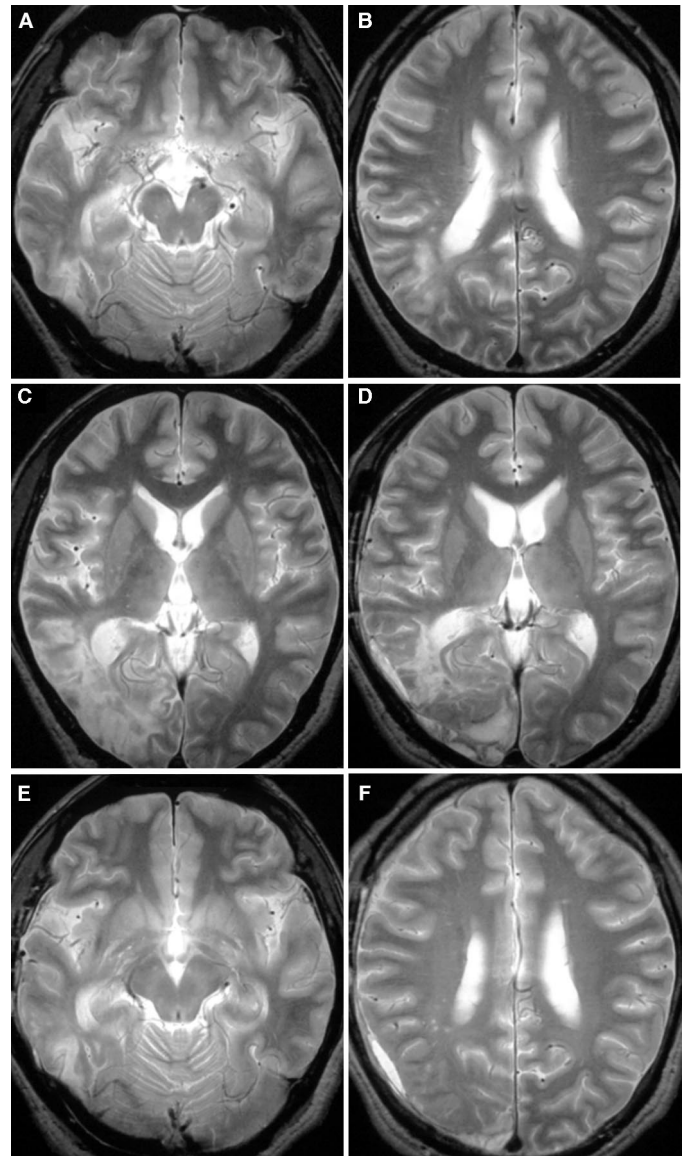


FIGURE 2. A, C, E, preoperative T2-weighted MR images showing a cerebral infarct in the right temporo-occipitoparietal region. An infarct lesion in the right occipital lobe was more extensive than that in the right temporal lobe. B, D, F, T2-weighted MR images obtained 3 months after surgery showing brain atrophy in only the right temporal lobe. The right frontal, parietal, and occipital lobes did not exhibit brain atrophy.

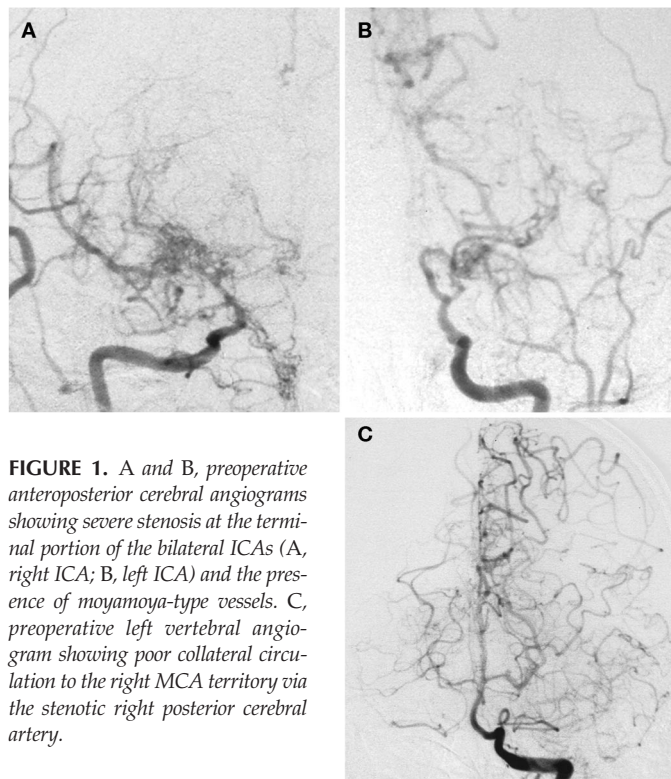


FIGURE 1. A and B, preoperative anteroposterior cerebral angiograms showing severe stenosis at the terminal portion of the bilateral ICAs (A, right ICA; B, left ICA) and the presence of moyamoya-type vessels. C, preoperative left vertebral angiogram showing poor collateral circulation to the right MCA territory via the stenotic right posterior cerebral artery.

temporal artery (STA)-MCA anastomosis was performed 1 month after the evaluation with neuropsychological testing, MR imaging, and PET study. Anesthesia was maintained by intravenous propofol and fentanyl, and the patient was mechanically ventilated with an air-oxygen mixture (inspired fraction of oxygen ~ 0.30). Periodic analysis of arterial blood gas samples ensured normocapnia (PaCO_2 , 38–40 mm Hg). Blood pressure was maintained in a range $\pm 15\%$ of the preoperative level throughout the procedure by adjusting the

TABLE 1. Neuropsychologic test scores before and after bypass surgery^a

Test	Preoperative	3rd postoperative month	6th postoperative month	SD ^b
WAIS-R				
Full-scale IQ	83	86	88	13.4
Verbal IQ	97	91	93	13.6
Information	11	12	12	4.2
Digit span	9	5	5	3.8
Vocabulary	10	7	8	3.5
Arithmetic	11	10	11	4.2
Comprehension	3	5	4	4.3
Similarities	13	12	13	5.1
Performance IQ	68	70	71	13.3
Picture completion	5	5	5	3.7
Picture arrangement	6	4	6	4.8
Block design	7	8	8	3.9
Digit symbol	4	3	4	4.6
Object assembly	5	8	8	3.5
WMS				
MQ	110	99	104	19.8
Information	5	6	6	2.6
Orientation	5	5	5	2.1
Mental control	9	4	6	5.1
Count back	3	2	3	2.1
Alphabet	3	2	3	1.8
Serial counting by 3	3	0	2	3.1
Logical memory	9	9	9	5.8
Digit span	8	3	3	4.7
Digits forward	5	0	0	3.5
D~igits backward	3	3	3	2.8
Visual reproduction	11	13	12	4.9
Associate learning	15.5	15	15	5.2
Easy pairs	17	18	18	4.8
Hard pairs	7	6	7	3.1

^a SD, standard deviation; WAIS-R, Wechsler Adult Intelligence Scale-Revised; IQ, intelligence quotient; WMS, Wechsler Memory Scale; MQ, memory quotient.

^b ~These values were obtained from a population of 81 patients with carotid stenosis that was described previously (20).

depth of anesthesia. During the operation, the frontal and parietal branches of the STA were anastomosed to a cortical artery in the temporal and frontal lobes, respectively. The operation was accomplished without difficulty, and the duration of the temporary occlusion of each recipient artery was 25 and 23 minutes, respectively. The patient recovered from anesthesia without new neurological deficits and did not exhibit additional ischemic lesions on a CT scan performed on the 1st postoperative day.

The patient had an uneventful course until the 4th postoperative day, when he experienced severe headache and agitated delirium characterized by vivid hallucinations, delusions, and extreme agitation and irritability (15). T2- and diffusion-weighted MR imaging performed 6 hours after the

onset of these symptoms demonstrated a hyperintensity in the right temporal lobe (Fig. 4). MR angiography revealed patent double STA-MCA anastomoses (Fig. 5). Subsequent perfusion CT imaging (19) demonstrated increased CBF and cerebral blood volume in the right temporal lobe (Fig. 6, top row). CBF was twice as high in the right temporal lobe as it was in the left temporal lobe. Based on these findings, a diagnosis of cerebral hyperperfusion syndrome was made, and intensive control of systolic blood pressure to a goal range between 90 and 120 mm Hg was instituted using 0.45 mg per day of an orally administered, centrally acting α_2 -agonist, clonidine (Catapres; Boehringer Ingelheim, Gaithersburg, MD), and 3 $\mu\text{g}/\text{kg}/\text{min}$ of an intravenously administered calcium antagonist, nicardipine (Perdipine; Yamanouchi Pharmaceutical, Tokyo, Japan). The patient's symptoms resolved 5 days after the onset of the hyperperfusion syndrome. Repeated T2-weighted MR and perfusion CT imaging performed 15 days after the onset of the hyperperfusion syndrome demonstrated resolution of both hyperintensity and hyperperfusion in the right temporal lobe (Fig. 6, bottom row), and pharmacological control of blood pressure was discontinued.

The PET study performed in the same manner 2 months after surgery revealed increased CBF and unchanged CMRO_2 , resulting in normalization of OEF in the right frontal and parietal lobes (Fig. 3B, bottom row). In contrast, in the right temporal lobe, whereas CBF was slightly increased, CMRO_2 was lower than the preoperative value, and OEF was lower than the contralateral value (Fig. 3A, bottom row). MR imaging performed 3 months after surgery showed brain atrophy only in the right temporal lobe (Fig. 2, D-F). In contrast, the right frontal, parietal, and occipital lobes did not exhibit brain atrophy. Neuropsychological testing was repeated 3 months after surgery, and a conventional definition of postoperative

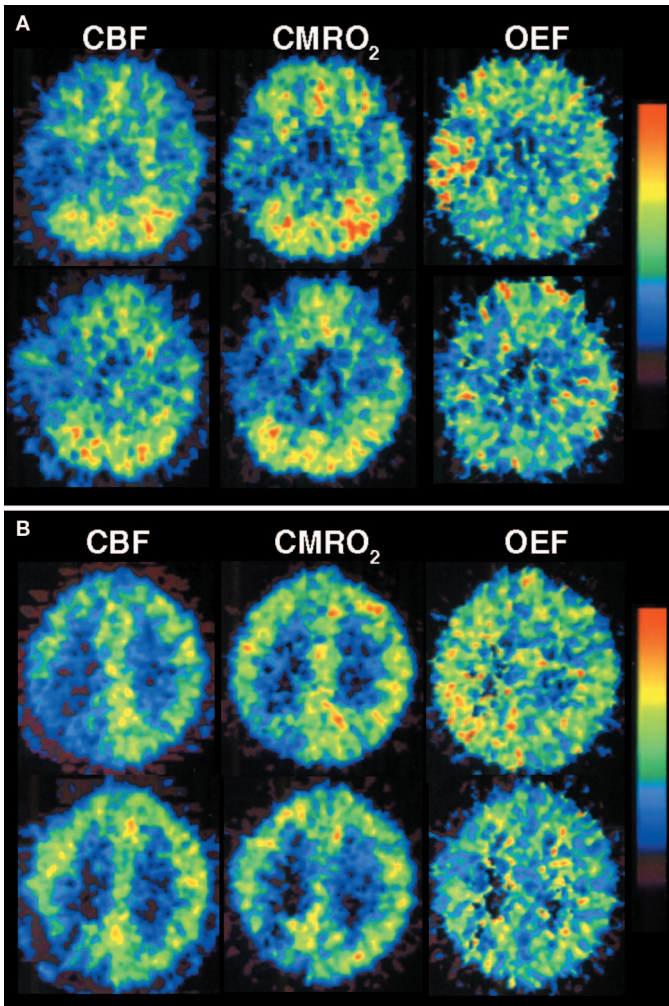


FIGURE 3. PET images at the level of the basal cistern (A) and the body of the lateral ventricle (B) before (top row) and 2 months after (bottom row) surgery. Preoperative $CMRO_2$ was decreased, and CBF was markedly decreased, which resulted in increased OEF in the right temporal, frontal, and parietal lobes. Preoperative OEF was not elevated in the left cerebral hemisphere. Whereas CBF in the right temporal lobe was slightly increased postoperatively, $CMRO_2$ was lower than the preoperative value, and OEF was lower than the contralateral value. In contrast, in the right frontal and parietal lobes, CBF was increased and $CMRO_2$ was unchanged postoperatively, which resulted in normalization of OEF.

neuropsychological deficit (20, 30) was applied. This system uses the standard deviation (SD) unit for each test obtained from the preoperative scores in the patient population and defines a deficit for each test in each patient as a decrease in the postoperative score by ≥ 1 SD unit from the preoperative score. Furthermore, an improvement was defined as ≥ 1 SD unit elevation above the preoperative score. In the current study, the SD obtained from 81 patients undergoing carotid endarterectomy was used (20), and neuropsychological testing demonstrated a postoperative decline only in digit span in both the WAIS-R and the WMS (Table 1). Furthermore, none of

the tests revealed postoperative improvement. Neuropsychological testing performed 6 months after surgery showed persistence of impaired digit span in both the WAIS-R and the WMS (Table 1). The patient's quality of life, including work ability, was adversely affected by this cognitive impairment.

DISCUSSION

Investigators have proposed mechanisms for development of hyperperfusion after vascular reconstructive surgery (1). In cases with severe ICA stenosis and deficient collateral circulation, hemispheric perfusion pressure is severely reduced distal to the ICA stenosis. This may result in a reduction of perfusion pressure below the compensatory capacity of autoregulatory mechanisms, thus leading to maximal dilation of resistance vessels and misery perfusion. After restoration of normal perfusion pressure after vascular reconstructive surgery, chronically impaired autoregulatory mechanisms may require several days to adjust to the new steady state, resulting in hyperperfusion in the interim. The current case, in which the patient experienced hyperperfusion after bypass surgery for the right temporal lobe with a misery perfusion, is consistent with this theory.

In the current case, PET performed 2 months after surgery demonstrated a postoperative reduction of $CMRO_2$ in the right temporal lobe, where brain atrophy was observed on MR images 3 months postoperatively. These findings indicate postoperative development of irreversible neural damage in the right temporal lobe. In addition, transient hyperperfusion after surgery was observed in that region, and diffusion-weighted MR imaging demonstrated transient hyperintense lesions, which may reflect cytotoxic edema (29). Thus, cytotoxic edema owing to hyperperfusion may result in irreversible neural damage in the right temporal lobe.

We previously demonstrated that cognitive improvement after STA-MCA bypass in patients with symptomatic atherosclerotic ICA or MCA occlusion was dependent on preoperative OEF and was associated with improvement in OEF (27).

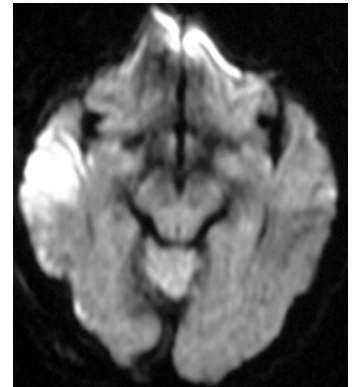


FIGURE 4. Diffusion-weighted MR image obtained 6 hours after the onset of headache and agitated delirium showing hyperintense lesions in the right temporal lobe.

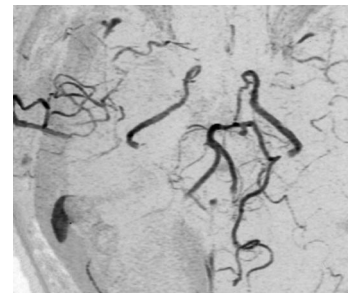


FIGURE 5. MR angiogram performed 6 hours after the onset of headache and agitated delirium showing patent double STA-MCA anastomoses. The signal intensity was higher in the right MCA branches than in the left MCA branches.

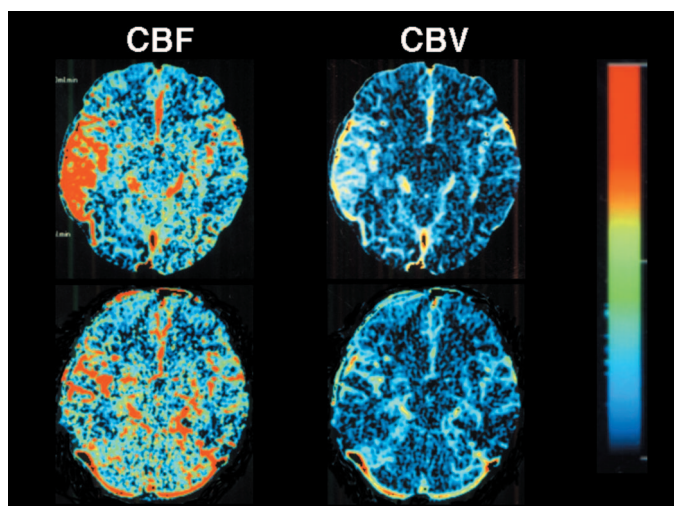


FIGURE 6. Perfusion CT images 7 hours after the onset of headache and agitated delirium showing increased CBF and cerebral blood volume in the right temporal lobe (top row). The CBF was twice as high in the right temporal lobe (76 ml/100 g/min) as in the left temporal lobe (34 ml/100 g/min). Repeated perfusion CT images 15 days after the onset of the symptoms show resolution of hyperperfusion in the right temporal lobe (bottom row).

In the current case, although the preoperative increase in OEF in the frontal and parietal lobes normalized after STA-MCA bypass, digit span, which is used to evaluate memory and attention (13, 28), worsened postoperatively. Several investigators hypothesize that the temporal lobe plays an important role in memory (7, 25). For example, Burton et al. (2) recently demonstrated significant associations between memory and white matter hyperintensity volumes in the left or right temporal lobe on MR imaging. In addition, agitated delirium, which developed as a symptom of cerebral hyperperfusion in the current case, may be caused by dysfunction of the right temporal lobe and can be associated with impairment of attention (15). Thus, the postoperative decline in digit span in our patient may result from neural damage in the right temporal lobe.

Postoperative cognitive impairment, as revealed by neuropsychological testing, occurs in 20 to 30% of patients undergoing carotid endarterectomy (3, 9) and is associated with cerebral hyperperfusion after surgery, even when asymptomatic (20). Furthermore, the development of hyperperfusion syndrome is associated with persistence (e.g., at least 6 mo) of postoperative cognitive impairment (20). Results from the current case are consistent with these findings and suggest that cerebral hyperperfusion after vascular reconstructive surgery can also cause irreversible neural damage and lead to cognitive impairment.

Interpretation of data from the current case poses several problems that require discussion. First, cognitive impairment or brain atrophy may also occur secondary to the chronic ischemia associated with moyamoya disease. However, this

patient developed brain atrophy and impairment in digit span between the 1-month preoperative evaluation and the 3-month postoperative evaluation. Furthermore, postoperative MR angiography revealed patent double STA-MCA bypasses, and postoperative PET imaging showed an increase in CBF and a reduction of OEF in the entire right cerebral hemisphere. Thus, it is not likely that the chronic cerebral ischemia of moyamoya disease explains the subacute development of brain atrophy and impaired digit span in the current case. Secondly, brain atrophy may also occur secondary to brain infarction (5, 24). Indeed, preoperative MR images of our patient showed an area of infarction that was much more prominent in the right occipital lobe than in the right temporal lobe. However, if the brain atrophy in this patient resulted from the initial infarction, then the right occipital lobe should become more atrophic than the right temporal lobe. Instead, MR images obtained 3 months after surgery showed brain atrophy in only the right temporal lobe. In addition, the right frontal, parietal, and occipital lobes did not exhibit brain atrophy. Thus, brain atrophy in our patient is likely not related to initial infarction. Lastly, postoperative cognitive impairment may also result from craniotomy or from the bypass surgery itself. However, at our institution, surgical treatment of unruptured intracranial aneurysms by means of craniotomy did not impair cognitive function (22), and patients with preoperative WAIS-R full-scale intelligence quotient greater than 80 did not display cognitive decline after bypass surgery (27). Thus, the postoperative cognitive impairment in this patient may not be related to the craniotomy or to the bypass surgery itself.

The patient's quality of life, including work ability, was adversely affected by his cognitive impairment. Although strict control of blood pressure in the postoperative period is effective in preventing intracerebral hemorrhage owing to hyperperfusion, it cannot prevent the development of cerebral hyperperfusion itself (4, 18, 21, 35). We have recently reported that pretreatment with a novel free radical scavenger, such as edaravone, could prevent the occurrence of cerebral hyperperfusion after carotid endarterectomy (17). Thus, further research regarding strategies to decrease the incidence of cerebral hyperperfusion after bypass surgery in moyamoya disease, which may include the use of edaravone, would be of benefit.

REFERENCES

- Bernstein M, Fleming JF, Deck JH: Cerebral hyperperfusion after carotid endarterectomy: A cause of cerebral hemorrhage. *Neurosurgery* 15:50–56, 1984.
- Burton EJ, Kenny RA, O'Brien J, Stephens S, Bradbury M, Rowan E, Kalaria R, Firbank M, Wesnes K, Ballard C: White matter hyperintensities are associated with impairment of memory, attention, and global cognitive performance in older stroke patients. *Stroke* 35:1270–1275, 2004.
- Crawley F, Stygall J, Lunn S, Harrison M, Brown MM, Newman S: Comparison of microembolism detected by transcranial Doppler and neuropsychological sequelae of carotid surgery and percutaneous transluminal angioplasty. *Stroke* 31:1329–1334, 2000.

4. Dalman JE, Beenackers IC, Moll FL, Leusink JA, Ackerstaff RG: Transcranial Doppler monitoring during carotid endarterectomy helps to identify patients at risk of postoperative hyperperfusion. *Eur J Vasc Endovasc Surg* 18:222–227, 1999.
5. Davalos A, Matias-Guiu J, Torrent O, Vilaseca J, Codina A: Computed tomography in reversible ischemic attacks: Clinical and prognostic correlations in a prospective study. *J Neurol* 235:155–158, 1988.
6. Furuya K, Kawahara N, Morita A, Momose T, Aoki S, Kirino T: Focal hyperperfusion after superficial temporal artery-middle cerebral artery anastomosis in a patient with moyamoya disease: Case report. *J Neurosurg* 100:128–132, 2004.
7. Golby AJ, Poldrack RA, Brewer JB, Spencer D, Desmond JE, Aron AP, Gabrieli JD: Material-specific lateralization in the medial temporal lobe and prefrontal cortex during memory encoding. *Brain* 124:1841–1854, 2001.
8. Heros RC, Scott RM, Kistler JP, Ackerman RH, Conner ES: Temporary neurological deterioration after extracranial-intracranial bypass. *Neurosurgery* 15:178–185, 1984.
9. Heyer EJ, Sharma R, Rampersad A, Winfree CJ, Mack WJ, Solomon RA, Todd GJ, McCormick PC, McMurtry JG, Quest DO, Stern Y, Lazar RM, Connolly ES Jr: A controlled prospective study of neuropsychological dysfunction following carotid endarterectomy. *Arch Neurol* 59:217–222, 2002.
10. Higashi S, Matsuda H, Fujii H, Ito H, Yamashita J: Luxury perfusion syndrome confirmed by sequential studies of regional cerebral blood flow and volume after extracranial to intracranial bypass surgery: Case report. *Neurosurgery* 25:85–89, 1989.
11. Hosoda K, Kawaguchi T, Shibata Y, Kamei M, Kidoguchi K, Koyama J, Fujita S, Tamaki N: Cerebral vasoreactivity and internal carotid artery flow help to identify patients at risk for hyperperfusion after carotid endarterectomy. *Stroke* 32:1567–1573, 2001.
12. Jansen C, Sprengers AM, Moll FL, Vermeulen FE, Hamerlijnck RP, van Gijn J, Ackerstaff RG: Prediction of intracerebral hemorrhage after carotid endarterectomy by clinical criteria and intraoperative transcranial Doppler monitoring: Results of 233 operations. *Eur J Vasc Surg* 8:220–225, 1994.
13. Koyama M: *Clinical Psychology of Brain Damage*. Tokyo, Gakuen Sha, 1985, pp 48–54.
14. Kuroda S, Kamiyama H, Abe H, Asaoka K, Mitsumori K: Temporary neurological deterioration caused by hyperperfusion after extracranial-intracranial bypass: Case report and study of cerebral hemodynamics. *Neurol Med Chir (Tokyo)* 34:15–19, 1994.
15. Mori E, Yamadori A: Acute confusional state and acute agitated delirium: Occurrence after infarction in the right middle cerebral artery territory. *Arch Neurol* 44:1139–1143, 1987.
16. Newell DW, Vilela MD: Superficial temporal artery to middle cerebral artery bypass. *Neurosurgery* 54:1441–1449, 2004.
17. Ogasawara K, Inoue T, Kobayashi M, Endo H, Fukuda T, Ogawa A: Pretreatment with the free radical scavenger edaravone prevents cerebral hyperperfusion after carotid endarterectomy. *Neurosurgery* 55:1060–1067, 2004.
18. Ogasawara K, Konno H, Yukawa H, Endo H, Inoue H, Ogawa A: Transcranial regional cerebral oxygen saturation monitoring during carotid endarterectomy as a predictor of postoperative hyperperfusion. *Neurosurgery* 53:309–315, 2003.
19. Ogasawara K, Sasaki M, Tomitsuka N, Kubo Y, Inoue T, Ogawa A: Early revascularization for perfusion computed tomography/diffusion weighted magnetic resonance imaging mismatch caused by acute vertebral artery occlusion: Case report. *Neurol Med Chir (Tokyo)* (in press).
20. Ogasawara K, Yamadate K, Kobayashi M, Endo H, Fukuda T, Yoshida K, Terasaki K, Inoue T, Ogawa A: Postoperative cerebral hyperperfusion is associated with impaired cognitive function in patients undergoing carotid endarterectomy. *J Neurosurg* 102:38–44, 2005.
21. Ogasawara K, Yukawa H, Kobayashi M, Mikami C, Konno H, Terasaki K, Inoue T, Ogawa A: Prediction and monitoring of cerebral hyperperfusion after carotid endarterectomy using single photon emission computed tomography. *J Neurosurg* 99:504–510, 2003.
22. Otawara Y, Ogasawara K, Ogawa A, Yamadate K: Cognitive function before and after surgery in patients with unruptured intracranial aneurysm. *Stroke* 36:142–143, 2005.
23. Oya S, Tsutsumi K, Ueki K: Adult-onset moyamoya disease with repetitive ischemic attacks successfully treated by superficial temporal-middle cerebral artery bypass: Case report. *Neurol Med Chir (Tokyo)* 43:138–141, 2003.
24. Pasquier F, Leys D, Weerts JG, Mounier-Vehier F, Barkhof F, Scheltens P: Inter- and intraobserver reproducibility of cerebral atrophy assessment on MRI scans with hemispheric infarcts. *Eur Neurol* 36:268–272, 1996.
25. Petersen RC, Jack CR Jr, Xu YC, Waring SC, O'Brien PC, Smith GE, Ivnik RJ, Tangalos EG, Boeve BF, Kokmen E: Memory and MRI-based hippocampal volumes in aging and AD. *Neurology* 54:581–587, 2000.
26. Piepgras DG, Morgan MK, Sundt TM Jr, Yanagihara T, Mussman LM: Intracerebral hemorrhage after carotid endarterectomy. *J Neurosurg* 68:532–536, 1988.
27. Sasoh M, Ogasawara K, Kuroda K, Okuguchi T, Terasaki K, Yamadate K, Ogawa A: Effects of EC-IC bypass surgery on cognitive impairment in patients with hemodynamic cerebral ischemia. *Surg Neurol* 59:455–463, 2003.
28. Shinagawa F, Kobayashi S, Fujita K, Maekawa H: *Japanese Wechsler Adult Intelligence Scale-Revised*. Tokyo, Nihon Bunka Kagakusha, 1990.
29. Shinno K, Ueda S, Uno M, Nishitani K, Nagahiro S, Harada M: Hyperperfusion syndrome following carotid endarterectomy: Evaluation using diffusion-weighted magnetic resonance imaging: case report. *Neurol Med Chir (Tokyo)* 38:557–561, 1998.
30. Smith PL, Treasure T, Newman SP, Joseph P, Ell PJ, Schneidau A, Harrison MJ: Cerebral consequences of cardiopulmonary bypass. *Lancet* 1:823–825, 1986.
31. Solomon RA, Loftus CM, Quest DO, Correll JW: Incidence and etiology of intracerebral hemorrhage following carotid endarterectomy. *J Neurosurg* 64:29–34, 1986.
32. Sundt TM Jr, Sharbrough FW, Piepgras DG, Kearns TP, Messick JM Jr, O'Fallon WM: Correlation of cerebral blood flow and electroencephalographic changes during carotid endarterectomy, with results of surgery and hemodynamics of cerebral ischemia. *Mayo Clin Proc* 56:533–543, 1981.
33. Suzuki J, Kodama N: Moyamoya disease: A review. *Stroke* 14:104–109, 1983.
34. Uno M, Nakajima N, Nishi K, Shinno K, Nagahiro S: Hyperperfusion syndrome after extracranial-intracranial bypass in a patient with moyamoya disease: Case report. *Neurol Med Chir (Tokyo)* 38:420–424, 1998.
35. Yoshimoto T, Houkin K, Kuroda S, Abe H, Kashiwaba T: Low cerebral blood flow and perfusion reserve induce hyperperfusion after surgical revascularization: Case reports and analysis of cerebral hemodynamics. *Surg Neurol* 48:132–139, 1997.

COMMENTS

The authors report a case of a 48-year-old man with symptomatic moyamoya disease that was treated with a double superficial temporal artery (STA)-middle cerebral artery (MCA) bypass, which subsequently caused a cerebral hyperperfusion syndrome similar to that observed after carotid endarterectomy. The patient was managed by lowering his systolic blood pressure to between 90 and 120 mmHg, but he suffered neural damage, cognitive impairment, and disability that were irreversible. Hyperperfusion syndrome is rare, is seen mostly after over exuberant revascularization after saphenous vein bypass, and can result in intracerebral hemorrhage with more devastating consequences. The authors serve us well by documenting this syndrome after a routine STA-MCA bypass in a moyamoya patient, and by investigating free radical scavengers as an additional therapy. Still, it is important to emphasize that most moyamoya patients require normal or slightly higher than normal blood pressures in the perioperative period during and after bypass surgery to prevent ischemic complications, rather than efforts to lower blood pressure and prevent this unlikely hyperperfusion syndrome.

Michael T. Lawton
San Francisco, California

Although there have been previous reports of hyperperfusion syndrome following STA-MCA bypass in moyamoya patients, including temporary neurologic deficits and imaging evidence of hyperperfusion, this is the first report to document persistent cerebral injury reflected by positron emission tomographic scanning 2 months after surgery and cognitive impairment potentially related to the hyperperfusion syndrome. In our series of 182 direct bypasses for moyamoya patients, we have observed two instances of temporary neurologic deficits (partial aphasia) unassociated with hemorrhage or acute ischemia or infarct on diffusion-weighted magnetic resonance imaging, which we attributed to hyperperfusion syndrome. Both these patients showed resolution of their deficits on neurological examination, but we did not perform neuropsychological testing. We currently measure intraoperative M4 middle cerebral artery blood flows before and after STA-MCA bypass, as well as pre- and postoperative transcranial Doppler MCA velocities in our moyamoya patients. If there is evidence of significant hyperperfusion after the bypass, we rigorously control the patients' blood pressure for several days postoperatively, with the hope of minimizing the detrimental consequences of hyperperfusion syndrome.

The authors draw attention to the benefits of performing neuropsychological testing before and after revascularization in their moyamoya patients, because less obvious, but functionally important, deficits or improvements can be detected compared with neurological examination alone. We too have recently initiated such neuropsychological testing in our moyamoya patients.

Gary K. Steinberg
Stanford, California

Cerebral hyperperfusion after revascularization of the brain has been well documented. The current study documents a case of cerebral hyperperfusion after extracranial to intracranial bypass surgery using modern imaging techniques to more elegantly and convincingly demonstrate the hyperperfusion and the long-term ill effects of that complication on the brain. The authors use perfusion computed tomography to illustrate the hyperperfusion in the right temporal lobe and positron emission tomography to demonstrate a postoperative reduction of the cerebral metabolic rate of oxygen consump-

tion in the ipsilateral temporal lobe. Perfusion computed tomography measurements of oxygen extraction fraction improved in the frontal and parietal lobes after the bypass, but worsened in the temporal lobe, which seemed to experience the consequences of postoperative hyperperfusion. Finally, the authors used both pre- and postoperative neuropsychological testing to document the deterioration of cognitive function in this patient.

Hyperperfusion after extracranial to intracranial bypass is rare, and is most likely caused by the relatively low blood flow provided by the STA initially after the operation. This report documents this risk and should serve as a caution to surgeons to be diligent in the postoperative management of patients undergoing revascularization procedures. In particular, strict control of blood pressure in the perioperative period is of paramount importance.

Daniel L. Barrow
Atlanta, Georgia

The authors reported an interesting case of moyamoya disease that developed delayed hyperperfusion syndrome after bypass surgery resulting in the disturbance of higher cognitive function. Although cases of hyperperfusion syndrome after bypass surgery in moyamoya disease has already been reported, it is of practical value because the authors mentioned the anesthesiological and medical management to avoid hyperperfusion syndrome in the surgical treatment of moyamoya disease. Additionally, they showed that higher cognitive function cannot always be improved by bypass surgery in moyamoya disease, even when misery perfusion is revealed by preoperative positron emission tomographic study, although it can usually be improved in the treatment of atherosclerotic cerebroocclusive disease. This paper provided significant information practically available for the treatment of moyamoya disease. We hope that this concept will be verified by many neurosurgeons to add further information for the understanding and improvement of the surgical treatment of moyamoya disease.

Ken-ichiro Kikuta
Nobuo Hashimoto
Kyoto, Japan