

Unilateral Opercular Macrogyria and Benign Childhood Epilepsy with Centrotemporal (Rolandic) Spikes: Report of a Case

Giovanni Ambrosetto

Institute of Neurology, University of Bologna, Bologna, Italy

Summary: An 18-year-old mentally normal epileptic boy had frequent left brachiofacial or unilateral motor seizures which started at age 4 years and ceased 10 years later. Seizures were exclusively sleep-related. No relapse followed antiepileptic drug (AED) discontinuation. Left arm slight paresis and left hand astereognosia occurred at age 10 years. Awake EEGs showed persistent right rolandic discharges increased by sleep. Somatosensory evoked potentials (SEPs) were giant with left median

nerve stimulation. Computed tomography (CT) and magnetic resonance imaging (MRI) disclosed right opercular macrogyria. We suggest that the structural brain lesion was causally related to his "idiopathic" partial epilepsy. Similar case reports and pathologic studies will elucidate the morphologic substrate of the underlying functional disorder in idiopathic partial epilepsies. **Key Words:** Epilepsy—Electroencephalography—Brain—Macrogyria.

In the latest proposal for a revised classification of epilepsies and epileptic syndromes (Commission, 1989), benign childhood epilepsy with centrotemporal (rolandic) spikes (BECTS) is considered an "idiopathic location-related (focal, local, partial) epilepsy." Idiopathic epilepsies are described as "disorders not preceded or occasioned by another" with "no underlying cause other than a possible hereditary predisposition." Thus, BECTS is a syndrome without demonstrable anatomic lesions, and patients clinically have neither neurologic and intellectual deficit nor a history of antecedent illness. I report a patient with unilateral opercular macrogyria and epilepsy with the electroclinical and evolutive characteristics of BECTS, which in all probability were causally related.

CASE REPORT

An 18-year-old boy with no family history of epilepsy had two simple febrile convulsions at age 2 years. The first epileptic seizure occurred at age 4 years during sleep, with jerking of the mouth and of

the left arm, hypersalivation, and inability to speak. The seizure was followed by transient left arm paresis. A similar sleep-related seizure occurred 2 months later, when he was first examined as an outpatient. Neurologic examination was normal. EEG showed normal background activity and a right high-voltage central spike focus. Despite phenobarbital (PB) treatment, left brachiofacial or left unilateral convulsive seizures persisted, with monthly recurrence. Seizures were strictly sleep-related, lasted 2–10 min, and were followed by left arm paresis and dysarthria whose transiency was related to the seizure duration. He had no secondarily generalized seizure. Treatment with a combination of PB and carbamazepine (CBZ) and then CBZ and valproate (VPA) with optimal plasma drug levels had no clinical effect.

EEGs performed twice yearly continued to show frequent or almost continuous right rolandic discharges (Fig. 1). Rarely, an independent left centrotemporal focus occurred (Fig. 2). NREM and REM sleep further increased right central discharges. A first computed tomography (CT) scan performed at age 8 years was judged unremarkable. Somatosensory evoked potentials (SEPs) showed normal short and mid-long latency responses except for the left median nerve stimulation, which showed a negative peak of 149V 60 ms after stimulation.

Received April 1991; revision accepted July 1991.

Address correspondence and reprint requests to Professor G. Ambrosetto at Institute of Neurology, Via Ugo Foscolo 7, 40123 Bologna, Italy.

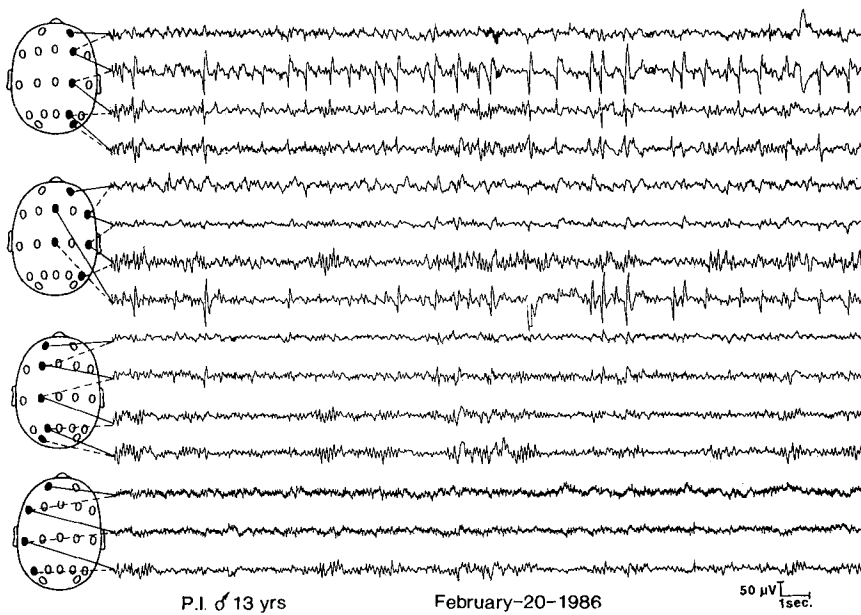


FIG. 1. EEG showing vertex and right central discharges spreading posteriorly.

When the child was aged 10 years, the mother reported that her child did not use his left hand much. Neurologic examination disclosed a very slight prominent distally left arm hyposthenia and hypotrophy, difficulty in left finger opposition, and a left

hand astereognosia. WISC full-scale IQ was 98, verbal IQ was 97, and performance IQ was 98. Cerebral CT scan showed right parietal hyperdensity with no contrast enhancement. Right carotid angiography was normal. SEPs performed 1 year later

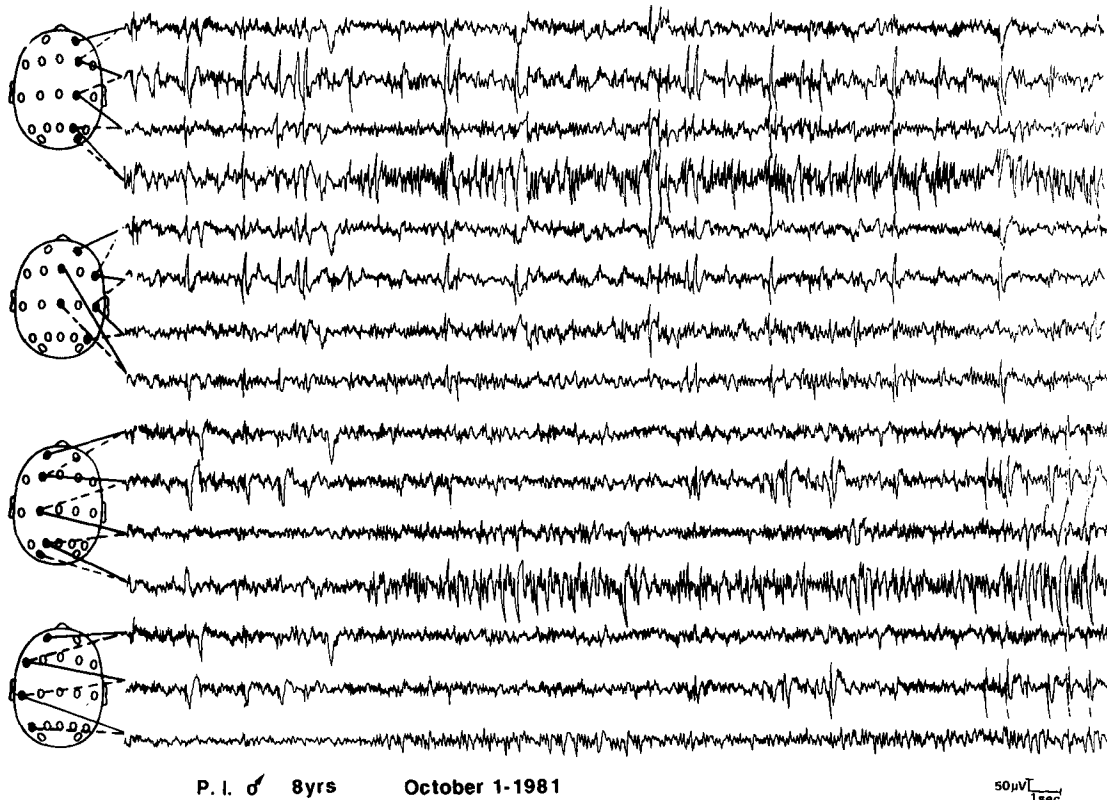


FIG. 2. EEG showing right discharges, prominent in the central area, and an asynchronous spike focus involving the left central and midtemporal regions.

were normal; in particular, N60 wave from the left median nerve stimulation was 21V.

Sleep-related left unilateral seizures persisted monthly until age 14 years, when epileptic attacks ceased abruptly. Right central spike focus also disappeared, whereas left centrottemporal discharges persisted transiently until age 15 years. Left arm deficit remained unchanged. Magnetic resonance imaging (MRI) showed right opercular macrogyria (Fig. 3). CT scan confirmed this finding. WAIS full-scale IQ was 97, verbal IQ was 97, and performance IQ was 98. Antiepileptic drugs (AEDs) were gradually discontinued at age 16 years, with no relapse.

DISCUSSION

The patient's epilepsy showed the electroclinical and evolutive patterns of BECTS. Epilepsy began in the first decade of life, after several febrile convulsions, and ceased around puberty (Lerman, 1985; Loiseau et al., 1988). Seizures were exclusively sleep-related, involved a hemiface or half of the body (Loiseau and Beaussart, 1973), and never entailed a persistent postictal deficit, even when they were long-lasting (Dalla Bernardina and Beghini, 1985). The patient had no intellectual deficit nor a history of antecedent illness. Interictal EEGs showed rolandic discharges increased by sleep (Dalla Bernardina and Beghini, 1985). SEPs showed giant evoked responses (Plasmati et al., 1990). The long duration of the active epilepsy and the frequent recurrence of the seizures could be considered atypical findings. Nevertheless, a long active period, although uncommon, was reported previously (Beaussart and Loiseau, 1973). BECTS is an age-related epileptic syndrome that tends to disappear at a certain age, regardless of age at on-

set. According to Loiseau et al., (1988) "the earlier the onset, the longer will be the active period." Epileptic seizures are usually rare, but frequent recurrence during all evolution of epilepsy appears to be a characteristic of several patients (Ambrosetto et al., 1987). Furthermore, the structural brain lesion could have influenced both duration of active epilepsy and frequency of seizure recurrence negatively.

The relationship between a structural brain lesion and an epileptic syndrome may be twofold, casual or causal. In an idiopathic epilepsy, such as BECTS, this association must necessarily be casual, and this is how the sporadically reported cases of BECTS and brain lesion have been interpreted (Mambelli et al., 1985, Santanelli et al., 1989). The major factor supporting this interpretation is that the brain lesions were seldom located in the rolandic area. The only two cases of BECTS and perirolandic lesion, a sylvian scissure enlargement (Morikawa et al., 1979) and a sylvian arachnoid cyst (Moscano et al., 1985) showed no concordance between focal brain damage and clinical seizures and/or interictal rolandic discharges. Thus, a particular brain lesion noted in BECTS patients is properly considered a fortuitous additional factor that may contribute to cause a hereditary predisposition to become a clinical condition by further lowering an already genetically low epileptogenic threshold (Santanelli et al., 1989).

In our patient, such an interpretation apparently is inapplicable for several reasons. First, the structural brain lesion was rolandic. Second, during 10 years of active epilepsy, motor ictal involvement was exclusively contralateral to the side of the opercular macrogyria, and a concordant EEG focus persisted for the same period of time. Third, a slight

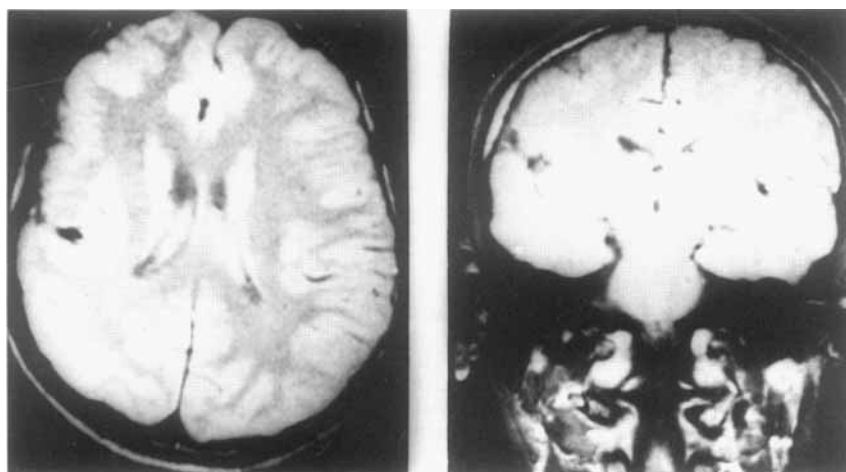


FIG. 3. Magnetic resonance imaging scan showing right hemisphere hypoplasia and thick and smooth cortex in right central region surrounding a large central sulcus. Less evident cortex abnormality extended to the right frontal and occipital areas.

neurologic deficit occurred, undoubtedly the result of the brain structural alteration. Finally, SEPs exploring the abnormal cortex function directly paralleled the clinical evolution, being giant during seizure recurrence and decreasing at neurologic deficit occurrence. Unlike the previously reported cases of brain-damaged BECTS patients, in our patient the opercular macrogyria is apparently an acceptable causal factor of epilepsy.

Opercular macrogyria is usually related to intractable epilepsy, mental retardation, and dysarthria. The attempt to explain why in our patient a BECTS-like epilepsy was sustained is open to speculation. Reported epileptic patients with opercular macrogyria usually had bilateral lesions that might have aggravated their clinical condition (Kuzniecky et al., 1989; Becker et al., 1989). Nevertheless, similarities exist between BECTS and opercular macrogyria-related epilepsy. The characteristic sleep-related oral motor seizures of BECTS have also been reported in patients with bilateral central macrogyria (Ambrosetto and Tassinari, 1990). Inversely, atonic drop attacks, a predominant epileptic pattern in bilateral central macrogyria (Kuzniecky et al., 1989) have been described in patients with BECTS when the ictal rolandic discharge immediately spreads to the contralateral homologous area (Kanazawa and Kawai, 1990).

Hereditary predisposition is a crucial factor in the etiology of idiopathic epilepsies. Genetic studies confirmed an autosomal-dominant genetic trait with age-dependent penetrance in BECTS (Bray and Wiser, 1965; Heijbel et al., 1975). Genetic and/or chromosomal causes also affect neuronal migration (Barth, 1987) and bilateral opercular macrogyria has been reported in identical twins (Graff Radford et al., 1986).

To our knowledge, neuronal migration disorders (NMDs) have never been previously reported in relation to a BECTS-like epilepsy, perhaps because neuroradiologic procedures are considered unnecessary in BECTS children and CT studies consequently are scarce. Nevertheless, CT scan is probably performed if a particular patient shows atypical features such as persistent seizure recurrence and/or long active epilepsy duration, as did our patient. Thus, this case report is probably exceptional in this respect, and we do not recommend further CT studies in BECTS. On the contrary, MRI studies are completely lacking in BECTS. MRI is known to be superior to CT in detecting minimal cortical lesions (Heinz et al., 1988). We believe that MRI studies in BECTS patients might be helpful in disclosing further underlying structural lesions in cases

of apparently idiopathic epilepsy. Unfortunately, MRI is an expensive technique and requires anesthesia in children. Furthermore, patients in whom BECTS is a transient expression of a lesional epilepsy are rare (Ambrosetto and Gobbi, 1975). Therefore, MRI examination is indicated only when a patient's clinical picture is unusual.

If further similar cases are reported, pathologic studies in BECTS, even if extremely difficult to obtain, are crucial to elucidate the pathophysiology of idiopathic partial epilepsies. In a study of neuropathologic findings (Meencke and Janz, 1984), 7 of 8 patients with idiopathic generalized epilepsy had marked cerebral microdysgenesis with varying diffuse distribution. It is logical that the same maturation disturbance with focal distribution is the morphologic substrate of the underlying functional disorder in idiopathic partial epilepsies.

REFERENCES

- Ambrosetto G, Gobbi G. Benign epilepsy of childhood with rolandic spikes, or a lesion? EEG during a seizure. *Epilepsia* 1975;16:793-6.
- Ambrosetto G, Giovanardi Rossi P, Tassinari CA. Predictive factors of seizure frequency and duration of antiepileptic treatment in rolandic epilepsy: a retrospective study. *Brain Dev* 1987;9:300-4.
- Ambrosetto G, Tassinari CA. Sleep-related focal motor seizures in bilateral central macrogyria. *Ann Neurol* 1990;28:840-1.
- Barth PG. Disorders of neuronal migration. *Can J Neurol Sci* 1987;14:1-16.
- Beaussart M, Loiseau P. Evolution et pronostic de l'épilepsie à paroxysmes rolandiques. In: Lugaresi E, Pazzaglia P, Tassinari CA, eds. *Evolution and prognosis of epilepsies*. Bologna: A. Gaggi, 1973:215-28.
- Becker PS, Dixon AM, Troncoso JC. Bilateral opercular polymicrogyria. *Ann Neurol* 1989;25:90-2.
- Bray PF, Wiser WC. Hereditary characteristics of familial temporal-central focal epilepsy. *Pediatrics* 1965;36:207-11.
- Commission on Classification and Terminology of the International League Against Epilepsy. Proposal for revised classification of epilepsies and epileptic syndromes. *Epilepsia* 1989;30:389-99.
- Dalla Bernardina B, Beghini G. Rolandic spikes in children with or without epilepsy (20 subjects polygraphically studied during sleep). *Epilepsia* 1975;16:497-501.
- Dalla Bernardina B, Chiamenti C, Capovilla G, et al. Benign partial epilepsies in childhood. In: Roger J, Dravet C, Bureau M, Dreifuss FE, Wolf P, eds. *Epileptic syndromes in infancy, childhood and adolescence*. London: John Libbey Eurotext, 1985:137-49.
- Graff Radford NR, Bosch EP, Stears JC, et al. Developmental Foix-Chavany-Marie syndrome in identical twins. *Ann Neurol* 1986;20:632-5.
- Heijbel J, Blom S, Rasmuson M. Benign epilepsy of childhood with centro-temporal EEG foci: a genetic study. *Epilepsia* 1975;16:285-93.
- Heinz ER, Heinz TR, Radtke R, et al. Efficacy of MR vs CT in epilepsy. *AJNR* 1988;9:1123-8.
- Kanazawa O, Kawai I. Status epilepticus characterized by repetitive asymmetrical atonia: two cases accompanied by partial seizures. *Epilepsia* 1990;31:536-43.
- Kuzniecky R, Andermann F, Tampieri D, et al. Bilateral central

- macrogyria: epilepsy, pseudobulbar palsy and mental retardation—a recognizable neuronal migration disorder. *Ann Neurol* 1989;25:547–54.
- Lerman P. Benign partial epilepsy with centro-temporal spikes. In: Roger J, Dravet C, Bureau M, Dreifuss FE, Wolf P, eds. *Epileptic syndromes in infancy, childhood and adolescence*. London: John Libbey Eurotext, 1985:153–62.
- Loiseau P, Beaussart M. The seizures of benign childhood epilepsy with rolandic paroxysmal discharges. *Epilepsia* 1973; 14:381–9.
- Loiseau P, Duche B, Cordova S, et al. Prognosis of benign childhood epilepsy with centrottemporal spikes: follow up study of 168 patients. *Epilepsia* 1988;29:229–35.
- Mambelli M, Moscano FC, Masoni P. Epilessia rolandica: considerazioni su una casistica di 40 bambini. *Boll Lega It Epil* 1985;51/52:79–80.
- Meencke HS, Janz D. Neuropathological findings in primary generalized epilepsy: a study of eight cases. *Epilepsia* 1984; 25:8–21.
- Morikawa T, Osawa T, Ishihara O, et al. A reappraisal of benign epilepsy of children with centro-temporal EEG foci. *Brain Dev* 1979;1:257–65.
- Moscano FC, Mambelli M, Masoni P, et al. Epilessia rolandica associata a cisti leptomeningea. *Boll Lega It Epil* 1985;51/ 52:81–2.
- Plasmati R, Michelucci R, Salvi F, et al. Giant somatosensory responses evoked by electrical and mechanical stimulation in idiopathic epilepsies of childhood [Abstract]. *Neurology* 1990;40(suppl 1):320.
- Santanelli P, Bureau M, Magaouda A, et al. Benign partial epilepsy with centrottemporal (or Rolandic) spikes and brain lesion. *Epilepsia* 1989;30:182–8.

RÉSUMÉ

Les auteurs rapportent l'observation d'un jeune homme intellectuellement normal, âgé de 18 ans, qui présentait de fréquentes crises brachio-faciales gauches ou motrices, ayant débuté à l'âge de 4 ans, et ayant cessé dix ans plus tard. Les crises survenaient uniquement pendant le sommeil. Il n'y avait pas eu de rechute après l'arrêt des médicaments antiépileptiques. Une discrète parésie du membre supérieur gauche et une astéréognosie de la main gauche avaient été constatées à l'âge de 10 ans. Les EEG de veille montraient la persistance de décharges rolandiques droites, augmentées par le sommeil. Les potentiels évoqués somatosensitifs étaient géants après stimulation du nerf médian gauche. La tomodensitométrie et l'IRM ont mis en évidence une macrogyrie operculaire droite. Les auteurs suggèrent que la lésion structurelle était responsable de cette épilepsie partielle "idiopathique". D'autres observations similaires et des études neu-

ropathologiques pourront élucider le substratum morphologique du désordre fonctionnel sous-jacent aux épilepsies partielles idiopathiques.

(P. Genton, Marseille)

RESUMEN

Un muchacho epiléptico de 18 años de edad y mentalmente normal padecía ataques frecuentes que afectaban al brazo y la cara del lado izquierdo o ataques motores unilaterales que empezaron a la edad de 4 años y cesaron diez años más tarde. Los ataques se producían exclusivamente durante el sueño. No se observó una reaparición de los ataques tras la interrupción de la medicación antiépileptica (AED). A la edad de 10 años se observó una ligera paresia del brazo izquierdo y una astereognosia de la mano izquierda. Los EEGs en vigilia mostraron descargas rolandicas persistentes en el lado derecho que se incrementaron durante el sueño. Los potenciales evocados somatosensoriales (SEPs) fueron gigantes tras la estimulación del nervio mediano. La tomografía computerizada (CT) y la Resonancia Magnética (MRI) mostraron una macrogyria opercular derecha. Se sugiere que esta lesión estructural cerebral esta relacionada causalmente con esta "idiopática" epilepsia parcial. Casos semejantes y estudios patológicos podrán, en un futuro, aclarar los substratos morfológicos de las alteraciones funcionales subyacentes en epilepsias parciales idiopáticas.

(A. Portera-Sánchez, Madrid)

ZUSAMMENFASSUNG

Ein 18 jähriger intellektuell unbeeinträchtiger Junge litt unter häufigen linksseitigen brachio-facialen oder unilateralen motorischen Anfällen, die mit 4 Jahren begonnen hatten und 10 Jahre später aufhörten. Es handelte sich ausschließlich um schlafgebundene Anfälle. Der Medikamentenreduktion folgte kein weiterer Anfall. Mit 10 Jahren trat eine leichte Armparese links mit Astereognosie der Hand auf. Die Wach-EEGs zeigten konstant rechtsseitig rolandische Entladungen, die sich im Schlaf vermehrten. Die somatosensorischen evozierten Potentiale waren bei linksseitiger Medianus-Stimulation riesig. Im Computertomogramm und im NMR fand sich eine operkulare Makrogyrie rechts. Wir vermuten, daß die strukturelle Hirnläsion ursächlich für diese sonst idiopathische Patialepilepsie verantwortlich war. Weitere Fallberichte und pathologische Untersuchungen könnten das morphologische Substrat der unterliegenden funktionellen Störungen bei der idiopathischen Patialepilepsie klären.

(C. G. Lipinski, Heidelberg/Neckargemünd)