

Slowly progressive familial dementia with recurrent strokes and white matter hypodensities on CT scan

Salvi F.*, Michelucci R.*, Plasmati R.*, Parmeggiani L.*, Zonari P.*, Mascalchi M.**, Tassinari C.A.*

* Clinica Neurologica Università di Bologna, Ospedale Bellaria, Bologna

** Dipartimento di Scienze Neurologiche, Università di Firenze

We describe 2 normotensive sisters presenting slowly progressive dementia associated with acute or subacute focal neurological symptoms, unilateral or bilateral motor signs, and dysarthria. Their father, who died in the seventh decade, had a similar clinical picture. Computerized axial tomography (CT) scan of the head showed symmetrical hypodensities in the periventricular white matter and mild to moderate hydrocephalus. In these patients a diagnosis of Binswanger's disease was based on the clinical features supported by white matter changes on CT scan. Our study suggests that genetic factors may play a role in the etiology of Binswanger's disease.

Key Words: Hereditary cerebrovascular disease — Binswanger disease — vascular dementia

Introduction

Vascular dementias (multi-infarct dementia, lacunar state, cerebral amyloid angiopathy, subcortical arteriosclerotic encephalopathy or Binswanger disease) usually occur sporadically in elderly hypertensive patients. However, rare instances of pathologically confirmed hereditary multi-infarct dementia and Binswanger disease (BD) in young and normotensive cases have been reported [9-19-23-24]. The present study describes a family in which two normotensive siblings had clinical and radiological features consistent with the diagnosis of BD and the father of the probands also had chronic vascular dementia.

Materials

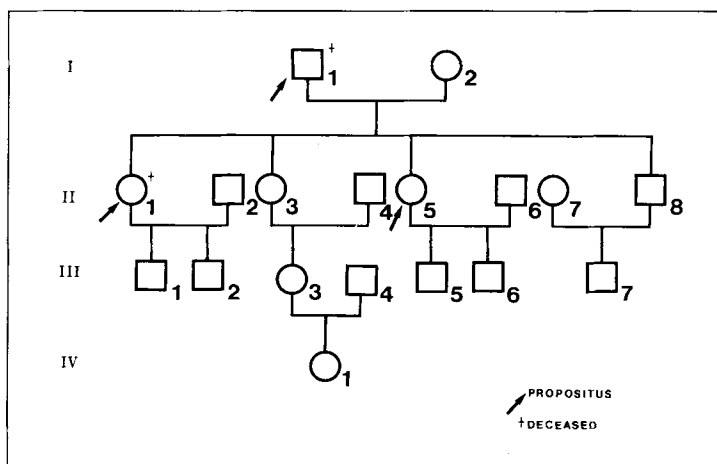
The pedigree of the family we studied is shown in Fig. 1. The genealogical tree includes three affect-

ed members: two of them are sisters (cases II-1 and II-5) who have been extensively studied clinically and radiologically, and the other is their father (case I-1) whose clinical history was obtained from past medical records and interviews with other family members. All patients had similar symptoms and the course of the disease showed relatively little variations from one case to another.

Case reports

Case I-1 was first admitted to the Institute of Clinical Neurology, Bologna, in 1966 at age 61 with a 24-hours history of headache, vomiting, dysarthria, right hemiparesis, and urinary incontinence. Neurological examination was unremarkable except for a mild right hemiparesis, increased tendon reflex on the right side, and a right extensor plantar response. He partially recovered from the deficits over a 3-week period. In

Fig. 1. Family pedigree.



1967 he presented another acute episode of headache, vertigo, and marked dysarthria, from which he totally recovered.

During the following four years, his mental status progressively deteriorated and revealed a particularly severe amnesia, disorientation in time and space, abulia, and dysphoria. In 1971 he was readmitted to the hospital because of history of

gait disturbance with frequent falls and urinary incontinence that developed over a 2-week period.

On neurological examination, he had evidence of dementia and bilateral pyramidal signs in the upper and lower extremities. In 1974, the patient died from circulatory shock at age 69. An autopsy was not performed.

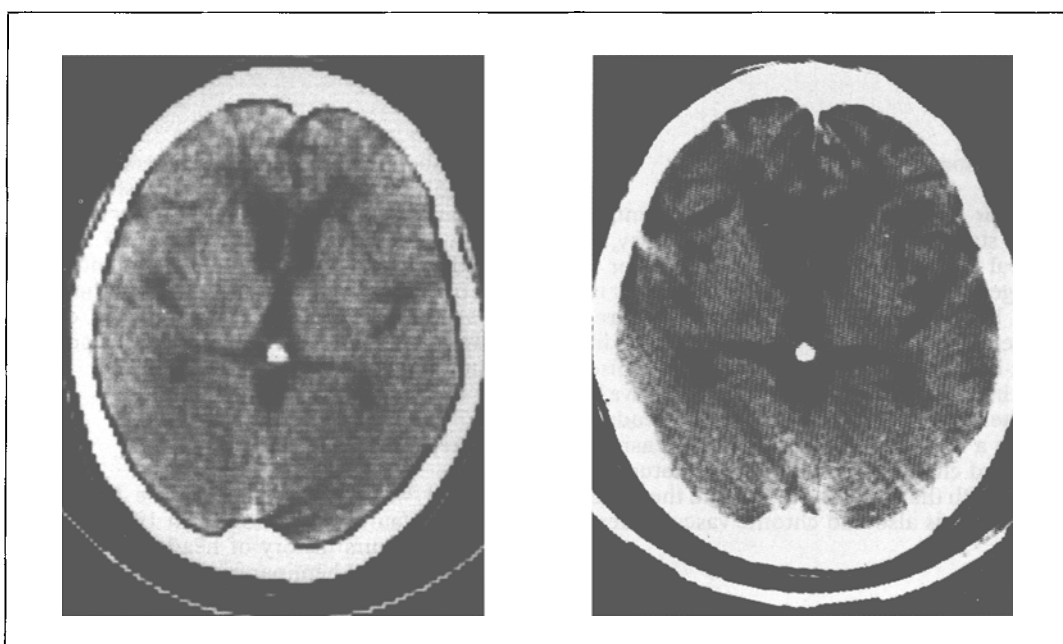


Fig. 2. Case II-1. CT scan of the brain at the age of 38 (2A) and 42 (2B). Periventricular white matter lucencies increased in size over time. At 42 a marked ventricular enlargement is present.

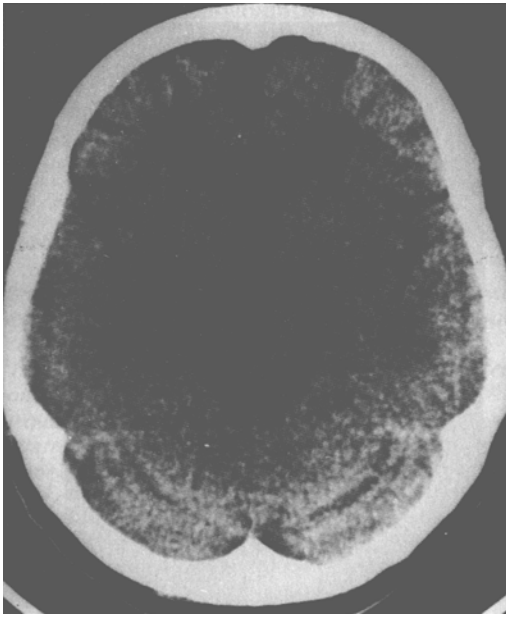


Fig. 3 Case II-5. CT images at the age of 49. White matter hypodensities around the frontal horn of the lateral ventricles.

Case II-1 was a 38-year-old woman who was first seen in May 1983 because of a 6-month history of rapidly progressive dementia. There was no past medical history of arterial hypertension or cardiovascular disease. On admission, mental status examination revealed a severe recent memory loss and a disorientation to time, space, and person.

Neurological examination was unremarkable except for a vertical nystagmus. Blood pressure was normal. Routine hematological and biochemical tests were normal and serology for syphilis was negative. Serum and urine aminoacids, urinary mucopolysaccharides and oligosaccharides and determination of the activity of lysosomal enzymes in the white cells were normal. The following tests were normal: electrocardiogram (ECG), electroencephalogram (EEG), electromyogram (EMG), and duplex ultrasonographic scanning of the carotid and vertebral arteries. Computerized tomography (CT) scan of the head showed a mild ventricular dilatation and diffuse, symmetrical hypodensities in the white matter of both hemispheres mainly localized in the frontal and occipital periventricular areas (Fig. 2A). An isotope cisternogram was normal. During the following 8 months, she presented a progressive deterioration of mental functions. On readmission to the hospital in February 1984, blood pressure was occasionally

mildly elevated with recordings up to 175/95 mmHg. On examination, she had a mild right hemiparesis and frontal lobe symptoms characterized by a marked apathy, dysphoria, bulimia, and urinary incontinence. CT scan of the head showed an extension of the white matter hypodense areas. On May 1985, she was seen at the outpatient clinic because of a progressive onset of left hemiparesis, which recovered partially over a 1-month period. In the following months, she gradually developed gait impairment with frequent falls. She also had dysphagia, dysarthria, urinary incontinence, and episodes of pathological crying and laughing. On admission in January 1987, she was mute and could follow only simple commands. On examination, a vertical nystagmus and bilateral pyramidal signs were noted and she was totally unable to walk. A third CT scan of the head revealed further enlargement of the ventricles (Fig. 2B). Over the following 8 months, there was some improvement of the pseudobulbar and pyramidal signs but the intellectual impairment remained unchanged. The patient died from pneumonia in July 1988 at the age 43. Permission for autopsy was refused.

Case II-5 was a 49-year-old woman who was first admitted to the hospital in June 1986 because of an acute onset of dysarthria and left hemiparesis. Blood pressure was normal. Head CT scan revealed white matter hypodensities in the frontal periventricular region (Fig. 3). Her symptoms partially improved within a few days. In December 1986, the patient was readmitted because of mood changes and intellectual deterioration. On mental examination, she was disoriented to time, space, and person and she had memory deficits. Neurological examination showed that she had dysphoria, dysarthria hypomimia, and brisk deep tendon reflexes but her gait was normal. Routine hematological and biochemical tests were normal and serology for syphilis was negative. Serum and urine aminoacids, urinary mucopolysaccharides and oligosaccharides, leukocyte arylsulfatase. A level, and determination of lysosomal activity in the white blood cells were normal. Screening for serum transthyretin (TTR) protein according to a previously described technique [1] was negative. The following tests were also normal: ECG, EMG, and duplex ultrasonographic scanning of the carotid and vertebral arteries. The EEG showed an excess of theta activity over the frontal and temporal regions bilaterally. A second CT scan of the head revealed an increase in the periventricular white matter hypodensities. Nuclear magnetic resonance (NMR) imaging showed signal hyperintensity of almost the entire cerebral white matter on T2 weighted images (Fig. 4A). Small areas of lucency lacunae were also evident in the basal ganglia

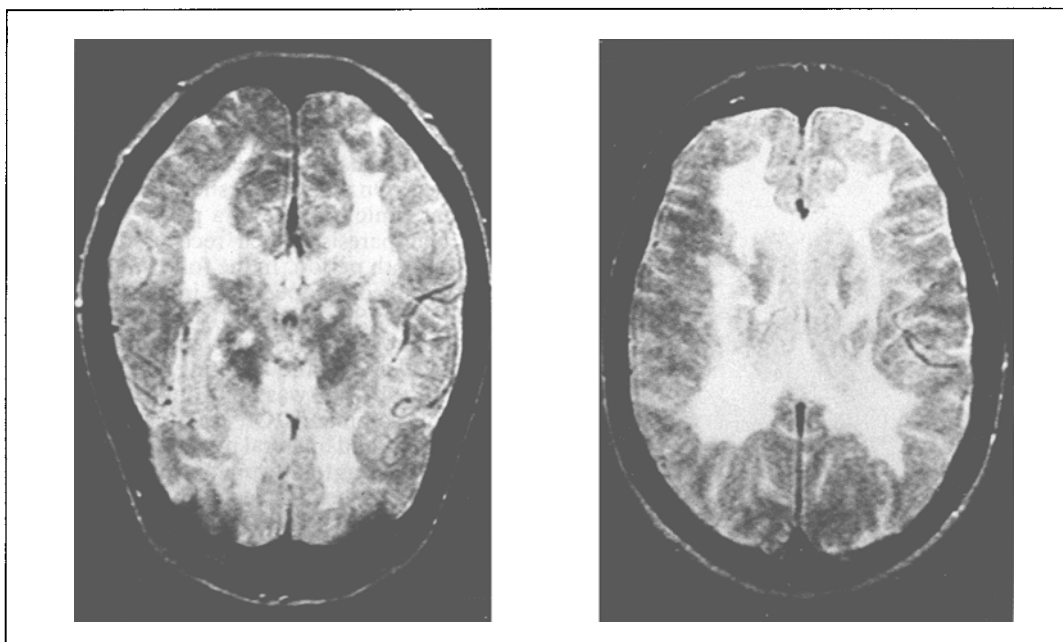


Fig. 4 Case II-5. NMR of the head at the age of 50. T2 weighted images. Diffuse involvement of the white matter (4A) associated with areas of increased signal in the basal ganglia (4B).

and thalamus (Fig. 4B). An isotope cisternogram was normal. Over the following year, she showed slight progression of the intellectual impairment.

Discussion

A clinical picture of slowly evolving dementia occurring in adult patients and associated with recurrent stroke-like episodes, subacute accumulation of focal deficits, dysarthria and deterioration of gait and sphincter control — as encountered in our cases — clearly suggests the diagnosis of vascular dementia. This term is currently used to designate a few clinical entities with distinctive pathological findings, such as multi-infarct dementia (MID), lacunar state, and subcortical arteriosclerotic encephalopathy or Binswanger disease (BD) [2, 4, 5, 6, 15, 16, 17, 21, 37]. In the present study pathological verification was not available and, therefore, no definite proof of any of these entities was reached. BD seemed however the most probable diagnosis owing to the neuroradiological findings of diffuse periventricular white matter involvement and subcortical lacunae, as previously stressed in DB by several investigators [5, 14, 18, 20, 22, 26]. A variety of different conditions with similar CT findings (such as normal pressure hydrocephalus,

chronic progressive multiple sclerosis, leukodystrophies, cerebral edema, watershed cerebral infarction in the distribution of the carotid arteries, progressive multifocal leukoencephalopathy, acute disseminated encephalomyelitis, methotrexate white matter necrosis, and hypertensive encephalopathy) were excluded in our cases because of different clinical pictures and negative complementary laboratory findings. Two main features in our patients are quite unusual in vascular dementia and warrant special emphasis: the familial occurrence and the absence of hypertension. Maeda et al. [19] first published the cases of two young normotensive Japanese brothers with autopsy proven BD. Since then, two further pairs of siblings with verified BD were described by Friedland et al. [9] and two large families with so-called “hereditary MID” were extensively reported by Sourander and Walider [24] and Sonninen and Savontaus [23]. All these cases have common clinical features, including young age at onset and absence of arterial hypertension. The familial occurrence of vascular dementia, as observed in our cases, calls for differential diagnosis from hereditary cerebral amyloid angiopathies. These include a form with recurrent cerebral hemorrhages, mainly described in Iceland [7, 8, 11, 12, 13], and also a variety defined under the heading of “familial oc-

loleptomeningeal amyloidosis" [10] with associated TTR accumulation [25]. In our patients cerebral hemorrhages were not detected and TTR serum typing was negative. In summary, we report 3 members of a family who had a vascular dementia and whose clinical and radiological features resembled BD. Our findings along with

scattered reports of similar families in the literature [9, 19, 23, 24], suggest that the role of genetic factors in vascular dementias may be more important than previously recognized. The absence of hypertension and early age at onset in patients with suspected vascular dementia should warrant further family inquiry.

Sommario

Descriviamo due giovani sorelle normotese affette da demenza lentamente progressiva associata a sintomi neurologici focali ad insorgenza sia acuta che subacuta. Un quadro clinico simile era presente nel padre deceduto all'età di 70 anni.

La TAC cranica mostrava nelle due pazienti ipodensità simmetriche della sostanza bianca periventricolare con idrocefalo moderato.

In questi pazienti una diagnosi di malattia di Binswanger fu fatta in base al quadro clinico ed alle lesioni riscontrate alla TAC. Il nostro studio dimostra la possibilità che fattori genetici siano responsabili di alcune forme di malattia di Binswanger soprattutto in pazienti normotesi, giovani e senza fattori di rischio per malattie cerebrovascolari.

Address reprint requests to:

Dr. Fabrizio Salvi

Divisione di Neurologia

Ospedale Bellaria

Via Altura 3 - 40139 Bologna

References

- [1] ALTLAND K., BEKER P., BARZOFF A.: *Paraffin oil protected high resolution hybrid isoelectric focusing for the demonstration of substitutions of neutral aminoacids in denaturated proteins: the case of four human transthyretin (prealbumin) variants associated with familial amyloidotic polyneuropathy*. Electrophoresis 8:293-297, 1987
- [2] BABIKIAN V., ROPPER A.H.: *Binswanger's disease: a review*. Stroke 18:2-12, 1987
- [3] BIEMOND A.: *On Binswanger's subcortical arteriosclerotic encephalopathy and the possibility of its clinical recognition*. Psychiat Neurol Neurosurg 73:413-417, 1970
- [4] BINSWANGER A.: *Die abgrenzung der allgemeinen progressiven paralys.* Ber Klin Wochenschr 31:1103-1105, 1137-1139, 1180-1186, 1894.
- [5] BOGUCKI A., PAJERZ W., SZYMANSKA R., STANIASZCZYK R.: *Cerebral amyloid angiopathy with attenuation of the white matter on CT scans: subcortical arteriosclerotic encephalopathy (Binswanger) in a normotensive patient*. J Neurol 235:435-437, 1988.
- [6] CAPLAN L.R., SCHOENE W.C.: *Clinical features of subcortical arteriosclerotic encephalopathy (Binswanger disease)*. Neurology 28:1206-1215, 1978.
- [7] COHEN D.H., FEINER H., JENSSON O., FRANGIONE B.: *Amyloid fibril in hereditary cerebral hemorrhage with amyloidosis (HCHWA) is related to the gastroentero-pancreatic neuroendocrine protein gamma trace*. J Exp Med 158:623-628, 1983.
- [8] COSGROVE G.R., LEBLANC R., MEAGHER-VILLEMURE K., ETHIER R.: *Cerebral amyloid angiopathy*. Neurology 35:625-631, 1985.
- [9] FRIEDLAND R.P., KOSS E., JAGUST W.J., BORCICH J.: *Familial subcortical arteriosclerotic encephalopathy (SAE) in two families: studied with X-Ray CT, NMR, and PET*. Neurology 36 (Suppl. 1): 102, 1986.
- [10] GOREN H., STEINBERG M.C., FARBOODY G.M.: *Familial oculoleptomeningeal amyloidosis*. Brain 103:473-495, 1980.
- [11] GRAY F., DUBAS F., ROUILLET E., ESCOUROLLE R.: *Leukoencephalopathy in diffuse hemorrhagic cerebral amyloid angiopathy*. Ann Neurol 18:54-59, 1985.
- [12] GRIFFITHS R.A., MORTIMER T.F., OPPENHEIMER D.R., SPALDING J.M.K.: *Congophilic angiopathy of the brain: a clinical and pathological report on two siblings*. J Neurol Neurosurg Psychiat 45:396-408, 1982.
- [13] GUDMUNDSSON G., HALLGRIMSSON J., JONASSON T.A., BJARNASON O.: *Hereditary cerebral hemorrhage with amyloidosis*. Brain 95:387-404, 1972.
- [14] JUNCCK L., HERRICK M.K., LANGSTON J.W.: *CT scan in subcortical arteriosclerotic encephalopathy*. Neurology 30:791-792, 1980.
- [15] KINKEL W.R., JACOBS L., POLACHINI I., BATES V., HEFFNER R.R.: *Subcortical arteriosclerotic encephalopathy (Binswanger's encephalopathy)*. Arch Neurol 42:951-959, 1985.
- [16] LADURNER G., SAGER W.D., ILIFF L.D., LECHNER H.: *A correlation of clinical findings and CT in ischemic cerebrovascular disease*. Eur Neurol 18:281-288, 1979.

- [17] LOIZOU L.A., JEFFERSON J.M., THOMAS SMITH W.T.: *Subcortical arteriosclerotic encephalopathy (Binswanger's type) and cortical infarcts in a young normotensive patient*. J Neurol Neurosurg Psychiatry 45:409-417, 1982.
- [18] LOIZOU L.A., KENDALL B.E., MARSHALL J.: *Subcortical arteriosclerotic encephalopathy: a clinical and radiological investigation*. J Neurol Neurosurg Psychiatry 44:294-304, 1981.
- [19] MAEDA S., NAKAYAMA H., ISAKA K., AIHARA Y., NEMOTO S.: *Familial unusual encephalopathy of Binswanger's type without hypertension*. Folia Psychiatri Neurol Japonica 30:165-177, 1976.
- [20] MASCALCHI M., INZITARI D., DAL POZZO G., TAVERINI N., ABBAMONDI A.L.: *Computed tomography, magnetic resonance imaging and pathological correlations in a case of Binswanger's disease*. Can J Neurol Sci 16:214-218, 1989.
- [21] OLSZEWSKI J.: *Subcortical arteriosclerotic encephalopathy*. World Neurol 3:359-375, 1962.
- [22] ROSENBERG G.A., KORNFELD M., STOVRING J., BICKNELL J.M.: *Subcortical arteriosclerotic encephalopathy (Binswanger): computerized tomography*. Neurology 29:1102-1106, 1979.
- [23] SONNINEN V., SAVONTAUS M.L.: *Hereditary multi-infarct dementia*. Eur Neurol 27:209-215, 1987.
- [24] SOURANDER P., WALIDER J.: *Hereditary multi-infarct dementia*. Acta Neuropath 39:247-254, 1977.
- [25] UTTI R.J., DONAT J.R., ROZDILSKY B., SCHNEIDER R.J., KOEPPEN A.H.: *Familial oculoleptomeningeal amyloidosis - report of a new family with unusual features*. Arch Neurol 45:1118-1122, 1988.
- [26] ZEUMER H., SCHONSKY B., STURM K.W.: *Predominant white matter involvement in subcortical arteriosclerotic encephalopathy (Binswanger's disease)*. J Comput Assist Tomogr 4:14-19, 1980.