

Collaboration of a dentist and speech-language pathologist in the rehabilitation of a stroke patient with dysarthria: a case study

Takahiro Ono¹, Mari Hamamura², Kosuke Honda³ and Takashi Nokubi¹

¹Division of Oromaxillofacial Regeneration, Osaka University Graduate School of Dentistry, Suita; ²Division of Speech and Language Rehabilitation, Arima Onsen Hospital, Kobe; ³Department of Dentistry and Oral Surgery, Hyogo College of Medicine, Nishinomiya, Japan

Gerodontology 2005; **22**: 116–119

Collaboration of a dentist and speech-language pathologist in the rehabilitation of a stroke patient with dysarthria: a case study

Objective: To elucidate the effectiveness of the collaboration of a dentist and speech-language pathologist (SLP) in the rehabilitation of a stroke patient with dysarthria.

Design: A clinical case report treated in the rehabilitation hospital and dental surgery.

Subject: A 71-year-old Japanese man who was admitted to the rehabilitation hospital for speech rehabilitation 2 years and 5 months after a stroke.

Methods: Provision of prosthesis (palatal lift prosthesis + palatal augmentation prosthesis) for improving velopharyngeal incompetence (VPI) and articulation by dentist, and speech behavioural management by SLP including self-monitoring and bio-feedback training using the See-Scape.

Results: Speech behavioural management proved useful for promoting improvement in speech intelligibility to a functionally sufficient level after improving VPI by prosthesis.

Conclusion: The collaborative efforts of the dentist and SLP in the rehabilitation of post-stroke patients with velopharyngeal incompetence should be encouraged.

Keywords: stroke, dysarthria, palatal lift prosthesis, palatal augmentation prosthesis.

Accepted 25 January 2005

Introduction

Many patients experience swallowing^{1,2} and speech³ dysfunction caused by oral motor disorder as a consequence of cerebral vascular disease. Dentists who treat stroke patients sometimes find it difficult to improve oral function through the use of a normal prosthesis. In recent years, these patients have been helped by the placement of prostheses designed especially for rehabilitation use, such as the palatal lift prosthesis (PLP)^{4,5}, palatal augmentation prosthesis (PAP)⁶ and combination of both prostheses⁷. However, there have been few reports on the effectiveness of collaboration between dentists and speech-language pathologists (SLP) in the field of speech and dysphagia rehabilitation of stroke patients.

This paper describes the rehabilitation of a dysarthric post-stroke patient with severe velopharyngeal incompetence (VPI) through the collaborative efforts of a dentist and an SLP. The palatal lift section was applied to the duplicated maxillary denture and then the palatal augmentation section was added to the hard palate of PLP. Successful outcome was provided by speech behavioural management following these prosthetic treatments.

ryngeal incompetence (VPI) through the collaborative efforts of a dentist and an SLP. The palatal lift section was applied to the duplicated maxillary denture and then the palatal augmentation section was added to the hard palate of PLP. Successful outcome was provided by speech behavioural management following these prosthetic treatments.

Case report

The patient was a 71-year-old Japanese man who was admitted to the rehabilitation unit of Arima Onsen Hospital (Kobe, Hyogo Prefecture, Japan) for speech rehabilitation 2 years and 5 months after a stroke. On initial assessment, he was diagnosed with moderate to severe dysarthria, slight dysphagia, ataxic hemiplegia and spastic gait. He had sufficient cognitive ability to actively participate in the rehabilitation and sufficient auditory

awareness and discrimination to monitor his own speech.

Initial assessment of continuous speech by the SLP indicated that the severe VPI was resulting in maladaptive compensatory strategies, such as excessive loudness or sudden forced inspiration, which reduced clarity of speech by the interruption of voice and articulation. The patient was introduced to the dentist for fabrication of the PLP to improve velopharyngeal closure and minimise nasal emission during speech and the SLP was present at each visit.

Treatment

For the first step in fabricating the PLP, the patient's existing maxillary complete denture was duplicated by using acrylic resin. The duplicate denture was placed on the maxilla, and a pick-up impression was taken using a modified impression tray, which covered the maxillary denture and soft palate, for fabricating the working cast. The initial shape of the palatal lifting section was formed by using a transparent self-polymerising resin (Unifast; GC Co., Tokyo, Japan) directly on the working cast where the soft palate had been slightly lifted up during impression taking. It was then attached to the duplicate denture on the cast. During the trial of the prosthesis, the effect of raising the soft palate on speech intelligibility was evaluated, and the dentist adjusted the angle of lift, if necessary, by applying self-polymerising resin. Despite the opposing force from the lifted soft palate, retention of the prosthesis was sufficient such that it remained seated even at maximum mouth opening (Fig. 1).

The mirror fogging test revealed improved velopharyngeal closure when using the PLP (Fig. 2). Reduced nasal emission in the continuous pro-

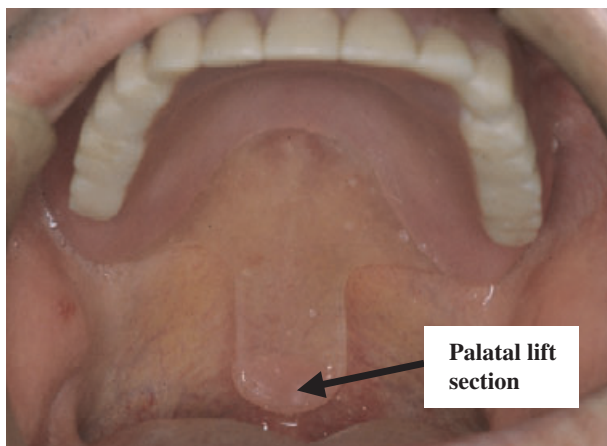


Figure 1 Trial of palatal lift section.

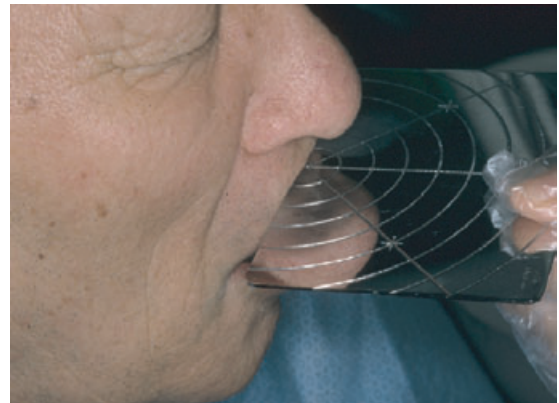

Figure 2 Mirror fogging test to assess velopharyngeal competency.

duction of 'a' was shown by a change on the 8-point scale from 4 to 2 on the right side and from 3.5 to 2 on the left side. Although a score of 2 represents slight nasal emission, maximum phonation duration was prolonged from 15 sec to 19 sec, and the Japanese monosyllable intelligibility score increased from 83% to 93%.

Radiographic evaluation in the lateral projection also showed a positive effect of the PLP on the resting position of the soft palate (Fig. 3). The incompetent soft palate dropped in the normal rest position and velopharyngeal closure during speech or swallowing was not possible with the residual ability. Placement of the PLP allowed an adequate velopharyngeal closure.

At the first follow-up visit 1 week after placement of the PLP, the angle and shape of the palatal lifting section was adjusted according to the patient's difficulties in swallowing saliva. The mucosal surface of palatal lift section was carefully removed little by little. Twelve weeks after starting prosthetic treatment, the patient left the rehabilitation hospital as swallowing had improved and any problem of drinking water when using the PLP had been overcome.

At the next step, the palatal surface was reshaped to improve articulation and swallowing by facilitating contact with the tongue. A tongue impression during articulation and swallowing was taken on the palatal surface of the prosthesis using soft paraffin wax (Soft Wax; GC Co.). Based on this tongue impression, an additional palatal augmentation section was polymerised using self-polymerising resin to provide sufficient thickness to the palatal surface for functional tongue-palate contact. Figure 4 shows the reshaped palatal surface and the palatal lift section viewed distally.

After reshaping the prosthesis, the patient was re-admitted to the rehabilitation hospital for

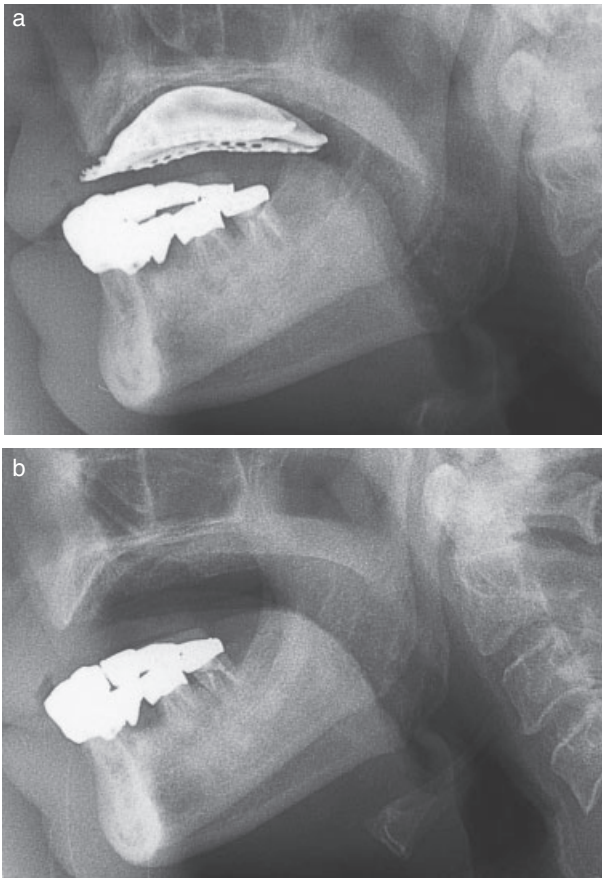


Figure 3 Radiographic evaluations in the lateral projection of soft palate in resting position. (a) Wearing maxillary denture. (b) Wearing palatal lift prosthesis (note the lifted soft palate).

speech-language rehabilitation, with the aim of improving the intelligibility of continuous speech. During hospitalisation, speech behavioural management was undertaken with the SLP three times

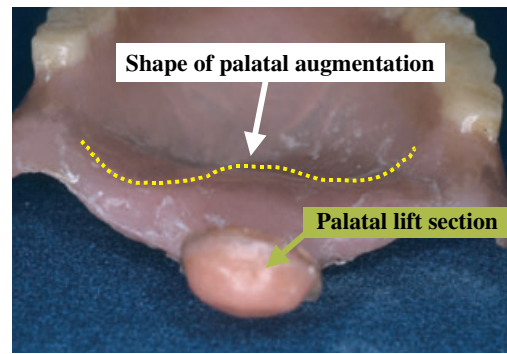


Figure 4 Reshaped palatal surface and palatal lift section viewed distally.

Table 1 The 9-point rating scale of the Japanese conversational speech intelligibility test⁸.

Scale 1	Intelligible
Scale 2	Occasionally unintelligible
Scale 3	Understandable if the topic is known
Scale 4	Occasionally intelligible
Scale 5	Unintelligible

Half scores can be assigned (e.g. 1.5).

per a week over a 3-month period. Therapy comprised two methods: training for self-monitoring to improve intelligibility when reading text or conversation; and bio-feedback training using the See-Scape (Pro-Ed, Austin, TX, USA) to improve the speed and accuracy of velopharyngeal closure.

Evaluation of speech

The Japanese single word intelligibility score, as judged by three healthy volunteers who were all university graduates, increased from 58% before

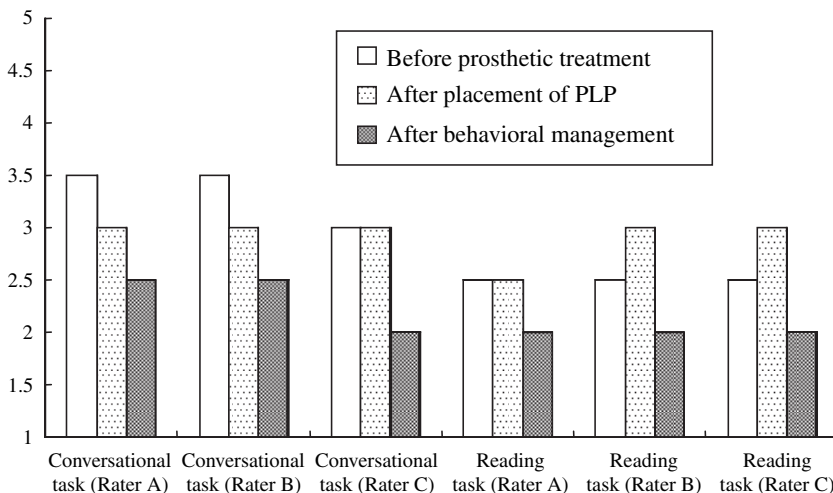


Figure 5 Comparison of conversational speech intelligibility test before and after palatal lift prosthesis (PLP) placement, and after behavioural management.

prosthodontic treatment to 79% after placement of the PLP, and then to 84% after behavioural management.

Table 1 shows the 9-point rating scale of the Japanese conversational speech intelligibility test⁸. The patient completed a conversational task and a reading task and intelligibility was assessed by three SLPs with more than 5 years clinical experience and no prior contact with the patient. Figure 5 shows that a 2-point improvement was seen for a conversational task and it should be noted that the score improved to a sufficiently functional level after behavioural management.

Clinical implication

- In the fabrication of a PLP for a stroke patient with dysarthria, the denture duplication technique allowed for effective utilisation of the patient's existing denture.
- The SLP was able to offer helpful suggestions to the dentist regarding the fabrication and adjustment of the PLP due to better perceived awareness and evaluation of articulation and speech intelligibility.
- Although the use of the prosthesis was judged to have improved VPI as shown by improved scores on the mirror fogging and single word intelligibility test, a similar degree of improvement was not seen in continuous conversational speech intelligibility due to the long-term usage of maladaptive compensatory strategies in speech⁹.
- Training in self-monitoring and biofeedback using the See-Scape by SLP were useful for promoting improvement in speech intelligibility to a sufficiently functional level by effecting some changes to the maladaptive compensatory strategies in speech.
- Given the successful outcome in this case, the collaborative efforts of the dentist and SLP in the rehabilitation of post-stroke patients with velopharyngeal incompetence should be encouraged.

Acknowledgements

The authors acknowledge Prof. Isami Kumakura (Kawasaki University of Medical Welfare) for advice, Dr Kazuhiro Hori for assistance in the

prosthetic treatment, Ms Yumiko Kandori, Ms Takako Matsuda (Nishinomiya-Kyoritsu Rehabilitation Hospital) and Ms Asako Sumitomo (Hyogo-prefectural Kaibara Hospital) for participation in the speech intelligibility test. We are also grateful to Prof. Motonobu Itoh (International University of Health and Welfare) for his kind advice on the scoring of the speech intelligibility test.

References

1. **Gordon C, Langton-Hewer R, Wade DT.** Dysphagia in acute stroke. *Br Med J* 1987; **295**: 411–414.
2. **Smithard D, O'Neill P, England R et al.** The natural history of dysphagia following a stroke. *Dysphagia* 1997; **12**: 188–193.
3. **Urban PP, Wicht S, Vukurevic G et al.** Dysarthria in acute ischemic stroke: lesion topography, clinico-radiologic correlation and etiology. *Neurology* 2001; **56**: 1021–1027.
4. **Light J.** A review of oral and oropharyngeal prostheses to facilitate speech and swallowing. *Am J Speech Lang Pathol* 1995; **4**: 15–21.
5. **Hongama S, Ishikawa M, Kawano F et al.** Complete denture with a removable palatal lift prosthesis: a case report and clinical evaluation. *Quintessence Int* 2002; **33**: 675–678.
6. **Selley W, Roche M, Pearce V et al.** Dysphagia following strokes: clinical observations of swallowing rehabilitation employing palatal training appliances. *Dysphagia* 1995; **10**: 32–35.
7. **Light J, Edelman S, Alba A.** The dental prosthesis used for intraoral muscle therapy in the rehabilitation of stroke patient. *N Y State Dent J* 2001; **67**: 22–27.
8. **Itoh M.** The sensitivity of single-word intelligibility test. *Jpn J Logoped Phoniatr* 1993; **34**: 237–243.
9. **Yorkston KM, Beukeman DR, Edythe AS.** *Management of Motor Speech Disorders in Children and Adults*, 2nd edn. Austin: Pro-Ed, 1999: 359–378.

Correspondence to:

Takahiro Ono,
Osaka University Graduate School of Dentistry,
1-8 Yamadaoka, Suita,
Osaka 565 0871,
Japan.
Tel.: +81 6 6879 2954
Fax: +81 6 6879 2957
E-mail: ono@dent.osaka-u.ac.jp