

Postictal neurogenic stunned myocardium

Abstract—Neurogenic left ventricular dysfunction is a recognized complication of subarachnoid hemorrhage, but this condition has not been reported after seizure activity. The authors present two cases of neurogenic stunned myocardium after convulsive seizures, suggesting that ictal activity can lead to sympathetically mediated cardiac injury.

NEUROLOGY 2005;64:1977–1978

Peter S. Chin, MD; Kelley R. Branch, MD; and Kyra J. Becker, MD

Cardiac abnormalities occur with a variety of CNS injuries.¹ Neurogenic left ventricular (LV) dysfunction, also called neurogenic stunned myocardium, is commonly associated with subarachnoid hemorrhage (SAH).² The dysfunction may be mediated by sympathetic hyperactivity causing myocardial stunning and characteristic pathologic changes. Neurogenic stunned myocardium is also seen in cerebral infarction,³ subdural hematoma,⁴ metastatic brain tumors⁵ and Guillain-Barré syndrome.⁶

Although neurally mediated ventricular hypokinesis has not previously been ascribed to seizure activity, cardiac pathology suggests that seizures can precipitate sympathetic cardiotoxicity. Postmortem cardiac examinations of young, otherwise healthy individuals with epilepsy demonstrate multiple foci of perivascular and interstitial fibrosis associated with myofibrillar atrophy in the absence of coronary artery disease.^{7,8} Furthermore, multifocal ventricular and septal myocyte vacuolization, a potentially reversible form of myocardial injury, is found in patients with epilepsy who experience sudden unexplained death.⁸ Supporting the notion of reversible seizure-related cardiac injury with clinical observations, we report two cases of transient postictal myocardial dysfunction suggestive of neurogenic stunned myocardium.

Case 1. A 62-year-old man with a history of traumatic right intracerebral hemorrhage at age 51 years reported headache and left arm dyscoordination and then collapsed. Emergency medical services found him with impaired consciousness and left arm paresis; he was subsequently witnessed to have a generalized tonic-clonic seizure. He was intubated for airway protection and treated

with IV diazepam. Noncontrast head CT revealed no acute abnormalities. After admission to the intensive care unit, the patient developed hypotension, with blood pressures as low as 84/65 mm Hg, and pulmonary edema. EKG on admission revealed ST-segment depressions in leads V2-V4 that resolved within a day (figure). Serum troponin I peaked at 17.8 ng/mL (reference <2 ng/mL). A transthoracic echocardiogram demonstrated normal LV size and a measured ejection fraction of 40%. Multiple areas of severe LV hypokinesis were observed, including the entire anterior wall, the anterior aspect of the lateral wall, and the distal inferior and posterior walls; there was normal function of the apex. He was treated for heart failure and extubated. On hospital day 3, B-type natriuretic peptide (BNP) was elevated at 950 pg/mL (reference <101 pg/mL), consistent with elevated left ventricular pressure. On hospital day 6, dual isotope rest and Persantine stress perfusion SPECT imaging demonstrated no areas of ischemia and gated SPECT revealed resolution of the previously described wall motion abnormalities and a calculated LV ejection fraction of 54%. Invasive cardiac evaluation was deferred.

Laboratory evaluation revealed no evidence of infection, metabolic disturbance, or stimulant drug use. Brain MRI showed encephalomalacia in the right frontoparietal and left frontal regions, consistent with remote traumatic injury (see figure E-1 on the *Neurology* Web site at www.neurology.org); there were no acute abnormalities. An interictal EEG detected right frontotemporal epileptiform discharges (see figure E-2). The patient's left-sided weakness resolved completely, and he was diagnosed with a Todd's postictal paralysis. Antiepileptic drug therapy was initiated for symptomatic epilepsy.

Case 2. A 50-year-old woman with a history of repaired ruptured left anterior communicating artery aneurysm 8 years previously with subsequent symptomatic epilepsy, hypothyroidism, and occasional migraines presented after an unwitnessed motor vehicle accident. Historically, she had recurrent seizures refractory to phenytoin, divalproex, and carbamazepine. The patient did not recall events before the accident but apparently hit a pole while traveling approximately 40 mph; she was found obtunded on arrival of Emergency Medical Services. She had two witnessed tonic-clonic seizures while in the field that resolved with IV benzodiazepines. She was intubated and brought to the emergency department. No overt chest or head trauma was noted. Head CT showed an old surgical clip and a chronic hypodensity in the left temporal region; no acute hemorrhage was noted. An IV phenytoin load was administered. EKG showed T-wave inversion and flattening in leads V1-V4. On hospital day 2, her troponin I increased to 3.0 ng/mL with a CK-MB of 8 mg/dL. A transthoracic echocardiogram showed hypokinesis of the entire mid left ventricle with normal to hyperdynamic function of the distal apex and the proximal one fourth of the left ventricle. The patient improved rapidly and was extubated on hospital day 1. She was treated conservatively without pharmacologic therapy for her LV dysfunction. On hospital day 4, she underwent a resting thallium perfusion scan; no areas of hypoperfusion were seen. A repeat echocardiogram the same day showed complete resolution of the wall motion abnormality, so cardiac catheterization was not performed. She was discharged on phenytoin.

Discussion. These two cases suggest that limited convulsive activity can precipitate neurogenic stunned myocardium. The left ventricular hypokinesis observed with neurogenic stunned myocardium

Additional material related to this article can be found on the *Neurology* Web site. Go to www.neurology.org and scroll down the Table of Contents for the June 14 issue to find the title link for this article.

From the Robert Wood Johnson/VA Clinical Scholars Program, Departments of Medicine and Neurology (Dr. Chin), University of California Los Angeles and the Greater Los Angeles VA Healthcare System; and the Division of Cardiology (Dr. Branch) and Departments of Neurology and Neurological Surgery (Dr. Becker), University of Washington and Harborview Medical Centers, Seattle, WA.

The views represented in this article do not necessarily reflect those of the Robert Wood Johnson Foundation.

Received July 14, 2004. Accepted in final form February 11, 2005.

Address correspondence and reprint requests to Dr. Peter Chin, UCLA RWJ Clinical Scholars Program, 911 Broxton Avenue, 3rd Floor, Los Angeles, CA 90024; e-mail: pchin@mednet.ucla.edu

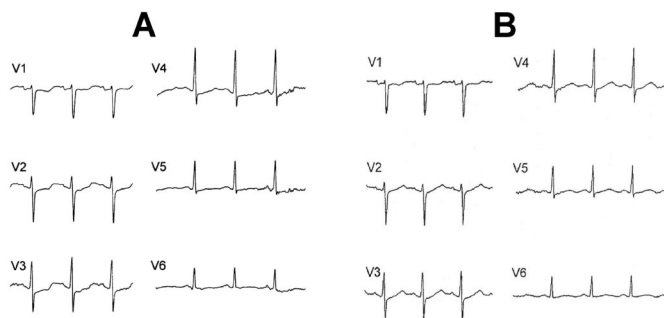


Figure. (A) EKG of Patient 1 with ST-segment depressions in leads V2-V4. (B) Repeat EKG shows resolution of ST changes.

tends to be multifocal or global, does not usually adhere to vascular distributions, and occurs in the absence of observable coronary disease.² EKG repolarization abnormalities and mild cardiac enzyme elevations are frequently observed.⁹ LV function typically returns to normal in days, as seen in both of these cases.

In Patient 1, the EKG abnormalities, mild troponin elevation, and reversible multifocal ventricular dysfunction in a nonvascular pattern reflect the usual findings seen with neurogenic stunned myocardium. Absence of cardiac ischemia on nuclear SPECT imaging supports this diagnosis. The postictal cardiac dysfunction was severe in this case, precipitating hypotension and pulmonary edema that necessitated critical care support. In Patient 2, the postictal ventricular hypokinesis and cardiac enzyme elevation were less prominent, but the constellation of EKG, troponin, and reversible echocardiographic abnormalities in a nonvascular distribution similarly suggests neurally mediated stunned myocardium. A resting thallium perfusion scan did not suggest areas of cardiac ischemia.

Because our patients did not undergo coronary angiography after the cardiac event, a degree of uncertainty remains regarding the mechanism of their transient myocardial dysfunction. Although ischemia due to a mismatch of myocardial oxygen supply and demand can manifest as myocardial stunning, a vascular etiology is unlikely. In both cases, multiple dis-

eased coronary vessels would be necessary to explain the observed wall motion abnormalities, a finding not corroborated with radionuclide stress testing in the first patient. Moreover, function of the apical left ventricle was spared in both cases, and ischemia in the territory of the left anterior descending artery, which would cause anterior wall dysfunction, should also involve the apex. This pattern of sparing the apical ventricle has been reported previously in neurogenic stunned myocardium with SAH.² Finally, both patients were initially treated with IV benzodiazepines for seizure activity; barbiturates, which can cause myocardial depression,¹⁰ were not administered.

The occurrence of neurogenic stunned myocardium after seizures is not surprising given the high sympathetic tone associated with convulsions and the characteristic myocardial pathology that has been demonstrated in individuals with epilepsy. The actual incidence of LV dysfunction resulting from seizure activity, however, is not known. The fact that neurally mediated ventricular dysfunction occurs with several other neurologic diseases may suggest a common mechanism, possibly CNS-mediated catecholamine stimulation.

References

1. Dixit S, Castle M, Velu RP, Swisher L, Hodge C, Jaffe AS. Cardiac involvement in patients with acute neurologic disease: confirmation with cardiac troponin I. *Arch Intern Med* 2000;160:3153-3158.
2. Zaroff JG, Rordorf GA, Ogilvy CS, Picard MH. Regional patterns of left ventricular systolic dysfunction after subarachnoid hemorrhage: evidence for neurally mediated cardiac injury. *J Am Soc Echocardiogr* 2000;13:774-779.
3. Wang TD, Wu CC, Lee YT. Myocardial stunning after cerebral infarction. *Int J Cardiol* 1997;58:308-311.
4. Ohtsuka T, Hamada M, Kodama K, et al. Images in cardiovascular medicine. Neurogenic stunned myocardium. *Circulation* 2000;101:2122-2124.
5. Chuang CP, Chao CL. Neurogenic stunned myocardium in a patient with metastatic brain tumors. *Int J Cardiol* 2000;76:251-253.
6. Bernstein R, Mayer SA, Magnano A. Neurogenic stunned myocardium in Guillain-Barre syndrome. *Neurology* 2000;54:759-762.
7. Falconer B, Rajs J. Post-mortem findings of cardiac lesions in epileptics: a preliminary report. *Forensic Sci* 1976;8:63-71.
8. Natelson BH, Suarez RV, Terrence CF, Turizo R. Patients with epilepsy who die suddenly have cardiac disease. *Arch Neurol* 1998;55:857-860.
9. Parekh N, Venkatesh B, Cross D, et al. Cardiac troponin I predicts myocardial dysfunction in aneurysmal subarachnoid hemorrhage. *J Am Coll Cardiol* 2000;36:1328-1335.
10. Lepage JY, Pinaud ML, Helias JH, Cozian AY, Le Normand Y, Souron RJ. Left ventricular performance during propofol or methohexital anesthesia: isotopic and invasive cardiac monitoring. *Anesth Analg* 1991;73:3-9.

Neurology[®]

Postictal neurogenic stunned myocardium

Peter S. Chin, Kelley R. Branch and Kyra J. Becker

Neurology 2005;64;1977-1978

DOI 10.1212/01.WNL.0000163858.77494.7A

This information is current as of June 13, 2005

Updated Information & Services	including high resolution figures, can be found at: http://www.neurology.org/content/64/11/1977.full.html
Supplementary Material	Supplementary material can be found at: http://www.neurology.org/content/suppl/2005/06/08/64.11.1977.DC1.html
References	This article cites 10 articles, 2 of which you can access for free at: http://www.neurology.org/content/64/11/1977.full.html##ref-list-1
Subspecialty Collections	This article, along with others on similar topics, appears in the following collection(s): All Epilepsy/Seizures http://www.neurology.org/cgi/collection/all_epilepsy_seizures Cardiac http://www.neurology.org/cgi/collection/cardiac
Permissions & Licensing	Information about reproducing this article in parts (figures, tables) or in its entirety can be found online at: http://www.neurology.org/misc/about.xhtml#permissions
Reprints	Information about ordering reprints can be found online: http://www.neurology.org/misc/addir.xhtml#reprintsus

Neurology® is the official journal of the American Academy of Neurology. Published continuously since 1951, it is now a weekly with 48 issues per year. Copyright . All rights reserved. Print ISSN: 0028-3878. Online ISSN: 1526-632X.

