

# Hyperperfusion Syndrome after Carotid Endarterectomy

Willis H. Wagner, MD, David V. Cossman, MD, Alik Farber, MD, Phillip M. Levin, MD, and J. Louis Cohen, MD, Los Angeles, California

The hyperperfusion syndrome is a rare delayed postoperative complication of carotid endarterectomy (CEA) characterized by headache and seizure, with or without intracranial edema or hemorrhage. Between January 1996 and December 2003, 1,602 CEAs were performed. Six patients (0.4%) developed symptoms of hyperperfusion within 2 weeks of surgery. All patients had critical stenoses, five  $\geq 90\%$  and one 80-90%, with poor backbleeding from the distal internal carotid artery noted at operation in all cases. Five patients were asymptomatic prior to operation; one had a hemispheric transient ischemic attack. Three patients had severe contralateral internal carotid disease (two occlusions and one severe stenosis). Two patients developed severe, self-limiting headache that prolonged hospitalization. Three patients had ipsilateral intracranial bleeding, two occurring after an uneventful postoperative course. After initial discharge from the hospital, severe intracranial hemorrhage caused death in two patients. One patient experienced focal seizures 1 week after discharge. Hypertension did not appear to be related to the symptoms in any case. During the study period, the hyperperfusion syndrome caused three of five perioperative strokes (60%) and two of seven deaths (29%) in the entire endarterectomy population. Although rare, the hyperperfusion syndrome accounts for a significant percentage of the neurological morbidity and mortality following CEA.

## INTRODUCTION

In 1975, Sundt et al.<sup>1</sup> proposed a syndrome of hyperperfusion as the cause of seizures after carotid endarterectomy (CEA) in five patients with high-grade stenoses and small preoperative infarcts. All patients had a significant increase in ipsilateral cerebral blood by xenon-133 washout and marked increases in retinal artery pressure. During the same year, Leviton et al.<sup>2</sup> described a patient who complained of severe frontal headaches lasting 2 weeks that began 3 days after endarterectomy. The headaches were thought to result from opening of collateral vessels and distention of a vascular bed with "disordered autoregulation." This is analogous to the "normal perfusion pressure breakthrough the-

ory" proposed by Spetzler et al.<sup>3</sup> to explain massive cerebral edema and hemorrhage after repair of a chronic arteriovenous malformation. Prolonged exposure of the arterial bed to low pressure may result in loss of the normal autoregulatory capacity that maintains constant cerebral blood flow over a range of perfusion pressures. Significant, abnormal increases in ipsilateral cerebral blood flow in patients with hyperperfusion symptoms have been documented with transcranial Doppler,<sup>4,12</sup> xenon washout,<sup>13</sup> duplex scan,<sup>14</sup> transit time flowmeter,<sup>15</sup> single photon emission computerized tomography (SPECT) scanning,<sup>16,17</sup> and diffusion-weighted magnetic resonance imaging (MRI).<sup>18</sup> Examination of autopsy specimens after fatal hyperperfusion syndrome reveals pathology characteristic of malignant hypertension, including fibrinoid necrosis, endothelial cell edema and hyperplasia, margination and extravasation of neutrophils, and marked cerebral edema.<sup>19,20</sup> The hyperperfusion syndrome has been described after a variety of procedures that improve flow to a chronically ischemic hemisphere, including carotid stenting,<sup>21-26</sup> subclavian-carotid bypass,<sup>27</sup> extracranial-intracranial bypass,<sup>15</sup> and innominate endarterectomy.<sup>28</sup> An analogous ocular hyperperfusion syndrome has been described after endarterectomy.<sup>29,30</sup>

Division of Vascular Surgery, Cedars-Sinai Medical Center, Los Angeles, CA, USA.

Presented at the Twenty-second Annual Meeting of the Southern California Vascular Surgery Society, La Jolla, CA, April 30-May 2, 2004.

Correspondence to: Willis H. Wagner, MD, 8631 W. Third Street, Suite 615-E, Los Angeles, CA 90048, USA, E-mail: wagnerwh@cshs.org

*Ann Vasc Surg* 2005; 19: 479-486

DOI: 10.1007/s10016-005-4644-3

© Annals of Vascular Surgery Inc.

Published online: June 23, 2005

The incidence of hyperperfusion syndrome after CEA is unclear due to the predominance of case reports and a lack of consensus regarding diagnostic criteria. The classic manifestations of the syndrome are postoperative seizures, in the absence of a structural abnormality, or intracranial hemorrhage. In series larger than 400 patients, the incidence of hyperperfusion seizures or hemorrhage ranges 0.3-2.0%.<sup>14,31-41</sup> However, other symptoms, such as severe headache, nausea and transient ischemic attacks, may result from hyperperfusion with or without radiological signs of cerebral edema.<sup>42</sup> We have reviewed our experience with six patients whose delayed postoperative morbidity and mortality were related to repair of a critical internal carotid stenosis.

## PATIENTS AND METHODS

Basic demographic information was accumulated prospectively for the 1,602 CEAs performed by a single practice from January 1, 1996, until December 31, 2003. Ninety-seven percent of the procedures were primary operations; 3% were for recurrent stenosis. The indications for operation were asymptomatic stenosis  $\geq 60$  in 72%, transient ischemic attack in 14%, ipsilateral amaurosis fugax in 5%, and recovered small stroke in 9%. All patients were on aspirin or clopidogrel prior to endarterectomy unless coronary artery bypass or major abdominal operations were planned within 1 week. During the endarterectomy, all patients were systemically heparinized and had intraluminal shunts. Protamine was routinely administered after completing the reconstruction. A Dacron<sup>TM</sup> patch was used to close the arteriotomy in 99% of the operations. Low-molecular weight dextran was infused at 50 ml/hr, beginning during the endarterectomy and continuing for 5 hr after the procedure. The majority of patients were discharged on the first day after the operation.

The records of patients with suspected hyperperfusion syndrome were reviewed retrospectively. Hyperperfusion syndrome was defined as severe headaches that significantly prolonged the patient's hospitalization, new-onset seizures, or intracranial hemorrhage that developed after completion of the endarterectomy.

## RESULTS

During the 7-year study period, there were seven deaths (0.4%) and five strokes (0.3%), three major and two minor. Three of the major strokes caused death, resulting in a combined stroke/mortality rate

of 0.6%. Six patients were diagnosed with hyperperfusion syndrome, resulting in one minor stroke and two fatal strokes. The history and clinical course for each patient are given in chronological order and summarized in Table I. None of the patients was significantly hypertensive ( $>160$  mm Hg systolic) during the onset of symptoms.

### Case 1

A 76-year-old man had a duplex scan which showed a  $\geq 95\%$  left internal carotid stenosis. Transcranial Doppler study prior to reconstruction showed low velocities in the left middle cerebral artery (MCA) (mean 64 vs. 104 cm/sec in the contralateral MCA). At operation, the stenosis was considered preocclusive and the backbleeding was poor. His postoperative course was unremarkable. Eight days after his CEA, he was readmitted with focal seizures involving the right arm. A duplex scan showed a normal reconstructed left carotid artery. Computed tomographic (CT) scans on the ninth and tenth postoperative days were negative. He was treated for 3 months with phenytoin (Dilantin) and did not have any further neurological symptoms.

### Case 2

A 76-year-old man had a transient episode of left arm weakness. A duplex scan, corroborated by arch angiography, showed 95% right internal carotid stenosis, occlusion of the left internal carotid, and retrograde flow in the left vertebral artery secondary to subclavian artery occlusion. MRI showed chronic ischemic changes in the right parietal lobe. At the time of right CEA, the backbleeding was noted to be fair. The patient was discharged on the first postoperative day without complaints. Two days later, without preceding symptoms, he had a massive right intracranial bleed and was admitted to another hospital. Supportive care was given, and he died without intervention.

### Case 3

An asymptomatic 72-year-old woman had the first of two critical carotid stenoses reconstructed. She complained of severe headaches immediately after her endarterectomy. Head CT and MRI scans were both normal. A transcranial Doppler exam was limited by the lack of a temporal window. Additional  $\beta$ -blockade was added to her antihypertensive regimen to maintain her blood pressure under 140 systolic. She was discharged 2 weeks after operation with persistent headaches, which

**Table 1.** Clinical data of the six patients with hyperperfusion syndrome

Age/sex	Diabetes	Preoperative hypertension medications	Ipsilateral stenosis (%)	Contralateral ICA (%)	Indication for endarterectomy	Backbleeding	Symptom	Onset of symptoms	Outcome
70/M	No	Atenolol	>95	50	Asymptomatic	Poor	Seizure	8 days	Good
74/M	No	None	>95	Occluded	TIA	Fair	ICH	3 days	Died
72/F	No	None	90-99	80-90	Asymptomatic	Poor	Headache	1 day	Good
54/M	Yes	Metoprolol, ramipril, spironolactone	>95	Occluded	Asymptomatic	Poor	ICH	3 days	Good
65/F	No	Lisinopril	>90	10-20	Asymptomatic	Poor	Headache, ICH	1 day	Died
76/F	No	Lisinopril, metoprolol	80-90	20-30	Asymptomatic	Poor	Headache	1 day	Good

ICA, internal carotid artery; TIA, transient ischemic attack; ICH, intracerebral hemorrhage.

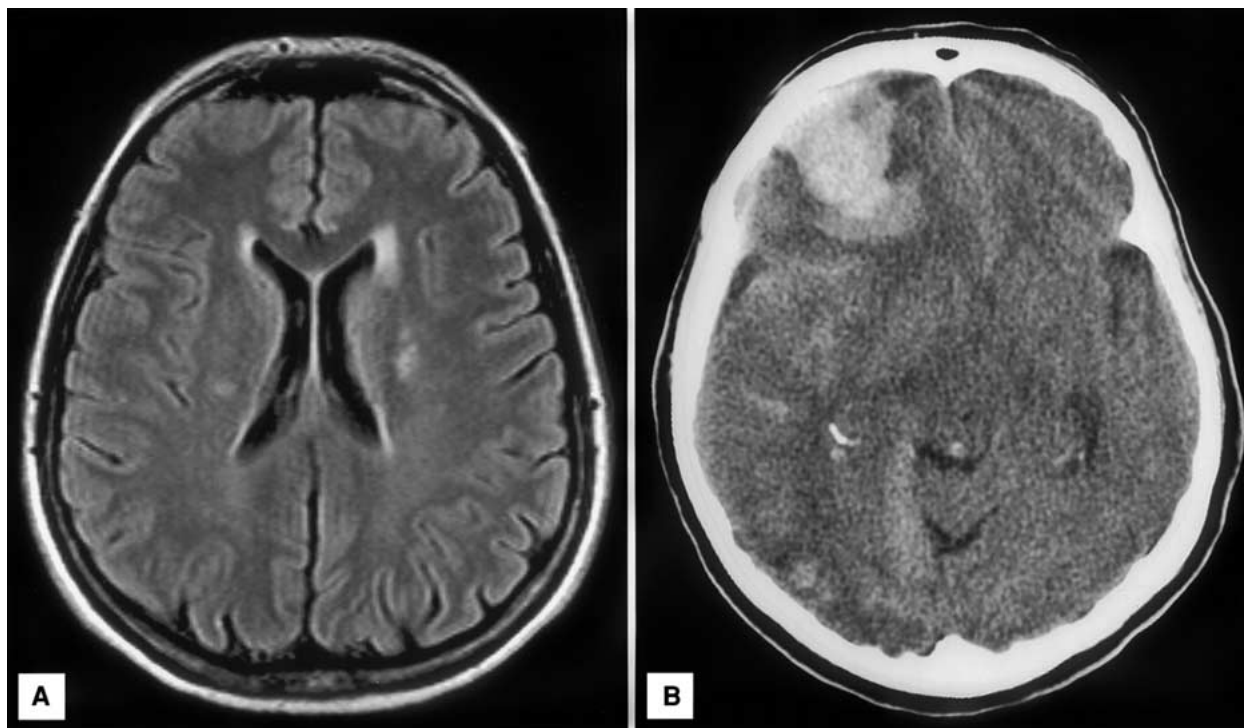
abated over the ensuing month. The contralateral carotid was repaired 6 months later without incident.

#### Case 4

A 54-year-old man admitted for elective coronary artery bypass had a routine duplex scan showing >95% right carotid stenosis and left carotid occlusion. Staged carotid and coronary artery reconstruction was planned. After induction of anesthesia, the blood pressure dropped and the cardiac monitor suggested ischemia. Following right CEA, he had emergent three-vessel coronary bypass, mitral valve repair, and tricuspid valve replacement. Although the patient was initially intubated for 2 days, he appeared grossly neurologically intact until 3 days after his procedure. He became confused and was found to have a new left arm and leg weakness. A CT scan showed a small hemorrhage in the right parietal lobe. Carotid duplex scan showed a patent internal carotid artery. He was transferred to an acute rehab unit 1 week later with subsequent complete neurological recovery.

#### Case 5

A 65-year-old woman had reconstruction of an asymptomatic 90% right internal carotid stenosis. Although the vertebral arteries were patent and the contralateral carotid had only minimal stenosis, the backbleeding from the distal internal carotid was negligible. The patient did not have complaints immediately after her procedure. The following day, she began having severe right frontal and retrobulbar pain associated with nausea. A carotid duplex showed normal flow in the patched carotid artery. An MRI scan (Fig. 1A) on the third postoperative day was normal. Systolic blood pressure was maintained below 140 mm Hg throughout her hospitalization. Magnetic resonance angiography showed a hypoplastic A1 segment of the right anterior cerebral artery but no evidence of aneurysm. The patient was discharged the following day when she claimed that her symptoms had resolved. Later, the patient's family suggested that she denied continued symptoms in order to leave the hospital. She was admitted to another facility 6 days after the original procedure with a large right frontal intracerebral hemorrhage with brain stem herniation (Fig. 1B). She had emergent evacuation of her hematoma, but postoperative nuclear flow studies and clinical exam were consistent with brain death.



**Fig. 1.** Postoperative cerebral imaging of case 5. **A** MRI of brain on postoperative day 3. **B** CT scan of the brain on postoperative day 6, showing large right frontal hemorrhage with brain stem herniation.

### Case 6

A 76-year-old woman was admitted with new-onset tonic-clonic seizure activity related to an old left hemisphere infarct. The stroke occurred 1 year prior, resulted in moderate expressive aphasia, and was thought to be due to atrial fibrillation. During this hospitalization, she was found to have an asymptomatic 80-90% right internal carotid stenosis and minimal left carotid disease on duplex scan. MRI showed no acute changes. An electroencephalogram revealed left frontal slowing consistent with her old infarct. Three months later, without any further seizure activity, she had a prophylactic right CEA. Very poor intracranial backbleeding was noted on placement of the intraluminal shunt. The first day after operation, she had severe ipsilateral frontal and retrobulbar headaches, poorly controlled by analgesics. A duplex scan of the repaired artery was normal. CT on the third postoperative day and MRI a day later did not show any new findings. Her blood pressure was well controlled throughout her hospitalization. Four days after the endarterectomy, she was given topiramate, an anticonvulsant with carbonic anhydrase inhibitory effects which is useful for migraine headaches. Her symptoms resolved, and she

was discharged the following day, with no subsequent problems.

### DISCUSSION

As techniques improve and the indications for intervention have been refined, the perioperative stroke and mortality rates associated with CEA have declined significantly over the last 20 years.<sup>43-48</sup> Between 1991 and 2000, the national 30-day mortality rates after CEA in Medicare patients declined by >50%.<sup>48</sup> Although national stroke data are not available, audits of large institutional experiences have confirmed the downward trend in surgical stroke risk.<sup>47,49</sup> Between 1984 and 1989, our perioperative stroke rate among 738 patients was 2.6% compared to the current rate of 0.3% between 1996 and 2003.<sup>50</sup> We attribute this improvement to a combination of experience and technical factors, including administration of intravenous low-molecular weight dextran and routine Dacron patching of the arteriotomy. With a reduction in technical errors, the hyperperfusion syndrome has assumed a major role in the morbidity and mortality of a procedure that remains under intense scrutiny. In three re-

cent reviews, hyperperfusion caused 22-50% of postendarterectomy strokes.<sup>31,51,52</sup>

The keys to reducing morbidity related to hyperperfusion are to identify patients at risk and institute effective, early therapy. The most dreaded complication is intracerebral hemorrhage, which carries a >50% chance of death or permanent neurological deficit. Until the mid-1970 s, most postoperative hemorrhages were due to early operation after major strokes. Bruetman et al.<sup>53</sup> emphasized the need to delay endarterectomy for at least 2 weeks after stroke. Currently, most delayed hemorrhages are unrelated to prior infarcts or intraoperative technical factors and are presumably consequences of hyperperfusion.<sup>7,33,34,37-39</sup> The only uniform risk factor is repair of a critical carotid stenosis. In all reported cases, the ipsilateral stenosis was at least 80%; the overwhelming majority are >90%. Most cases are associated with a contralateral occlusion or critical stenosis. In our experience, all patients with postoperative hyperperfusion symptoms had evidence of low hemispheric perfusion pressure determined by subjective assessment of the distal internal carotid backbleeding. Although this information is not available for all 1,602 endarterectomy patients in this series, an intraoperative finding of poor backbleeding is more common in the hyperperfusion subset and indicates an uncommon pathophysiological milieu. Stump pressures measured by Nielsen et al.<sup>54</sup> in five patients with postoperative seizures were 20-42 mm Hg, with four being <35 mm Hg.

Three of our patients had severe postoperative headache, one of whom died due to intracerebral hemorrhage. Although headache is frequently reported as a precursor to seizures or hemorrhage, it is a nonspecific finding. Postoperative headache, usually frontal and bilateral, occurs in 42-62% of patients after endarterectomy.<sup>55,56</sup> In the current series, the characteristic that differentiated the hyperperfusion patients was the magnitude of the headache. Each patient was incapacitated by the headaches, a presentation not seen in our patients with lesser degrees of carotid stenosis.

A variety of techniques have been employed to identify patients at risk for hyperperfusion syndrome. Transcranial Doppler has been used, primarily in Europe, to identify patients with increased ipsilateral intra- and postoperative MCA flow.<sup>5-7,9,11,57</sup> Based on a retrospective study from the same institution,<sup>7</sup> Dalman et al.<sup>5</sup> prospectively measured intraoperative changes in peak flow volume (PFV) and the Golsing pulsatility index (PI) in the ipsilateral MCA before test clamping of the carotid artery and 3 min after clamp release at

completion of the endarterectomy. The PI is calculated by comparing the difference in flow velocity between systole and diastole with mean velocity and relates to arterial resistance. Patients with increases in PFV or PI of >100% were treated aggressively to maintain systolic blood pressure <140 mm Hg. Of 62 patients considered at risk, 11 had postoperative headache and three had seizures, but no patient had intracerebral hemorrhage. The threshold for developing hyperperfusion syndrome may be lower in patients who present with hemispheric symptoms prior to endarterectomy. Symptomatic patients demonstrate greater increases in PFV and PI than asymptomatic patients.<sup>58</sup> Preoperative symptomatic status did not appear to be a factor in our experience as five of the six patients underwent endarterectomy for asymptomatic stenosis. While serial transcranial Doppler exams show promise in identifying postendarterectomy patients at risk, this technology has not gained widespread acceptance in the United States. Transcranial regional cerebral oxygen saturation monitoring via near-infrared spectroscopy was recently used to examine 50 patients undergoing carotid endarterectomy.<sup>59</sup> Hyperperfusion, defined as an increase in cerebral blood flow of >100%, was observed in six patients, one of whom developed seizures on the sixth postoperative day. No other patient developed symptoms of hyperperfusion.

The critical issue in limiting morbidity from intracranial hemorrhage is whether antihypertensive treatment is effective treatment or prophylaxis. The onset of hyperperfusion symptoms is frequently said to coincide with hypertensive episodes. This finding results in the recommendation to aggressively treat blood pressure in postendarterectomy patients with headache or seizures or who are identified by noninvasive technology to have evidence of significantly increased cerebral blood flow.<sup>5,7,9,36,37,39,54,57,60</sup> However, we and others have not seen a relationship between the onset of hyperperfusion symptoms and hypertension.<sup>14,16,17,19,33,38,61</sup> Over the last 10 years, a routine order set that includes an antihypertensive regimen has resulted in tighter blood pressure control in our patients. Ogasawara et al.<sup>16</sup> used SPECT scanning to identify patients with increased cerebral blood flow. Patients considered at risk of developing symptoms had systolic blood pressure controlled in the range of 100-140 mm Hg by intravenous nicardipine. If hyperperfusion persisted after 3 days, the systolic blood pressure was maintained below 90 mm Hg. Despite this rigorous control, two of eight at-risk patients developed seizures and transient ischemic attacks.

Anesthetic management may have a role in limiting the risk of hyperperfusion. Volatile anesthetic agents that produce cerebral vasodilation, particularly isoflurane, exacerbate the loss of cerebral autoregulation and should be limited to low doses<sup>5,62</sup>. Regional anesthesia may reduce the risk of hyperperfusion by preventing the anesthetic effects on cerebral blood flow.<sup>60</sup> It is unclear whether early contralateral endarterectomy increases the risk of hyperperfusion syndrome. Ascher et al.<sup>14</sup> found that in patients having bilateral carotid endarterectomy within 3 months the risk was 14.3% compared to 0% with longer intervals between operations. This is in contrast to two other series where the interval between operations was 1-8 days, with a 1% incidence of hyperperfusion injury.<sup>63,64</sup>

We believe that it is possible to identify patients at risk by anatomical and intraoperative findings. Patients with critical stenoses who have evidence of poor collateral flow either by subjective evaluation of backbleeding, objective measurement of stump pressure, or neurological impairment after carotid clamping in an awake state should have blood pressure carefully monitored. Unless contraindicated, addition of  $\beta$ -blockers in the postoperative period may be prudent. Whether maintaining blood pressure below standard postoperative levels will reduce the incidence or severity of the hyperperfusion syndrome is unproven.

## REFERENCES

1. Sundt TM, Jr, Sandok BA, Whisnant JP. Carotid endarterectomy: complications and preoperative assessment of risk. *Mayo Clin Proc* 1975;50:301-306.
2. Levitan A, Caplan L, Salzman E. Severe headache after carotid endarterectomy. *Headache* 1975;15:207-210.
3. Spetzler RF, Wilson CB, Weinstein P, Mehdorn M, Townsend J, Telles D. Normal perfusion pressure breakthrough theory. *Clin Neurosurg* 1978;25:651-672.
4. Chambers BR, Smidt V, Koh P. Hyperperfusion post-endarterectomy. *Cerebrovasc Dis* 1994;4:32-37.
5. Dalman JE, Beenackers ICM, Moll FL, Leusink JA, Ackerstaff RGA. Transcranial Doppler monitoring during carotid endarterectomy helps to identify patients at risk of postoperative hyperperfusion. *Eur J Vasc Endovasc Surg* 1999;18:222-227.
6. Gossetti B, Martinelli O, Guerricchio R, Irace L, Benedetti-Valentini F. Transcranial Doppler in 178 patients before, during, and after carotid endarterectomy. *J Neuroimaging* 1997;7:213-216.
7. Jansen C, Sprengers AM, Moll FL, Vermeulen FEE, Hamerlijnck RPHM, van Gijn J, Ackerstaff RGA. Prediction of intracerebral haemorrhage after carotid endarterectomy by clinical criteria and intraoperative transcranial Doppler monitoring: results of 233 operations. *Eur J Vasc Surg* 1994;8:220-225.
8. Magee TR, Davies AH, Horrocks M. Transcranial Doppler evaluation of cerebral hyperperfusion syndrome after carotid endarterectomy. *Eur J Vasc Surg* 1994;8:104-106.
9. Müller M, Behnke S, Walter P. Cerebrovascular resistance and blood flow velocity changes after carotid endarterectomy. *Vasa* 1999;28:279-282.
10. Powers AD, Smith RR. Hyperperfusion syndrome after carotid endarterectomy: a transcranial Doppler evaluation. *Neurosurgery* 1990;26:56-60.
11. Sbarigia E, Speziale F, Giannoni MF, Colonna M, Panico MA, Fiorani P. Post-carotid endarterectomy hyperperfusion syndrome: preliminary observations for identifying at risk patients by transcranial Doppler sonography and the acetazolamide test. *Eur J Vasc Surg* 1993;7:252-256.
12. Zachrisson H, Blomstrand C, Holm J, Mattsson E, Volkmann R. Changes in middle cerebral artery blood flow after carotid endarterectomy as monitored by transcranial Doppler. *J Vasc Surg* 2002;36:285-90.
13. Sundt TM, Jr, Sharbrough FW, Piepgras DG, Kearns TP, Messick JM, O'Fallon WM. Correlation of cerebral blood flow and electroencephalographic changes during carotid endarterectomy. *Mayo Clin Proc* 1981;56:533-543.
14. Ascher E, Markevich N, Schutzer RW, Kallakuri S, Jacob T, Hingorani AP. Cerebral hyperperfusion syndrome after carotid endarterectomy: predictive factors and hemodynamic changes. *J Vasc Surg* 2003;37:769-777.
15. Nakayama N, Kuroda S, Houkin K, Takikawa S, Abe H. Intraoperative measurement of arterial blood flow using a transit time flowmeter: monitoring of hemodynamic changes during cerebrovascular surgery. *Acta Neurochir (Wien)* 2001;143:17-24.
16. Ogasawara K, Yukawa H, Kobayashi M, et al. Prediction and monitoring of cerebral hyperperfusion after carotid endarterectomy by using single-photon emission computerized tomography scanning. *J Neurosurg* 2003;99:504-510.
17. Yoshimoto T, Houkin K, Kuroda S, Abe H, Kashiwaba T. Low cerebral blood flow and perfusion reserve induce hyperperfusion after surgical revascularization: case reports and analysis of cerebral hemodynamics. *Surg Neurol* 1997;48:132-139.
18. Shinno K, Ueda S, Uno M, Nishitani K, Nagahiro S, Harada M. Hyperperfusion syndrome following carotid endarterectomy: evaluation using diffusion-weighted magnetic resonance imaging. *Neurol Med Chir (Tokyo)* 1998;38:557-561.
19. Bernstein M, Fleming JFR, Deck JHN. Cerebral hyperperfusion after carotid endarterectomy: a cause of cerebral hemorrhage. *Neurosurgery* 1984;15:50-56.
20. Mansoor GA, White WB, Grunnet M, Ruby ST. Intracerebral hemorrhage after carotid endarterectomy associated with ipsilateral fibrinoid necrosis: a consequence of the hyperperfusion syndrome? *J Vasc Surg* 1996;23:147-151.
21. Ho DSW, Wang Y, Chui M, Ho SL, Cheung RTF. Epileptic seizures attributed to cerebral hyperperfusion after percutaneous transluminal angioplasty and stenting of the internal carotid artery. *Cerebrovasc Dis* 2000;10:374-379.
22. McCabe DJH, Brown MM, Clifton A. Fatal cerebral reperfusion hemorrhage after carotid stenting. *Stroke* 1999;30:2483-2486.
23. Meyers PM, Higashida RT, Phatouros C, Malek AM, Lempert TE, Dowd CF, Halbach VV. Cerebral hyperperfusion syndrome after percutaneous transluminal stenting of the craniocervical arteries. *Neurosurgery* 2000;47:335-345.
24. Morrish W, Grahovac S, Douen A, et al. Intracranial hemorrhage after stenting and angioplasty of extracranial

- carotid stenosis. *AJNR Am J Neuroradiol* 2000;21:1911-1916.
25. Nikolsky E, Patil CV, Beyar R. Ipsilateral intracerebral hemorrhage following carotid stent-assisted angioplasty: a manifestation of hyperperfusion syndrome. *Angiology* 2002;53:217-223.
  26. Schoser BGH, Heesen C, Eckert B, Thie A. Cerebral hyperperfusion injury after percutaneous transluminal angioplasty of extracranial arteries. *J Neurol* 1997;244:101-104.
  27. Ammar AD. Seizures following subclavian-carotid bypass. *J Vasc Surg* 1987;5:483-485.
  28. MacGillivray DC, Valentine RJ, Rob CG. Reperfusion seizures after innominate endarterectomy. *J Vasc Surg* 1987;6:521-523.
  29. Nicholas GG, Hashemi H, Gee W, Reed JF, III. The cerebral hyperperfusion syndrome: diagnostic value of ocular pneumoplethysmography. *J Vasc Surg* 1993;17:690-695.
  30. Wagner WH, Weaver FA, Brinkley JR, Borchert M, Lindsay SF. Chronic ocular ischemia and neovascular glaucoma: a result of extracranial carotid artery disease. *J Vasc Surg* 1988;8:551-557.
  31. Archie JP, Jr. A fifteen-year experience with carotid endarterectomy after a formal operative protocol requiring highly frequent patch angioplasty. *J Vasc Surg* 2000;31:724-735.
  32. de Borst GJ, Moll FL, van de Pavoordt HDWM, Mauser HW, Kelder JC, Ackerstaff RGA. Stroke from carotid endarterectomy: when and how to reduce perioperative stroke rate? *Eur J Vasc Endovasc Surg* 2001;21:484-489.
  33. Hafner DH, Smith RB, III, King OW, Perdue GD, Stewart MT, Rosenthal D, Jordan D. Massive intracerebral hemorrhage following carotid endarterectomy. *Arch Surg* 1987;122:305-307.
  34. Henderson RD, Phan TG, Piepgras DG, Wijdicks EFM. Mechanisms of intracerebral hemorrhage after carotid endarterectomy. *J Neurosurg* 2001;95:964-969.
  35. Kiebertz K, Ricotta JJ, Moxley RT. Seizures following carotid endarterectomy. *Arch Neurol* 1990;47:568-570.
  36. Naylor AR, Evans J, Thompson MM, London NJM, Abbott RJ, Cherryman G, Bell PRF. Seizures after carotid endarterectomy: hyperperfusion, dysautoregulation or hypertensive encephalopathy? *Eur J Vasc Endovasc Surg*. 2003;26:39-44.
  37. Ouriel K, Shortell CK, Illig KA, Greenberg RK, Green RM. Intracerebral hemorrhage after carotid endarterectomy: incidence, contribution to neurologic morbidity, and predictive factors. *J Vasc Surg* 1999;29:82-89.
  38. Piepgras DG, Morgan MK, Sundt TM, Yanagihara T, Mussman LM. Intracerebral hemorrhage after carotid endarterectomy. *J Neurosurg* 1988;68:532-536.
  39. Pomposelli FB, Lamparello PJ, Riles TS, Craighead CC, Giangola G, Imperato AM. Intracranial hemorrhage after carotid endarterectomy. *J Vasc Surg* 1988;7:248-255.
  40. Reigel MM, Hollier LH, Sundt TM, Piepgras DG, Sharbrough FW, Cherry KJ. Cerebral hyperperfusion syndrome: a cause of neurologic dysfunction after carotid endarterectomy. *J Vasc Surg* 1987;5:628-634.
  41. Youkey JR, Clagett GP, Jaffin JH, Parisi JE, Rich NM. Focal motor seizures complicating carotid endarterectomy. *Arch Surg* 1984;119:1080-1084.
  42. Breen JC, Caplan LR, DeWitt LD, Belkin M, Mackey WC, O'Donnell TP. Brain edema after carotid surgery. *Neurology* 1996;46:175-181.
  43. Goodney PP, Siewers AE, Stukel TA, Lucas FL, Wennberg DE, Birkmeyer JD. Is surgery getting safer? National trends in operative mortality. *J Am Coll Surg* 2002;195:219-227.
  44. Hsia DC, Moscoe LM, Krushat WM. Epidemiology of carotid endarterectomy among Medicare beneficiaries. *Stroke* 1998;29:346-350.
  45. Kresowik TF, Bratzler DW, Kresowik RA, Hendel ME, Grund SL, Brown KR, Nilasena DS. Multistate improvement in process and outcomes of carotid endarterectomy. *J Vasc Surg* 2004;39:372-380.
  46. Naylor AR, Hayes PD, Alloggen H, et al. Reducing the risk of carotid surgery: a 7-year audit of the role of monitoring and quality control assessment. *J Vasc Surg* 2000;32:750-759.
  47. Olcott C IV, Mitchell RS, Steinberg GK, Zarins CK. Institutional peer review can reduce the risk and cost of carotid endarterectomy. *Arch Surg* 2000;135:939-942.
  48. Sheikh K, Bullock C. Variation and changes in state-specific carotid endarterectomy and 30-day mortality rates, United States, 1991-2000. *J Vasc Surg* 2003;38:779-784.
  49. Hertzner NR, O'Hara PJ, Mascha EJ, Krajewski LP, Sullivan TM, Beven EG. Early outcome assessment for 2228 consecutive carotid endarterectomy procedures: the Cleveland Clinic experience from 1989 to 1995. *J Vasc Surg* 1997;26:1-10.
  50. Wagner WH, Treiman RL, Cossman DV, Foran RF, Levin PM, Cohen JL. The diminishing role of diagnostic arteriography in carotid artery disease: duplex scanning as definitive preoperative study. *Ann Vasc Surg* 1991;5:105-110.
  51. Ascher E, Hingorani A. Changing characteristics of carotid endarterectomy. *Ann Vasc Surg* 2001;15:275-280.
  52. Coutts SB, Hill MD, Hu WY, Sutherland GR. Hyperperfusion syndrome: toward a stricter definition. *Neurosurgery* 2003;53:1053-1060.
  53. Bruetman ME, Fields WS, Crawford ES, DeBakey ME. Cerebral hemorrhage in carotid artery surgery. *Arch Neurol* 1963;9:458-467.
  54. Nielsen TG, Sillesen H, Schroeder TV. Seizures following carotid endarterectomy in patients with severely compromised cerebral circulation. *Eur J Vasc Endovasc Surg* 1995;9:53-57.
  55. Messert B, Black JA. Cluster headache, hemicrania, and other head pains: morbidity of carotid endarterectomy. *Stroke* 1978;9:559-562.
  56. Tehindrazanarivelo AD, Lutz G, PetitJean C, Bousser M. Headache following carotid endarterectomy: a prospective study. *Cephalalgia* 1992;12:380-382.
  57. Jørgensen LG, Schroeder TV. Defective cerebrovascular autoregulation after carotid endarterectomy. *Eur J Vasc Surg* 1993;7:370-379.
  58. Soinne L, Helenius J, Tatlisumak T, Saimanen E, Salonen O, Lindsberg PJ, Kaste M. Cerebral hemodynamics in asymptomatic and symptomatic patients with high-grade carotid stenosis undergoing carotid endarterectomy. *Stroke* 2003;34:1655-1661.
  59. Ogasawara K, Konno H, Yukawa H, Endo H, Inoue T, Ogawa A. Transcranial regional cerebral oxygen saturation monitoring during carotid endarterectomy as a predictor of postoperative hyperperfusion. *Neurosurgery* 2003;53:309-315.
  60. Beard JD, Mountney J, Wilkinson JM, Payne A, Dicks J, Mitton D. Prevention of postoperative wound haematomas and hyperperfusion following carotid endarterectomy. *Eur J Vasc Endovasc Surg* 2001;21:490-493.

61. Haisa T, Kondo T, Shimpo T, Hara T. Post-carotid endarterectomy cerebral hyperperfusion leading to intracerebral haemorrhage. *J Neurol Neurosurg Psychiatry* 1999; 67:546.
62. Skydell JL, Machleder HI, Baker JD, Busuttil RW, Moore WS. Incidence and mechanism of post-carotid endarterectomy hypertension. *Arch Surg* 1987;122:1153-1155.
63. Darling RC, III, Kubaska S, Shah DM, Paty PSK, Chang BB, Lloyd WE, Leather RP. Bilateral carotid endarterectomy during the same hospital admission. *Cardiovasc Surg* 1996;4:759-762.
64. Habozit B, Derosier J, Gaillard A. Risk of early contralateral carotid endarterectomy. *Ann Vasc Surg* 1997;11:491-495.