

“Seeing oneself”: a case of autoscopia

GIOVANNA ZAMBONI, CARLA BUDRIESI, and PAOLO NICHELLI

Department of Neuroscience, University of Modena and Reggio Emilia, Italy

Autoscopia is the experience of seeing an image of one's body in external space. We describe the case of a patient who reported longstanding autoscopic hallucinations following post-eclamptic brain damage. The MR scan demonstrated damage involving the occipital cortex and the basal ganglia bilaterally.

We hypothesize that the image was the result of aberrant plasticity mechanisms involving cortical areas that play a central role in high-order body or representation of oneself.

Introduction

Autoscopia is the experience of seeing one's own body or its upper parts in external space, as though reflected in a mirror (Féré, 1891). Like previous authors (Brugger, 2002), we distinguish autoscopia from heautoscopy and from out-of-body experiences. Heautoscopy, also called the phenomenon of the double, is a reduplicative illusion: the belief that one has an exact double, which may or may not be visible. In an out-of-body experience, the subject appears to be awake and to see himself and the world from a location outside his physical body, usually from above. Autoscopia is usually experienced as unreal and hallucinatory, whereas heautoscopy and out-of-body experiences are mostly judged as vivid and veridical (Blanke *et al.*, 2004). These complex experiences of physical duality are usually brief and transient, lasting only a few seconds.

Autoscopic experiences have been reported following brain injury, brain tumors, stroke, and encephalitis. They also have been described in patients suffering from psychiatric disorders such as schizophrenia, depression, and dissociative disorders (Blanke *et al.*, 2004).

Most authors agree that the frequency of associated brain pathology points to an organic substrate for autoscopia, heautoscopy, and out-of-body experiences. These phenomena have been related to temporal (Devinsky *et al.*, 1989), parietal (Menninger-Lerchenthal, 1935; Lopez-Ibor, 1957), and parieto-occipital lesions (Hécaen and Ajiuriaguerra, 1952). Very recently Blanke argued that both out-of-body experiences and autoscopia are due to a cerebral dysfunction of the parieto-temporal junction (Blanke *et al.*, 2004).

Case report

We present the case of B.F., a 30-year-old, right-handed female, who developed gestosis and eclampsia, complicated by hemorrhagic shock, cardiocirculatory arrest, and still-birth. She regained consciousness following two days in a comatose state.

Twenty days after cardiocirculatory arrest, B.F. was alert, but on neurological examination showed cortical blindness and tetraparesis, more severe in the lower limbs. Fifty days after the onset, the MR scan showed bilateral occipito-polar damage extending to the right parieto-occipital junction and bilateral hyperintense signal alteration in the putamen, globus pallidus, and the head of the caudate nucleus on T2-weighted images (Figure 1). Insular cortex and thalamus were not involved. One month later a (99m)Tc-ECD SPET demonstrated bilateral posterior hypoperfusion, more extended to the right occipital lobe.

Three months after the onset, neuropsychological testing demonstrated severe object agnosia and alexia without agraphia. She was not able to recognize objects, famous faces, or letters, to discriminate between similar shapes, or to copy simple drawings. Visual acuity, visual fields, color discrimination and ability to detect a stimulus against a background were preserved. This picture was consistent with apperceptive agnosia. She also showed optic ataxia, ocular apraxia, impaired depth perception and deficit of spatial analysis, as simultanagnosia, with tendency to left side hemi-neglect. B.F. performed well in language and verbal intelligence tests. She showed a borderline performance in Babcock's story scale. Motor coordination, tactile and joint position sense were spared. At this time, tetraparesis was greatly improved: the patient was able to walk without assistance with a minimal residual right lower limb weakness.

It was during this assessment, at three months, that the patient first reported seeing her image as though it were reflected in a mirror. Like a mirror image, the image replicated her movements. In particular, any facial or arm movement she executed was reproduced in real time by the image and

Received 21 June 2004; accepted 3 November 2004

We want to thank the two reviewers for their helpful comments on our paper.

Address correspondence to Paolo Nichelli, MD, Department of Neuroscience, University of Modena and Reggio Emilia, Via Del Pozzo, 71, 41100 Modena Italy. E-mail: nichelli@unimo.it

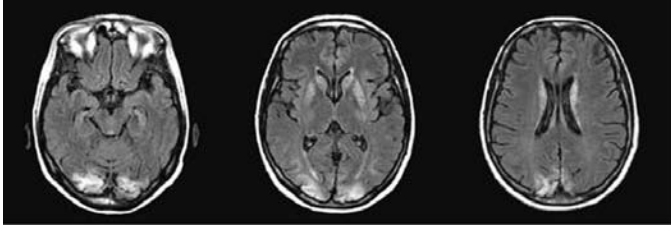


Fig. 1. FLAIR MRI image showing bilateral occipito-polar damage and bilateral hyperintense signal in the basal ganglia.



Fig. 2. Graphic representation of the autoscopy hallucination drawn by one of the examiners (G.Z.) following the description by the patient. Note the distance of the image, the perfect correspondence of movements, the apparent left-right reversal attributed to mirrors, the transparency of the image.

respected the apparent left-right reversal attributed to mirrors (Figure 2).

Wherever she looked, B.F. saw her mirror image right in front of her, at a distance that varied depending on where she was looking. The image appeared at a distance of about 1 meter if she was looking into the distance, seemed to be lying on the floor if she was looking down, or appeared on the ceiling if she was looking up. During the examination the image was interposed between the patient and the examiner. If a solid object, for example a sheet of paper, was placed between the mirror image and the patient, she said that she still saw the image, but nearer to her, on the surface of the paper. According to her description, it was as though the image, which was transparent, was set "on a sheet of glass" resting against whatever object she was looking at. The autoscopy image was somewhat blurred and she could not make out its colors or small details. It disturbed her vision of other objects, even though she could see through it. The image was

life-sized, appeared fully face on and usually included head and shoulders, but could extend as far as the legs if the patient explored it by moving the gaze downward over the figure. For example, the patient was able to see the legs if she looked carefully at the lower part of the image. The autoscopy figure was always dressed exactly like the patient.

If the examiner drew the outline of a circle on the patient's forehead with a black pencil she reported seeing something dark and round tattooed on the image's forehead. She reported seeing the same when the examiner touched her forehead with a capped pencil without inking her.

If the examiner put his hand on the patient's shoulder she said that she could perceive something on the image's shoulder similar to a hand.

The hallucinatory image had been present since B.F. regained consciousness. At the beginning the patient saw something similar to a person appearing on the ceiling of her hospital room. In a couple of days she realized that the image was always present if she paid attention to it. After one week, when she was recovering from tetraparesis, she noticed that the image imitated her own movements, in particular of the upper limbs. Then she began to recognize that the image had her own physical characteristics: for example, dark curly hair. During the recovery from coma, in the first couple of days after regaining consciousness, she also reported the hallucination of seeing the baby she had just lost.

B.F. reported perceiving her mirror image all the time. However, she noticed that its appearance was modulated by the degree of attention she paid to it. Thus, B.F. saw the image every time she opened her eyes, was sometimes able to "forget" it was there, yet would immediately see it again if she once more focused her attention on it. It disappeared when she closed her eyes.

The image was not associated with an emotional state and the patient appeared somewhat indifferent to its presence. She was conscious of the unreality of her visual experience and she was able to discuss it critically and quite freely. She had never attributed feelings or thoughts to the image, nor had she ever experienced depersonalization or regarded the image as her double.

Six months after the onset, a second neuropsychological evaluation showed improvement of the apperceptive agnosia. Recognition of drawings and photographs was still impaired, whereas recognition of corresponding objects was spared. The patient performed better in letters and number reading. Ocular apraxia was also improved but optic ataxia, simultanagnosia, and left side hemi-neglect were still present. Other cognitive abilities and neurological exam were negative. During this evaluation B.F. reported that her autoscopy image had gradually disappeared.

Discussion

We found few cases in the literature meeting the definition of autoscopy as a mirror hallucination without psychological attributions. Most were associated with epilepsy (Nouet, 1923;

Genner, 1947; Hécaen and Ajiuriagverra, 1952; Blanke, 2004). Specifically, the more recent case report concerned a patient with left temporal epilepsy (Blanke, 2004). One was secondary to right occipital ischemia (Bhaskaran *et al.*, 1990), and others were described in patients with psychiatric disorders (Lukianowicz, 1958). In these cases the autoscopic hallucination commonly lasts only a few seconds or minutes, even if it can appear repeatedly, and it is related to alteration of consciousness.

Conrad (1953) reported the only case that, in terms of the persistence over time of the autoscopic hallucination, can be considered similar to the one we present here. He described a man who, eight days after becoming blind, noticed a face in front of him and slowly, after a few days, recognized himself. The image did not change for seven years. As in our case, it was possible to carry out simple experiments on the image and the patient was somehow surprised about the results. Other similar characteristics were the not immediate self-recognition by the patient and the "attention related" appearance of the image. The author termed the image "mirror phantom" to distinguish it from other brief hallucinatory phenomena and proposed a common origin for both the phantom limb and the autoscopic image, on the basis of the persistence of the image over time. We propose that this "mirror phantom" might be the result of an aberrant plasticity mechanism.

West (1962) suggested that hallucinations are due to decreased sensory input releasing spontaneous activity of the CNS structures that normally mediate perceptual experience. Neuroimaging studies (ffytche *et al.*, 1998) confirmed an increased activity of ventral occipital regions in blind patients who experience spontaneous visual hallucinations. We would speculate that the autoscopic image originated from hyperactivity of visual extrastriate areas deprived of complex visual stimuli following bilateral occipital damage. This is consistent with the presence of the hallucination together with visual agnosia. In line with this hypothesis, the hallucination gradually disappeared during the patient's recovery from agnosia. To explain how this "spontaneous hyperactivity" originates an image of one's own self we would argue that this mechanism should be coupled with a sort of cross-modal plasticity. Cross-modal plasticity refers to the concept that the part of the cortex normally responsive to one sensory modality may become responsive to inputs from other sensory modalities (Sadato *et al.*, 1998).

Several investigations have suggested the existence of specific neural networks responsible for the representation of the self and of its interactions with the external world. These self-representational capacities of the brain are assumed to be distributed across several brain structures (Damasio, 2003; Northoff and Bermpohl, 2004). Neural correlates of ownership of one's body, as reflected in the body image, are assumed to involve the right insula (Farrer and Frith, 2002; Craig, 2003), ventromedial prefrontal cortex, and medial parietal areas (Craig *et al.*, 1999; Kelley *et al.*, 2002). In particular, other imaging studies have reported evidence of a neural substrate underlying facial self-recognition involving the right limbic system and left pre-frontal and temporo-parietal cortices (Kircher *et al.*, 2001).

In order to create a central representation of one's own body those areas must realize multisensory integration between different sensory source: vision, touch, proprioception, and so on (Maravita *et al.*, 2003). Blanke (2004) speculates that illusory reduplications of one's own body result from a failure to integrate proprioceptive, tactile and visual information in personal space. We would add that in case of persistent autoscopic experience hyperactivity of high-order cortical visual areas, deprived of their input, may have established "abnormal cross-talk" with cortical areas involved in body-schema representation. They may have been activated by integrated proprioceptive, tactile, and visceral integrated information (the body-schema representation), giving rise to a complex visual hallucination of one's own self.

Thus, we would argue that autoscopia is a visual interpretation of the representation of the self, in which self-sensory or proprioceptive information is transformed into a visual image.

References

- Bhaskaran R, Kumar A, Nayar PC. Autoscopia in emianopic field. *Journal of Neurology, Neurosurgery, and Psychiatry* 1990; 53: 1016–1017.
- Blanke O, Landis T, Spinelli L, Seeck M. Out-of-body experience and autoscopia of neurological origin. *Brain* 2004; 127: 243–258.
- Brugger P. Reflective mirrors: Perspective-taking in autoscopic phenomena. *Cognitive Neuropsychiatry* 2002; 7(3): 179–194.
- Conrad K. Un cas singulier de "Fantome spéculaire". Phénomène héautoscopique comme état permanent dans une tumeur de l'hypophyse. *Encephale* 1953; 42: 338–352.
- Craig AD. Interoception: The sense of the physiological condition of the body. *Current Opinion in Neurobiology* 2003; 13: 500–505.
- Craik FI, Moroz T, Moscovitch M, Stuss DT, Winocur G, Tlving E, et al. In search of the self: A positron emission tomography study. *Psychological Science* 1999; 10: 26–34.
- Damasio AR. The person within. *Nature* 2003; 423: 227.
- Devinsky O, Feldmann E, Burrows K, Bromfield E. Autoscopic phenomena with seizures. *Archives of Neurology* 1989; 46: 1080–1088.
- Farrer C, Frith CD. Experiencing oneself vs another person as being the cause of an action: The neural correlates of the experience of agency. *Neuroimage* 2002; 15: 596–603.
- Féré C. Note sur les allucinations autoscopiques ou spéculaires et sur les hallucinations altruistes. *Comptes Rendus de la Société de Biologie* 1891; 43: 451–453.
- ffytche DH, Howard RJ, Brammer MJ, David A, Woodruff P, Williams S. The anatomy of conscious vision: An fMRI study of visual hallucinations. *Nature Neuroscience* 1998; 1(8): 738–742.
- Genner T. Das Sehen des eigenen spiegelbildes als epileptisches äquivalent. *Wiener Klinische Wochenschrift* 1947; 59: 656–658.
- Hécaen H, Ajiuriaguerra J. L'héautoscopique. In: Hécaen H, Ajiuriaguerra J, editors. *Méconnaissances et hallucinations corporelles*. Paris: Masson, 1952; p. 310–343.
- Kelley WM, Macrae CN, Wyland CL, Caglar S, Inati S, Heatherton TF. Finding the self? An event related fMRI study. *Journal of Cognitive Neuroscience* 2002; 14(5): 785–794.
- Kircher TJ, Senior C, Phillips ML, Rabe-Hesketh S, Benson P, Bullmore ET, et al. Recognizing one's own face. *Cognition* 2001; 78: B1–B15.
- Lopez-Ibor J. Analyse structurale de l'expérience de dépersonnalisation. *Encephale* 1957; 5–6: 630–638.
- Lukianowicz N. Autoscopic phenomena. *Archives of Neurology and Psychiatry* 1958; 80: 199–220.

- Maravita A, Spence C, Driver J. Multisensory integration and the body schema: Close to hand and within to reach. *Current Biology* 2003; 13: R531–R539.
- Menninger-Lerchenthal E. *Das truggebilde der eigenen gestalt*. Berlin: Karger, 1935.
- Northoff G, Bermpohl F. Cortical midline structures and the self. *Trends in Cognitive Sciences* 2004; 8(3): 102–107.
- Nouet H. Hallucinations speculaires et traumatisme crânien. *Encephale* 1923; 18: 327–329.
- Sadato N, Pascual-Leone A, Grafman J, Deiber MP, Ibanez V, Hallett M. Neural networks for Braille reading by the blind. *Brain* 1998; 121 (Pt 7): 1213–1229.
- West IJ. A general theory of hallucinations and dreams. In: West IJ, editor. *Hallucinations*. New York: Grune & Stratton, 1962; p. 275–291.