


This article was downloaded by: [FU Berlin]

On: 26 November 2014, At: 08:26

Publisher: Routledge

Informa Ltd Registered in England and Wales Registered Number: 1072954 Registered office: Mortimer House, 37-41 Mortimer Street, London W1T 3JH, UK



Neurocase: The Neural Basis of Cognition

Publication details, including instructions for authors and subscription information:

<http://www.tandfonline.com/loi/nncs20>

Post Graphemic Impairments Of Writing: The Case Of Micrographia

Gianfranco Denes^{a b}, Matteo Signorini^{a b c} & Chiara Volpato^{a c}

^a Dept. of Neurology, Venice Hospital, Venice, Italy

^b Dept. of Science of Language, Ca' Foscari Venice University, Venice, Italy

^c AfaR - Fatebenefratelli Hospital, Venice, Italy

Published online: 16 Feb 2007.

To cite this article: Gianfranco Denes, Matteo Signorini & Chiara Volpato (2005) Post Graphemic Impairments Of Writing: The Case Of Micrographia, *Neurocase: The Neural Basis of Cognition*, 11:3, 176-181, DOI: [10.1080/13554790590944636](https://doi.org/10.1080/13554790590944636)

To link to this article: <http://dx.doi.org/10.1080/13554790590944636>

PLEASE SCROLL DOWN FOR ARTICLE

Taylor & Francis makes every effort to ensure the accuracy of all the information (the "Content") contained in the publications on our platform. However, Taylor & Francis, our agents, and our licensors make no representations or warranties whatsoever as to the accuracy, completeness, or suitability for any purpose of the Content. Any opinions and views expressed in this publication are the opinions and views of the authors, and are not the views of or endorsed by Taylor & Francis. The accuracy of the Content should not be relied upon and should be independently verified with primary sources of information. Taylor and Francis shall not be liable for any losses, actions, claims, proceedings, demands, costs, expenses, damages, and other liabilities whatsoever or howsoever caused arising directly or indirectly in connection with, in relation to or arising out of the use of the Content.

This article may be used for research, teaching, and private study purposes. Any substantial or systematic reproduction, redistribution, reselling, loan, sub-licensing, systematic supply, or distribution in any form to anyone is expressly forbidden. Terms & Conditions of access and use can be found at <http://www.tandfonline.com/page/terms-and-conditions>

Post graphemic impairments of writing: The case of micrographia

GIANFRANCO DENES^{1,2}, MATTEO SIGNORINI^{1,2,3}, and CHIARA VOLPATO^{1,3}

¹Dept. of Neurology, Venice Hospital, ²Dept. of Science of Language, Ca' Foscari Venice University, and ³AFaR - Fatebenefratelli Hospital, Venice, Italy

Micrographia (MG), an acquired impairment of writing characterized by diminution of letter size, coupled with slowing and loss of accuracy, is most frequently observed in the course of degenerative disease of basal ganglia, such as Parkinson's Disease. Only a few cases of MG without concomitant extrapyramidal signs have been described, mostly following vascular lesion of the left basal ganglia.

In this article we report an isolated pattern of MG following an extensive traumatic cerebral lesion centered in the left basal ganglia. The nature of this impairment is analyzed according to a cognitive model of writing and interpreted as a specific example of peripheral dysgraphia.

Introduction

Any cognitive model of writing includes central and peripheral processes (Caramazza, 1988; Ellis, 1988a). Central processes involve a number of functionally, if not anatomically, distinct components, whose task is to retrieve stored spellings in the central lexicon, or to convert phonological representations into orthographic representations sublexically.

The final product of these processes is then temporarily stored in the graphemic buffer (Caramazza *et al.*, 1987; Schonauer and Denes, 1994), whose task is to maintain the activation level of the identity and order of letter sequences for the time needed for the sequential assignment of format-specific information.

Peripheral processes are involved in the task of translating the distinct specific letter representations into specific letter names or letter shapes, via letter name or letter shape conversion processes (Ellis, 1988b; Rapp and Caramazza, 1997). These processes can dissociate, as shown by the patient reported by Chialant, Domoto-Reilly, Proios and Caramazza (2002), that had intact oral spelling, but severely impaired written spelling. Ellis (1982) proposed that at least two stages below the graphemic level should be identified in the production of handwriting, the allographic and the graphomotor levels.

The allographic representation is a quasi-spatial representation of each letter form. B, b, *ℓ* are all allographs of the same grapheme, which can be selectively used by a person handwriting according to the needs and rules. The errors at this stage are characterized either by case substitution

(De Bastiani and Barry, 1989) or visually similar letters substitution (Ellis 1988). Selective deficits in writing upper case (Trojano and Chiacchio, 1994) or lower case (Patterson and Wing, 1997) letters and words are often assumed to reflect the existence of independent representations of cursive and print style. Silveri (1996) reported a patient who was much better in writing cursive than uppercase print. The opposite dissociation was reported by Hanley and Peters (1996), whose patient was much more severely impaired at writing in lower case than in upper case letters.

The second stage is the retrieval of the graphic motor program (Van Galen, 1980), which will guide the movement of the pen specifying the sequence, direction and relative size of the strokes to be produced. The information about abstract spatio-temporal movement aspects, such as size, sequence, position and direction of strokes necessary to write letters, is included in graphic motor programs: these programs, independent from the muscle group necessary for the movement execution, don't, however, specify parameters of an absolute stroke size or duration, and are distinct from motor programs involved in other limb movements (Ellis 1982, 1988). Patients, whose impairment is assumed to lie at the level of the graphic motor program, often write shapes that are not real letters. Baxter and Warrington (1986) described a nonapraxic patient with intact oral spelling, who was unable to write even single letters, his errors involving writing incorrect, incomplete letters and forms which looked like fusions of two letters. In contrast their patient could flawlessly copy written texts. The opposite dissociation was present in the patient described by Cipolotti and Denes (1989), who showed a pattern of spared spontaneous and impaired writing on copy, coupled with severe limb and constructional apraxia.

The final stage of the motor control system of handwriting consists of the translation of the graphic motor programs into

Received 28 April 2004, accepted 6 January 2005.

Address correspondence to Dr. Gianfranco Denes, Dept. of Neurology, Ospedale Civile di Venezia, Campo SS Giovanni e Paolo 30122, Venezia, Italy. E-mail: denes@unive.it.

sequences of graphic motor commands; a deficit of the system ascribed to generate graphic innervatory patterns results in a defective control of force, amplitude and speed of writing.

The most frequent example of peripheral dysgraphia is the writing impairment present in Parkinson's Disease (PD), a degenerative disorder of the brain, characterized by a degeneration of the dopaminergic nigrostriatal neurons of the basal ganglia, resulting in akinesia, rigidity and tremor (Mardesen and Obeso, 1994). Writing of PD patients, consequent to an impairment of control and speed, results in a combination of hypometria and bradykinesia, the first impairment giving rise to a reduction of letter size, Micrographia (MG), and the second to an increased length and loss of accuracy. MG includes progressive diminution of letter size as the subject continues to write, in addition to overall smallness. MG must be distinguished from "the fine, dainty style, sometimes observed in the handwriting of the learned" (Pick, 1903). The presence (10–15% of PD patients) and severity of MG is neither related to the occurrence of other extrapyramidal symptoms, such as tremor, rigidity and bradykinesia, nor to the degree of severity of illness.

In some cases MG has been described in isolation or not in the context of PD. Since Pick's seminal observation (1903) of isolated MG following a syphilitic infarct of the left thalamus, this symptom has been reported following a lesion different from the condition usually linked to PD. MG has been described following lesions, mostly of vascular origin, of the left basal ganglia including putamen, globus pallidus, thalamus or substantia nigra (Scolding and Lees, 1994; Pullicino *et al.*, 1994; Kim *et al.*, 1998; Derkinderen *et al.*, 2002; Nakamura *et al.*, 2003; Troyer *et al.*, 2004), sometimes as the only clinical manifestation (Martinez-Vila *et al.*, 1988), in other cases with concomitant mild deficits of expressive language and verbal memory (Pullicino *et al.*, 1994), attentional disorders (Troyer *et al.*, 2004) or focal dystonia (Münchau *et al.*, 2000); a pattern of MG and hypophonia has been described in a case of extensive cerebral vein thrombosis (Murray *et al.*, 2000) or associated to the dysarthria-clumsy hand syndrome (Noda *et al.*, 1994). Finally, MG has been reported following a parietal lobe lesion in Multiple Sclerosis (Scolding and Lees, 1994).

The underlying reasons for a motor disorder such as MG are not clear: from the anatomical point of view, basal ganglia structures exert their influence on motor behavior through connections to frontal premotor areas via a major reentrant basal ganglia-thalamo-cortical motor loop (Alexander *et al.*, 1986). Operating as a functional unit, this neural network plays a critical role in controlling movement force, speed and amplitude. According to the influential force impulse model of handwriting proposed by Wing (1978), changes in letter height can be produced by altering applied force (amplitude or duration) or interpose interval. On this basis, Margolin and Wing (1983), and Demirci *et al.* (1997) proposed that MG could be caused by the combined effect of reduced kinesthesia and reduced motor output. Finally MG in PD has been interpreted as a manifestation of a generalized hypometria evident in other tasks such as drawing (Longstaff *et al.*, 2003).

In the present article, starting from the description of a case of MG following head trauma (pistol shot) in the left basal ganglia, we'll try to clarify the nature of MG.

Case report

P.P is a 43- year- old right-handed woman, with a university degree in business administration, working as a tax consultant. Previous medical history was unremarkable until the age of 40 when, in the course of a depressive episode, she attempted suicide, shooting her head with a gun. The patient was admitted to a neurosurgical unit and operated on, but the bullet was not removed from her brain. After an initial state of coma, the patient started to improve and was discharged 15 days later in good condition and in antiepileptic prophylaxis (Phenobarbital 100 mg a day) that the patient followed for about one year.

She resumed her work four months later, her only complaint being a change of writing, that became micrographic, a mild dystonic position of the fourth and fifth fingers of the right hand and, to a lesser degree, of the right foot.

A cerebral MRI (June 2001) showed the following pattern: a bullet is located in the left basal ganglia; given, however, its high density, the bullet provokes many artifacts. A large proencephalic cavity is situated close to the bullet, in the region corresponding to the head of caudate and lenticular nucleus. A wide area of cortico-subcortical atrophy involves the right frontal lobe in the region corresponding to the entry hole of the bullet (Figure. 1).

The patient was seen in our clinic three years after the trauma, at the age of 43. Neurological examination showed a slight dystonic position of the ring and little fingers of the right hand and of the toe of the right foot, but no other evidence of dystonia. Muscle tone was normal and she could easily perform rapid movements of alternating fingers. Power and reflexes were normal. Plantars were flexor. Arm swing was normal. Cranial nerve examination was normal, with normal facial mimic and no gaze abnormalities.

Neuropsychological examination

The patient was fully alert, cooperative and her mood was normal. Her score on the WAIS-R Test (Wechsler 1974) was normal (Full-scale IQ 132). Executive Functions: her performance on attention tests was above average: digit span forward 7 (n.v.≥3.75, Orsini *et al.*, 1987), spatial span (Corsi Test) 5 (n.v.3.50, Orsini *et al.*, 1987). Category naming following semantic and phonemic cueing was normal: semantic 30 (n.v.≥25), phonemic 32 (n.v.≥17) (Novelli *et al.*, 1986). In a shortened version of the Tower of London Test (Shallice, 1982) her performance was 4/4 correct.

Memory: episodic and semantic memory in every day life were normal as proved by her successful working activity. On the Wechsler Memory Scale (Wechsler, 1945) she obtained a Memory Quotient of 143.

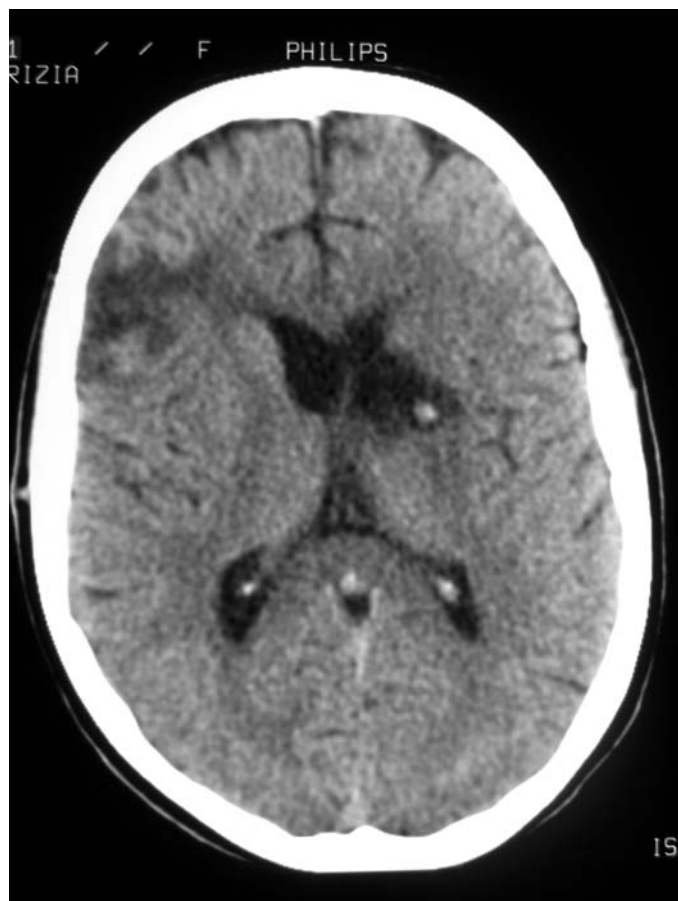

Fig. 1. Cerebral MRI showing a bullet located in the left basal ganglia. A large proencephalic cavity is situated close to the bullet, in the region corresponding to the head of caudate and lenticular nucleus. A wide area of cortico-subcortical atrophy involves the right frontal lobe in the region corresponding to the entry hole of the bullet.

Her performance on an Italian version of Aachen Aphasia Test (Luzzatti *et al.*, 1991) was flawless: spontaneous speech, repetition, naming, oral and written comprehension, reading were normal. Apart from MG (*vide infra*) her written production was normal, from the orthographic, lexical and syntactic point of view. Oral and written calculation was flawless.

The patient was submitted to an Apraxia Battery, tapping Ideatory, Ideomotor and Limb-kinetic Apraxia (Denes *et al.*, 1998), currently in use in our Unit, and her performance was perfect.

Experimental section

Methods

The patient was submitted to a series of graphic tasks, tapping her skills in processing alphabetic and non-alphabetic material, such as drawing and copying meaningful and meaningless pictures. In order to investigate if MG was a consequence of a strategy to maintain accuracy in order to reduce

movement variability (Longstaff *et al.*, 2003) in writing tasks, we explored several variables such as spontaneous writing versus writing on copy and the use of different allographs and characters.

Writing to dictation. The patient was asked to write to dictation a short text, two lists of 20 high frequency words, and two lists of nonwords of different length (two-four syllables), half in cursive and the other half in capital letters.

Writing from copy. A similar list was presented to the patient, whose task was to copy it in the same and double dimension. The stimuli to be processed were written in Times New Roman Character, corpus 16 (capital letters) and Lucida Handwriting, corpus 16 (cursive letters).

Transcoding. The patient was asked to translate a similar list written in block letters in italics and vice-versa.

Drawing from copy. The patient was asked to copy 30 items from Benton's Visual Retention task (Benton, 1945).

Copying of Japanese characters. The patient was asked to copy a list of ten Japanese words, approximately two centimeters in height, under three conditions: same size, double size and half size.

Follow-up

The patient was required to repeat all the tasks on a follow-up evaluation after six months.

Results

Alphabetic tasks

Writing to dictation

Writing was fluent, composed of well written letters, the style of writing being the same as before the trauma except for the MG: a definite pattern of MG was evident both on writing in capital letters and in cursive, without any difference in writing sentences or single words. Her MG pattern was compared with a sample of her handwriting before the accident: the size of actual writing was about one-third of the previous writing size, for example, the height of the cursive *f* was 14 mm. before the trauma and 5 mm in MG writing. In contrast with PD patients the height of the letters was the same throughout the text, without progressive tendency to diminution and with good accuracy (Figure. 2).

Transcoding

MG was evident in translating block letters into cursive and vice versa.

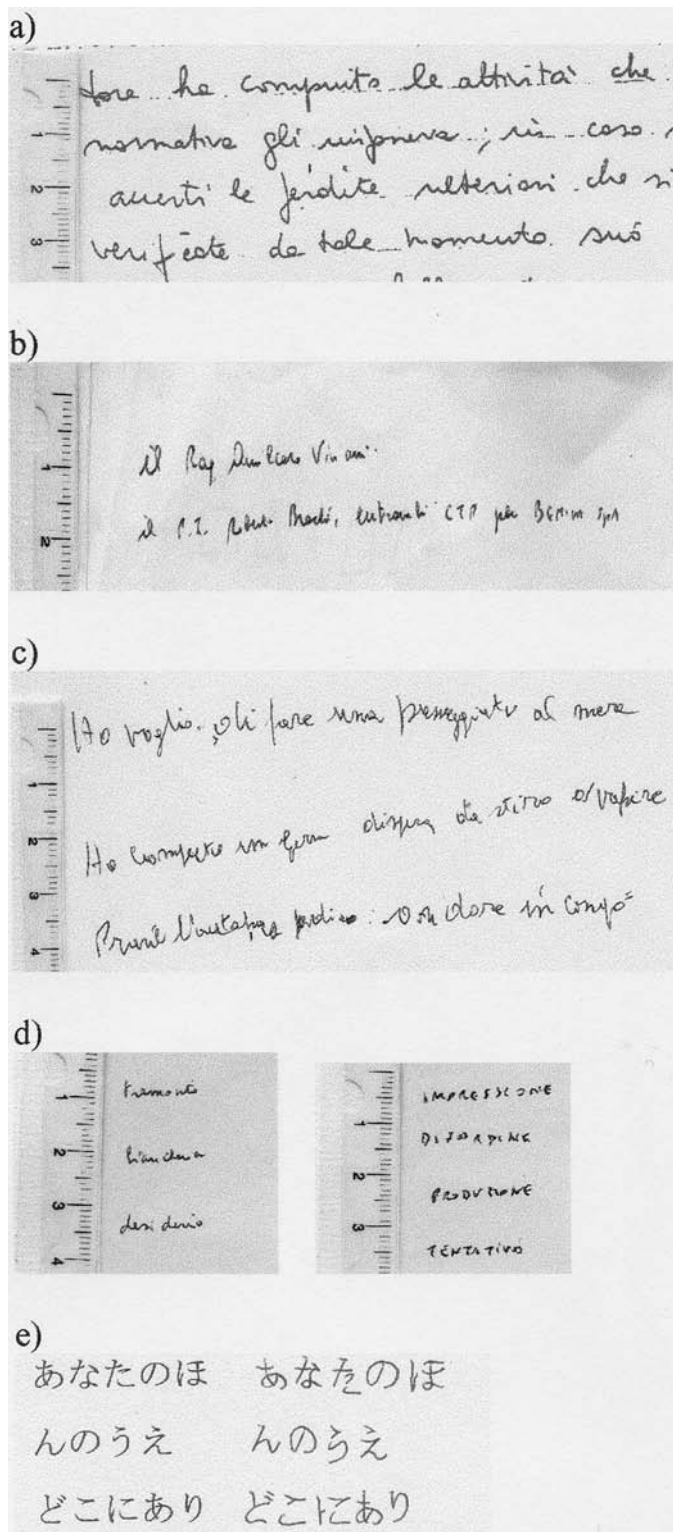


Fig. 2. (a) Spontaneous writing of P.P. before the trauma; (b) spontaneous writing of P.P. 3 years after the trauma; (c) spontaneous writing of a patient with Parkinson's Disease and MG; (d) P.P.: Writing to dictation in cursive and capital letters; (e) P.P.: writing from copy of non-alphabetical signs. Note the accuracy of P.P.'s MG compared with PD's MG.

Writing on copy

MG was evident only on copying cursive, while copying of words in capital letters was normal. In the double dimension copy task the correct dimension was evident only in copying capital letters.

Non alphabetic tasks

Writing arabic numbers

The patient's production was correct, but micrographic.

Drawing on copy

The patient copied the drawings flawlessly, following the model size.

Copying of Japanese characters

The patient's performance was flawless and the dimension of her production strictly followed the model.

Follow up

At the follow-up control, six months later, the patient reported that she could write in normal dimensions using capital letters, a strategy that she adopted in everyday writing. On testing, MG was evident only in cursive writing.

Discussion

In this study we report the case of a highly educated patient who, following an extensive lesion of the left basal ganglia of traumatic origin (gunshot), developed a definite pattern of MG, its only accompanying deficit being a very mild dystonia of right hand and foot; in particular, unlike other cases of MG following focal lesion, there was not hypophonia (Murray *et al.*, 2000; Nakamura *et al.*, 2003), or clumsiness of hand movements.

At variance with the MG present in PD, P.P.'s writing was not distorted, and did not show a progressive reduction in writing size as the length of the text to be produced increased, her MG pattern being constant throughout the text. This latter finding excludes that her MG was secondary to an increase of processing load, consequent to the increased coordination and control of fingers, wrist and arm during writing and the processing of future words, or increased extension of the wrist joint, as the execution of the writing progresses to the right across the page (Van Gemmert *et al.*, 2001).

Actual production of letters in handwriting is dependent upon a graphic motor plan, which specifies the appropriate sequence of strokes, while graphic innervatory patterns specify their relative size. Only a few cases are reported in the literature where a detailed analysis of isolated MG is provided: Troyer *et al.* (2004) reported a case of MG, following a left basal ganglia lesion of ischemic origin, context

dependent, thus appearing only on spontaneous writing, but not when copying sentences or drawing: they interpreted this dissociation as an effect of task difficulty (spontaneous writing requires the generation and expression of ideas, while copying has no demands on generation or expressive language). P.P.'s MG was present both in cursive and capital letters (spontaneous writing and dictation), in writing texts and single words and persisted even when she had to copy in large dimensions. Her production was fluent, syntactically and semantically correct, as was her spontaneous language. P.P. was able to retrieve and produce the appropriate sequence of strokes, she respected the difference in size in writing capital letters at the beginning of text and sentences and the cursive writing in the remaining words. This finding clearly shows that the patient has an intact graphemic code, her only writing impairment being an inability to form the appropriate letter size. Similarly to the patient of Troyer *et al.* (2004), spontaneous drawing, drawing from copy and copying of non-alphabetical graphic signs (*Japanese characters*), were flawless, without any tendency to size reduction.

At the follow-up, MG was present only in cursive writing, while spontaneous writing in capital letters, as well as copying of cursive, was of normal size.

This dissociation could be ascribed to the work of different processes used in handwriting: automatic and controlled: writing in cursive, the usual, everyday writing, is a fast, familiar process; in addition, the production of the single letters of a word to be written requires an anticipation process that could vary according to the subsequent letter; on the other hand, writing words in capital letters is a less frequent, slower process and the composition of the letters is not influenced by the presence of preceding or subsequent letters. It is not unreasonable to postulate that cursive writing requires less conscious attention to the mechanic output, while writing in capital letters, copying and drawing require more visual control; this in turn could exert a positive influence in modifying the writing size reduction. While MG present in PD patients is easily interpreted as an epiphenomenon of a diminution of force, with secondary changes in timing and in some subjects to the effect of tremor (Margolin and Wing, 1983), the question of the underlying deficit in pure MG is far from being resolved: most of the published reports are merely descriptive and do not deal with this problem.

Two possible answers could be offered, one based on the presence of a subtle motor deficit not evident in other tasks, whose execution does not require such a fine degree of motor control as in writing. Pullicino *et al.* (1994) and more recently Nakamura *et al.* (2003) suggest that a disruption of the connections between basal ganglia and frontal lobes could play a major role in the pathogenesis of MG due to the damage of one of the frontal-subcortical motor circuits. The second hypothesis, more attractive from a cognitive point of view, postulates a specific role of the basal ganglia in the process of choosing and realizing the appropriate size of the letters to be written, once the graphomotor plan is realized.

Finally, of particular interest was the normality of P.P.'s cognitive functions: there is considerable evidence that damage to the basal ganglia is frequently associated with both direct effects and indirect effects due to the interruption of the frontal-subcortical circuits and consequent effects on frontal lobe functions. Thus, it could be easily predicted that our patient should have been affected by cognitive deficits similar to those found in frontal lobe-damaged patients such as impairments of executive functions (impaired attention, working memory, planning, etc.). (For a summary see Faglioni, 1999). More than her normal to superior performance in the tests to which the patient was submitted in the course of the present work, particularly indicative of the normality of her cognitive skills was her highly successful professional activity as head of an important tax consultant firm.

The implication of such a pattern of cognitive normality, despite the gross anatomical lesion, is intriguing and we cannot offer a reasonable explanation. Only multiple single case studies (Shallice, 1988) can help to disentangle the problem of selective deficit or sparing of cognitive functions in patients with basal ganglia lesions.

References

- Alexander GE, DeLong MR, Strick PL. Parallel organization of functionally segregated circuits linking basal ganglia and cortex. *Annual Review of Neuroscience* 1986; 9: 357–81.
- Baxter DM, Warrington EK. Ideational apraxia: A single case study. *Journal of Neurology, Neurosurgery and Psychiatry* 1986; 49: 369–74.
- Benton AL. A visual retention test for clinical use. *Archives of Neurology and Psychiatry* 1945; 54: 212–6.
- Caramazza A. Some aspects of language processing revealed through the analysis of acquired dysgraphia: The lexical system. *Annual Review of Neuroscience* 1988; 11: 395–421.
- Caramazza A, Miceli G, Villa G, Romani C. The role of the Graphemic Buffer in spelling: Evidence from a case of acquired dysgraphia. *Cognition* 1987; 26: 59–85.
- Chialant D, Domoto-Reilly K, Proios H, Caramazza A. Preserved orthographic length and transitional probabilities in written spelling in a case of acquired dysgraphia. *Brain and Language* 2002; 82: 30–46.
- Cipolotti L, Denes G. When a patient can write but not copy: Report of a single case. *Cortex* 1989; 25: 331–7.
- De Bastiani P, Barry C. A cognitive analysis of an acquired dysgraphic patient with “allographic” writing disorder. *Cognitive Neuropsychology* 1989; 6: 25–41.
- Demirci M, Grill S, McShane L, Hallett M. A mismatch between kinesthetic and visual perception in Parkinson's disease. *Annual Neurology* 1997; 41: 781–8.
- Denes G, Mantovan MC, Gallana A, Cappelletti JY. Limb-kinetic apraxia. *Movement Disorders* 1998; 13: 468–76.
- Derkinderen P, Dupont S, Vidal JS, Chedru F, Vidailhet M. Micrographia secondary to lenticular lesions. *Movement Disorders* 2002; 17: 835–7.
- Ellis AW. Spelling and writing (and reading and speaking). In: Ellis AW, editor, *Normality and pathology in cognitive function*. London: Academic Press, 1982.
- Ellis AW. Reading, writing and dyslexia. Hove, UK: LEA Publishers, 1988a.
- Ellis AW. Normal writing processes and peripheral acquired dysgraphias. *Language and Cognitive Processes* 1988b; 3: 99–127.

- Faglioni P. The frontal lobe. In: Handbook of clinical and experimental neuropsychology. Denes G, Pizzamiglio E, editors. Hove: Psychology Press, 1999; 525–570
- Hanley JR, Peters S. A dissociation between the ability to print and write cursorily in lower-case letters. *Cortex* 1996; 32: 737–45.
- Kim JS, Im JH, Kwon SU, Kang JH, Lee MC. Micrographia after thalamo-mesencephalic infarction: evidence of striatal dopaminergic hypofunction. *Neurology* 1998; 51: 625–7.
- Longstaff MG, Mahant PR, Stacy MA, VanGemert AW, Leis BC, Stelmach GE. Discrete and dynamic scaling of the size of continuous graphic movements of parkinsonian patient and elderly controls. *Journal of Neurology, Neurosurgery and Psychiatry* 2003; 74: 299–304.
- Luzzatti C, Willmess K, De Bleser R. Aachener Aphasia Test. Firenze, Italy: Organizzazioni Speciali 1991.
- Margolin DI, Wing AM. Agraphia and micrographia: clinical manifestations of motor programming and performance disorders. *Acta Psychologica (Amst)* 1983; 54: 263–83.
- Marsden CD, Obeso JA. The functions of the basal ganglia and the paradox of stereotaxic surgery in Parkinson's disease. *Brain* 1994; 117: 877–97.
- Martinez-Vila E, Artieda J, Obeso JA. Micrographia secondary to lenticular haematoma. *Journal of Neurology Neurosurgery and Psychiatry* 1988; 51: 1353.
- Münchau A, Mathen D, Cox T, Quinn NP, Marsden CD, Bhatia KP. Unilateral lesions of the globus pallidus: Report of four patients presenting with focal or segmental dystonia. *Journal of Neurology, Neurosurgery and Psychiatry* 2000; 69(4): 494–8.
- Murray BJ, Llinas R, Caplan LR, Scammell T, Pascual-Leone A. Cerebral deep venous thrombosis presenting as acute micrographia and hypophonia. *Neurology* 2000; 54: 751–3.
- Nakamura M, Hamamoto M, Uchida S, Nagayama H, Amemiya S, Okubo S, Tanaka K. A case of micrographia after subcortical infarction: Possible involvement of frontal lobe function. *European Journal of Neurology* 2003; 10: 593–6.
- Noda S, Itoh H, Goda S. Micrographia due to focal cerebral lesions as seen in the dysarthria-clumsy hand syndrome. *Neurology* 1994; 44: 150–1.
- Novelli G, Papagno C, Capitani E, Laiacona M, Vallar G, Cappa SF. Tre test clinici di ricerca e produzione lessicale: Taratura su soggetti normali. *Archivio di Neurologia, psichiatria e psicologia* 1986; 47: 477–505.
- Orsini A, Grossi D, Capitani E, Laiacona M, Papagno C, Vallar G. Verbal and spatial memory span: normative data from 1355 adults and 1112 children. *Italian Journal of Neurological Sciences* 1987; 85: 39–48.
- Patterson K, Wing AM. Processes in hand-writing: A case for case. *Cognitive Neuropsychology* 1997; 6: 1–23.
- Pick A. Ueber eine eigenthumliche Schreibstörung, Mikrographie, in Folge cerebraler Erkrankung. *Prag Med Wochenschr* 1903; 28: 1–4. Quoted by LeWitt PA. Micrographia after thalamo-mesencephalic infarction. *Neurology* 1999; 52: 1921–2.
- Pullicino P, Lichter D, Benedict R. Micrographia with cognitive dysfunction: “Minimal” sequelae of a putaminal infarct. *Movement Disorders* 1994; 9: 371–3.
- Rapp B, Caramazza A. From graphemes to abstract letter shapes: levels of representation in written spelling. *Journal of Experimental Psychology and Human Perception Performance* 1997; 23: 1130–52.
- Schonauer K, Denes G. Graphemic jargon: A case report. *Brain and Language* 1994; 47: 279–99.
- Scolding NJ, Lees AJ. Micrographia associated with parietal lobe lesion in multiple sclerosis. *Journal of Neurology, Neurosurgery and Psychiatry* 1994; 57: 739–41.
- Shallice T. Specific impairments of planning. *Philosophical transactions of the Royal Society of London. Series B, Biological Sciences* 1982; 298: 199–209.
- Shallice T. From neuropsychology to mental structure. Cambridge University Press, 1988.
- Silveri MC. Peripheral aspects of writing can be differentially affected by sensorial and attentional defect: evidence from a patient with afferent dysgraphia and case dissociation. *Cortex* 1996; 32: 155–72.
- Trojano L, Chiacchio L. Pure dysgraphia with relative sparing of lower-case writing. *Cortex* 1994; 30: 499–501.
- Troyer AK, Black SE, Armillo ML, Moscovitch M. Cognitive and motor functioning in a patient with selective infraction of the basal ganglia: evidence for decrease non routine response selection and performance. *Neuropsychologia* 2004; 42: 902–911.
- Van Galen, GP. Handwriting and drawing: A two stage model of complex motor behaviour. In Stelmach G, Requin S, editors. *Tutorials in motor behavior*. Amsterdam; North Holland, 1980.
- Van Gemmert AW, Teulings HL, Stelmach GE. Parkinsonian patients reduce their stroke size with increased processing demands. *Brain and Cognition* 2001; 47: 504–12.
- Wechsler D. A standardized memory scale for clinical use. *Journal of Psychology* 1945; 19: 87–95.
- Wechsler D. *Adult Intelligence Scale*. Firenze, Italy: Organizzazioni Speciali, 1974.
- Wing A. Response time in handwriting. In: Stelmach GE, editor. *Information processing in motor control and learning*. New York: Academic Press, 1978.