

Deep White Matter Pathologic Features in Watershed Regions

A Novel Pattern of Central Nervous System Involvement in MELAS

Liana G. Apostolova, MD; Matthew White, MD; Steven A. Moore, MD, PhD; Patricia H. Davis, MD

Background: Myopathy, encephalopathy, lactic acidosis, and stroke-like episodes (MELAS) syndrome typically manifests in adults younger than 40 years with encephalopathy, stroke-like episodes, and lactic acidosis. Magnetic resonance imaging (MRI) abnormalities typically involve the cortical gray and the adjacent subcortical white matter.

Objective: To describe a 58-year-old woman diagnosed with MELAS who was initially seen with acute myopathy, cardiac ischemia, psychosis, and MRI changes in a watershed distribution.

Results: Initial MRI of the brain showed the characteristic parieto-occipital gray matter lesions involving the adjacent white matter. Follow-up MRI revealed striking

deep white matter involvement in a watershed distribution. A cerebral angiogram and thorough hypercoagulable workup results were normal. Electromyography showed acute denervation and myopathy. A muscle biopsy specimen revealed ragged red and cytochrome-c oxidase-negative fibers. Mitochondrial DNA analysis revealed an A3243G mutation.

Conclusions: Myopathy, encephalopathy, lactic acidosis, and stroke-like episodes should be considered in older patients with myopathy, cardiomyopathy, encephalopathy, and unaccountable MRI findings. Watershed pathologic features are a rare pattern of cerebral involvement in MELAS.

Arch Neurol. 2005;62:1154-1156

REPORT OF A CASE

A 58-year-old, right-handed woman was hospitalized twice for unstable angina. Electrocardiography revealed diffuse ischemic ST-T changes. Her creatine kinase level was normal. Her troponin level was elevated at 5.2 µg/mL (reference range, <0.5 µg/mL). Two coronary angiograms failed to demonstrate significant stenosis. Three days later, she awoke with bilateral, painless proximal arm weakness. She was transferred to our institution for further evaluation. Her history included hypertension, asthma, and chronic fatigue but no headaches, nausea, emesis, dysarthria, dysphagia, or visual or sensory deficits. Her parents and brother had coronary artery disease. There was no family history of stroke, headaches, seizures, weakness, hearing loss, short stature, or endocrinopathies.

On hospital admission, her mental status, cranial nerves, funduscopy results, sensory examination results, tendon reflexes, and plantar responses were normal. On manual muscle testing, her right

deltoid, left wrist flexors and extensors, and left finger extensors had a strength grade of 1/5. Her left deltoid was 3/5. Her right wrist and finger extensors, iliopsoas, and tibialis anterior muscles were 4/5. The remaining muscles were full strength. She was able to stand but unable to walk.

Outside magnetic resonance imaging (MRI) revealed several T2 and fluid-attenuated inversion recovery hyperintensities in the centrum semiovale and few parieto-occipital cortical lesions. A transesophageal echocardiogram revealed ejection fraction of 46% and mild tricuspid regurgitation. There were neither intracardiac thrombi nor right-to-left shunts. Antinuclear antibody, double-stranded DNA antibody, antineutrophil cytoplasmic antibody, anti-SSA/Ro and anti-SSB/La antibodies, anti-Smith antibody, C3, C4, and rheumatoid factor test results were negative. Lyme titer, rapid plasma reagin, gliadin IgA, endomysial antibody, aminolevulinic acid, porphobilinogen, and human immunodeficiency virus test results were negative; findings from a thyroid profile were normal. Spinal fluid examination showed a glucose level of

Author Affiliations:

Department of Neurology, University of California, Los Angeles (Dr Apostolova); Departments of Radiology (Dr White), Pathology (Dr Moore), and Neurology (Dr Davis), University of Iowa, Iowa City.

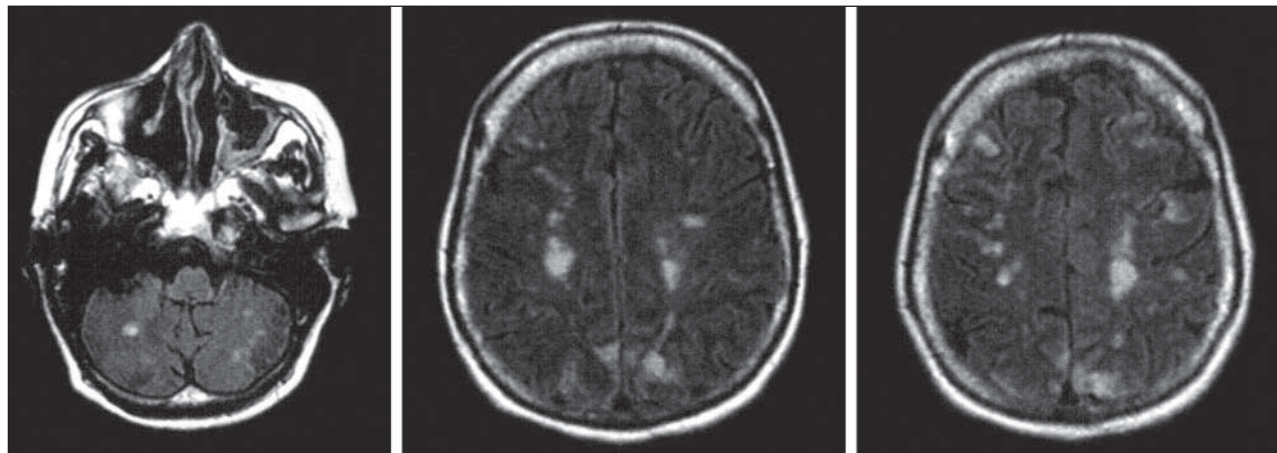


Figure. Fluid-attenuated inversion recovery magnetic resonance images demonstrating the patient's partially resolving initial occipital lesions and prominent new cerebral and cerebellar white matter lesions in watershed distribution.

79 mg/dL (4.38 mmol/L), protein level of 30 mg/dL, 1 white blood cell, and 9 red blood cells.

Her weakness rapidly progressed. The deltoids tested as 0/5. Bilateral wrist extensors, left finger flexors, and extensors were 2/5. Proximal right leg muscles were 2/5. The right tibialis anterior was 0/5. Right soleus and all left leg muscles were 4/5.

She developed paranoia, agitation, and hallucinations, which were treated with risperidone. Neuropsychological testing revealed prominent visuospatial and visuoperceptual deficits, defective orientation, mental tracking, working and anterograde memory, nonverbal reasoning, social judgment, verbal fluency, repetition, and naming. She was anosognosic and anosodiaphoric. Repeated MRI demonstrated an increased number of prominent deep white matter hyperintensities, many in watershed distribution, and bilateral involvement of the cerebellum (**Figure**). She had not experienced hypotensive episodes.

Cerebral angiography results were normal except for 30% stenosis of the left internal carotid artery. Shortly after the angiogram, partially blanching purpura appeared on her toes and fingertips, microscopically characterized by microvascular thrombosis and mild lymphocytic perivascular infiltrates. Prothrombin time, partial thromboplastin time, cryoglobulins, factor V Leiden, anticardiolipin antibodies, β 2-glycoprotein autoantibodies, lupus anticoagulant, antithrombin 3, protein C and protein S, heparin antibodies, fibrin degradation products, and D-dimer test results were normal. Her fibrinogen level was elevated at 767 mg/dL (22.55 μ mol/L) (reference range, 160-340 mg/dL [4.70-10 μ mol/L]). The skin lesions were attributed to microemboli following the angiogram.

Initial electromyography revealed small motor unit potentials. Eight days later, electromyography demonstrated bilateral biceps and deltoid denervation. A muscle biopsy specimen showed ragged red and cytochrome-*c* oxidase-negative fibers suggestive of a mitochondrial disorder. Her blood lactate level was normal. Restriction endonuclease digestion of polymerase chain reaction-amplified mitochondrial DNA from muscle revealed an A3243G mutation. She was treated with coenzyme Q,

L-carnitine, multivitamins, and vitamin E and transferred to skilled level of care.

She was reassessed 4 months later. She was walking with minimal support. Residual weakness of 4/5 was present in her finger flexors bilaterally. She was living independently requiring minimal assistance. Repeated MRI showed cystic degeneration of the subcortical lesions and patchy cortical hemorrhagic transformation.

COMMENT

Myopathy, encephalopathy, lactic acidosis, and stroke-like episodes (MELAS) syndrome is a rare, maternally transmitted genetic disorder. The diagnostic criteria include (1) stroke before age 40 years; (2) encephalopathy defined as seizures, dementia, or both; and (3) lactic acidosis, ragged red fibers, or both.¹ The diagnosis is secured by 2 of the following: normal early development, recurrent headaches, or emesis. Hirano et al¹ suggested that incomplete syndromes might be encountered in sporadic cases.

Most patients typically develop MELAS in childhood and adolescence. Late-onset MELAS, although reported, is exceedingly rare.^{2,3} We describe a late-age onset of oligosymptomatic MELAS with acute encephalopathy and profound patchy myopathy without family history of mitochondrial abnormalities. She manifested with psychosis rather than seizures or dementia. The cardiomyopathy, muscle pathologic features, and messenger DNA analysis were consistent with MELAS.

Only few MELAS reports describe deep white matter involvement (**Table**).³⁻⁶ Fujii et al⁴ reported a 14-year-old girl with MELAS and diffuse contiguous involvement of cortex, subcortical, and deep white matter in the occipital and frontal lobes bilaterally. Brain autopsy disclosed extensive cortical laminar necrosis, along with demyelination and gliosis of the affected white matter regions. Matthews et al⁵ encountered a patient with involvement of the corpus callosum and preservation of the remaining deep white matter. Barkovich et al⁶ reviewed the computed tomographic and MRI findings of 4 patients with MELAS. One patient had isolated involve-

Table. Deep White Matter Involvement in MELAS: Review of the Literature

Source	Patient Sex/Age	Diagnosis	Clinical Symptoms	MRI Results
Fujii et al, ⁴ 1990	F/14 y	MELAS	Stroke-like episodes, short stature, ophthalmoplegia, muscle weakness, hyporeflexia	Extensive cortical, subcortical, and deep white matter changes in frontal and occipital lobes bilaterally and the left cerebellar hemisphere
Matthews et al, ⁵ 1991	F/20 y	MELAS	Neonatal hypoglycemia and hypotonia, recurrent vomiting, short stature, stroke-like episodes, headaches, seizures, and renal failure	Extensive bilateral corticosubcortical involvement and involvement of the corpus callosum
Barkovich et al, ⁶ 1993	6 y	MELAS	Hemiparesis	Diffuse left parietooccipital white matter changes; medial frontoparietal corticosubcortical involvement later in the course
Castillo et al, ³ 1995	F/18 mo	MELAS	Developmental delay, seizures	Cerebral atrophy, diffuse periventricular white matter changes
	F/47 y	MELAS	Unknown	Focal periventricular white matter changes
	F/13 y	MELAS	Transient ischemic attack	Cerebral atrophy, periventricular white matter changes
	F/80 y	MELAS	Transient ischemic attack	Cerebral atrophy, periventricular white matter changes

Abbreviations: MELAS, myopathy, encephalopathy, lactic acidosis, and stroke-like episodes; MRI, magnetic resonance imaging.

ment of the left parieto-occipital white matter sparing the cortex. The magnetic resonance spectroscopy of the area showed elevated lactate levels. Castillo et al³ presented 4 cases with periventricular white matter changes. One of the patients underwent postmortem MRI followed by autopsy. The hyperintense periventricular white matter changes on postmortem MRI had underlying microcystic degeneration similar to the microvacuolation of other respiratory chain disorders.⁷ While the concept of deep white matter involvement in MELAS is not new, to our knowledge, no one has described such striking bilateral confinement to the hemodynamically vulnerable watershed areas. The changes likely result from impaired microcirculatory autocontrol and microangiopathy due to endothelial and myocytic mitochondrial dysfunction.^{8,9}

The constellation of progressive asymmetric muscle weakness, cardiomyopathy, psychosis, and unaccountable gray and white matter pathologic features led us to consider the diagnosis of MELAS. We suggest that the possibility of MELAS should be investigated in older patients with atypical manifestations.

Accepted for Publication: June 14, 2004.

Correspondence: Liana G. Apostolova, MD, UCLA Alzheimer's Disease Research Center, RNRC 2-238, 710 Westwood Blvd, Los Angeles, CA 90095 (lapostolova@mednet.ucla.edu).

Author Contributions: *Study concept and design:* Apostolova and Davis. *Acquisition of data:* Apostolova, White, Moore, and Davis. *Analysis and interpretation of data:* Apostolova, White, Moore, and Davis. *Drafting of the manu-*

script: Apostolova. *Critical revision of the manuscript for important intellectual content:* Apostolova, White, Moore, and Davis. *Administrative, technical, and material support:* Apostolova and White. *Study supervision:* Davis.

Additional Information: Dr Apostolova is the first author of the manuscript. Dr Davis is the senior author of the manuscript. Dr White was consulted on the radiological findings. Dr Moore was consulted on the pathological findings.

REFERENCES

- Hirano M, Ricci E, Koenigsberger MR, et al. MELAS: an original case and clinical criteria for diagnosis. *Neuromuscul Disord.* 1992;2:125-135.
- Kimata KG, Gordan L, Ajax ET, Davis PH, Grabowski T. A case of late-onset MELAS. *Arch Neurol.* 1998;55:722-725.
- Castillo M, Kwock L, Green C. MELAS syndrome: imaging and proton MR spectroscopic findings. *AJNR Am J Neuroradiol.* 1995;16:233-239.
- Fujii T, Okuno T, Ito M, et al. MRI and autopsy findings in brain of a patient with MELAS. *Pediatr Neurol.* 1990;6:253-256.
- Matthews PM, Tampieri D, Berkovic SF, et al. Magnetic resonance imaging shows specific abnormalities in the MELAS syndrome. *Neurology.* 1991;41:1043-1046.
- Barkovich AJ, Good WV, Koch TK, Berg BO. Mitochondrial disorders: analysis of their clinical and imaging characteristics. *AJNR Am J Neuroradiol.* 1993;14:1119-1137.
- McKelvie PA, Morley JB, Byrne E, Marzuki S. Mitochondrial encephalomyelopathies: a correlation between neuropathological findings and defects in mitochondrial DNA. *J Neurol Sci.* 1991;102:51-60.
- Ohama E, Ohara S, Ikuta F, Tanaka K, Nishizawa M, Miyatake T. Mitochondrial angiopathy in cerebral blood vessels of mitochondrial encephalomyopathy. *Acta Neuropathol Berl.* 1987;74:226-233.
- Sakuta R, Nonaka I. Vascular involvement in mitochondrial myopathy. *Ann Neurol.* 1989;25:594-601.