

The First Case of Invasive EEG Monitoring for the Surgical Treatment of Epilepsy: Historical Significance and Context

*Antonio N. Almeida, †Victor Martinez, and ‡William Feindel

*Hospital das Clínicas da Universidade de São Paulo, Departamento de Neurologia, São Paulo, São Paulo;
†Hospital São Lucas da PUCRS, Porto Alegre Epilepsy Surgery Program, Porto Alegre, Rio Grande do Sul, Brazil;
and ‡Montreal Neurological Institute, Montreal, Quebec, Canada

Summary: *Purpose:* Controversy persists about when EEG became a fundamental tool in the preoperative investigation for epilepsy surgery. We revisit Penfield's first use of invasive EEG monitoring, emphasizing its historical importance for the evolution of epilepsy surgery.

Methods: Patients' hospital charts and articles published before 1940 regarding EEG and epilepsy or EEG and cerebral lesions were reviewed to evaluate the historical context of the surgery.

Results: In April 1939, Penfield performed trephination over both temporal regions and placed electrodes on the dura, intending to lateralize seizure origin in a patient with bitemporal epilepsy. The patient underwent serial EEGs with this technique. The final report of the recordings from epidural leads was "con-

tinued random delta activity in the left temporal region indicating a cortical lesion on this side." The pneumoencephalogram showed "the presence of diffuse cerebral atrophy, particularly in the left cerebral hemisphere." Based on these findings, the patient underwent surgery on April 21, revealing a meningocerebral scar in the posterior part of the left temporal lobe. Brain stimulation and electrocorticography delineated the extent of resection, while preserving the speech area. Seizures did not improve.

Conclusions: We revisit the first case of epidural EEG monitoring for epilepsy surgery and show that the concept of EEG-directed surgery was already present at the Montreal Neurological Institute in the late 1930s. **Key Words:** Epilepsy—History—Neurosurgery—Penfield—Jasper.

Engel divides surgery for epilepsy into three historical phases: lesion-directed surgery, EEG-directed surgery, and imaging (lesion)-directed surgery (1). In the first phase, operations were aimed at resection of brain lesions diagnosed by a detailed review of seizure pattern and by neurologic examination. The second phase started when clinicians acknowledged EEG as a tool of prime importance for localization of epileptogenic areas in the brain (2). A monograph by Penfield and Erickson in 1941 contains a chapter by Jasper, in which he remarks, "that a consistently localized random spike or sharp-wave focus worked out on the scalp surface is a faithful guide to a focal cortical epileptic discharge" (3). Nevertheless, the article written by Bailey and Gibbs in 1951 (4) has been considered the milestone between the first and second phases (1). The advent of new methods of imaging brought new perspectives to the understanding of the interaction between lesions and epileptogenic areas in epilepsy.

Invasive monitoring was a risky procedure carried out only by neurosurgeons convinced of the reliability of EEG to define an epileptic area, and as such, it should be included in the second phase of epilepsy surgery. Penfield (5) described the first case of intracranial EEG monitoring for surgical treatment of epilepsy in 1939. We revisit this case, emphasizing its historical importance in the evolution of epilepsy surgery.

CASE REPORT

The patient, 32 years old, had a head injury in a car accident in March 1937. He had a period of unconsciousness lasting for 3 days, followed by irritability and aggressive behavior for 13 days. On day 17, his mental faculties cleared, and he was discharged apparently without permanent sequelae. Associated with the accident was bleeding from the left ear and a skull fracture of the base and the left parietal bone. Over the following year, he had two episodes of loss of consciousness, one in January and other in April 1938, but without aura and questionably no convulsive movements. Aggressive behavior lasting ~30 min followed the episodes.

Accepted March 27, 2005.

Address correspondence and reprint requests to Dr. A. N. Almeida, Instituto Neurológico São Paulo, Rua Maestro Cardim, 808, Liberdade, São Paulo, Brazil CEP 01323-001. E-mail: almeidaan@globo.com

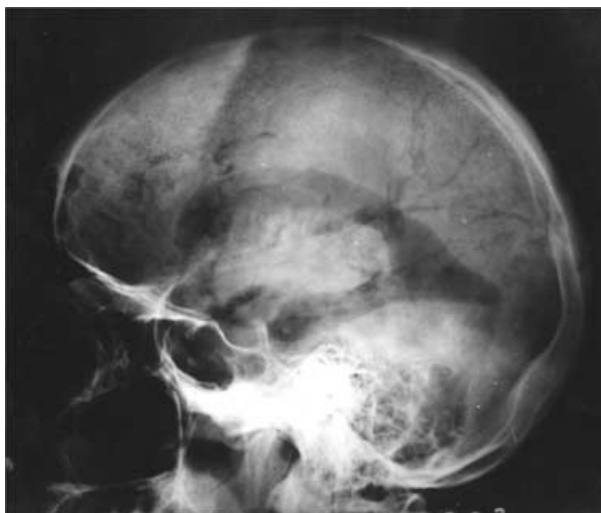

FIG. 1. Patient's pneumoencephalogram done in 1938, 1 year after his car accident, showing bilaterally enlarged ventricles with selective dilatation of the left temporal horn.

His first admission at the Montreal Neurological Institute (MNI) was on May 15, 1938. During evaluation for the loss of consciousness, he underwent a radiograph that showed the old parietal fracture without depression. Pneumoencephalography disclosed diffuse cerebral atrophy (Fig. 1), more apparent on the left side. On May 29, he was discharged to his home with no medication.

His second admission occurred April 8, 1939. Between admissions, he had an additional four episodes of loss of consciousness, similar to the earlier ones. EEGs showed bitemporal epileptiform discharges. Pneumoencephalograms again showed bilateral atrophy, more apparent on the left side. Because of bilateral findings on scalp EEG and imaging, the patient underwent placement of epidural single-contact electrodes through burr holes over both temporal lobes (Fig. 2). A series of EEG, using a four-channel ink-writing EEG apparatus, were done during daytime hours over a 3-day interval. At night, he was taken back to the ward. The invasive monitoring, recording simultaneously from both sides, showed continued random delta activity in the left temporal region, indicating a cortical lesion on this side, as compared with the normal EEG on the right side. Based on the dural lead finding, the patient was taken to the operating room on April 21, where a meningocerebral scar was removed from the posterior part of left temporal lobe. Because the lesion was very close to the speech area, the surgery was done under local anesthesia, and the patient encouraged to talk constantly to Dr. Donald Hebb, who drew him out on various subjects while the area of scar was being removed. Intraoperative brain stimulation was used to map the motor and sensory cortex. Electroconvulsive therapy (ECT) showed no epileptiform activity over the scar but slow waves on the adjacent cortex. Afterdischarges lasting for ≤ 4 s were recorded on one occasion while stimulating close to the scar tissue. At the end of the surgery, the electroconvulsively ac-

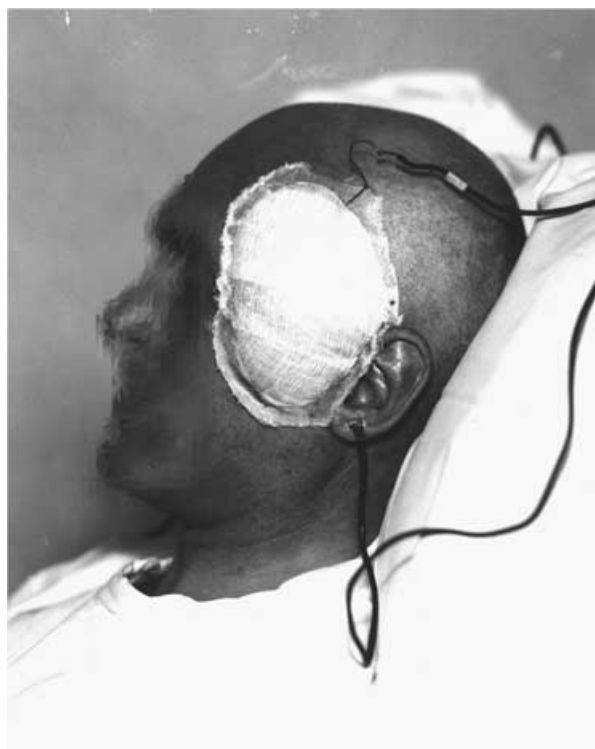

FIG. 2. Patient with the epidural lead and reference electrode on ear lobe positioned for recording. He was monitored for 3 days until enough data were gathered for surgery.

tive area was only partially removed, and no improvement was found on the postoperative EEG (Fig. 3). Immediately after the surgery, the patient did well, but on the first postoperative day, he developed aphasia, and on the second day, epileptic attacks, both focal and generalized. Seizures lasted for 6 days, after which the patient improved, and he was discharged to his home.

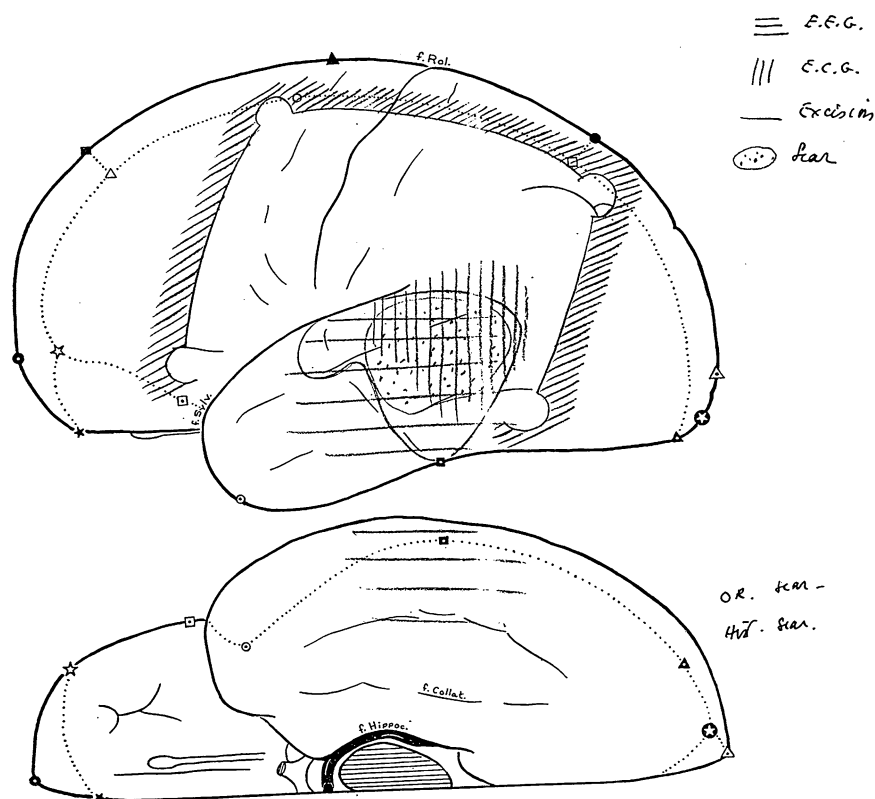
The patient's seizures did not improve, and he was admitted for a third time in 1940. Scalp EEG showed sharp spikes over the anterior part of the left temporal lobe, in front of the area of previous resection. Surgical treatment was not performed because the EEG focus was too close of the speech area. Follow-up to 1950 disclosed no improvement of the seizures.

To evaluate whether the procedure was original at that time, we reviewed articles published before 1940 regarding EEG and epilepsy or EEG and cerebral lesions, compiled by International Federation of Electroencephalography and Clinical Neurophysiology (6). We used information about identity and location of authors and title of the article to select articles from neurologists and neurosurgeons in which EEG technology was available for study of seizures.

DISCUSSION

The outcome was disappointing in this case, but the case illustrates several important points. It displays the technology available and the difficulties of performing surgery for

FIG. 3. Operative map showing the areas delineated by EEG (horizontal lines), ECoG (vertical lines), extent of the lesion (dots), and surgical resection (solid lines). The letters represent responses from mapping of sensorimotor strip by stimulation. As the resection did not encompass completely the ECoG active area, the prognosis was defined as poor.



epilepsy in the 1930s. It also shows Penfield, Jasper, and Hebb working together as team during the surgery, attesting to the MNI multidisciplinary approach. In addition, the case shows adoption of the EEG as a fundamental technique to define an epileptic focus, because it disclosed the abnormality only on one side, despite bilateral atrophy on radiographs. It emphasizes the importance for epilepsy of the epileptogenic area, and not just the lesion. The idea of the epidural leads presumably came from Jasper. He was working with epidural ECoG in cats and had stated earlier that scalp could be an important source of artifacts and errors for EEG (7). Prolonged invasive EEG had not been used in humans before. Carrying out such procedure indicates that Penfield had a high degree of confidence in Jasper and in EEG. The EEG-directed approach for epilepsy surgery was reaffirmed when a second surgery was discussed a year later because of persistent spikes in the temporal lobe, even after most of the scar had already been removed.

In Europe, the most prolific groups working with epilepsy and neurophysiology were in Germany. Berger (8), despite his work with EEG, was not interested in using it to localize intracranial lesions. Even epilepsy occupied only a small part of his efforts. After the ascension of Nazism, he had difficulties pursuing his research and digressed from the evolution of his invention. Foerster (9), conversely, was doing epilepsy surgery on a routine basis in 1935 and described the use of ECoG during surgery.

Like Berger, he had poor relations with the German government and came under intense stress because his wife was Jewish. His work was interrupted before implementing scalp EEG. In this context, Berlin became the most prominent site for work with EEGs in Germany. Tönnis (10), working with Kornmüller as an electrophysiologist, did cases of epilepsy surgery, but his field of interest was tumor surgery. In his article in 1939, describing 34 cases of scar resection for epilepsy, Tönnis did not mention EEG. During the war, his work was diverted to treatment of wartime wounds.

In North America, after Jasper published the first article about human EEG, the technique gained wider acceptance. Some groups disputed the supremacy of clinical EEG before 1940: Jasper at Providence and Schwab, Davis, Gibbs, and Lennox at three different units at Harvard. In Lennox's extensive review of 1941 (11), fewer than 2 pages were dedicated to surgery for epilepsy. Nevertheless, one patient seen by Cobb and Gibbs underwent frontal lobectomy by Mixer in 1938, based on EEG findings. Unfortunately, the outcome was not successful (12). After Gibbs moved from Harvard, no epilepsy surgery was done at that institution until the arrival, much later, of Welch, Blume, and Cosgrove, who had trained at the MNI.

In the second half of the 1930s, several authors published articles using scalp EEG or ECoG to confirm localization of epileptogenic lesions, which had been diagnosed by neurologic or other auxiliary examinations (13–17).

In Argentina, Manuel Balado (18) published several articles about using EEG to localize brain tumors. He eventually wrote a textbook about EEG in 1939. As he always wrote in Spanish, his work had some impact on Latin America but was not acknowledged in the English language literature. He was not known to have used invasive EEG.

In the late 1930s, most of neurologists were working with epilepsy, whereas neurosurgeons were working with brain lesions, presenting as seizures. In this scenario, the close relation and mutual respect of Jasper and Penfield, associated with their interest in epilepsy, created an environment for research and treatment for this disease at the MNI. The history of their accomplishments has been told before (19,20). The case reported offers another example of their valuable pioneer work in the field of epilepsy surgery.

REFERENCES

1. Engel J Jr. Historical perspectives. In: Engel J Jr, ed. *Surgical treatment of the epilepsies*. New York: Raven Press, 1993:695–705.
2. Quesney LF, Binnie CD, Chatrian G-E. Electro-corticography: current trends and future. *Electroencephalogr Clin Neurophysiol* 1998;suppl 48.
3. Jasper HH. Electroencephalography. In: Penfield W, Erickson TC, eds. *Epilepsy and cerebral localization*. Springfield: Charles C Thomas, 1941:380–454.
4. Bailey P, Gibbs FA. The surgical treatment of psychomotor epilepsy. *JAMA* 1951;145:365–70.
5. Penfield W. The epilepsies: with a note on radical therapy. *N Engl J Med* 1939;221:209–18.
6. Brazier MAB. *Bibliography of electroencephalography 1875-1948*. Montreal International Federation of Electroencephalography and Clinical Neurophysiology, 1950.
7. Jasper HH. Localized analysis of the human brain by the electroencephalogram. *Arch Neurol Psychol* 1936;36:1131–4.
8. Gloor P. Hans Berger on the electroencephalogram of man. *Electroencephalogr Clin Neurophysiol* 1969;suppl 28.
9. Foerster O, Altenburger H. Electrobiologische Vorgänge an der menschlichen Hirnrinde. *Dtsch A Nervenheilk* 1935;135:277–88.
10. Tonnis W. Die Behandlung der posttraumatischen Spätepilepsie. *Zbl Neurochir* 1939;4:240–1.
11. Lennox WG. *Science and seizures: new light on epilepsy and migraine*. New York: Harper, 1941.
12. Hermann BP, Stone JL. A historical review of the epilepsy surgery program at the University of Illinois Medical Center: the contributions of Bailey, Gibbs and collaborators to the refinement of anterior temporal lobectomy. *J Epilepsy* 1989;2:155–63.
13. Walter WG. Electroencephalogram in cases of cerebral tumor. *Proc R Soc Med* 1937;30:579–98.
14. Posteli T, Musiani U. Elettro-encefalogramma nell'epilessia sintomatica de reproduzioni dela convessita cranica. *Clinica* 1940;6:541–55.
15. Olivercrona H. Corticomeningeal scars in traumatic epilepsy. *Arch Neurol Psychol* 1940;45:666–71.
16. Schwartz HG, Kerr AS. Electrical activity of exposed human brain: description of technique and report of observation. *Arch Neurol Psychiatry (Chicago)* 1940;43:547–59.
17. Case TJ, Bucy PC. Localization of cerebral lesions by EEG. *J Neurophysiol* 1938;1:245–61.
18. Christensen JC. Valor diagnóstico quirúrgico del electroencefalograma. *Arch Argentinos Neurol* 1939;21:5–29.
19. Jasper HH. History of the early development of electroencephalogram and clinical neurophysiology at the Montreal Neurological Institute: the first 25 years 1939-1964. *Can J Neurol Sci* 1991;18(suppl 4):533–48.
20. Feindel W. Toward a surgical cure for epilepsy: the work of Wilder Penfield and his school at the Montreal Neurological Institute. In: Engel J Jr, ed. *Surgical treatment of the epilepsies*. New York: Raven Press, 1993:1–9.