

Transient global amnesia after cerebral angiography with iohexol

J. Juni, J. Morera, J. M. Láinez, J. Escudero, C. Ferrer, and J. Sancho

Servicio de Neurología, Hospital General Universitario de Valencia, Valencia, Spain

Summary. We describe a patient without a previous history of migraine or epilepsy and with no known vascular risk factors, who suffered subarachnoid haemorrhage. During vertebral angiography using nonionic contrast medium (iohexol), spasm of the basilar artery was seen. The patient suffered transient global amnesia. Angiography 3 months later with the same contrast medium was normal and produced no further deficit. This case lends support to the supposed ischaemic aetiology of transient global amnesia; in patients without other evidence of cerebrovascular disease, arterial spasm may be responsible.

Key words: Transient global amnesia – Cerebral angiography – Arterial spasm

Transient global amnesia (TGA), first described by Fisher and Adams in 1968 [1], is a condition of sudden onset that tends to resolve spontaneously, characterized by sudden loss of memory for recent events and a transient incapacity to learn new data; consciousness and personal identity are preserved. The aetiology of TGA is controversial because, although the neurological deficit is considered to be due to disturbance of the medial temporal lobe [2], there is disagreement over whether this is caused by migraine [3–5], ictal phenomena [6–8] or ischaemia. The last of these seems to be the most widely accepted, although debate continues as to whether TGA is a form of transient ischaemic attack [9–13] with a good prognosis, or is unrelated to atherothrombotic cerebrovascular disease [14–17].

The first case of TGA complicating cerebral angiography was reported by Wales and Nov in 1981 [18], although there are earlier descriptions of amnesia following vertebral angiography [19]. Isolated cases [20] and a number of series [21, 22] have also been reported. With the introduction of nonionic contrast media, a reduction in such complications might have been anticipated, although in 1989 Giang and Kido [23] reported the first cases of TGA following the use of such media.

We present a case of TGA following angiography with nonionic contrast medium, possibly as a result of arterial spasm.

Case report

A 56 year-old man without a history of migraine or epilepsy, and free of vascular risk factors, was admitted for intense, sudden headache induced by effort associated with nausea, vomiting and sweating. Apart from neck rigidity the examination was normal, as was cranial computed tomography (CT). A diagnosis of subarachnoid haemorrhage was made when xanthochromic cerebrospinal fluid was obtained at lumbar puncture. Angiography was performed on the 12th day. Via a femoral approach the left and right common carotid and left vertebral arteries were selectively catheterized, in that order. Twenty millilitres of Omnigraf 240 (10.36 g iohexol) diluted in 2 ml physiological saline was used, 1.55 g being injected directly into the vertebral artery via a 5.5 F catheter. No abnormality was seen on the carotid angiograms. Study of the left vertebral artery revealed spasm of its intracranial portion and of the basilar artery, with poor visualization of the posterior cerebral arteries and the vessels of the posterior cranial fossa (Fig. 1). A few seconds later, the patient developed dizziness, paraesthesiae of all limbs and somnolence. The catheter was removed immediately after the symptoms appeared and they then resolved after 4–5 min. Following the angiogram, the patient was unable to remember anything from the time of his admission to hospital, and asked repeated questions. The next day, about 15 h after the angiogram, the retrograde amnesia was limited to the entire preceding day, and the patient was able to take in new information. Cranial CT 4 days later showed no abnormality. Repeat angiography 3 months later (with the same protocol) was normal and without incident, confirming the absence of any aneurysm (Fig. 2). After 4 months follow-up an amnesic gap persisted – corresponding to a period of approximately 2 h – in relation to the first angio-

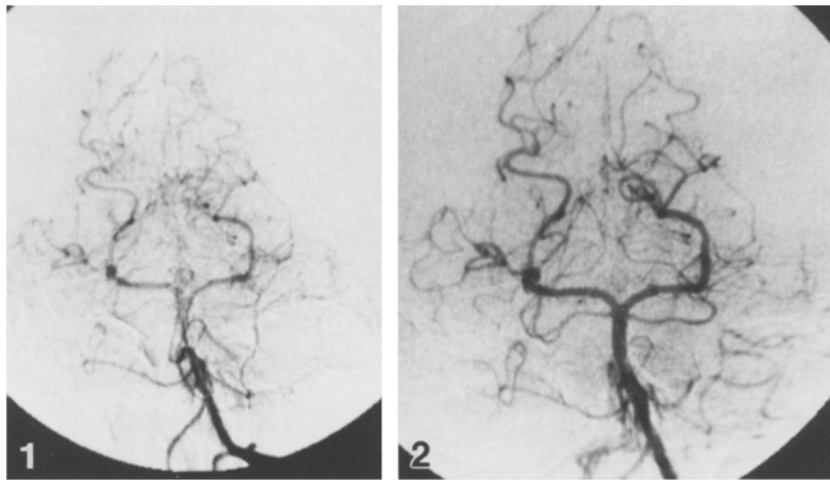


Fig. 1. Left vertebral angiogram, a-p projection. The distal vertebral artery and the basilar artery are of small calibre, and peripheral filling is poor. The blob of contrast medium overlying the right posterior cerebral artery was shown on other projections to be a loop

Fig. 2. As Fig. 1, 3 months later. Considerable increase in calibre of the vessels, with improved peripheral filling

gram. Neuropsychological examination at this stage revealed no further change.

Discussion

The incidence of TGA following femorocerebral angiography was 0.59 % in a series of 1520 patients [21]. The factors mentioned [21, 23, 24] as possible causes include detachment of atheromatous plaques from the vessel wall by the catheter, or formation of thrombi with distal embolism; the presence of particles in the contrast medium; endothelial damage and consequent direct neurotoxic effects; and arterial spasm. Shuaib and Hachinski [25] found only one case of TGA in 149 angiograms in migrainous patients (0.67 %), so that migraine should not be considered a risk factor for TGA following cerebral angiography.

These figures for TGA as a complication of angiography relate to the use of ionic contrast medium. During the 1980s, with the introduction of nonionic media whose osmolality is approximately half that of ionic media, a decrease in angiographic complications was anticipated, but 3 patients with TGA after angiography have since been described: in 2 cases reported by Giang and Kido [23], iopamidol was used, whereas in the report by Minuk et al. [26], iothalamate meglumine was employed. Two of these patients had temporal lesions shown by CT (one left temporo-occipital infarct and a right temporal haematoma), whereas the third patient suffered from migraine. Arterial spasm was not reported in any of them. The lesions described could favour extravasation of contrast medium, which might have a local toxic effect, and in the patient with headaches TGA could constitute an attack of migraine without headache, triggered by angiography – as suggested by a number of authors [19].

At one time the epileptic theory of TGA received considerable support [6–8], although it has since lost favour: in a study in which 13 EEG recordings were obtained during TGA episodes [27], none exhibited epileptiform activity. However, Hodges and Warlow [28] found 7 % of patients suffering TGA to develop epilepsy, usually in the course of the 1st year of follow-up. The patient observed by Stracciari et al. [29] suffered amnesic epileptic attacks

of short duration (seconds) and prolonged amnesic attacks resembling TGA.

Although studies reporting good correlations between cerebrovascular risk factors and TGA abound [9, 11–14, 30–32], and ischaemic lesions have been seen on CT [10, 31], the low rates of recurrence and of stroke found on follow-up [10, 12, 14, 31], and the low incidence of atherosclerotic pathology of the extracranial carotid artery on Doppler sonography [15], suggest an ischaemic mechanism unrelated to cerebrovascular atherothrombotic disease, in which spasm may play an important role.

Migraine has also been implicated in the genesis of TGA; vasomotor phenomena [4, 5] and Leao's cortical depression [3] have been suggested as active contributing factors. In the study by Hodges and Warlow [28] migraine was the only factor related to TGA. The incidence of classical cerebrovascular risk factors was no greater in patients with TGA, and prognosis in terms of vascular complications and mortality was better than for patients with transient ischaemic attacks.

Our patient showed no structural lesions on CT, and had no history of migraine; his TGA could have been due to spasm and ischaemia. We have found only one report [22] of spasm during angiography, in a series of 7 patients who developed TGA, in whom ionic contrast media were employed. It is possible that spasm in the vertebrobasilar territory may be the underlying mechanism in a number of patients lacking signs of atheroma.

Acknowledgements. We thank Dr. F. Soler (Clínica Casa de Salud, Valencia) for his comments on the radiological study.

References

1. Fisher CM, Adams RD (1964) Transient global amnesia. *Acta Neurol Scand* 40 [Suppl 9]: 1–83
2. Palmer EP (1986) Transient global amnesia and the amnesic syndrome. *Med Clin North Am* 70: 1361–1374
3. Olesen J, Jørgensen MB (1986) Leao's spreading depression in the hippocampus explains transient global amnesia. A hypothesis. *Acta Neurol Scand* 73: 219–220
4. Crowell GF, Stump DA, Biller J, McHenry LC Jr, Toole JF (1984) The transient global amnesia-migraine connection. *Arch Neurol* 41: 75–79

5. Caplan L, Chedru F, Lhermitte F, Mayman C (1981) Transient global amnesia and migraine. *Neurology* 31: 1167–1170
6. Meador KJ, Adams RJ, Flanigin HF (1985) Transient global amnesia and meningioma. *Neurology* 35: 769–771
7. Dugan TM, Nordgren RE, O'Leary P (1981) Transient global amnesia associated with bradycardia and temporal lobe spikes. *Cortex* 17: 633–637
8. Deisenhammer E (1981) Transient global amnesia as an epileptic manifestation. *J Neurol* 225: 289–292
9. Colombo A, Scarpa M (1988) Transient global amnesia: pathogenesis and prognosis. *Eur Neurol* 28: 111–114
10. Matias Guiu J, Colomer R, Segura A, Codina A (1986) Cranial CT scan in transient global amnesia. *Acta Neurol Scand* 73: 298–301
11. Santoloci D, Bacigalupo F, Cocito L, Farinini D, Bo G (1985) Amnesia globale transitoria. *Riv Neurol* 55: 369–376
12. Cattaino G, Querin F, Pomes A, Piazza P (1984) Transient global amnesia. *Acta Neurol Scand* 70: 385–390
13. Jensen TS, Fine Olivarius B de (1981) Transient global amnesia – its clinical and pathophysiological basis and prognosis. *Acta Neurol Scand* 63: 220–230
14. Guidotti M, Anzalone N, Morabito A, Landi G (1989) A case-control study of transient global amnesia. *J Neurol Neurosurg Psychiatry* 52: 320–323
15. Feuer D, Weinberger J (1987) Extracranial carotid artery in patients with transient global amnesia: evaluation by real-time B-mode ultrasonography with duplex Doppler flow. *Stroke* 18: 951–953
16. Kritchewski M (1987) Transient global amnesia. When memory temporarily disappears. *Postgrad Med* 82: 95–97
17. Hinge HH, Jensen TS, Kjaer M, Marquardsen J, Fine Olivarius B de (1986) The prognosis of transient global amnesia. Results of a multicenter study. *Arch Neurol* 43: 673–676
18. Wales LR, Nov AA (1981) Transient global amnesia: complication of cerebral angiography. *AJNR* 2: 275–277
19. Haas DC (1983) Transient global amnesia after cerebral angiography. *Arch Neurol* 40: 258–259
20. Reichter RE, Belt TG, Stevens J (1986) Transient global amnesia: complication of arterial DSA. *AJNR* 7: 179–180
21. Pexman JH, Coates RK (1983) Amnesia after femorocerebral angiography. *AJNR* 4: 979–983
22. Cochran JW, Morrell F, Huckman MS, Cochran EJ (1982) Transient global amnesia after cerebral angiography. Report of seven cases. *Arch Neurol* 39: 593–594
23. Giang DW, Kido DK (1989) Transient global amnesia associated with cerebral angiography performed with use of iopamidol. *Radiology* 172: 195–196
24. Dion JE, Gates PC, Fox AJ, Barnett HJ, Blom RJ (1987) Clinical events following neuroangiography: a prospective study. *Stroke* 18: 997–1004
25. Shuaib A, Hachinski VC (1988) Migraine and the risks from angiography. *Arch Neurol* 45: 911–912
26. Minuk J, Melancon D, Tampieri D, Ethier R (1990) Transient global amnesia associated with cerebral angiography performed with use of iopamidol. *Radiology* 174: 285–286
27. Miller JW, Yanagihara T, Petersen RC, Klass DW (1987) Transient global amnesia and epilepsy. Electroencephalographic distinction. *Arch Neurol* 44: 629–633
28. Hodges JR, Warlow CP (1990) The aetiology of transient global amnesia. A case-control study of 114 cases with prospective follow-up. *Brain* 113: 639–657
29. Stracciari A, Ciucci G, Bianchedi G, Rebucci GG (1990) Epileptic transient amnesia. *Eur Neurol* 30: 176–179
30. Shuping JR, Rollinson RD, Toole JF (1980) Transient global amnesia. *Ann Neurol* 7: 281–285
31. Kushner MJ, Hauser WA (1985) Transient global amnesia: a case-control study. *Ann Neurol* 18: 684–691
32. Matias Guiu J, Pico M, Bonaventura I, Martin R, Monasterio J (1989) Platelet aggregation in transient global amnesia. *Ital J Neurol Sci* 10: 171–174

Dr. J. Juni
 Servicio de Neurología
 Hospital General Universitario de Valencia
 Avda. Tres Cruces, s/n
 E-46014 Valencia
 Spain