

NOTE

ANOMIC ALEXIA OF KANJI IN A PATIENT WITH ANOMIC APHASIA

Rie Yamawaki¹, Kyoko Suzuki¹, Kazuyo Tanji¹, Toshikatsu Fujii¹, Keiko Endo², Kenichi Meguro¹
and Atsushi Yamadori¹

(¹Division of Neuropsychology, Department of Disability Medicine, Tohoku University Graduate School of Medicine, Tohoku, Japan; ²Department of Rehabilitation, Tohoku University Hospital, Tohoku, Japan)

ABSTRACT

The ability to read aloud kanji (logogram) words and to comprehend their meaning was systematically examined to clarify the underlying mechanism of kanji alexia in a patient with anomic aphasia. Confrontation naming, reading aloud and reading comprehension tasks were performed using 110 words from 11 semantic categories written in kanji or kana. Performance in oral reading of kanji words was significantly worse than oral reading of the same words transcribed into kana words. In addition, for kanji words reading aloud was much worse than reading comprehension. Oral reading of kanji words had a significant correlation with naming pictures corresponding to the words, but no correlation with comprehension of kanji words. Qualitative analyses demonstrated that errors in oral reading and naming tasks had many features in common. Our results indicated that some common mechanisms underlie both naming and oral reading of kanji words. We propose calling this type of alexia “anomic alexia of kanji”, which should be distinguished from kanji alexia with difficulty in both reading aloud and comprehension. Lesions in our patient were located in the middle part of the left middle temporal gyrus and its subcortical area, which could be important for access to the phonological lexicon from semantics.

Key words: kanji, alexia, anomic aphasia

INTRODUCTION

Alexia refers to an acquired disturbance in reading, both reading aloud and reading comprehension (Benson and Ardila, 1996). Japanese has two writing systems, kanji (logogram) and kana (syllabogram), which are used in combination. Dissociated reading ability between kanji and kana has sometimes been reported in alexia in Japanese (Yamadori, 1975, 1979; Iwata, 1984). More than twenty patients have been reported with alexia specific to or predominant for kanji, in which performance of reading aloud and reading comprehension was not examined separately. Some of these patients also had anomia together with kanji alexia. However, the relationship between anomia and alexia has not been fully examined.

We describe a patient with severe anomia with alexia specific for kanji, who could not read aloud kanji words but could comprehend their meanings. Systematic investigation was made to clarify the nature of his alexia and the neuronal basis of the impairment.

CASE REPORT

A 71-year-old, right-handed retired construction worker suffered from a head injury because of an accident while riding a bicycle. He was transferred to a local hospital where he was treated conservatively. A brain CT scan showed a cerebral haemorrhage in the left temporal lobe. He became alert in a week, but showed some difficulty with

language. After two months, he was admitted to our hospital for further evaluation and rehabilitation. Neurological examination showed that functions of cranial nerves, motor and sensory functions were all preserved. Magnetic resonance images (MRI) of the brain demonstrated a haemorrhagic lesion in the middle temporal gyrus and its subcortical area extending to the temporal stem (Figure 1). Measurement of blood flow with ¹²³I-IMP single photon emission computed tomography (SPECT) demonstrated generalized hypoperfusion in the left cerebral hemisphere.

Neuropsychological examination revealed that he was oriented in time and place. His speech was fluent but with word finding difficulty and semantic paraphasia. Listening comprehension was fair and repetition was well preserved. Marked impairment was observed in naming objects through visual and tactile stimuli and by verbal description of objects (Table I). In contrast, he could describe the nature of these objects and show by gesture how to use them. Oral reading of kanji words was impaired while oral reading of kana characters was well preserved. Writing kanji characters was severely impaired, but writing kana characters was fairly preserved. No amnesia, apraxia, agnosia or visuoconstructional problems were observed.

EXPERIMENTAL INVESTIGATIONS

Reading and listening comprehension, reading aloud and naming was extensively examined using 110 common words in 11 semantic categories.

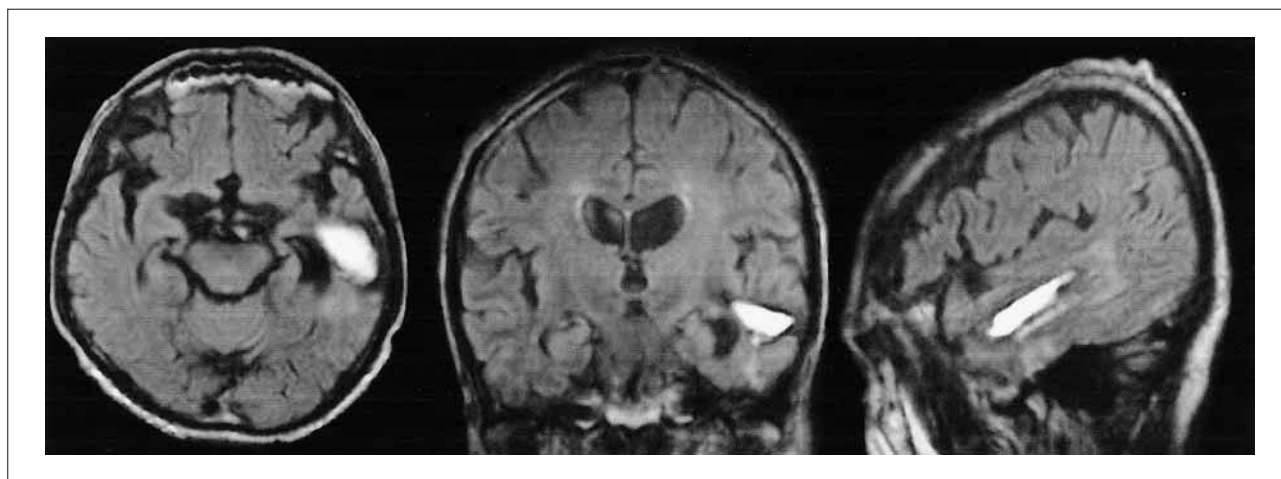


Fig. 1 – Fluid-attenuated inversion recovery (FLAIR) MR images taken two months after injury (left: axial; middle: coronal; right: sagittal section) demonstrated a hyperintensity area in the left middle temporal gyrus.

TABLE I
Results of Neuropsychological Tests

Task	Correct
Language	
Reading aloud task of kanji characters* [240]	148 (62%)
Visual naming (real objects) [10]	0
Tactual naming [10]	1
Naming due to verbal description [20]	1
Auditory naming of environment sounds [10]	5
Standard language test of aphasia	
Oral reading of kanji words [5]	4
Kanji words recognition [10]	10
Oral reading of kana words [5]	5
Kana words recognition [10]	10
Intelligence	
WAIS-R (PIQ)	83
Raven Colored Progressive Matrices [36]	28
Memory	
Rey-Osterreich complex figure test (copy, immediate recall, 40-min recall) [36]	33, 11, 12
Benton visual retention test	4 correct, 10 errors
Frontal lobe function	
Trail making test A	1'51 (10-25%ile)
B	10'10 (under 10% ile)

[Full score]

*Relatively simple kanji characters were selected, which were learnt by the second grade of a primary school.

Black and white line pictures of 100 nameable objects belonging to the 10 semantic categories and 10 color cards were prepared. Word cards corresponding to the pictures and colors were also prepared, which were written with kanji or hiragana characters. Thus the total number of word-cards was 220. Words were selected from familiar concrete nouns from the NTT data base in Japanese (2000) so that word familiarity, character familiarity and orthographic plausibility for kanji words were high. In Japanese, a word can be written with either kanji or kana characters. But a word is usually written with kanji characters and another word is almost always written with kana characters. Orthographic plausibility refers to a subjective measure whether one type of characters is appropriate for a word. In the NTT data base for Japanese, orthographic plausibility was measured

using a 5-point scale. For example, “Ongaku (music)” is almost always written with two kanji characters, so that the orthographic plausibility of Ongaku as a kanji word is 5. The mean value of word familiarity was 5.9 on a 7 point scale, the mean value of familiarity for kanji words 5.8 on a 7 point scale, orthographic plausibility 4.8 on a 5 point scale. Although consistency of the words was not available, orthographic plausibility has a good correlation with consistency. These parameters were not significantly different among category groups. Number of characters in kanji words was 1 to 3 with a mean of 1.5 characters and that in kana words was 1 to 8 with a mean of 3.05 characters.

The patient performed 8 tasks over a period of 40 days. Each session lasted an hour or less, the order of tasks was varied across the 11 categories. Correct answers within 20 s were counted in all the tasks except the description task that was performed without time pressure. (1) Naming. He was asked to name a picture or a color pointed to by an examiner. (2) Description. When he failed to produce a correct answer, he was asked to describe what it was. If his description was not detailed enough, questions about specific features of the item were given. His descriptions were rated by the third person who did not know the items since they were covered. They were considered correct when the rater could guess the name of the described items. The number of appropriate descriptions and that of correct namings were counted. (3) Pointing to pictures by names. To examine his ability of listening comprehension of words, we asked him to point to a picture corresponding to a heard word out of 10 within-category exemplars. (4) Pointing to kanji words by pictures. He was required to select a target kanji word from 10 within-category kanji words in response to a picture/color shown by an examiner. (5) Reading aloud kanji words. He read aloud kanji words one by one. (6) Reading comprehension of kanji words. He was asked to select an item from 10 within-category exemplars in response to

TABLE II
Result of Reading and Naming

Task	Patient	Controls*
Pictures		
Naming pictures	27	108.8 ± 2.2
Describing pictures	105	110 ± 0
Pointing to pictures by names	74	109.6 ± 0.5
Pointing to kanji words by pictures	84	104.8 ± 7.3
Kanji words		
Reading aloud kanji words**	30	100.4 ± 7.8
Reading comprehension of kanji words**	83	104.4 ± 5.7
Kana words		
Reading aloud kana words	103	110 ± 0
Reading comprehension of kana words	92	110 ± 0

Numbers of correct responses out of 110 items.

*n = 5, mean ± standard deviation, ** P < 0.001 (McNemar's test)

presentation of a kanji word. (7) Reading aloud hiragana words. Same as (5). (8) Reading comprehension of hiragana words. Same as (6).

RESULTS

All the tasks except description of pictures were poorly performed compared to normal controls (Table II). Fairly preserved ability to describe pictures indicated that the difficulty existed in naming but not in visual recognition. Reading comprehension of kanji words was significantly better than reading aloud kanji words (McNemar's test; $p < 0.001$). Counting correct answers in each semantic category and applying the Cochran's Q test showed, significant difference among 8 tasks ($p < 0.005$). Wilcoxon's signed rank test revealed again that reading comprehension of kanji words was significantly better than reading aloud kanji words ($p < 0.005$). No other difference between two tasks was significant in the 8 experimental tasks. The number of correct answers of naming and reading aloud kanji words was correlated with each other (Chi-square analysis; $p < 0.005$). Qualitative analyses of the task of reading aloud kanji words revealed that the most common errors were no responses (32.5%), followed by semantic paraphasia (10%). A similar pattern of errors was observed in the naming task, which included 42.2% of no responses and 21.7% of semantic paraphasia.

DISCUSSION

Our patient demonstrated a significant difference in the results of reading tasks between kana and kanji words, and also between reading aloud and reading comprehension of kanji words. It seemed that the meaning of a kanji word could be recalled without simultaneous recollection of its pronunciation. The contrasting results on reading aloud and reading comprehension of kanji words indicated that the neuronal bases of these two functions are dissociable. In addition, the similarity

of error patterns and the significant correlation between the oral reading of kanji words and naming of objects suggested that both processes used some mechanisms in common. He could rarely succeed in reading aloud kanji words without comprehension of their meanings. Thus he might be able to read aloud kanji words only through their meanings. Kana word reading was fairly well preserved, which may be related to the transparency of kana reading.

In the Japanese script system, a kana character represents a consonant-vowel type syllable or vowel. And its pronunciation is completely regular and transparent. In contrast, oral reading of kanji script is extremely irregular. A kanji character has more than two ways of reading, i.e. Chinese pronunciation (called On-reading) and Japanese pronunciation (called Kun-reading). When reading a kanji character, a reader has to choose a correct pronunciation from the multiple candidates. When kanji characters are combined to make a word, pronunciation of the component characters is determined by the meaning of a word. We have to learn not only the way of pronunciation of individual kanji characters, but also a specific pronunciation of a particular combination of characters making up a word. Consistency of character-sound correspondences affects accuracy of kanji-word reading. To make things more complex, Japanese has many homonyms, each of which is transcribed with different kanji words. Without seeing kanji words, the differentiation of the meaning of homonymous words is difficult (Takashima, 1998), which suggests that kanji words are intrinsically connected to their meaning.

Some methodological problems should be considered here. In the experimental investigations, we used words with high familiarity and orthographic plausibility, because patients with kanji reading disorders are usually affected by these parameters. Although the same set of 110 words was used for all the experimental tasks, each task was performed on separate days and the order of tasks was different in each semantic category. Thus the learning effect for a certain task was minimal.

Better performance on reading comprehension than that on the reading aloud task could not be explained by the difference in difficulties between the two tasks. Selecting a correct answer by chance in the reading aloud task was only 10% and he selected correctly over 75% items. In addition, he nearly always described the meaning of kanji words correctly, which he could not read aloud. Thus the dissociation between reading aloud and reading comprehension for kanji words cannot be an artifact of the nature of the tasks.

Most reported cases with kanji alexia had difficulty in both reading aloud and reading comprehension (Iwata, 1984). Only two cases with kanji alexia demonstrated relatively preserved ability to comprehend kanji words compared to severely impaired oral reading (Azumi et al., 1981; Sakai et al., 1992). In both cases, object naming was also impaired. We propose to call this type of alexia 'anomic alexia of kanji' to stress the dissociated disability to read aloud kanji compared to reading comprehension of kanji.

We reviewed the existing clinical and neuroimaging studies to investigate the anatomical bases of kanji alexia. Drawing data from the comparable clinical studies, we divided patients with kanji alexia into two groups; kanji alexia with and without object anomia (Table III). The lesions in cases with kanji alexia with anomia were centered in the left posterior inferior temporal area, extending either rostrally as far as the anterior part of the middle temporal gyrus or medially to the parahippocampal gyrus (Sakurai et al., 1994). In contrast, lesions in cases with kanji alexia without

anomia were limited to the posterior part of the left inferior temporal gyrus. Consistent with this, neuroimaging studies with English speaking subjects also suggest two routes for reading: a semantic route that links visual input via the left inferior temporal cortex to the frontal operculum and a nonsemantic route that links visual input via the left posterior superior temporal cortex to the frontal operculum (Price, 2000). Kanji characters may be read mainly via the semantic route.

Our patient had quite limited lesions confined to the middle part of the left temporal gyrus and its subcortical region. The superior temporal sulcus (STS) in rhesus monkeys receives input from the auditory, visual and somatosensory association areas and other polymodal areas as well as the paralimbic regions (Barnes and Pandya, 1992). Likewise the middle temporal gyrus in humans seems to be a heteromodal association cortex and strategically located among unimodal association cortex; auditory association cortex in the superior temporal gyrus, somatosensory association cortex in the parietal lobe and visual association cortex in the occipito-temporal area (Mesulam, 2000). Thus the lesion in our patient was strategically located in the area that includes important nodes for word retrieval via the semantic route, resulting in anomic alexia of kanji and anomia. Reading aloud and reading comprehension should be examined separately in cases with kanji alexia to clarify its neuronal bases.

Acknowledgements. We thank Professor David Howard for correcting the manuscript. We wish to thank our patient for his enduring and friendly collaboration in all testing procedures.

TABLE III
Reported Patients with Kanji Alexia and Kanji Alexia with Anomia

Authors	Method	MT	IT	Med	HIPPC	Lat	TOP
Kanji alexia							
Iwata et al., 1986	CT	*	*				
Shiota et al., 1986	CT		*				
Kawamura et al., 1987	MRI		*				
Kawahata and Nagata, 1998, Pt2 Pt3	CT		*				
	CT		*				
Yoshida et al., 1997	MRI		*	*		*	
Oka et al., 1985	CT		*	*			
Kawamura et al., 1988	CT		*	*			
Morioka et al., 1995	CT		*	*			
Sugimoto et al., 1987	CT		* ^R				
Kanji alexia with anomia							
Takahashi et al., 1986	CT						*
Sakai et al., 1992	MRI		*	*			
Mizuta et al., 2001	MRI		* ^R	* ^R			
Kezuka and Kawamura, 1993			*	*			
Notoya et al., 1987	CT		*	*	*		
Ohara et al., 2001	MRI		*	*	*		
Imamura et al., 1985, Pt1	CT		*	*	*		
Yamamoto et al., 1994	MRI	*	*	*	*		
Azumi et al., 1981	CT	*	*	*			
Izawa et al., 1999	CT	*	*	*		*	*
Notoya et al., 1991	CT	*	*	*			
The present case	MRI	*					

MT: Middle temporal gyrus; IT: Inferior temporal gyrus; Med: medial occipital lobe; Lat: Lateral occipital lobe; HIPPC: Hippocampal complex; TOP: Temporo-Occipito-Parietal area. Patients whose lesions were combined by MRI or CT were selected. Lesion were in the left hemisphere except ones indicated by "R".

REFERENCES

- AZUMI S, KASHIWAGI A and KASHIWAGI T. Processes of confrontation naming and oral reading of kanji – a case report of language therapy. *Shitsugosho Kenkyu*, 1: 86-98, 1981. [in Japanese]
- BARNES CL and PANDYA DN. Efferent cortical connections of multimodal cortex of the superior temporal sulcus in the rhesus monkey. *Journal of Comparative Neurology*, 318: 222-244, 1992.
- BENSON DF and ARDILA A. *Aphasia: A Clinical Perspective*. New York: Oxford University Press, 1996, pp. 180-211.
- IMAMURA S, OHNO N, NAKASHIMA A, YAMANAGA H and IDETA T. Alexia with agraphia caused by temporo-occipital infarcts of the dominant side. Case report. *Shinkeinaika*, 23: 362-368, 1985. [in Japanese]
- IWATA M. Kanji versus Kana: Neuropsychological correlates of the Japanese writing system. *Trends in Neurosciences*, 7: 290-293, 1984.
- IWATA M. Neural mechanism of reading and writing in the Japanese language. *Functional Neurology*, 1: 43-52, 1986.
- IZAWA Y, KOJIMA T and KATO M. Training program for phonetic reading of individual kanji letters using information processing of kanji compound words. *Onseigengoigaku*, 40: 217-226, 1999. [in Japanese]
- KAWAHATA K and NAGATA K. Alexia with agraphia due to the left posterior inferior temporal lobe lesion – Neuropsychological analysis and its pathogenetic mechanisms. *Brain and Language*, 33: 296-310, 1998.
- KAWAMURA M. “Non-classical type” alexia without agraphia. *Shitsugosho Kenkyu*, 8: 185-193, 1988. [in Japanese]
- KAWAMURA M, HIRAYAMA K, HASEGAWA K, TAKAHASHI N and YAMAMURA A. Alexia with agraphia of kanji (Japanese morphograms). *Journal of Neurology, Neurosurgery and Psychiatry*, 50: 1125-1129, 1987.
- KEZUKA M and KAWAMURA M. Naming difficulty associated with the left inferior temporal lesion. *ShinkeiShinrigaku*, 10: 26-31, 1993. [in Japanese]
- MESULAM MM. *Principles of Behavioral and Cognitive Neurology* (2nd Ed). New York: Oxford University Press, 2000, pp. 9-11.
- MIZUTA H. Alexia with agraphia of kanji due to right posterior inferior temporal lesion – The relationship between naming difficulty and kanji alexia. *Shitsugosho Kenkyu*, 21: 222-229, 2001. [in Japanese]
- MORIOKA E and UNO A. A case of alexia and agraphia following left temporo-occipital lobe lesion. *Onseigengoigaku*, 36: 177-183, 1995. [in Japanese]
- NOTOYA M, SUZUKI S, KURACHI M, KOYAMA Y and HIRAMATU H. A case of alexia with agraphia caused by a left inferior temporal lesion. *ShinkeiShinrigaku*, 3: 244-250, 1987. [in Japanese]
- NOTOYA M, TEDORIYA H, SUZUKI S, FUJII H and FURUKAWA M. Alexia with agraphia of kanji in the lesion of the left inferior Temporal gyrus. *Shitsugosho Kenkyu*, 11: 140-146, 1991. [in Japanese]
- OKA H, ASANO T, HATTORI S, MOCHIO S and SUGISHITA M. Pure alexia and alexia with agraphia caused by lesions of the left inferior temporal and fusiform gyri. *Shinkeinaika*, 23: 73-76, 1985. [in Japanese]
- OHARA K, SHUDO M, KAMAE M, SUGINO E, KOKAI M and MORITA Y. A case of alexia with agraphia for kanji whose immediate copying ability for complicated letters of kanji are well preserved. *Seishinigaku*, 43: 1339-1344, 2001. [in Japanese]
- PRICE CJ. The anatomy of language: Contributions from functional neuroimaging. *Journal of Anatomy*, 197: 335-359, 2000.
- SAKAI K, SAKURAI Y, SAKUTA M and IWATA M. Naming difficulties seen in a case of alexia with agraphia caused by a left postero-inferior temporal lesion. *Rinshosinkeigaku*, 32: 1227-1231, 1992. [in Japanese]
- SAKURAI Y, SAKAI K, SAKUTA M and IWATA M. Naming difficulties in alexia with agraphia for kanji after a left posterior inferior temporal lesion. *Journal of Neurology, Neurosurgery and Psychiatry*, 57: 609-613, 1994.
- SASANUMA S. Kanji versus kana processing in alexia with transient agraphia: A case report. *Cortex*, 10: 89-97, 1974.
- SHIOTA J, KAWAMURA M, ISONO O and HIRAYAMA K. Alexia with agraphia produced by a localized infarction in the inferior posterior region of the left temporal lobe. *No To Shinkei*, 38: 1051-1055, 1986. [in Japanese]
- SUGIMOTO K, ONO F, HASEGAWA Y, MIYASHITA T and YAMAGUCHI T. Reading and writing disturbance confined to kanji characters – A case of right hemisphere lesion. *Shitsugosho Kenkyu*, 7: 167-174, 1987. [in Japanese]
- TAKAHASHI M, TAKEUCHI A and KAWACHI J. The selective impairment of kanji in alexia with agraphia: A case report. *Chounougengogaku Kenkyu*, 3: 10-19, 1986. [in Japanese]
- TAKASHIMA T. Chinese characters and the Japanese language 2. *Japanese Book News*, 24: 4-5, 1998.
- YAMADORI A. Ideogram reading in alexia. *Brain*, 98: 231-238, 1975.
- YAMADORI A. Alexia with agraphia. *Shinkeinaika*, 10: 428-436, 1979. [in Japanese]
- YAMAMOTO H, HASEGAWA K and KAWAMURA M. Naming difficulty and alexia with agraphia of kanji due to herpes simplex encephalitis. *Shitsugosho Kenkyu*, 14: 187-195, 1994. [in Japanese]
- YOSHIDA M, KURODA H and YOSHIDA T. A case with non-classical pure alexia showing difficulty in reading Kanji due to infraction of the left inferior temporo-occipital lobe. *Shinkeinaika*, 47: 399-402, 1997. [in Japanese]

Rie Yamawaki, Division of Neuropsychology, Department of Disability Medicine, Tohoku University Graduate School of Medicine, 2-1 Seiryomachi, Aoba-ku, Sendai 980-0875, Japan. e-mail: r2022@theia.ocn.ne.jp

(Received 3 February 2003; reviewed 11 March 2003; revised 27 August 2003; accepted 2 March 2004; Action Editor Ria De Bleser)