

37. Nezu A, Kimura S, Osaka H. Tolosa-Hunt syndrome with pseudotumor cerebri. Report of an unusual case. *Brain Dev* 1995; 17: 218.
38. Ohta S, Nishizawa S, Namba H, Sugimura H. Bilateral cavernous sinus actinomycosis resulting in painful ophthalmoplegia. Case report. *J Neurosurg* 2002; 96: 600–602.
39. Sanchez Pina C, Pascual-Castroviejo I, Martinez Fernandez V, Martinez Jimenez A, Carrasco Sanz A. Burkitt's lymphoma presenting as Tolosa-Hunt syndrome. *Pediatr Neurol* 1993; 9: 157–158.
40. Vailati A, Marena C, Comis S, Aristia L, Sozze E, Galenda P, et al. Hashimoto's thyroiditis in association with Tolosa-Hunt syndrome: a case report. *Thyroid* 1993; 3: 125–127.
41. Wasmeier C, Pfadenhauer K, Rosler A. Idiopathic inflammatory pseudotumor of the orbit and Tolosa-Hunt syndrome – are they the same disease? *J Neurol* 2002; 249: 1237–1241.

Bilateral spontaneous carotid artery dissection

Bradley Scott Townend, Laura Traves, Denis Crimmins

Neurology Department, Gosford Hospital, NSW, Australia

Summary Bilateral internal carotid artery dissections have been reported, but spontaneous bilateral dissections are rare. Internal carotid artery dissection can present with a spectrum of symptoms ranging from headache to completed stroke. Two cases of spontaneous bilateral carotid artery dissection are presented, one with headache and minimal symptoms and the other with a stroke syndrome. No cause could be found in either case, making the dissections completely spontaneous. Bilateral internal carotid artery dissection (ICAD) should be considered in young patients with unexplained head and neck pain with or without focal neurological symptoms and signs. The increasing availability of imaging would sustain the higher index of suspicion.

© 2005 Elsevier Ltd. All rights reserved.

Journal of Clinical Neuroscience (2005) 12(5), 592–594
0967-5868/\$ - see front matter © 2005 Elsevier Ltd. All rights reserved.
doi:10.1016/j.jocn.2004.08.020

Keywords: Bilateral, spontaneous, carotid, vertebral, dissection, complications

Received 15 June 2004

Accepted 18 August 2004

Correspondence to: Dr. Brad Townend, Neurology Department, Gosford Hospital, Holden St, Gosford, NSW 2250 Australia.

Tel.: 61 2 4320 3932/0407 757 111(Mob);

E-mail: btownend@doh.health.nsw.gov.au

INTRODUCTION

It has been reported that 20% of cerebral ischaemic accidents occurring before the age of 45 are the result of carotid dissection.¹ Such dissections are usually unilateral, however. We present two cases of spontaneous bilateral carotid dissection (the second case involving dissection of all four major cerebral arteries). Both these cases are defined as spontaneous since no cause was demonstrated. There is no suggestion in the literature to explain why two independent carotid arteries would dissect simultaneously. While bilateral ICADs have been reported, spontaneous bilateral dissections are rare. However, the greater availability of diagnostic imaging and a higher index of clinical suspicion will increase detection.

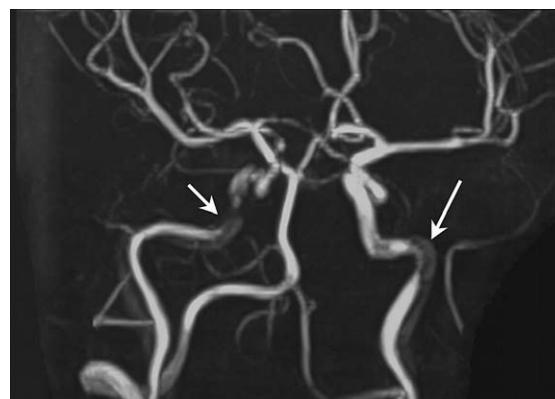


Fig. 1 MRA demonstrating bilateral internal carotid artery dissections.

CASE REPORT 1

A 51 year-old Caucasian female, previously fit and well, presented to her local emergency department with an eight day history of headache. The headache was severe, radiating from her neck to the base of her skull and forward into the vertex. It was associated with sharp pain in the left side of her neck that travelled across the back of the throat. There was some loss of taste sensation reported, along with nausea, vertigo and photophobia. There was no history of neck trauma (including manipulation) or vigorous exercise. Clinical examination was normal. Routine blood tests were unremarkable and head CT was normal. After a 5 day admission and no positive findings, the symptoms resolved and the patient discharged.

She was readmitted two weeks later with the headache persisting. In addition she now reported an episode of dysphasia lasting 10 minutes and an episode of tingling down the left side of her body. She was found to be normotensive, with no carotid bruits and no neurological signs. Investigations were again normal, including an MRI of the brain. MRA however, showed bilateral internal carotid artery dissection with significant flow disturbance affecting the R > L, distal to the carotid siphon (Fig. 1). There was no evidence of fibromuscular dysplasia on MRA, and cerebral angiography confirmed bilateral ICAD. The patient was treated with clopidogrel, and no further neurological events were reported. She remains well 6 months after the dissection.

CASE REPORT 2

A 31 year old female who was previously fit and well, presented to the local emergency department with a three day history of headache, increasing confusion and neck pain. She had symptoms of slurred speech and tingling down the right side of her face and both arms. On examination she was found to be hypertensive, orientated but confused with no neurological signs. Routine blood tests were normal except for a high plasma homocysteine level. Lumbar puncture and head CT were normal. The EEG showed non-specific slowing. MRI/MRA demonstrated acute and subacute right middle cerebral artery cortical and subcortical infarcts, combined with bilateral internal carotid artery dissections with a high grade stenosis on the right. Anticoagulation was commenced (See Figs. 2 and 3).

Subsequent cerebral angiography demonstrated significant stenosis of both carotid arteries (R > L) and also bilateral vertebral artery (VA) stenosis (R > L). These findings were consistent with bilateral carotid and vertebral artery dissections. The left internal carotid artery (ICA) and VA were stented and a perioperative MRA confirmed a further complicating non-haemorrhagic right

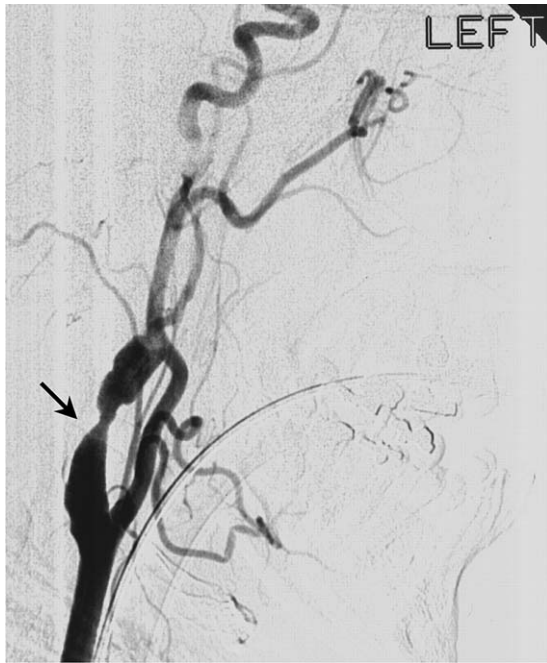

Fig. 2 Angiogram demonstrating occlusion of the left internal carotid artery due to dissection.

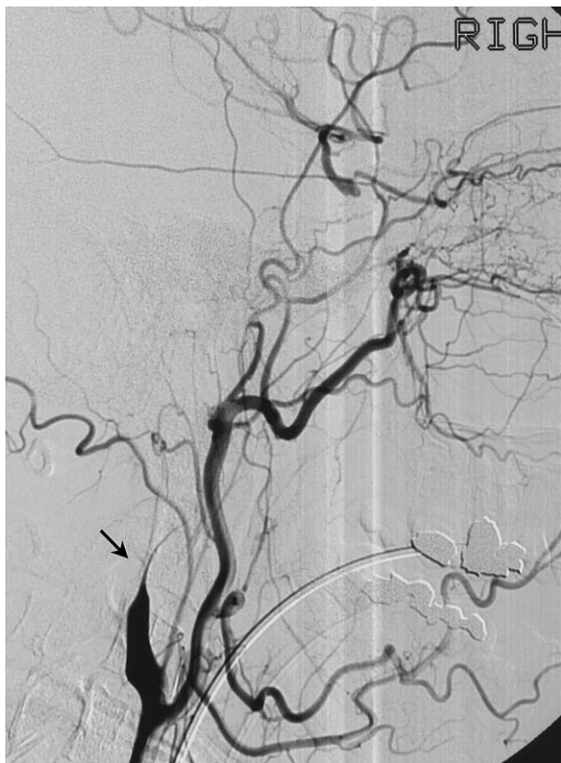

Fig. 3 Angiogram demonstrating complete occlusion of the right internal carotid artery due to dissection.

middle cerebral artery infarct resulting in hemiparesis and persistent confusion. Follow-up angiogram showed both stents were patent, and the RICA and RVA had started to recanalise. Current treatment continues with antiplatelet agents, folic acid, a statin and anti-hypertensive therapy. She is presently making a good recovery in rehabilitation.

DISCUSSION

While the majority of ICAD's present with major ischaemic events, suspicion of ICAD should also be aroused by local symptoms such as headache, neck pain and cranial nerve signs including hypoglossal nerve lesions or Horner's Syndrome - especially in young patients. These cases demonstrate that even with severe bilateral vessel pathology, symptomatology may still be atypical or minimal. For this reason bilateral, and even unilateral dissections may be missed. Baumgartner *et al* (2001)² describe a case series of 200 patients where 145/200 ICADs had ischaemic events and 55/200 had local signs as in our cases.

Bilateral ICAD is rare with the actual incidence difficult to quantify. As in these cases, the cause is often not found. Many conditions have been postulated to play a role in unilateral ICAD and this has been well reviewed in the literature. Fibromuscular dysplasia has been associated with up to 50% of bilateral dissections³, but this was not detected by the imaging in these cases. Mild hyperhomocysteinaemia (as present in case 2) could represent a risk factor through causing arterial wall damage.⁴ There is no explanation in the literature for carotid arteries to dissect bilaterally, simultaneously and spontaneously (i.e. no obvious precipitant or risk factor). In case 2 all four major cerebral arteries dissected simultaneously.

Both anticoagulation and antiplatelet therapies seem to be safe for managing ICAD and currently there is no evidence for different efficacy. These findings may indicate that a randomised controlled trial comparing anticoagulation and antiplatelet agents is ethically justified.⁵ Routine risk factor modification is also indicated, since hypertension, cholesterol and hyperhomocysteinaemia are all medically treatable causes. Complications make thrombolysis, surgery and endovascular stent placement contentious issues in the management of cerebral artery dissection, yet they may have their place.^{6,7,8} The second case highlights the potential complications of endovascular intervention when vessel recanalisation may have otherwise occurred spontaneously (as in case 1).

These cases highlight that symptoms and signs in bilateral ICAD may be non-specific and not correlate with the degree of pathology. Since many dissections go undiagnosed and untreated there is support for a natural history of ICAD resolution with minimal morbidity and mortality. Although ethically difficult to prove, withholding active treatment may be a feasible management option. There is however a likely place for well-tolerated medical treatment in reducing morbidity, and the more aggressive treatments of thrombolysis or endovascular stent placement may prove useful. The causative factor/s for spontaneous bilateral internal carotid artery dissection remain enigmatic.

REFERENCES

1. Leys D, Lucas C, et al. Cervical artery dissection. *Bur Neurology* 1997; 37: 3-12.
2. Baumgartner RW, Arnold M, Baumgartner I, Mosso M, Gonner F, Studer A, et al Carotid dissection with and without ischemic events: local symptoms and cerebral artery findings. *Neurology* 2001; 57(5): 827-832.
3. Ramos T, Goldstone J. Carotid artery dissection. In: *Current Therapy in Vascular Surgery*. 3rd ed.. St Louis: Mosby; 1995. p. 109-114.
4. Gallai V, Caso V, Paciaroni M, Cardaioli G, Arming E, Bottiglieri T, et al. Mild hyperhomocysteinaemia: a possible risk factor for cervical artery dissection. *Stroke* 2001; 32(3): 714-718.
5. Engelter S, Lyrer P, Kirsch E, Steck A. Long-term follow-up after extracranial internal carotid artery dissection. *Eur Neurol* 2000; 44(4): 199-204.
6. Derex L, Nighoghossian N, Turjman F, Hermier M, Honnorat J, Neuschwander P. Intravenous tPA in acute ischaemic stroke related to internal carotid artery dissection. *Neurology* 2000; 54(11): 2159-2161.

7. Muller B, Luther B, Hort W, Neumann-Haefelin T, Aulich A, Sandmann W. Surgical treatment of 50 carotid dissections: indications and results. *J Vasc Surg* 2000; 31(5): 980–988.
8. Malek A, Higashida R, Phatouros C, Lempert T, Meyers P, Smith W, et al. Endovascular management of extracranial carotid artery dissection achieved using stent angioplasty. *American Journal of Neuroradiology* 2000; 21(7): 1280–1292.

Adult intranasal meningoencephalocele presenting as a nasal polyp

K Krishna Kumar¹ MS DLO, K Ganapathy² MCH PHD
V Sumathi¹ DNB DLO, Vijay Rangachari¹ MBBS DNB,
Indu Sundararajan¹ MBBS DLO, R Govindaraj^a MBBS DLO

¹Department of Otorhinolaryngology, ²Department of Neurosurgery, Sundaram Medical Foundation, Chennai, India

Summary We present an isolated purely intranasal meningoencephalocele, presenting as a nasal polyp in an adult, which is uncommon. Based on a review of the literature, we emphasize that nasal obstruction may be the only presenting symptom of an intranasal meningoencephalocele.

© 2005 Elsevier Ltd. All rights reserved.

Journal of Clinical Neuroscience (2005) 12(5), 594–596
0967-5868/\$ - see front matter © 2005 Elsevier Ltd. All rights reserved.
doi:10.1016/j.jocn.2005.03.006

Keywords: intranasal meningoencephalocele, endoscopy

Received 15 October 2003

Correspondence to: K. Krishna Kumar ENT Surgeon, Sundaram Medical Foundation, Shanthi Colony, Anna Nagar, Chennai, 600040, India.
Tel.: +91 44 26268844;
E-mail: kganap@vsnl.com

INTRODUCTION

Intranasal meningoencephalocele is rare and is characterized by protrusion of the meninges from the cranial cavity into the nose, through a discontinuity in the cribriform plate of the ethmoid bone.^{1–5} Although it is usually a congenital anomaly, it may also occur following trauma or as a result of chronic raised intracranial hypertension. Rhinorrhoea and meningitis may be presenting features but it may also be asymptomatic until adulthood. Presentation with nasal obstruction or unilateral nasal congestion has been reported.^{6,7} Occult intranasal meningocele has been identified during preoperative investigation for craniofacial corrective surgery for hypertelorism.⁵

CASE REPORT

A 23-year old male presented with nasal obstruction on the left for 2 years. He also gave a history of intermittent clear nasal discharge, only on straining, for the last 5 years. There was no history of anosmia, trauma or previous nasal surgery. One episode of pyogenic meningitis had occurred 9 years previously. Clinical examination revealed no neurological deficit. Anterior rhinoscopy revealed deviation of the nasal septum to the right. A large cystic polypoid mass, arising from the roof of the nasal cavity and at-

tached to the bony septum, was seen in the left nasal cavity. Posterior rhinoscopy revealed a normal nasopharynx. A CT scan (Fig. 1) of the paranasal sinuses revealed a polypoid mass arising from the roof of the nose, with clear paranasal sinuses.

With a preoperative diagnosis of a nasal polyp, surgery was undertaken. Under general anesthesia using a nasal endoscope (0/30/45°), the attachment of the mass was initially defined. The mass was arising from the roof of the nasal cavity and attached to the bony septum (Fig. 2,3). As the mass appeared cystic, it was initially aspirated and 8 to 10 ml of clear fluid was obtained. Biochemical analysis was compatible with CSF. The mass was excised using turbinate scissors. A CSF leak was noted after excision of the mass (Fig. 4). The area adjacent to the defect was cleared and the defect closed using fat and temporalis fascia. The nasal cavity was packed in layers. A postoperative CT scan of the paranasal sinuses revealed no evidence of a CSF leak. Postoperative endoscopy showed a healthy graft around the defect with no CSF leak. Histopathology of the excised specimen revealed fibrosis, chronic inflammation and heterotopic glial tissue (Fig. 5). The patient was asymptomatic at 6 months follow up.

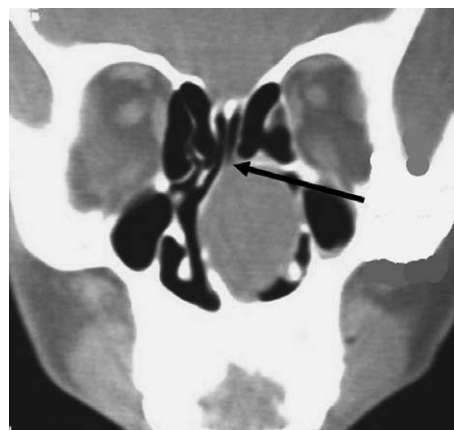


Fig. 1 Coronal CT scan of the paranasal sinuses showing a polypoid mass arising from the roof of the nose (arrow), with clear paranasal sinuses.

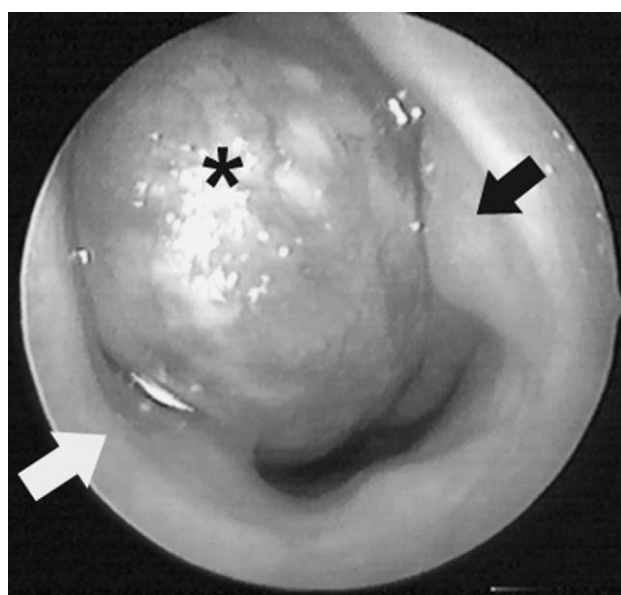


Fig. 2 The mass (asterix) was clearly seen on anterior rhinoscopy between the nasal septum (white arrow) and the lateral nasal wall (black arrow).