

Selection and combination of various endovascular techniques in the treatment of giant aneurysms

WARO TAKI, M.D., SHOGO NISHI, M.D., KOHSUKE YAMASHITA, M.D.,
AKIYO SADATO, M.D., ICHIRO NAKAHARA, M.D., HARUHIKO KIKUCHI, M.D., AND
HIROO IWATA, PH.D.

Department of Neurosurgery, Kyoto University Medical School, Kyoto, and Department of Experimental Medicine, National Cardiovascular Center, Osaka, Japan

✓ Between April, 1989, and January, 1991, a total of 19 cases of giant aneurysm were treated by the endovascular approach. The patients included seven males and 12 females aged 15 to 72 years. Detachable balloons, occlusion coils, and ethylene vinyl alcohol copolymer liquid were used as embolic materials. In seven cases, thrombosis of the aneurysmal sac and/or base was achieved while sparing the parent arterial flow; complete obliteration of the aneurysm was achieved in four of these. Of these four patients, the thrombotic material was a detachable balloon in two, a combination of a detachable balloon and coils in one, and occlusion liquid in one. In the other three cases, complete occlusion was not achieved; one aneurysm was occluded with a detachable balloon and two with coils. In 11 patients, the parent artery was occluded either by trapping or by proximal arterial occlusion, and all patients showed complete occlusion of the aneurysms. In one patient, a combined bypass procedure and parent artery occlusion was performed.

Among the 19 cases in this series there were four transient ischemic attacks, one reversible ischemic neurological deficit, and one death due to aneurysmal rupture during the procedure. Two patients died in the follow-up period, one from pneumonia 2 months postoperatively and the other from acute cardiac failure 2 weeks following surgery. Both deaths were unrelated to the endovascular procedure. It is concluded that the endovascular treatment of giant aneurysms remains difficult because of the large and irregular shape of the aneurysmal base and thrombus in the aneurysmal sac. The proper selection and combination of the available endovascular techniques is therefore of critical importance.

KEY WORDS • giant aneurysm • interventional radiology • embolization

ALTHOUGH the endovascular treatment of giant aneurysms (> 25 mm) has opened new horizons, it is still a subject of controversy.^{1,8} Endovascular treatment was once thought to be the ideal approach for these aneurysms, but in practice it has proved to be technically very difficult, with problems stemming apparently from the large and irregular-shaped aneurysmal base, the irregular size of the sac, and the presence of thrombus inside the aneurysm.⁴⁻⁷

In a recent 2-year period, we treated 19 cases of giant aneurysm using detachable balloons, coils, and a liquid occlusion material (ethylene vinyl alcohol copolymer).^{1,3} Our strategy is to spare the parent artery and occlude the aneurysm completely whenever possible. When this proves to be impossible, occlusion of the parent artery with a detachable balloon is performed. Because these aneurysms must be treated according to the requirements of the individual case, no single technique can be applied universally. Our results using a

variety of techniques are presented in this communication.

Clinical Material and Methods

Case Material

Between April, 1989, and January, 1991, we treated 19 cases of giant aneurysm. A clinical summary of these patients appears in Table 1. There were seven males and 12 females, aged 15 to 72 years. All were viewed as presenting surgical difficulties because of aneurysm location, aneurysm size, or thrombus formation in the aneurysmal sac. The presenting symptoms related to compression of the adjacent brain in 13 cases. One patient presented for treatment with reversible ischemic neurological deficit. The others were found by chance through computerized tomography scans performed to evaluate headache or injuries sustained in traffic accidents.

TABLE 1
Presenting symptoms in 19 cases of giant aneurysm*

Case No.	Age (yrs), Sex	Location	Presenting Symptoms
1	37, M	ACoA	visual disturbance
2	70, F	MCA	incidental
3	65, F	ICA-cavernous	III, IV, VI, V deficits
4	34, F	ACoA	incidental
5	67, F	ICA-ophthalmic	visual disturbance
6	69, F	ICA-ophthalmic	visual disturbance
7	62, M	A ₁	incidental
8	60, F	ICA-cavernous	III, IV, VI, V deficits
9	72, F	ICA-cavernous	III, IV, VI, V deficits
10	68, F	ICA-cavernous	III, V deficits
11	68, M	basilar top	tetraparesis, diplopia
12	15, M	PCA	III deficits
13	59, F	basilar top	incidental
14	72, M	VA-PICA	dysarthria, gait disturbance
15	56, M	BA-SCA	headache, dizziness
16	56, M	VA-PICA	dysarthria, nystagmus
17	18, F	VA-PICA	incidental
18	68, F	VA-PICA	gait disturbance, nystagmus
19	51, F	VA-PICA	dysarthria

* ACoA = anterior communicating artery; MCA = middle cerebral artery; ICA = internal carotid artery; A₁ = A₁ segment of the anterior cerebral artery; PCA = posterior cerebral artery; VA = vertebral artery; PICA = posterior inferior cerebellar artery; BA = basilar artery; SCA = superior cerebellar artery. Roman numerals denote cranial nerves.

Endovascular Techniques

Balloon Alone or Combination of Balloon and Coils. In 15 patients the aneurysm was treated by balloon occlusion alone, and in one a balloon and coils were introduced. In all but one case, the transfemoral approach was used. The exception was a patient with an ophthalmic aneurysm in whom the transfemoral approach failed because of tortuosity and arteriosclerosis of the origin of the carotid artery; direct carotid puncture was used instead. The transfemoral approach was begun with the patient under local anesthesia; the femoral artery was cannulated with the sheath introducer. The introducing catheter was then guided into either the internal carotid artery (ICA) or the vertebral artery. Through this catheter, a superselective balloon catheter with a deflated diameter of 1.35 mm was introduced and used to examine whether occlusion of the aneurysmal base was possible. When it was found that the base could be closed by the balloon, there was a strong possibility of achieving occlusion with a detachable balloon catheter; therefore, we proceeded with this as the next stage of the procedure. Since most of the giant aneurysms had a large sac that could not be obliterated with a single balloon, the sac was first filled with a number of balloons or coils. The remaining sac around the aneurysmal base was then obliterated with an electrodetachable balloon.*⁹⁻¹¹

* Electrodetachable balloon manufactured by Dow Corning, Kanagawa, Japan.

Coils Alone. When the carotid or vertebral artery was so tortuous that the detachable balloon could not reach the aneurysmal sac, the microcatheter was threaded up to the aneurysm using a guide wire, and platinum coils were packed into the aneurysm. This method was used in two cases.

Liquid Material. Thrombus formation in the aneurysm makes balloon occlusion at the base difficult, since the detached balloon will gradually become embedded in the thrombus, then move from the original site over the following days or weeks, with possible reopening of the neck.⁷ Also, several giant aneurysms had an irregular cavity shape that did not match the spherical shape of the balloon. Because of this, liquid occlusion material was used in one patient. The need for a precise injection technique and a favorable anatomical environment for this technique is discussed later.

Aneurysm Occlusion Without Sparing Parent Arterial Flow. When the aneurysm was not suitable for the above-mentioned methods of treatment, occlusion of the parent artery with a detachable balloon was performed. Prior to permanent occlusion of the parent artery, an occlusion test was performed for 15 minutes under full heparinization. Changes in patient neurological signs and electroencephalographic recordings were closely monitored. If the occlusion test was positive, bypass surgery was performed. The occlusion test was then repeated and the parent artery was occluded 3 weeks later.

Illustrative Cases

Case 1: Combination of Detachable Balloon and Coils

This 37-year-old man experienced the gradual onset of left visual disturbance due to optic nerve compression caused by a giant aneurysm of the anterior communicating artery (ACoA) (Fig. 1 *left*). Vision in the left eye was reduced to finger counting. A combination of detachable balloons and coils was used to obliterate the aneurysm. The first balloon was placed accurately, but the remaining sac was very large. A microcatheter was guided into the sac and a number of platinum coils† were placed into the aneurysmal sac; the remaining sac at the base was then embolized with a second balloon (Fig. 1 *center and right*). The patient was followed for 23 months, and visual acuity improved sufficiently for the patient to be able to read a newspaper.

Case 7: Coils Alone

This 62-year-old man presented with headache and dizziness. Angiography revealed a partially thrombosed aneurysm at the terminal portion of the right ICA. Since the ICA was tortuous and a detachable balloon could not reach the aneurysmal sac, a microcatheter

† Platinum coils manufactured by Target Therapeutics, San Jose, California.

Endovascular treatment of giant aneurysms

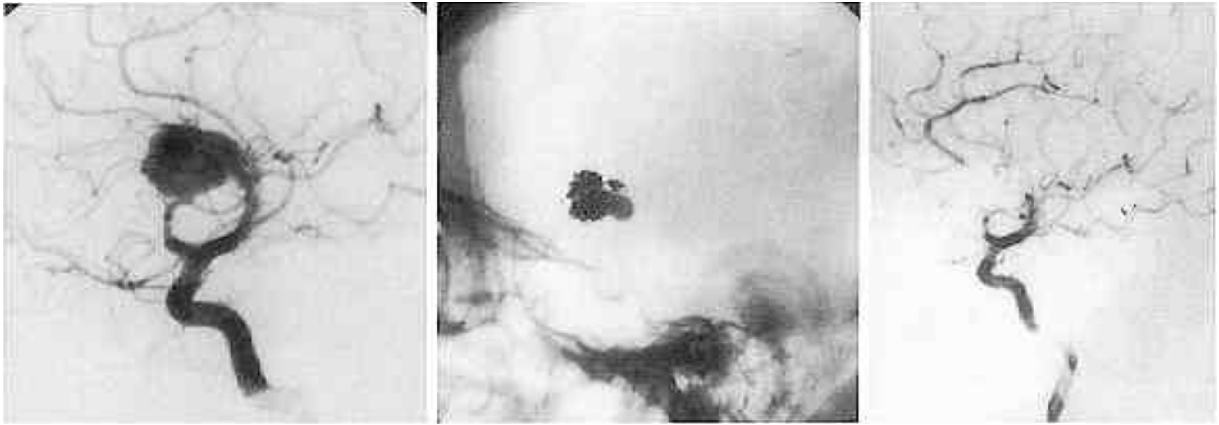


FIG. 1. Right internal carotid arteriograms of Case 1. *Left:* A giant aneurysm is seen at the anterior communicating artery. *Center:* Balloons and coils are seen in the aneurysm. The base of the aneurysm was occluded by the second balloon. *Right:* Postoperative study.

was guided into the aneurysmal sac and Hilal coils[‡] were inserted. However, placing coils inside the aneurysmal sac without any protrusion into the parent artery proved to be difficult and the base could not be sealed. Follow-up angiography 3 months later revealed migration of the coils and a persisting aneurysmal sac (Fig. 2).

Case 4: Liquid Occlusion Material

This 34-year-old woman suddenly developed right hemiparesis and slight aphasia. Angiography revealed occlusion of the left middle cerebral artery and a giant aneurysm at the ACoA (Fig. 3A). Her neurological symptoms subsequently improved. A craniotomy was performed and the aneurysm was clipped. Immediately after the operation, angiography showed disappearance of the aneurysm. Nine years later, the patient complained of headache and follow-up angiography revealed reopening and enlargement of the previous aneurysm. Incomplete clipping or slipping of the clip was thought to have been the cause.

A second craniotomy was performed, but the surgeon could not clip the aneurysm, and the patient was referred to our hospital. The A₁ segment of the left anterior cerebral artery (ACA) was very narrow due to compression by the aneurysm, and the left ACA was mainly supplied by the right ICA via the ACoA (Fig. 3B). Thus, the ACoA and the base of the aneurysm were occluded for 15 minutes prior to embolization to determine whether this caused ischemia of the left ACA territory. There were no ischemic symptoms since the retrograde leptomeningeal collateral supply was apparently adequate. It was concluded that any inadvertent leakage of the occlusion liquid into the proximal segment of the opposite A₁ segment would not result in severe ischemic neurological deficit. Femoral arte-

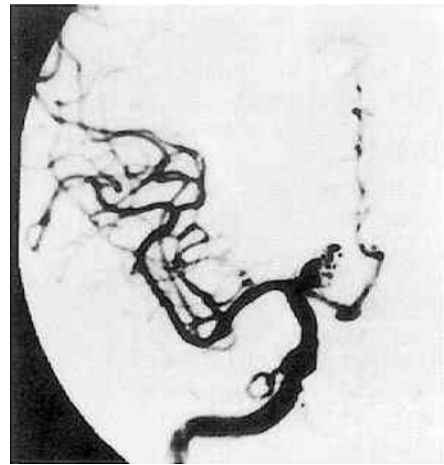


FIG. 2. Case 7. Right internal carotid arteriogram 3 months after treatment of a giant aneurysm at the right A₁ segment. Many coils were placed in the aneurysmal sac but it was difficult to place coils near the base of the aneurysm due to the likelihood that part of a coil might protrude into the parent arterial lumen. Some migration of a coil and incomplete occlusion of the aneurysm are seen.

ries on both sides were punctured and sheath introducers were placed in each artery. A microcatheter was guided up to the narrow segment of the ACoA, while the superselective balloon catheter was simultaneously threaded to the aneurysmal sac through this narrow segment of the artery. The balloon was inflated at the right A₁-A₂ junction. With the balloon inflated and occluding the orifice, contrast medium was injected through the microcatheter and the flow through the aneurysm to the left ACA was closely monitored to avoid inadvertent embolization (Fig. 3C). Under fluoroscopic control, a calculated volume of ethylene vinyl alcohol copolymer was slowly injected and after 3 minutes its precipitation was complete. During injection,

[‡] Hilal coils manufactured by Cook, Inc., Bloomington, Indiana.

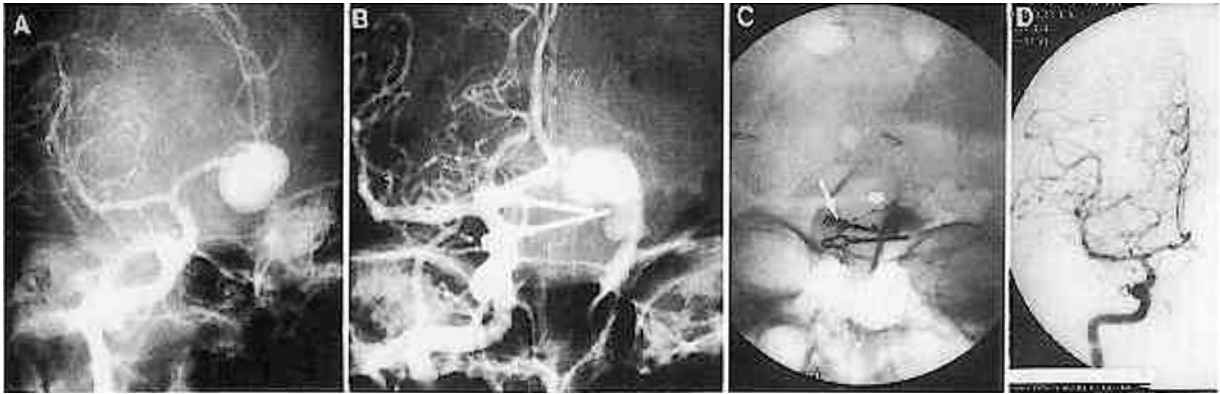


FIG. 3. Right internal carotid arteriograms in Case 4. A: A giant aneurysm of the anterior communicating artery is shown. B: Nine years after clipping, the aneurysm can be seen to have recanalized. C: A microcatheter was guided into the aneurysm (*long arrow*). The balloon was inflated at the right A₁-A₂ junction, while contrast medium was injected from the other microcatheter (*short arrow*). The flow into the aneurysm and out to the left A₁ drainage was closely monitored so as to avoid inadvertent embolization. Following this, ethylene vinyl alcohol copolymer liquid was carefully injected into the aneurysmal lumen. D: Follow-up angiogram 6 months after embolization confirming complete occlusion of the aneurysm.

strict care was taken not to permit the liquid to enter the left ACA. After this, the balloon was deflated and both catheters were extracted. Angiography immediately after treatment revealed occlusion of the aneurysm, and repeat angiography after 6 months confirmed the occlusion (Fig. 3D).

Results

The operative results are shown in Table 2. In seven patients, the aneurysmal sac and/or the base was occluded, with complete obliteration of the aneurysm being obtained in four cases. In two of four patients with complete thrombosis, balloons were used to produce the occlusion; one of these patients was treated with a combination of detachable balloons and coils and the other with occlusion liquid. There were three cases in which complete occlusion was not achieved; one was managed with a detachable balloon and two with coils. In 11 patients, the parent artery was occluded; in each case, complete angiographically verified occlusion of the aneurysm was achieved. In one cavernous aneurysm, a combined bypass procedure and parent arterial occlusion was performed. In this patient, the occlusion test was positive and therefore temporary occlusion of the ICA could not be tolerated. Three weeks after extracranial-intracranial bypass, occlusion became possible and the ICA was occluded.

Six patients suffered postoperative complications. Two experienced transient ischemic attacks (TIA's) during the procedure that were due to mechanical vasospasm of the ICA caused by the relatively large introducing catheter; however, the symptoms disappeared within 10 to 20 minutes after the introducing catheter was repositioned more proximally. One patient exhibited a reversible ischemic neurological deficit, caused by dissection of an intimal flap of the vertebral artery with the guide wire. Two patients treated by parent

artery occlusion suffered a TIA on the 4th postoperative day, due to hypotension in one and microthromboembolism in the other. The diagnosis of microthromboembolism was not angiographically proven but was a diagnosis of exclusion, since the TIA lasted for only a few minutes and the patient was normotensive. One aneurysm ruptured during navigation of the balloon into the aneurysmal sac and the patient died 5 days later. Two patients died during the follow-up period, one from pneumonia 2 months postoperatively and the other from acute cardiac failure 2 weeks after surgery. Both causes were unrelated to the endovascular procedure.

Discussion

Surgical Considerations

The surgical treatment of giant aneurysms is very difficult because the base of such lesions is usually very stiff as well as broad, and clipping can be associated with occlusion of adjacent small perforators or even the parent artery if the clip slips off the base.^{2,3} Temporary occlusion of the parent artery during the removal of a thrombus from the aneurysmal sac to facilitate clipping can cause permanent complications if the period of occlusion is long. Furthermore, dissection of the hard mass of a thrombosed aneurysm from the brain stem is not an easy procedure.

Endovascular Treatments

Difficulties with the surgical treatment of giant aneurysms stimulated enthusiastic expectations from endovascular treatment when it was first introduced.⁸ However, in our experience this treatment for giant aneurysms still has many problems. Our present occlusive material are balloons, coils, and liquid. To achieve complete occlusion of the aneurysmal base, it is neces-

Endovascular treatment of giant aneurysms

TABLE 2
Results of endovascular treatments in 19 cases of giant aneurysm*

Case No.	Location	Embolitic Material	Parent Vessel Patent	Angiographic Results (1 wk)	Follow-up Period (mos)	Complications
1	ACoA	balloon & coils	yes	complete	23	TIA (Day 0)
2	MCA	balloon	yes	complete	8	—
3	ICA-cavernous	balloon	no	complete	12	—
4	ACoA	EVC	yes	complete	8	TIA (Day 0)
5	ICA-ophthalmic	balloon	no	complete	died (unrelated pneumonia), 2	—
6	ICA-ophthalmic	balloon	yes	complete	13	—
7	A ₁	coils	yes	incomplete	15	—
8	ICA-cavernous	balloon	no	complete	18	—
9	ICA-cavernous	balloon	no & bypass	complete	20	TIA (Day 4)
10	ICA-cavernous	balloon	no	complete	22	—
11	basilar top	balloon	aneurysmal rupture	died	died	rupture
12	PCA	balloon	no	complete	13	TIA (Day 4)
13	basilar top	balloon	yes	incomplete	died (unrelated cardiac failure), 0.5	—
14	VA-PICA	balloon	no	complete	20	—
15	BA-SCA	coils	yes	incomplete	23	RIND (Day 1)
16	VA-PICA	balloon	no	complete	23	—
17	VA-PICA	balloon	no	complete	20	—
18	VA-PICA	balloon	no	complete	3	—
19	VA-PICA	balloon	no	complete	3	—

* ACoA = anterior communicating artery; MCA = middle cerebral artery; ICA = internal carotid artery; EVC = ethylene vinyl alcohol copolymer; A₁ = A₁ segment of the anterior cerebral artery; PCA = posterior cerebral artery; VA = vertebral artery; PICA = posterior inferior cerebellar artery; BA = basilar artery; SCA = superior cerebellar artery; TIA = transient ischemic attack; RIND = reversible ischemic neurological deficit; — = none.

sary to choose a thrombotic material that will tightly occlude the sac and stay firmly in place.

Balloons

Problems connected with the use of balloons include a limited choice of size and shape and the potential risk of rupturing the aneurysm. A giant aneurysm often has a neck that is larger and broader than the balloons used for embolization, and sometimes the parent artery itself is incorporated into the aneurysm, so the selection of an appropriate balloon can be very difficult. Detachable balloons are usually smaller than the aneurysmal base, and part of the balloon may protrude into the parent arterial lumen. Also, the base often has an irregular shape and does not correspond to the shape of the balloon, which is spherical or oval. Inflation of a balloon large enough to occlude the base of the aneurysm completely might cause distention of the wall of the aneurysm where the base is nonspherical, resulting in accidental rupture. Thus, in our series complete occlusion by the balloon alone was achieved in only two cases.

Coils

Coils, which are small and malleable, can be packed into the aneurysmal sac with relative ease. When neatly piled up along the aneurysmal sac, many coils might present a lower risk of aneurysmal rupture compared with a detachable balloon. However, packing becomes difficult when it reaches near the base of the aneurysm. Packing the aneurysm with coils by means of a catheter

and guide wire causes small movements of the tip of the catheter and part of a coil may protrude into the parent arterial lumen after being pushed out from the catheter. Thus, complete packing of the aneurysmal base with coils alone becomes very difficult. Our results showed that complete obliteration was not achieved by coils alone, but the combined use of the coils in the sac and balloons at the base was useful in one case. Future technical improvements for the precise placement of coils are required.

Liquid Occlusion Material

In consideration of the disadvantages of balloons and coils, filling the aneurysmal lumen with a liquid material appeared to be a feasible alternative. However, before injection of the liquid material, drainage of blood from the aneurysmal sac is necessary to prevent rupture of the aneurysm. In our Case 4, drainage was into the opposite A₂ segment, a rather exceptional situation. Before injection of the occlusion liquid, precise observation of the flow of contrast medium into the aneurysm and out of the draining vessel is mandatory. Also, occlusion of the proximal orifice of the aneurysm during the injection of liquid embolic material must be complete, since any leak into the parent artery could cause disastrous ischemic complications.

Thus, the indications for use of liquid embolic material are very limited (one of 19 patients in our series). If there is no arterial drainage, blood should be removed via another catheter while injecting the liquid material; however, this is not possible at present because a suitable

ble catheter is not available. The liquid material to be used must undergo rapid precipitation or polymerization since the occlusion time must be short; also, it should not adhere to the catheter.¹² For these reasons, we chose ethylene vinyl alcohol copolymer. This liquid occlusion technique is very effective and should be considered when no other method is feasible.

References

1. Debrun G, Lacour P, Caron JP, et al: Detachable balloon and calibrated-leak balloon techniques in the treatment of cerebral vascular lesions. *J Neurosurg* **49**:635-649, 1978
2. Drake CG: Giant intracranial aneurysms: experience with surgical treatment in 174 patients. *Clin Neurosurg* **26**: 12-95, 1979
3. Drake CG: Ligation of the vertebral (unilateral or bilateral) or basilar artery in the treatment of large intracranial aneurysms. *J Neurosurg* **43**:255-274, 1975
4. Halbach VV, Hieshima GB, Higashida RT: Treatment of intracranial aneurysms by balloon embolization. *Semin Intervent Radiol* **4**:261-268, 1987
5. Higashida RT, Halbach VV, Cahan LD, et al: Detachable balloon embolization therapy of posterior circulation intracranial aneurysms. *J Neurosurg* **71**:512-519, 1989
6. Higashida RT, Hieshima GB, Halbach VV, et al: Intravascular detachable balloon embolization of intracranial aneurysms. Indications and techniques. *Acta Radiol Suppl* **369**:594-596, 1986
7. Nakahara I, Taki W, Nishi S, et al: Treatment of giant anterior communicating artery aneurysm via an endovascular approach using detachable balloons and occlusive coils. *AJNR* **11**:1195-1197, 1990
8. Serbinenko FA: Balloon catheterization and occlusion of major cerebral vessels. *J Neurosurg* **41**:125-145, 1974
9. Taki W, Handa H, Yamagata S, et al: Balloon embolization of a giant aneurysm using a newly developed catheter. *Surg Neurol* **12**:363-365, 1979
10. Taki W, Handa H, Yamagata S, et al: Embolization and superselective angiography by means of balloon catheters. *Surg Neurol* **12**:7-14, 1979
11. Taki W, Handa H, Yamagata S, et al: Radiopaque solidifying liquids for releasable balloon technique: a technical note. *Surg Neurol* **13**:140-142, 1980
12. Taki W, Yonekawa Y, Iwata H, et al: A new liquid material for embolization of arteriovenous malformations. *AJNR* **11**:163-168, 1990

Manuscript received June 18, 1991.

Accepted in final form December 11, 1991.

Address reprint requests to: Waro Taki, M.D., Department of Neurosurgery, Kyoto University Medical School, 54 Kawaharacho Shogoin Sakyoku, Kyoto, Japan.