

Role of dynamic CT myelography in identifying the etiology of superficial siderosis

Abstract—The authors report three cases of superficial siderosis with a fluid-filled spinal canal cavity communicating with the subarachnoid space. The site of communication was identified with dynamic CT myelography and the defect was surgically repaired.

NEUROLOGY 2005;65:486–488

Neeraj Kumar, MD; E. Paul Lindell, MD; Jessica A. Wilden, BS; and Dudley H. Davis, MD

Superficial siderosis is characterized by sensorineural deafness, cerebellar ataxia, pyramidal signs, cognitive decline, and bladder disturbance.¹ It is due to chronic subarachnoid hemorrhage and resulting hemosiderin deposition in the subpial layers of the brain and spinal cord. Causes include root avulsion, tumors, vascular malformations, and brain or spine surgery.¹ MRI has a high sensitivity for detection of hemosiderin. Findings include hypointensity on T2-weighted MRI on the surface of the brainstem, cerebellum, and cortical fissures. Cerebral and spinal angiogram and CT-myelogram can identify the source of bleeding. Surgical intervention with ablation of the bleeding source is the most effective therapy. Often the source of bleeding is not identified.

We report three cases of superficial siderosis. Each had a history of trauma and MRI revealed a fluid-filled cavity in the spinal canal (table). The initial course of one case has been reported elsewhere.² The site of communication between the cavity and subarachnoid space was identified on dynamic CT-myelography and the dural defect was successfully repaired.

Case reports. Case 1 is a 42-year-old man with a history of a motor vehicle accident (MVA) who was evaluated for an 8-year history of progressive gait ataxia and deafness. His examination revealed dysarthria, extensor plantar responses, and an ataxic gait. Typical findings of superficial siderosis were seen on brain and cord MRI. Also present was a nonenhancing, fluid-filled cavity ventral to the spinal cord from C4 to T9 (figure, A and B). Prominent vessels were seen along the surface of the ventral cervical cord, medulla, and pons. The cord was tethered to the dural sac at T9. No abnormalities were noted on cerebral and spinal angiography. CSF examination showed xanthochromia with 1,133 red cells/ μ L, 13 white cells/ μ L, and a protein of 117 mg/dL. Surgery was done with the intent of releasing a presumed T9 cord herniation. A T9-10 laminectomy was done and the adhered cord was

released. A left-sided root avulsion was seen at T10. No dural defect or cord herniation was noted. CSF examination 6 months following the surgery showed persisting subarachnoid hemorrhage. A dynamic CT-myelogram done 10 months after the surgery identified a dural defect communicating with the fluid-filled cyst at T1-2 (figure, C). A T1-3 laminectomy was done. Ventral to the exit of the T2 root a well-circumscribed dural defect was identified and packed with harvested paraspinal muscle. A repeat CSF study done 12 weeks later showed no cells. A follow-up MRI showed decrease in the fluid-filled cavity (figure, D). On telephone contact 6 months later no deterioration was reported.

Case 2 is a 51-year-old woman who was evaluated for a 4-year history of gait ataxia and deafness. After a MVA at age 16, she had a left hemiparesis. Her examination also showed cerebellar signs and spasticity. Typical findings of superficial siderosis were seen on brain and cord MRI. The cord was atrophic and a nonenhancing fluid collection was seen ventral to the spinal cord from T1 to T3 (figure, E and F). Prominent vessels were seen along the surface of the upper cervical cord and right posterior fossa. The spinal angiogram was normal. The cerebral angiogram showed an occluded right internal jugular vein at the jugular foramen, possibly related to her prior trauma. A dynamic CT-myelogram showed a communication between the fluid-filled cavity and thecal sac at T1-2 (figure, G). A T1-2 laminectomy was done. A dural rent was identified at the level of exit of the T2 root. The rent extended to the left of the midline. Repair of the defect required sacrificing the left T2 root. Follow-up MRI showed resolution of the fluid-filled cavity (figure, H).

Case 3 is a 52-year-old man with a history of a MVA who was evaluated for a 7-year history of gait difficulty and deafness. His examination was remarkable for cerebellar signs, extensor plantar responses, and decreased pinprick and touch perception in the S2-S4 dermatomes. Brain (figure, L) and spine MRIs showed typical findings of superficial siderosis. The spine MRI also showed an atrophic conus and evidence of arachnoiditis. Also present was fluid collection ventral to the cord from C3 to L5 (figure, I and J). A dynamic CT-myelogram identified a communication between the thecal sac and the cavity at T11 (figure, K). A T10-11 laminectomy identified a defect caudal to the T11 root. Repair required transecting the left T11 root. At this level the arachnoid around the discolored cord was adhered to the dura which in turn was attached to the epidural tissues and was keeping the opening patent. No follow-up MRI is available.

Discussion. In each case the superficial siderosis was accompanied by a loculated, nonenhancing spinal fluid collection ventral to the cord. It was unclear if the cyst was intradural or extradural. The differential diagnosis entertained was that of an arachnoid cyst, meningocele, or CSF loculation. A dynamic CT-myelogram done in each case showed filling of the area of fluid collection with contrast, confirming free communication with the subarachnoid space. The dynamic nature of the study helped identify the

From the Department of Neurology (Dr. Kumar), Department of Radiology (Dr. Lindell), Mayo Medical School (J.A. Wilden), and Department of Neurosurgery (Dr. Davis), Mayo Clinic, Rochester, MN.

Disclosure: The authors report no conflicts of interest.

Received January 25, 2005. Accepted in final form April 25, 2005.

Address correspondence and reprint requests to Neeraj Kumar, Department of Neurology, Mayo Clinic, 200 First Street SW, Rochester, MN 55905; e-mail: kumar.neeraj@mayo.edu

See also page 489

Table Clinical, imaging, and surgical aspects of the 3 cases

	Case 1	Case 2	Case 3
Age at presentation, y	42	51	52
Sex	M	F	M
Age at symptom onset, y	34	47	45
Age at time of MVA	10 y	16 mo	27 y
Symptoms	Gait ataxia, hearing difficulty, anosmia, incontinence	Gait ataxia, hearing difficulty, incontinence	Gait ataxia, hearing difficulty, tinnitus, incontinence
Signs	Cerebellar signs, impaired hearing, spasticity	Baseline spastic left hemiparesis, cerebellar signs, impaired hearing, spasticity	Cerebellar signs, impaired hearing, spasticity, decreased pinprick and touch perception in S2-4 dermatome
Brain MRI	Superficial siderosis, cerebellar atrophy, prominent vessels along ventral medulla and pons	Superficial siderosis, cerebellar atrophy, prominent vessels along right posterior fossa	Superficial siderosis, cerebellar atrophy
Spine MRI			
Superficial siderosis	Arachnoiditis	Arachnoiditis	Arachnoiditis
Cord	Cord tethered to dural sac at T9	Atrophic cord with myelomalacia from T4-T5	Atrophic conus
Fluid collection	Ventral to spinal cord from C4 to T9, non-enhancing	Ventral to spinal cord from T1 to T3	Ventral to spinal cord from C3 to L5
Prominent Vessels	Along surface of upper ventral cervical spinal cord	Along surface of upper cervical spinal cord	
		Scalloping of dorsal body of T1 and T2	Mild epidural lipomatosis
Dynamic CT myelogram	Communication between fluid filled cavity and thecal sac at T1-2	Communication between fluid filled cavity and thecal sac at T1-2	Communication between fluid filled cavity and thecal sac at T11 (left)
Surgery			
First	T9-10 laminectomy with release of the adherent cord	T1-2 laminectomy with repair of defect	T10-11 laminectomy with repair of defect caudal to the T11 root on the left
Second	10 mo later: T1-3 laminectomy with repair of a dural defect ventral to the exit of the T2 root		

progressive differential opacification of the ventral cyst thus leading to localization of the site of communication between the fluid collection and thecal sac. This technique is also used to identify the site of dural defects in patients with intracranial hypotension due to high-flow CSF leaks. The study helped determine the level of the laminectomy. In each case the site of CSF leak was successfully localized at surgery and repaired. Successful repair in Case 1 was confirmed by showing absence of cells on a CSF study after the second surgery.

Spinal arteriovenous malformations can cause superficial siderosis.³ The prominent vascularity seen in the posterior fossa and cervical cord in Case 1 prompted a search for a vascular malformation as a cause for the superficial siderosis. None was found. In Case 1 the extensive siderosis could have caused

sclerosis of the epidural veins leading to venous hypertension and prominent vascularity. The vascularity in Case 2 was possibly due to the occluded right internal jugular vein. The atrophic conus or involvement of the S2-4 nerve roots is the likely reason for the sacral sensory loss seen in Case 3. In superficial siderosis the peripheral nervous system is not involved and there is a cut-off in the spinal roots at the junction of the peripheral Schwann cell segment and central glial segment.⁴

The duration of follow-up in our patients is too short to determine benefit of surgery. Further, it is unclear if the pathologic process is halted after correction of the cause. Disease progression despite removal of the source of exposure is well described in manganese neurotoxicity.⁵

Traumatic pseudomeningoceles are well described

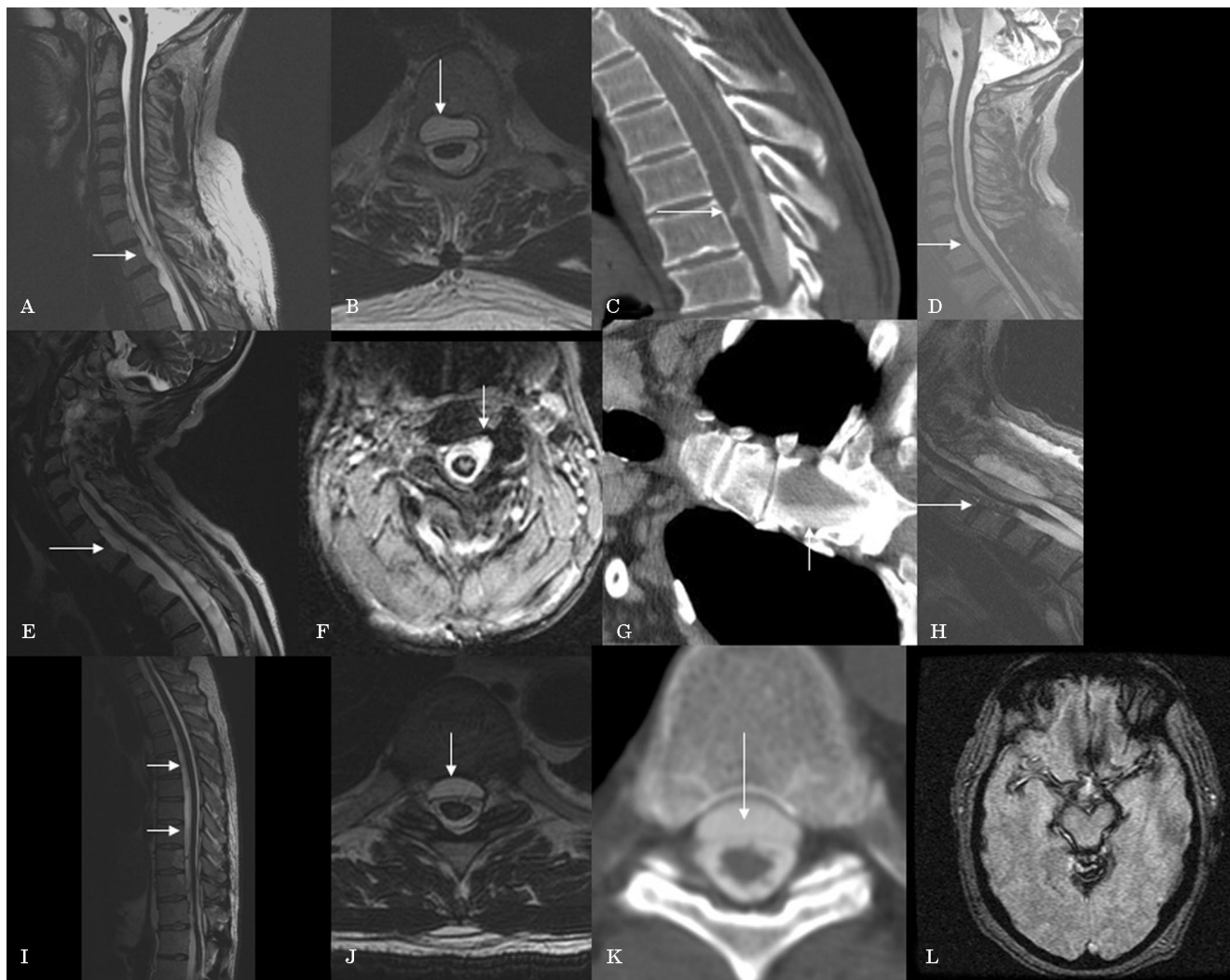


Figure. Sagittal T2 (A, E, I), axial T2 (B, F, J) spine MRIs in Case 1 (A, B), 2 (E, F), and 3 (I, J) showing the ventral fluid collection. Dynamic CT myelogram (C, G, K) showed differential opacification of the fluid-filled cavity and localized the defect to T1-2 in Cases 1 and 2, and to T11 in Case 3. Follow-up sagittal T2 MRIs in Case 1 (D) and 2 (H) show decrease and resolution respectively of the fluid-filled cavity. (L) Shows the findings of superficial siderosis on an axial gradient echo axial brain MRI in Case 3. Similar findings were seen in the other patients.

but the reason why pseudomeningoceles are predisposed to chronic venous bleeding is unknown. Superficial siderosis due to traumatic pseudomeningoceles following brachial plexus injury has been treated surgically in some patients.⁶⁻⁹ The association of a fluid-filled spinal column cavity that communicates with the subarachnoid space in patients with superficial siderosis and history of trauma is not well recognized. The three cases presented illustrate the importance of looking for such a communication with dynamic CT-myelogram. Repair of the dural defect can decrease intrathecal bleeding and hopefully slow or halt progression of symptoms. Dynamic CT-myelogram should be part of the evaluation of patients with superficial siderosis who have cystic fluid collections. Detection of a fistulous communication may lead to surgical correction. The exact mechanism of chronic bleeding in these patients remains to be elucidated.

References

1. Fearnley JM, Stevens JM, Rudge P. Superficial siderosis of the central nervous system. *Brain* 1995;118:1051-1066.
2. Wilden JA, Kumar N, Murali HR, Lindell PE, Davis DH. Unusual neuroimaging in superficial siderosis. *Neurology* 2005;65:489.
3. Schievink WI, Apostolides PJ, Spetzler RF. Surgical treatment of superficial siderosis associated with a spinal arteriovenous malformation. Case report. *J Neurosurg* 1998;89:1029-1031.
4. Koeppen AH, Dentinger MP. Brain hemosiderin and superficial siderosis of the central nervous system. *J Neuropathol Exp Neurol* 1988;47:249-270.
5. Huang CC, Chu NS, Lu CS, Chen RS, Calne DB. Long-term progression in chronic manganism: ten years of follow-up. *Neurology* 1998;50:698-700.
6. Bonito V, Agostinis C, Ferraresi S, Defanti CA. Superficial siderosis of the central nervous system after brachial plexus injury. Case report. *J Neurosurg* 1994;80:931-934.
7. Tapscott SJ, Eskridge J, Kliot M. Surgical management of superficial siderosis following cervical nerve root avulsion. *Ann Neurol* 1996;40:936-940.
8. Kole MK, Steven D, Kirk A, Lownie SP. Superficial siderosis of the central nervous system from a bleeding pseudomeningocele. Case illustration. *J Neurosurg* 2004;100:718.
9. Cohen-Gadol AA, Krauss WE, Spinner RJ. Delayed central nervous system superficial siderosis following brachial plexus avulsion injury. *Neurosurg Focus* 2004;16:E10.

Neurology[®]

Role of dynamic CT myelography in identifying the etiology of superficial siderosis

Neeraj Kumar, E. Paul Lindell, Jessica A. Wilden, et al.

Neurology 2005;65;486-488

DOI 10.1212/01.wnl.0000172345.05810.14

This information is current as of August 8, 2005

Updated Information & Services	including high resolution figures, can be found at: http://www.neurology.org/content/65/3/486.full.html
References	This article cites 9 articles, 3 of which you can access for free at: http://www.neurology.org/content/65/3/486.full.html#ref-list-1
Citations	This article has been cited by 7 HighWire-hosted articles: http://www.neurology.org/content/65/3/486.full.html#otherarticles
Subspecialty Collections	This article, along with others on similar topics, appears in the following collection(s): All Spinal Cord http://www.neurology.org/cgi/collection/all_spinal_cord MRI http://www.neurology.org/cgi/collection/mri
Permissions & Licensing	Information about reproducing this article in parts (figures, tables) or in its entirety can be found online at: http://www.neurology.org/misc/about.xhtml#permissions
Reprints	Information about ordering reprints can be found online: http://www.neurology.org/misc/addir.xhtml#reprintsus

Neurology® is the official journal of the American Academy of Neurology. Published continuously since 1951, it is now a weekly with 48 issues per year. Copyright . All rights reserved. Print ISSN: 0028-3878. Online ISSN: 1526-632X.

