

CADASIL with *NOTCH3* S180C presenting anticipation of onset age and hallucinations

Tomohiko Nakamura^a, Hirohisa Watanabe^a, Masaaki Hirayama^a, Akira Inukai^a,
Hidehiro Kabasawa^b, Michitaka Matsubara^c, Shigehisa Mitake^d, Masaaki Nakamura^e,
Yukio Ando^e, Makoto Uchino^f, Gen Sobue^{a,*}

^a Department of Neurology, Nagoya University Graduate School of Medicine, 65 Tsurumai-cho, Showa-ku, Nagoya 466-8550, Japan

^b Department of Rehabilitation, Nagoya City Rehabilitation and Sports Center, Nagoya 467-8622, Japan

^c Department of Neurology, Nagoya City Rehabilitation and Sports Center, Nagoya 467-8622, Japan

^d Department of Neurology, Tosei General Hospital, Seto 489-8642, Japan

^e Department of Diagnostic Medicine, Graduate School of Medical Sciences, Kumamoto University, Kumamoto 860-8556, Japan

^f Department of Neurology, Graduate School of Medical Sciences, Kumamoto University, Kumamoto 860-8556, Japan

Received 18 March 2005; received in revised form 6 June 2005; accepted 6 July 2005

Available online 18 August 2005

Abstract

Cerebral autosomal dominant arteriopathy with subcortical infarcts and leukoencephalopathy (CADASIL) is an inherited disease leading to strokes and vascular dementia. The average age of onset for stroke is 45 years with a range of about 30 to 70 years. We describe a Japanese CADASIL family showing S180C in the exon 4 of *NOTCH3*, presenting an anticipation of the onset age for stroke. MRI demonstrated a similar extent of white matter involvement in younger and older individuals, supporting the presence of anticipation. In addition, hallucinations in 71% of affected patients, and delusions in 57% were also described. Our findings in this family suggest that a specific *NOTCH3* mutation was related to unique clinical features, although such correlations have seldom been encountered in CADASIL.

© 2005 Elsevier B.V. All rights reserved.

Keywords: CADASIL; Anticipation; Hallucination; *NOTCH3*; S180C; Vascular dementia

1. Introduction

Cerebral autosomal dominant arteriopathy with subcortical infarcts and leukoencephalopathy (CADASIL) is an inherited vasculopathy resulting in stroke and vascular dementia [1,2]. Although various mutations in the *NOTCH3* gene cause the disease, mutation sites related to specific clinical phenotypes have not been well recognized [3,4]. However, recent studies have shown that mutations such as C455R [5] and C174Y [6] are associated with an earlier onset of illness. We recently encountered a family presenting an anticipation of the onset age for stroke. Gene analysis showed an S180C mutation in *NOTCH3*, for which details of the clinical phenotype have not been described. To our knowl-

edge, this is the first report of a CADASIL family presenting with such a condition. In addition, a marked prevalence of hallucinations and delusions was also presented, which would be an unusual clinical feature in CADASIL. These clinical features seem to indicate the possibility of phenotype–genotype correlations in CADASIL.

2. Patients and methods

2.1. Clinical and radiological evaluation

No consanguineous marriages had occurred in the family. All living patients were examined by neurologists. Deceased individuals were reevaluated by reviewing their medical records, including CT and MRI [T1-weighted, T2-weighted, and fluid-attenuated inversion recovery (FLAIR) images].

* Corresponding author. Tel.: +81 52 744 2385; fax: +81 52 744 2384.

E-mail address: sobueg@med.nagoya-u.ac.jp (G. Sobue).

Scheltens' rating scale was used to rate hyperintensities in T2-weighted images of white matter lesions in the subcortical region of frontal, parietal, occipital, temporal, and periventricular areas, basal ganglia, insula and infratentorial regions as follows: 0 (absent), 1 (<3 mm; $n < 5$), 2 (<3 mm; $n > 5$), 3 (4 to 10 mm; $n < 5$), 4 (4 to 10 mm; $n > 5$), 5 (>10 mm; $n > 1$), or 6 (confluent) [5,7].

2.2. Mutation analysis

After informed consent was obtained, total genomic DNA was isolated from peripheral blood cells by using the PUREGEN DNA Isolation Kit (Gentra Systems, Minneapolis, MN). Exons 3 and 4 for the *NOTCH3* gene were amplified by PCR using primers as follows: exon 3, 5'-ATCTTTGTGTCTGGGGCCAT-3' and 5'-ACTGACCACACCCCGACTA-3'; and exon 4, 5'-TAGTCGGGGGTGTGGTCAGT-3' and 5'-CCTC-TACTCCTGAGTAG-3'. After a sequencing reaction with the amplified PCR products, a pair of primers, and the BigDye Terminator v1.1 cycle sequencing kit (Applied Biosystems, Foster City, CA), nucleotide sequences were determined by an automated DNA sequencer (model 310; Applied Biosystems).

2.3. Statistics

The Wilcoxon signed rank test was used for the analysis of anticipation of age at onset for stroke, which was defined as the age when an individual first presented symptoms of apparent ischemic attacks and symptoms lasting more than 24 h.

3. Results

3.1. Representative case

The proband was a 40-year-old man (Fig. 1: III-7) with a 17-year history of migraine with aura, emotional lability

evident as weeping, and two episodes of stroke. He showed dysarthria and right hemiparesis at age 23. Brain CT demonstrated multiple, small low-density lesions bilaterally in the subcortical cerebral white matter. After admission to a hospital for about a month, his symptom almost recovered. In the following year, he first suffered migraine headaches with aura. At age 38, numbness affected the right side of his body in the absence of common cardiovascular risk factors and of any identifiable vascular abnormalities in a cerebral angiogram. His grandmother, father, four uncles, and a cousin were also affected (Fig. 1). Neurologic examination revealed personality change, reports of hallucinations, mild dysarthria, pseudobulbar palsy, right hemiparesis, diminished superficial touch sensation, and increased deep tendon reflexes in all extremities. Hallucinations that first appeared at age 40 were visual, usually involving a human figure or sometimes a few animals such as cats and dogs. These suddenly appeared on the patient's right side, crossing the street. Figures were not clearly recognized, nor were their color perceived. When the patient shifted his gaze, the hallucinations disappeared. He experienced such hallucinations in the daytime with his eyes open, and was aware that they were unreal. He had no auditory hallucinations. No medication was used that might cause hallucinations, and EEG showed no epileptic discharge. The revised Wechsler Intelligence Scale (WAIS-R) showed intellectual impairment (VIQ, 78; PIQ, 83; TIQ, 77). No laboratory abnormalities for any known vascular risk factor, including blood glucose, protein C and S, antinuclear/anti-DNA/antiphospholipid antibodies, antithrombin III, or fibrinogen, were presented except for hypercholesterolemia (246 mg/dl, normal values <220). Lactic acid and pyruvic acid were normal. Fundoscopic findings, visual acuity, and visual fields were normal. Carotid ultrasonography and MR angiography revealed no apparent arteriosclerotic lesion. T2-weighted and FLAIR MRI demonstrated multiple hyperintense lesions in the subcortical cerebral white matter, basal ganglia, midbrain, and anterior temporal lobe. No infarction was found in the region of the posterior

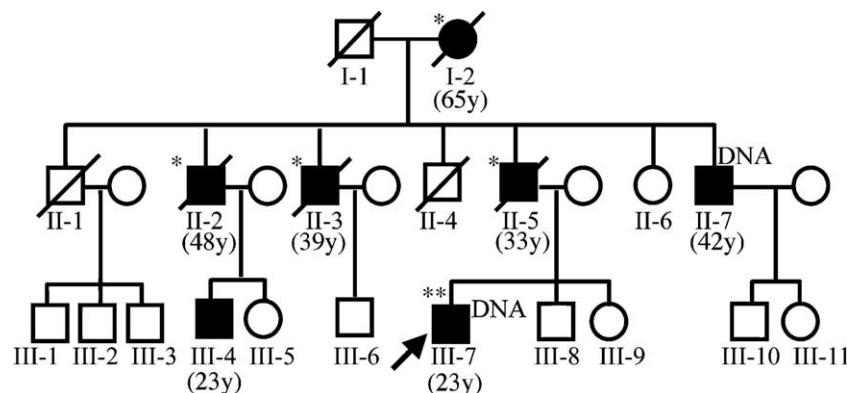


Fig. 1. Pedigree in our CADASIL family. Squares represent men, and circles women. Filled symbols represent individuals with CADASIL. Oblique lines indicate deceased family members. The proband is indicated by an arrow. Numbers in parentheses are age at onset for stroke. DNA, DNA examined; *, hallucinations and delusions present; **, hallucinations present.

cerebral artery, including the occipital cortex or posterior thalamus, except for periventricular lesions.

3.2. Clinical, radiologic, and genetic features of family members

Clinical features are summarized in Table 1. Four of seven patients in the family were deceased, and two were bedridden from recurrent strokes. The initial symptoms were apathy in one individual, bradykinesia with depression in one, and ischemic episode in five. Stroke occurred at the age of 65 years in the first generation, 33 to 48 years in the second, and 23 years in the third. Thus, onset occurred significantly earlier in patients of successive generations ($p=0.027$, Wilcoxon signed rank test). No patients had either hypertension or diabetes. Hypercholesterolemia that was evident in six of seven patients was below 260 mg/dl. Most affected members of this family manifested sensory and motor deficits, gait disturbance, increased tendon reflexes, cognitive impairment, personality changes and mood disorders. In addition, five of seven (71%) had hallucinations, and four (57%) experienced delusions during their disease. All hallucinations were visual, occurring mostly in the daytime. The content of hallucinations varied among patients, although humans and animals were most common. No one had taken any drugs which might induce hallucinations.

Although CT in patient II-3 and MRI in patients II-5, II-7, and III-4 demonstrated severe periventricular subcortical white matter lesions, no apparent infarction was observed in

the region of the posterior cerebral artery, including the occipital cortex except for a periventricular lesion of the posterior horn of lateral ventricle. Small lacunar infarction in the cerebral peduncle was observed only in patient II-7 at age 57, but no hallucination or delusion was observed in this patient. According to Scheltens' score, the extent of white matter lesions revealed by MRI was similar, indicating larger, more numerous lesions present at an earlier age in patients belonging to younger generations (Table 1).

Direct DNA sequencing of the exon 4 PCR product from the DNA of patients II-7 and III-7 showed both cytosine and guanine at the second base of codon 180 of the *NOTCH3* gene. Thus, the patients were heterozygous, with both a normal TCC (serine) and a variant TGC (cysteine) codon corresponding to amino acid position 180 of *NOTCH3*.

Brain autopsy was performed in patients I-1 and II-2. Diffuse myelin pallor and numerous infarcts were observed mainly in the cerebral white matter and basal ganglia with the preservation of U-fiber. Atherosclerosis was generally mild, and occlusion was rarely observed. No pathological change of neuronal degeneration in the substantia nigra nor the presence of Lewy bodies in the substantia nigra, locus ceruleus and cerebral cortex was found. There were also no plaques and tangle observed.

4. Discussion

To our knowledge, this is the first description of clinical and radiologic findings of patients with CADASIL asso-

Table 1
Clinical and MRI features of affected CADASIL family members

Patient	I-2	II-2	II-3	II-5	II-7	III-4	III-7
Gender	F	M	M	M	M	M	M
Onset of stroke (years)	65	48	39	33	42	23	23
Onset of psychosis (years)	67	45	43	42	35	NA	24
Disease duration (years)	7	5	21	15	22	25	17
Hypercholesterolemia	—	+	+	+	+	+	+
Migraine	—	—	—	—	—	—	+
Initial symptom	Left hemiparesis	Depression	Left hemiparesis	Left hemiparesis	Bradykinesia	Gait disturbance	Right hemiparesis
Psychiatric features							
Depressive state	+	+	+	+	+	+	+
Affective incontinence	+	+	+	+	+	+	+
Change of personality	+	+	+	+	+	+	+
Hallucinations	+	+	+	+	—	—	+
Delusions	+	+	+	+	—	—	—
Status	Deceased	Deceased	Deceased	Deceased	Bedridden	Bedridden	Difficulties at work
MRI features	NA	NA	NA				
Age at examination (years)				48	39	31	40
Scheltens' scores							
PWM				6	6	6	5
SWM				24	24	24	24
BG				10	5	9	4
IT				1	1	1	4
In				6	5	6	6

NA, not available; +, present; —, absent; PWM, periventricular white matter; SWM, subcortical white matter; BG, basal ganglia; IT, infratentorial structures; In, insula. SWM, total of individual Scheltens' scores from frontal, parietal, occipital, and temporal lobes. BG, total of individual scores from caudate, putamen, globus pallidus, thalamus, and capsules. IT, total of individual scores from brainstem and cerebellum.

ciated with a *NOTCH3* S180C mutation in the literature. The present family exhibited characteristic features in several respects. First, the onset age for stroke occurred earlier in patients of successive generations. Previous studies reported that the mean onset age for stroke is about 45 years with a range of about 30 to 70 years in CADASIL [3,8,9]. An association with transient ischemic attacks and a history of smoking at the time of the stroke episode has been reported in certain patients with CADASIL, particularly in early-onset cases [4]. Such relationships were not found in the present family. Arboleda-Velasquez et al. [5] reported that CADASIL patients with a C455R mutation in *NOTCH3* showed a significantly earlier onset of illness (median age, 31 years) than that seen with other mutations. Furthermore, patients with the C174Y mutation showed a phenotype–genotype correlation with an earlier age of onset [6]. However, no anticipation was seen concerning age of onset. Van dem Boom et al. [10] demonstrated that the spectrum of imaging abnormalities of hyperintensity of lacunar infarcts revealed in a T2-weighted MRI increases with age in CADASIL patients. However, younger patients in the most recent generation of this family showed severe white matter involvement, similar to findings in older patients of prior generations. This finding would also support the presence of anticipation. Anticipation has been reported mostly in polyglutamine disease with an instability of CAG repeat expansion, and has also been documented in association with point mutations in several neurodegenerative diseases such as familial amyloid polyneuropathy, Creutzfeldt–Jakob disease, and familial amyotrophic lateral sclerosis, although the mechanisms underlying such anticipation remain unknown [11]. Indeed, it will be virtually impossible to confirm that patients who were reported to be affected in their 50s or 60s were free of migraine, stroke-like episodes or psychiatric symptoms during younger ages since four cases were already deceased. Thus, the presence of anticipation of age onset must be discussed with caution. In addition, the number of patients investigated in the study is limited since we did not investigate the *NOTCH3* S180C mutation of the siblings for preclinical diagnosis because of ethical reason. Further studies are needed to clarify whether the S180C mutation causes anticipation, or whether different modulating genetic/environmental factors might be involved.

The second characteristic feature in this family was the presentation of hallucinations and delusion. About 15% of the CADASIL population has been reported to demonstrate psychiatric disturbances such as depression or mood change as initial symptoms [12,13]. Almost one fourth of the CADASIL patients present such symptoms in their disease course, but the prevalence of hallucinations and delusions is extremely low [8]. Although hallucinations are generally related to cortical lesions [14], such lesions are rare in patients with CADASIL [15]. There are several explanations for hallucination in our patients with CADASIL. First, peduncular hallucinosis [14,16] is related with

hypoperfusion or infarction in the mesencephalon which can occur in CADASIL. In this series, no family member who presented hallucinations had obvious ischemic lesion in the midbrain except for patient III-7. However, the existence of hypoperfusion in the mesencephalon could not be denied since no SPECT had been studied during the hallucinations. In general, peduncular hallucinosis is characterized by vivid, nonstereotypical-colored visual images of people and animals of brief duration occurring at dusk [16], while hallucinations in our patients, which were not vivid images appearing in daytime, were not related to peduncular hallucinosis. Second, ocular involvement may relate to hallucinations (Charles Bonnet syndrome) [14] since retinal lesions of the vascular origin [17] and retinal dysfunction [18] have been described in CADASIL. Charles Bonnet syndrome affects people with sight difficulties, usually only people who have lost their sight later in life. But patient III-7 had normal retina. In addition, to our knowledge, no CADASIL patient presenting Charles Bonnet syndrome had been reported. Third, there might be concomitant diseases. Hallucination and delusion have been also reported in mitochondrial myopathy, encephalopathy, lactic acidosis and stroke-like episodes (MELAS), in which hypoperfusion in occipital cortex and thalamus or delirium due to stroke-like episode is considered to be the cause of the symptom [19]. However, our family member had no characteristic features of MELAS represented by short stature, deafness, and glucose intolerance, and there was also no maternal inheritance in the third generation. Patients with Parkinson's disease and Alzheimer's disease also had high prevalences of visual hallucinations. Especially in Alzheimer's disease, they often presented with other psychotic symptoms such as auditory hallucinations and delusions [20]. Pathologic findings in I-2 and II-2 were different from those in Parkinson's disease and Alzheimer's disease. Fourth, periventricular white matter change in the temporal horn is one of the other possible causes of the psychiatric symptoms [21], or CADASIL patients with a vascular risk factors are reported to show symptoms related to cortical involvement [22].

Furthermore, no family member was treated with hallucinogenic drugs [14]. On the other hand, Lagas and Juvonen reported a patient with an R133C mutation in *NOTCH3* presenting psychiatric symptoms similar to those of schizophrenia including auditory hallucinations [23]. Further studies will be needed to clarify whether *NOTCH3* S180C is associated with the hallucinations and delusions observed in this family.

Third, the occurrence of hypercholesterolemia was high (86%) compared with that observed in a CADASIL population (20%) [9,24]. Although hypercholesterolemia is generally closely related with macroangiopathy, MRA and ultrasonic echo in patient III-7 showed no atherosclerotic changes in the main arteries. A recent study reported that hypercholesterolemia had no association with either the MRI lesion volume or stroke in CADASIL [4]. Thus

hypercholesterolemia was an unlikely cause of stroke in this series.

In conclusion, we found that a Japanese CADASIL family showing S180C in *NOTCH3* showed an anticipation of the onset age for stroke and high rates of hallucination and hypercholesterolemia. To our knowledge, mutations associated with anticipation have not been reported in CADASIL to date. Although specific phenotype–genotype correlations have been considered rare in CADASIL, the unique clinical features observed in our patients suggest the possibility of certain phenotypes being associated with specific *NOTCH3* mutations.

References

- [1] Tournier-Lasserre E, Joutel A, Melki J, Weissenbach J, Lathrop GM, Chabriat H, et al. Cerebral autosomal dominant arteriopathy with subcortical infarcts and leukoencephalopathy maps to chromosome 19q12. *Nat Genet* 1993;3:256–9.
- [2] Chabriat H, Vahedi K, Iba-Zizen MT, Joutel A, Nibbio A, Nagy TG, et al. Clinical spectrum of CADASIL: a study of 7 families. Cerebral autosomal dominant arteriopathy with subcortical infarcts and leukoencephalopathy. *Lancet* 1995;346:934–9.
- [3] Dichgans M. Cerebral autosomal dominant arteriopathy with subcortical infarcts and leukoencephalopathy: phenotypic and mutational spectrum. *J Neurol Sci* 2002;203–204:77–80.
- [4] Singhal S, Bevan S, Barrick T, Rich P, Markus HS. The influence of genetic and cardiovascular risk factors on the CADASIL phenotype. *Brain* 2004;127:2031–8.
- [5] Arboleda-Velasquez JF, Lopera F, Lopez E, Frosch MP, Sepulveda-Falla D, Gutierrez JE, et al. C455R notch3 mutation in a Colombian CADASIL kindred with early onset of stroke. *Neurology* 2002;59:277–9.
- [6] Opherk C, Peters N, Herzog J, Luedtke R, Dichgans M. Long-term prognosis and causes of death in CADASIL: a retrospective study in 411 patients. *Brain* 2004;127:2533–9.
- [7] Scheltens P, Barkhof F, Leys D, Pruvo JP, Nauta JJ, Vermersch P, et al. A semiquantitative rating scale for the assessment of signal hyperintensities on magnetic resonance imaging. *J Neurol Sci* 1993;114:7–12.
- [8] Dichgans M, Mayer M, Uttner I, Bruning R, Muller-Hocker J, Rungger G, et al. The phenotypic spectrum of CADASIL: clinical findings in 102 cases. *Ann Neurol* 1998;44:731–9.
- [9] Davous P. CADASIL: a review with proposed diagnostic criteria. *Eur J Neurol* 1998;5:219–33.
- [10] van den Boom R, Lesnik Oberstein SA, Ferrari MD, Haan J, van Buchem MA. Cerebral autosomal dominant arteriopathy with subcortical infarcts and leukoencephalopathy: MR imaging findings at different ages—3rd–6th decades. *Radiology* 2003;229:683–90.
- [11] Iwai K, Yamamoto M, Yoshihara T, Sobue G. Anticipation in familial amyotrophic lateral sclerosis with SOD1-G93S mutation. *J Neurol Neurosurg Psychiatry* 2002;72:819–20.
- [12] Leyhe T, Wiendl H, Buchkremer G, Wormstall H. CADASIL: underdiagnosed in psychiatric patients? *Acta Psychiatr Scand* 2005;111:392–6.
- [13] Desmond DW, Moroney JT, Lynch T, Chan S, Chin SS, Mohr JP. The natural history of CADASIL: a pooled analysis of previously published cases. *Stroke* 1999;30:1230–3.
- [14] Manford M, Andermann F. Complex visual hallucinations. Clinical and neurobiological insights. *Brain* 1998;121:1819–40.
- [15] Chabriat H, Levy C, Taillia H, Iba-Zizen MT, Vahedi K, Joutel A, et al. Patterns of MRI lesions in CADASIL. *Neurology* 1998;51:452–7.
- [16] Lhermitte J. Syndrome de la calotte du pedoncle cerebral: les troubles psychosensoriels dans les lesions du mesencephale. *Rev Neurol* 1922;38:1359–63.
- [17] Haritoglou C, Hoops JP, Stefani FH, Mehraein P, Kampik A, Dichgans M. Histopathological abnormalities in ocular blood vessels of CADASIL patients. *Am J Ophthalmol* 2004;138:302–5.
- [18] Parisi V, Pierelli F, Malandrini A, Carrera P, Olzi D, Gregori D, et al. Visual electrophysiological responses in subjects with cerebral autosomal dominant arteriopathy with subcortical infarcts and leukoencephalopathy (CADASIL). *Clin Neurophysiol* 2000;111:1582–8.
- [19] Narita H, Odawara T, Matsumoto T, Kimura S, Yamada T, Iseki E, et al. A case with late-onset MELAS with hallucination and delusion. *No To Shinkei* 2004;56:345–9 [Japanese].
- [20] Holroyd S, Currie L, Wooten GF. Prospective study of hallucinations and delusions in Parkinson's disease. *J Neurol Neurosurg Psychiatry* 2001;70:734–8.
- [21] Feinstein A, du Boulay G, Ron MA. Psychotic illness in multiple sclerosis. A clinical and magnetic resonance imaging study. *Br J Psychiatry* 1992;161:680–5.
- [22] Pantoni L, Sarti C, Pescini F, Bianchi S, Bartolini L, Nencini P, et al. Thrombophilic risk factors and unusual clinical features in three Italian CADASIL patients. *Eur J Neurol* 2004;11:782–7.
- [23] Lagas PA, Juvonen V. Schizophrenia in a patient with cerebral autosomally dominant arteriopathy with subcortical infarcts and leukoencephalopathy (CADASIL disease). *Nord J Psychiatry* 2001;55:41–2.
- [24] Uchino M, Hirano T, Uyama E, Hashimoto Y. Cerebral autosomal dominant arteriopathy with subcortical infarcts and leukoencephalopathy (CADASIL) and CADASIL-like disorders in Japan. *Ann N Y Acad Sci* 2002;977:273–8.