

Case report

Prenatal stroke in a neonate heterozygous for factor V Leiden mutation

Alfonso Verdu^{a,*}, María R. Cazorla^b, Juan C. Moreno^c, Luis F. Casado^d

^aSection of Pediatric Neurology, Hospital General Universitario Gregorio Marañón, Doctor Castelo 49, 28009 Madrid, Spain

^bNeuropediatric Unit, Hospital Virgen de la Salud, Toledo, Spain

^cService of Obstetrics and Gynaecology, Hospital Virgen de la Salud, Toledo, Spain

^dService of Hematology, Hospital Virgen de la Salud, Toledo, Spain

Received 23 February 2004; received in revised form 27 October 2004; accepted 27 October 2004

Abstract

The authors report an infant with congenital hemiplegia associated to heterozygosity for factor V Leiden. Prenatal stroke in the left cerebral hemisphere was diagnosed by ultrasonography at the 28th week of pregnancy, and followed up until birth. Although neonatal neurologic examination was normal, a moderate right hemiparesis developed along the 1st months of life. Coagulation studies performed in the neonatal period and at the age of 18 months revealed activated protein C resistance due to factor V Leiden mutation (R506Q). There are some previous reports of stroke associated to this mutation in near or at term neonates, but to our knowledge this is the stroke detected at the most early stage of fetal development.

© 2004 Elsevier B.V. All rights reserved.

Keywords: Stroke; Fetal; Factor V Leiden; Thrombophilia; Congenital hemiplegia

1. Introduction

The widespread use of intrauterine ultrasonography and other neuroimaging techniques has led to a better recognition and diagnosis of perinatal stroke [1–3]. This is defined as occurring between 28 weeks gestation and 7 days of age. Its incidence is considered to be 4/1000 live births [4], although this figure is probably underestimated because of variations in the presentation and difficulties in diagnosis [4,5]. Despite the presumed importance of perinatal stroke as the cause of static cerebral disease of childhood [4], the vascular derangements that lead to ‘in utero’ stroke remain unknown in most cases. In the past decade there has been increasing evidence that acquired and genetic prothrombotic risk factors play a role in perinatal stroke [6–12]. Furthermore, a recent study from the Canadian Stroke Registry indicated that a number of thrombophilias posed a significant threat to the developing brain, including antithrombin III, Protein C and Protein S deficiencies, hyperhomocystinaemia, and factor V Leiden (FV-L) and

prothrombin 20210A mutations [13]. In this report we describe the occurrence of stroke in a fetus at the 28th week. After birth, the neonate and his mother were shown to have activated protein C resistance due to heterozygosity for FV-L. This case adds to several previous reports of the association of FV-L and stroke in a developing brain.

2. Case report

A 33-year-old, healthy secundigravida with no relevant personal or family history underwent an ultrasonographic study at the 25th week of an otherwise uneventful pregnancy. The study showed normal brain echodensity. An ultrasonography was performed again, at the 28th week, because of mild but persistent abdominal discomfort during the two previous days. It showed a peri-intraventricular hemorrhage on the left side (Figs. 1 and 2), suggestive of hemorrhagic infarction. This image evolved to a porencephalic cyst in the following weeks (Fig. 3) and remained stable until birth. No abnormalities were found in other parts of the body. The abdominal discomfort subsided spontaneously a few days later. Blood studies in

* Corresponding author. Fax: +34 1 5290107.

E-mail address: averdu@sescam.jccm.es (A. Verdu).

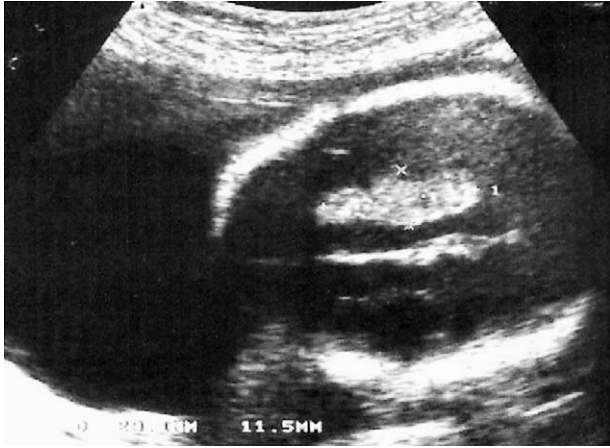

Fig. 1. Cranial ultrasonography at the 28th week of gestation (axial section through the mid-portion of the cerebral hemispheres) the left lateral ventricle is larger than the right one, with an irregular echogenic image of 29×11 mm, compatible with a peri-intraventricular hemorrhage.

the mother, including serological screening for TORCH, were normal. Fetal growth proceeded at a normal rate and the pregnancy continued uneventful until term. A male infant was born at 39 weeks gestation by uncomplicated vaginal delivery. The neonate was in good condition and had no problems following delivery. Apgar scores at 1 and 5 min were, respectively, 9 and 10. The pathologic analysis of the placenta did not reveal abnormalities. Neurological examination and behaviour in the 1st day of life were appropriate for gestational age. The neonate did not show abnormal neurological signs or symptoms during the 1st week of life.

Serum electrolytes, blood glucose, urea, nitrogen, creatinine, liver function tests, ammonia, lactate, pyruvate, aminoacid profile, and TORCH screen were normal. The urinary screening for toxic substances, aminoacids and organic acids did not disclosed abnormalities. On follow-up, a mild right hemiparesis began to appear by the 3rd month,

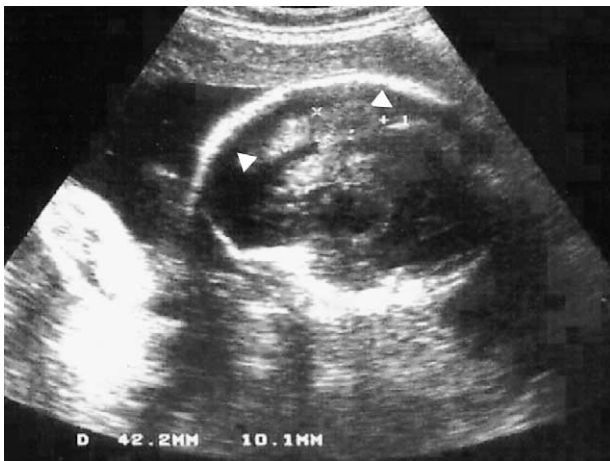

Fig. 2. Cranial ultrasonography performed 3 days later (parasagittal section through the left cerebral hemisphere): periventricular echodensity of 42×10 mm (arrowheads), suggestive of hemorrhagic infarction.

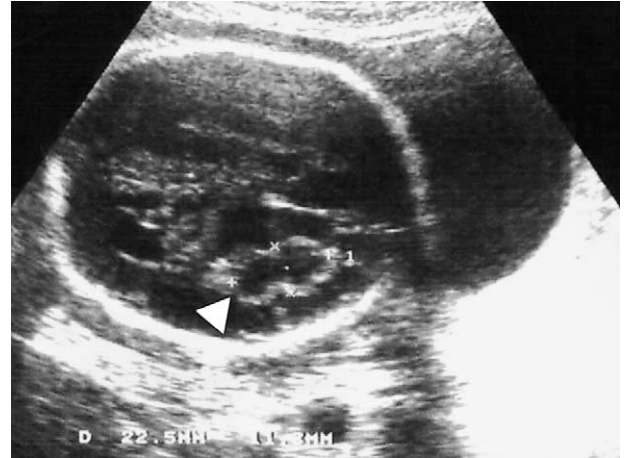

Fig. 3. Cranial ultrasonography 4 weeks after the initial hemorrhage (axial section through the cerebral hemispheres): the previous image has evolved into a cystic cavity in the left frontoparietal area (arrowhead).

and was well established at 6 months of age. At 2 years of age, despite a moderate right hemiparesis, manipulative skills with the left hand were normal. Language development, and social behaviour were adequate for his age. A magnetic resonance imaging scan of the brain showed cystic enlargement of the left lateral ventricle and loss of subcortical white matter (Fig. 4).

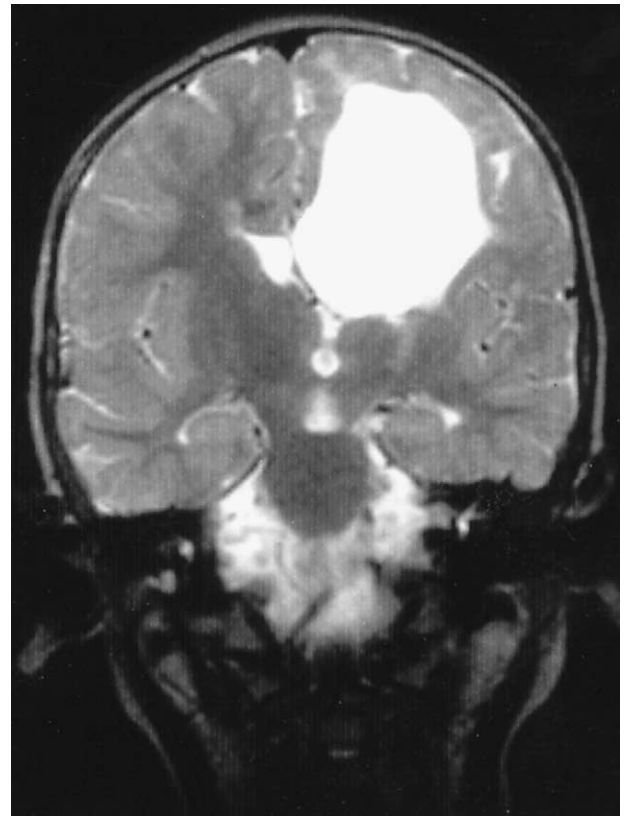


Fig. 4. MRI (coronal section, T2 weighted) at 2 years of age. Porencephalic cystic dilatation of the left lateral ventricle with loss of subcortical white matter.

Coagulation studies were performed in the neonatal period and repeated at 18 months of age with similar results. Prothrombin and activated thromboplastin times were normal. Anticardiolipin antibodies (IgM, IgG) were not detected in blood; activities of protein C, protein S and antithrombin III were within normal limits. The activated protein C resistance ratio (Coatest APC Resistance, Chromogenix, Mölndahl, Sweden) was 1.5 (normal >2.3). To investigate the presence of FV-L, a 267 bp fragment of the factor V gene containing base pair 1691 was amplified using PCR as described elsewhere [14]. The patient was found to be heterozygous for FV-L (FV R506Q). A search for the prothrombin G20210A gene mutation, was negative. Although there was no family history of stroke or venous thrombosis, coagulation studies determined the mother and the brother of the patient as heterozygous for FV-L.

3. Discussion

Although strokes produced before birth were described as early as the second half of the 19th century, they have been for long considered as exceedingly rare. At present, the precise incidence of perinatal stroke remains unknown. Based on the prevalence of neonatal seizures, it has been estimated in 4/1000 live births [1,2]. However, the real incidence may probably be higher because many children with presumed pre or perinatal strokes usually had a normal neonatal neurological history and showed clinical signs later [13]. Furthermore, the history of pregnancy often gives no clues to determine the moment at which the brain damage occurs [15]. With the widespread use of intrauterine ultrasonography, there has been an increasing number of reported cases [1–4,16–18]. Our case exemplifies these points. The stroke occurred at the 28th week of gestation, when a ‘spontaneous’ periventricular hemorrhage, most likely due to subcortical infarction, was detected by chance. The pregnancy proceeded uneventful and the neonate was born normally without neurological signs or symptoms in the neonatal period. The hemiparesis developed gradually over the 1st months of age, as it happens in many children with congenital hemiplegia of presumed prenatal origin.

The etiology of most prenatal strokes is unknown. Some pathological studies attributed them to thrombosis or to embolism of placental origin [1,19,20]. There also seems to be some recognized causes in a small number of fetal strokes, like twin to twin embolization [15,21], maternal cocaine abuse during pregnancy [22] or parvovirus infection [23]. However, the pathogenesis of stroke in the majority of cases has been mostly speculative. In the last decade, along with a better knowledge of thrombophilias, there have been increasing evidences of their association with perinatal strokes. There are some case reports of thrombophilic conditions that may have contributed to perinatal strokes of obscure etiology [6–8,24]. But, most significantly, some

population-based and large series studies have shown that a number of thrombophilias pose significant threats to the developing brain [4,10,13,11,12,25]. The described thrombophilic conditions associated with perinatal stroke include antithrombin III, protein S and protein C deficiencies, hyperhomocysteinemia, anticardiolipin antibodies, and prothrombin 20210 A and FV-L mutations. FV-L seems to be the most frequently identified, both in case reports as well as in large series. This may be a reflection of its high prevalence in the general population [24]. In the case reported all known risk factors for fetal stroke were reasonably excluded, and FV-L mutation was shown in the neonate as well as in the mother. At difference with other reports, the stroke occurred at an earlier stage of fetal development [6,8,11]. This suggests that the presumed deleterious effect of this thrombophilia may occur even in the second trimester of pregnancy. However, the precise role of FV-L mutation and other prothrombotic conditions, as well as the contribution of additional environmental factors (i.e. asphyxia, septicemia, birth trauma), awaits future studies. To gain further insight into the pathophysiology of perinatal stroke it seemed reasonable the widespread screen of the most prevalent thrombophilias, like FV-L and prothrombin gene 20210 A in pregnant women.

References

- [1] Ong BY, Ellison PH, Browling C. Intrauterine stroke in the neonate. *Arch Neurol* 1983;40:55–6.
- [2] Amato M, Hüppi P, Herschkowitz N, Huber P. Prenatal stroke suggested by intrauterine ultrasound and confirmed by magnetic resonance imaging. *Neuropediatrics* 1991;22:100–2.
- [3] Canapicchi R, Cioni G, Strigini F, Abbruzzese A, Bartalena L, Lencioni G. Prenatal diagnosis of periventricular hemorrhage by fetal brain magnetic resonance imaging. *Child's Nervous System* 1998;14: 689–92.
- [4] Ferriero DM. Toward the recognition and treatment of perinatal stroke. *Curr Opin Pediatr* 2001;13:497–8.
- [5] Lynch JK, Nelson KB. Epidemiology of perinatal stroke. *Curr Opin Pediatr* 2001;13:499–505.
- [6] Thorarensen O, Ryan S, Hunter J, Younkin DP. Factor V Leiden mutation: an unrecognized cause of hemiplegic cerebral palsy, neonatal stroke, and placental thrombosis. *Ann Neurol* 1997;42: 372–5.
- [7] Silver RK, MacGregor SN, Pasternak JF, Neely SE. Fetal stroke associated with elevated maternal anticardiolipin antibodies. *Obstet Gynecol* 1992;80:497–9.
- [8] Varelas PN, Sleight BJ, Rinder HM, Sze G, Ment LR. Stroke in a neonate heterozygous for factor V Leiden. *Pediatr Neurol* 1998;18: 262–4.
- [9] Kenet G, Sadetzki S, Murad H, Martinowitz U, Rosenberg N, Gitel S, et al. Factor V Leiden and antiphospholipid antibodies are significant risk factors for ischemic stroke in children. *Stroke* 2000;31:1283–8.
- [10] Gunther G, Junker R, Strater R, Schobess R, Kurnik K, Heller C, et al. Symptomatic ischemic stroke in full-term neonates: role of acquired and genetic prothrombotic risk factors. *Stroke* 2000;31:2437–41.
- [11] Mercuri E, Cowan F, Gupte G, Manning R, Laffan M, Rutherford M, et al. Prothrombotic disorders and abnormal neurodevelopmental outcome in infants with neonatal cerebral infarction. *Pediatrics* 2001; 107:1400–4.

- [12] Hogeveen M, Blom HJ, Van Amerongen M, Boogmans B, Van Beynum IM, Van de Bor M. Hyperhomocystinemia as risk factor for ischemic and hemorrhagic stroke in newborn infants. *J Pediatr* 2002; 141:429–31.
- [13] Golomb MR, MacGregor DL, Domi T, Armstrong DC, McCrindle BW, Mayank S, et al. Presumed pre- or perinatal arterial ischemic stroke: risk factors and outcomes. *Ann Neurol* 2001;50: 163–8.
- [14] Bertina RM, Koeleman BP, Koster T, Rosendaal FR, Dirven RJ, de Ronde H, et al. Mutation in blood coagulation factor V associated with resistance to activated protein C. *Nature* 1994;369:64–7.
- [15] Manterola A, Towbin A, Yakovlev PI. Cerebral infarction in the human fetus near term. *J Neuropathol Exp Neurol* 1966;25:479–88.
- [16] Scher MS. Cerebrovascular lesions of fetal onset: antepartum causes of cerebral palsy. *Ann Neurol* 1990;28:451.
- [17] Kirkinen P, Partanen K, Ryyänen M, Ordén MR. Fetal intracranial hemorrhage. Imaging by ultrasound and magnetic resonance imaging. *J Reprod Med* 1997;42:467–72.
- [18] Sibony O, Stempfle N, Luton D, Oury JF, Blot PH. In utero fetal cerebral intraparenchymal ischemia diagnosed by nuclear magnetic resonance. *Dev Med Child Neurol* 1998;40:122–3.
- [19] Cocker J, George SW, Yates PO. Perinatal occlusion of the middle cerebral artery. *Dev Med Child Neurol* 1965;7:235–43.
- [20] Kraus FT, Acheen VI. Fetal thrombotic vasculopathy in the placenta: cerebral thrombi and infarcts, coagulopathies, and cerebral palsy. *Hum Pathol* 1999;30:759–69.
- [21] Fusi L, McParland P, Fisk N, Nicolini U, Wigglesworth J. Acute twin–twin transfusion: a possible mechanism for brain-damaged survivors after intrauterine death of a monochorionic twin. *Obstet Gynecol* 1991;78:517–20.
- [22] Heier LA, Carpanzano CR, Mast J, Brill PW, Winchester P, Deck MD. Maternal cocaine abuse: the spectrum of radiologic abnormalities in the neonatal CNS. *Am J Neuroradiol* 1991;12:951–6.
- [23] Craze JL, Salisbury AJ, Pike MG. Prenatal stroke associated with maternal parvovirus infection. *Dev Med Child Neurol* 1996;38:84–5.
- [24] Chow G, Mellor D. Neonatal cerebral ischaemia with elevated maternal and infant anticardiolipin antibodies. *Dev Med Child Neurol* 2000;42:412–3.
- [25] Vern TZ, Alles AJ, Kowal-Vern A, Longtine J, Roberts DJ. Frequency of factor V Leiden and prothrombin G20210A in placentas and their relationship with placental lesions. *Hum Pathol* 2000;31:1036–43.