

5. Dini G, Hartmann O, Pinkerton R, et al. Autologous bone marrow transplantation in Ewing's sarcoma: An analysis of phase II studies from the European Bone Marrow Transplantation Group. *Proc Fourth Int Symp autologous Bone Marrow Transplant* 1988;39: 593–599.
6. Tanaka K, Matsunobu T, Sakamoto A, et al. High-dose chemotherapy and autologous peripheral blood stem-cell transfusion after conventional chemotherapy for patients with high-risk Ewing's tumors. *J Orthop Sci* 2002;7:477–482.
7. Burdach S, Jurgens H. High-dose chemotherapy (HDC) in the Ewing family of tumors (EFT). *Crit Rev Oncol Hematol* 2002; 41:169–189.
8. Jacobsen AB, Wist EA, Solheim OP. Treatment of Ewing's sarcoma with high-dose melphalan and autologous bone marrow rescue. *Monogr Ser Eur Organ Res Treat Cancer* 1984;14:157–160.
9. Herzig RH, Phillips GL, Lazarus HM, et al. Intensive chemotherapy and autologous bone marrow transplantation for the treatment of refractory malignancies. *Proc First Int Symp autologous Bone Marrow Transplant* 1985;1:197–202.
10. Burdach S, Jurgens H, Peters C, et al. Myeloablative radio-chemotherapy and hematopoietic stem cell rescue in poor prognosis Ewing's sarcoma. *J Clin Oncol* 1993;11:1482–1488.
11. Chan KW, Petropoulos D, Choroszy M, et al. High-dose sequential chemotherapy and autologous stem cell reinfusion in advanced pediatric solid tumors. *Bone Marrow Transplant* 1996;18:315–318.
12. Atra A, Whelan JS, Calvagna V, et al. High-dose busulfan/melphalan with autologous stem cell rescue in Ewing's sarcoma. *Bone Marrow Transplant* 1997;20:843–846.
13. Cornbleet MA, Corringham RET, Prentice HG, et al. Treatment of Ewing's sarcoma with high-dose melphalan and autologous bone marrow transplantation. *Cancer Treat Rep* 1981;65:241–244.
14. Kalambakas S, Moore T, Feig S. Megatherapy and stem cell transplantation for Ewing's family of tumors: A critical review of current literature. *Pediatr Transplant* 2004;8:83–88.
15. Grier H, Krailo M, Tarbell N, et al. Addition of ifosfamide and etoposide to standard chemotherapy for Ewing's sarcoma and primitive neuroectodermal tumor of bone. *NEJM* 2003;348:694–701.

Reversible Posterior Leukoencephalopathy Syndrome in Children Undergoing Induction Therapy for Acute Lymphoblastic Leukemia

Jennifer K. Norman, MD,¹ Julie T. Parke, MD,² Don A. Wilson, MD,³ and René Y. McNall-Knapp, MD^{1*}

We present three cases of children with acute neurologic changes while undergoing induction chemotherapy for acute lymphoblastic leukemia (ALL). These cases fall into the spectrum of reversible posterior leukoencephalopathy syndrome (RPLS), including abrupt alterations in mental status, headache, seizures, visual changes, hypertension, and characteristic findings on magnetic resonance

imaging. Although the underlying mechanism of RPLS is still under investigation, the appropriate treatment and management of the acute event is becoming clearer. Early treatment of hypertension, control of seizure activity, and withdrawal of inciting agents can lead to rapid reversal of symptoms and return to baseline functioning. *Pediatr Blood Cancer* 2007;49:198–203. © 2005 Wiley-Liss, Inc.

Key words: ALL; cortical blindness; induction; neurotoxicity; seizures

BACKGROUND

In 1996, Hinchey et al. described a constellation of acute but reversible clinical findings including headache, altered mental functioning, seizures, hypertension, and acute visual changes associated with abnormalities seen on magnetic resonance imaging of symmetric white matter lesions, usually in bilateral parietal and occipital lobes. They termed this constellation reversible posterior leukoencephalopathy syndrome (RPLS) [1]. Although initially thought to only affect the subcortical white matter, additional studies as well as improvement in radiological imaging modalities have revealed that the cortical gray matter may also be involved. This research prompted the suggestion for revision of the name to reversible occipitoparietal encephalopathy (ROPE) [2]. When this syndrome was described in the radiology literature, the name posterior reversible encephalopathy syndrome was also suggested [3].

There have been many reports of this phenomenon in the literature since its initial definition; however, the underlying pathophysiologic mechanism still remain unclear. Many predisposing factors have been proposed including hypertension, immuno-

suppression, chemotherapy agents, eclampsia, and renal dysfunction [4–10]. Scattered case studies have reported RPLS in children undergoing therapy for cancer, [8,10,11] although it is still not widely recognized as a potential complication of chemotherapy. Reports prior to description of the entity and more advanced imaging techniques also described cortical blindness in children receiving vincristine, cyclosporine, or other immunosuppressive agents [12–15]. In this report, we include three patients undergoing induction chemotherapy for newly diagnosed acute lymphoblastic

¹Department of Pediatrics, The University of Oklahoma Health Sciences Center Oklahoma City, Oklahoma; ²Department of Neurology, The University of Oklahoma Health Sciences Center Oklahoma City, Oklahoma; ³Department of Radiological Sciences, The University of Oklahoma Health Sciences Center Oklahoma City, Oklahoma

*Correspondence to: René Y. McNall-Knapp, Division of Pediatric Hematology/Oncology, 940 NE 13th Street, Room 3B3308, Oklahoma City, OK 73104. E-mail: Rene-McNall@ouhsc.edu

Received 10 June 2005; Accepted 26 July 2005

leukemia (ALL) who present with clinical and radiological findings of RPLS.

CASE PRESENTATIONS

Case 1

A 9-year-old male with T-cell ALL (mediastinal mass, initial WBC $16.9 \times 10^6/\text{dl}$, no CNS disease) started on induction therapy as per POG 9404 with intrathecal cytarabine, oral prednisone and intravenous vincristine, dezoxozane, doxorubicin, and methotrexate. He was readmitted to the hospital on induction day 17 with significant constipation and abdominal pain. On day 18 of induction he developed a severe headache and had episodes of dizziness and confusion. A CT of the head with and without contrast was performed and was normal. His level of consciousness continued waxing and waning over the next 24 hr with features of delirium and agitation. On day 19, he had a possible seizure episode lasting about 20 min in which he appeared dazed and was staring off into the far distance. He was unresponsive to voice, and had some eye twitching, but no extremity twitching. After recovering consciousness, he complained of blurred vision, which progressed to complete blindness over the course of a few hours. He was hypertensive most of the day with blood pressure ranging from 141/93–174/96. His mental status continued to decline, becoming responsive only to a sternal rub. MRI was done showing T2 signal abnormality, principally affecting the gray matter, involving the occipital and parietal lobes bilaterally without associated mass effect (see Fig. 1). The diffusion-weighted images (DWI) were normal except for T2 shine-through, indicating vasogenic edema and ruling out acute stroke. The apparent diffusion coefficient (ADC) map (not shown) showed the same regions to be hyperintense, consistent with vasogenic edema. Over the next several days, his vision gradually returned to normal and his mental status returned to baseline. He was given no further vincristine doses, but otherwise continued on planned chemotherapy after induction. Follow-up MRI scans 2 and 6 months after the episode showed resolution of T2 signal abnormalities, but with residual gliosis in the temporal, occipital, and right frontal regions, consistent with evolution of post-chemotherapy changes. Visual evoked potentials were measured 6 weeks after the episode and showed an increased latency of 121 msec (normal range 100–105 msec). Although he continued to have mild hand-eye coordination difficulty for several months after his event, he now has no remaining deficits and is functioning at his baseline.

Case 2

A 13-year-old male was diagnosed with pre-B ALL (initial WBC $1.3 \times 10^6/\text{dl}$, no CNS disease) after he presented to the Children's Hospital with a history of severe lower extremity pain and inability to bear weight. He was started on four-drug induction chemotherapy on POG 9900 with intrathecal methotrexate and systemic vincristine, prednisone, daunorubicin, and L-asparaginase. On induction day 6, prior to receiving any daunorubicin, he had a total of three generalized tonic clonic seizures lasting 1–6 min each, and all resolving spontaneously. His neurological exam after each seizure was remarkable only for dilated but fully reactive pupils and 3–4 beats of clonus at the ankles bilaterally. CT of the head was normal. He was loaded with fosphenytoin then continued on oral phenytoin

with no recurrence of the seizures. His blood pressure had become elevated on day 2 of induction, measuring 132/84–160/110, with the highest being just prior to the seizure activity. An MRI done 2 days after the seizure episodes showed areas of increased T2 signal of bilateral frontal lobes, bilateral parietal lobes, and the right cerebellar hemisphere, without concurrent abnormality in DWI (Fig. 2). This was interpreted to be consistent with vasogenic edema secondary to drug toxicity or vasculitis. MR angiography and venography was done at the same time, which showed no intracranial thrombus. Prior to discharge he was changed to oral levetiracetam with no further recurrence of seizure activity. His induction therapy was not altered and he was in complete remission on day 29 bone marrow aspiration. Repeat MRI done 8 months after the events shows complete resolution of the T2 changes (not shown).

Case 3

A 4-year-old female was diagnosed with pre-B ALL (initial WBC $51 \times 10^6/\text{dl}$, CNS negative) after presenting with fever, bilateral ankle pain with refusal to walk, and edema of her hands and feet. She also started on four-drug induction chemotherapy on protocol POG 9900 with intrathecal methotrexate and systemic vincristine, prednisone, daunorubicin, and L-asparaginase. On day 3, prior to any daunorubicin, she had an episode in which she became unresponsive with her eyes deviated downward, for approximately 45 min. During this time, there was no tonic clonic activity observed but EEG confirmed seizure activity with focus in the left temporal area. After 45 min she recovered completely and neurological examination was normal except a bilateral upgoing Babinski sign. A CT scan done just after the seizure was normal. MRI of the brain done approximately 3 hr after the incident showed patchy subcortical T2 abnormalities predominantly in the occipital and posterior parietal lobes bilaterally with diffusion-weighted imaging normal except for T2 shine-through (Fig. 3). The ADC map showed the same areas to be hyperintense (not shown). These findings were interpreted as vasogenic edema due to posterior reversible encephalopathy syndrome. MR angiography and venography done at the same time showed no evidence for intracranial thrombus. The patient was given a loading dose of fosphenytoin and continued on oral phenytoin after her discharge from the hospital. As an outpatient, she was also started on levetiracetam and the phenytoin was weaned. She had been noted to be hypertensive, starting day 1 of induction, with a range of 130/68–170/123. She was started on amlodipine on day 3. Follow up MRI done 2 months after the episode was normal. She is currently at her baseline mental status and has not had any recurrence of seizure activity.

DISCUSSION

In a year's timespan we had a high incidence of RPLS, with 3 of 18 children newly-diagnosed with ALL developing the clinical and imaging criteria. All of these patients have been continuously followed for persistent or recurrent symptoms and have had repeat imaging performed. One of our patients (patient 1) developed long-lasting clinical findings, with his prolonged visual evoked response, and imaging findings, with gliosis. The other patients, with much milder initial courses, had complete resolution of their symptoms and imaging abnormalities.

Many theories have been offered to explain the pathophysiology of RPLS. Hinchey et al. initially proposed that the syndrome

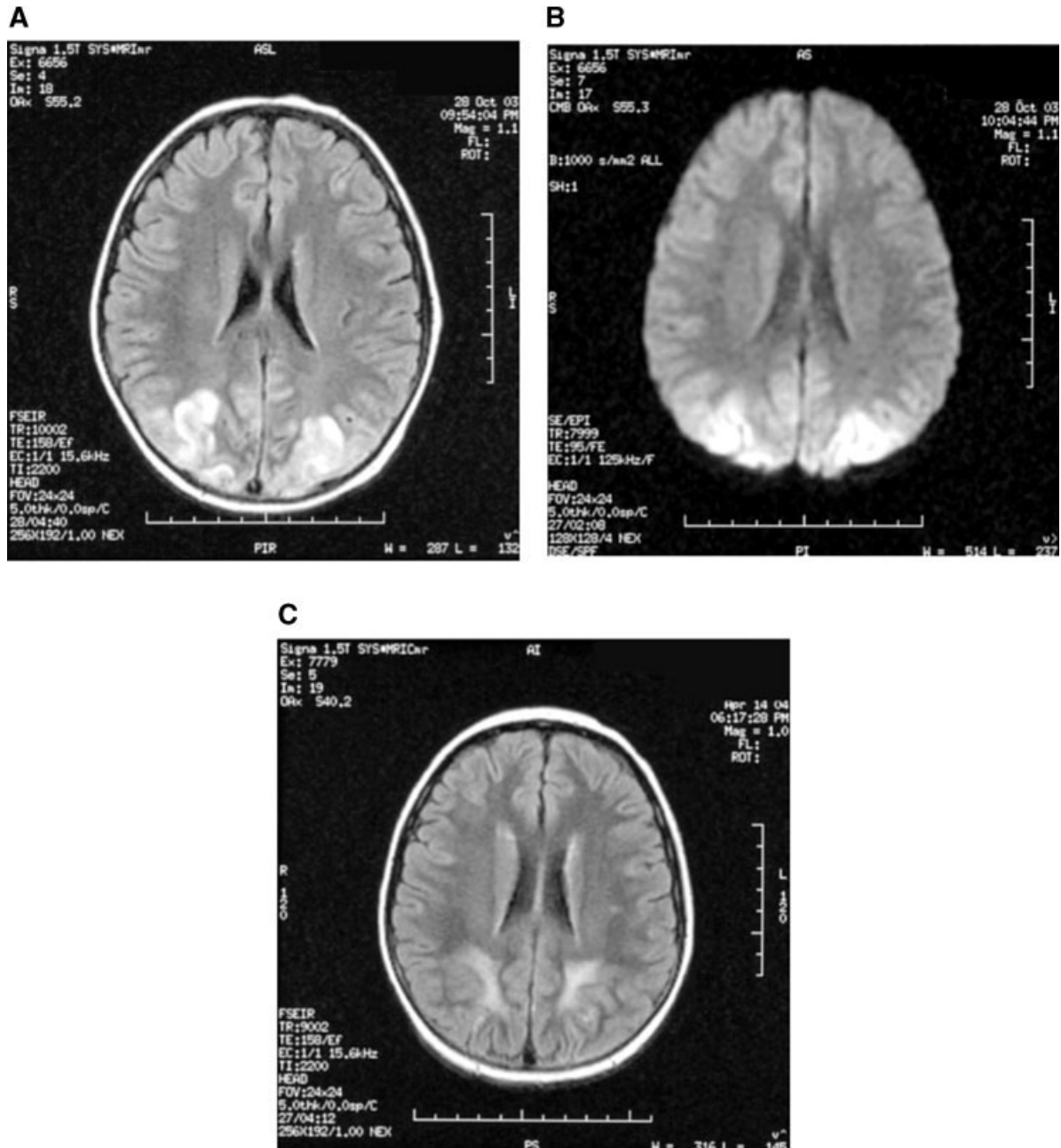


Fig. 1. (MRI images): **A:** Initial T2-weighted FLAIR image showing T2-signal abnormalities in bilateral parietal and occipital gray matter. **B:** Initial diffusion weighted image that has some T2 shine-through, but is otherwise normal. **C:** Follow up T2 weighted FLAIR image at 6 months showing gliosis in the temporal, parietal, and right frontal regions.

resulted from sudden elevations in systemic blood pressure exceeding the autoregulatory capability of the brain vasculature. This causes acute disruption of the blood-brain barrier leading to capillary leakage and subsequent vasogenic edema [1]. The selective involvement of structures perfused by the posterior circulation and the rapid reversibility of symptoms indicates a loss of autoregulation of the vertebrobasilar system, likely due to its relatively sparse sympathetic innervation [16]. Cerebral white matter is preferentially involved in RPLS, likely because it is composed of myelinated-fiber tracts in a cellular matrix of glial cells, arterioles, and capillaries that makes this region more

susceptible to vasogenic edema. The cortex is more tightly packed and organized than the white matter, and tends to resist accumulation of large amounts of vasogenic edema [1]. Although all three of our patients had documented hypertension during their hospitalization, there are many reports in the literature of patients who had only mildly elevated or normal blood pressure at the onset of symptoms [10,16,17]. However, all three received prednisone, which likely contributed to the hypertension as well. Therefore, hypertension appears to be a contributing but not required factor in the development of RPLS. Many drugs routinely used during childhood cancer chemotherapy have also been linked to RPLS,

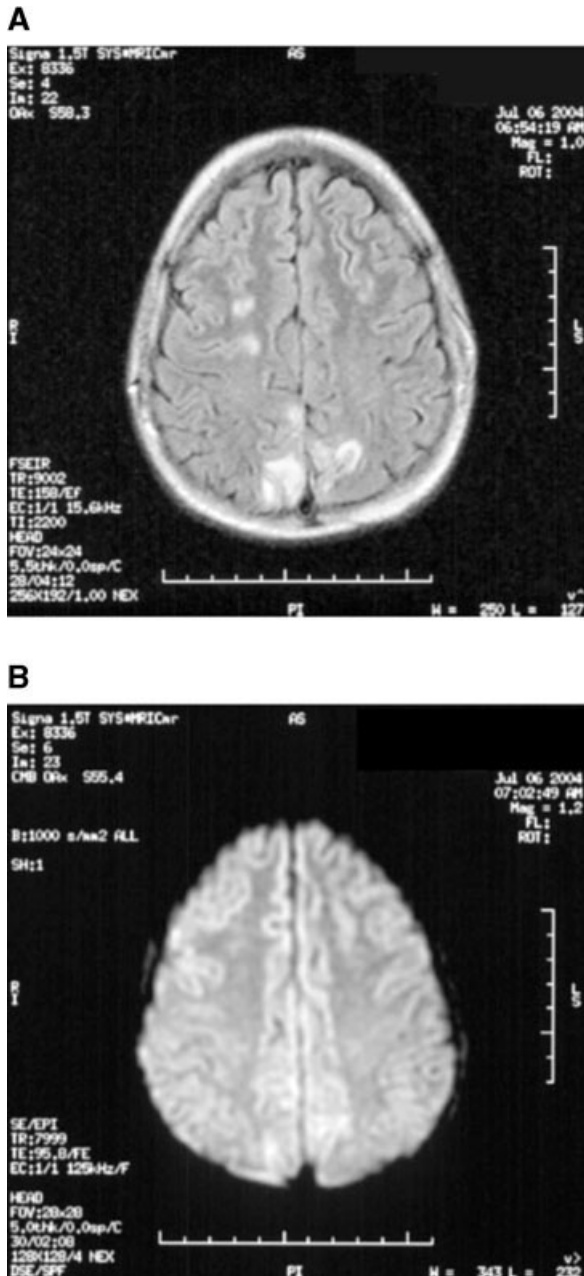


Fig. 2. (MRI images): **A:** Initial T2-weighted FLAIR image demonstrating T2 changes in bilateral frontal and parietal lobes and the right cerebellar hemisphere. **B:** Initial diffusion weighted image that is normal.

including vincristine, high dose methotrexate, cisplatin, cytarabine, gemcitabine, and cyclosporine. Of these suspected offending drugs, only vincristine and intrathecal methotrexate were given to all three of our patients prior to onset of their symptoms. These drugs may contribute to the development of RPLS by direct cytotoxic effect on the endothelial cells of blood vessels, exacerbation of hypertension, or by lowering the seizure threshold [1,16].

Another pathophysiologic mechanism has recently been proposed, involving a cortical spreading depression (CSD) phenomenon similar to that thought to cause migraine headaches. A study by

Sanchez-Carpintero, proposed that this might be the same mechanism causing symptoms of RPLS [10]. SPECT scans were performed on three children undergoing therapy for osteosarcoma who developed clinical signs of RPLS. The scans all showed hypoperfusion of the parieto-occipital regions of the brain, consistent with findings during complicated migraine. Although the CSD phenomenon is not completely understood, it is known that low brain magnesium strongly facilitates the development of CSD in vitro. Hypomagnesemia occurs frequently during cancer chemotherapy therefore it might serve as a trigger for RPLS. Although there have been several reported cases in the literature of low serum magnesium at the onset of RPLS, the serum magnesium levels on all of our patients was normal at the time of their events.

Characteristic findings of RPLS on MRI have been well described in the literature. The MRI findings include abnormal T2 weighted images involving predominantly the white matter of the posterior occipitoparietal regions of the brain bilaterally. Grey matter may also be included. These lesions are generally isointense on DWI performed at the same time, consistent with vasogenic edema [16]. As cytotoxic edema, seen in ischemic cerebral events, appears hyperintense on DWI, this series can successfully differentiate RPLS from early cerebral ischemia, playing a pivotal role in early treatment decisions. The ADC map will also appear hyperintense with vasogenic edema. Since the lesions are typically cortical and subcortical near the brain surface, mild cases may be difficult to detect on T2 images due to volume averaging with the adjacent bright cerebrospinal fluid (CSF). A recent study by Casey [3] showed that by using fluid-attenuated inversion recovery (FLAIR), images the lesions of RPLS become more visible due to the signal suppression of the adjacent CSF. This has allowed for milder cases of RPLS to be identified, allowing for initiation of proper treatment in a more timely fashion. Therefore, if RPLS is suspected, MRI series should be done, including T2, DWI, and FLAIR images for the most accurate diagnosis.

There is no clearly defined treatment recommendation for children who present with the signs and symptoms of the syndrome. Since hypertension appears to play an important role in the development of symptoms, routine monitoring of blood pressure as well as early and aggressive therapy for hypertension would likely aid in prevention of the onset of symptoms. Also when these children present with seizure activity, it is important to quickly control the seizures, usually requiring intravenous loading of phenobarbital or fosphenytoin. Due to the potential of these medications to interfere with ongoing chemotherapy, they should be changed as soon as possible to a non-enzyme inducing agent, such as levetiracetam. The most important decision for children with ongoing chemotherapy is whether or not to withhold the potential inciting agent in future rounds of treatment. In the first case presented, the decision was made to withhold further therapy with vincristine (as this seemed the most likely agent) due to his ongoing measurable deficits seen on visual evoked response measurements and gliosis seen on MRI. The second and third cases had manifestations of RPLS that rapidly resolved with the appropriate antiepileptic and antihypertensive medications so the decision was made to proceed with all chemotherapy as initially planned. It is important to note that none of the patients presented in our report had any further events resembling RPLS during their course of therapy.

Although not previously widely recognized as a complication of chemotherapy, a recent study by Antunes [4] showed that RPLS is the most common abnormality leading to seizures in children with

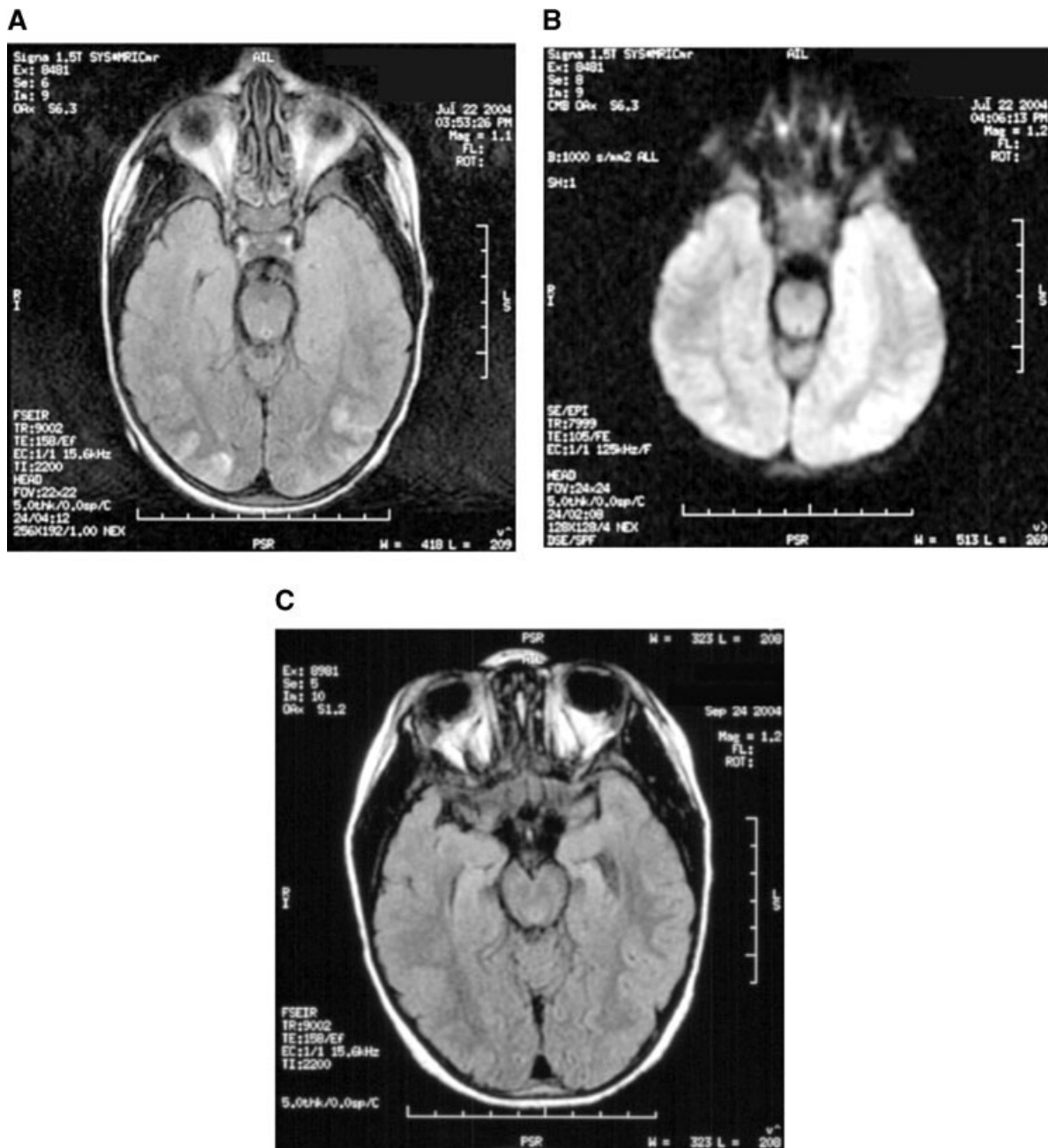


Fig. 3. (MRI images): **A:** Initial T2-weighted FLAIR image with patchy subcortical T2 abnormalities in bilateral parietal and occipital lobes. **B:** Initial diffusion-weighted image that has some T2 shine-through, but is otherwise normal. **C:** Follow up T2 weighted FLAIR image at 2 months with resolution of the T2 changes.

leukemia. All of the cases presented here include at least two of the clinical criteria for RPLS, and the first case has four (headache, mental status changes, cortical blindness, and hypertension). They all showed characteristic and reversible lesions on MRI scan, and all regained their normal state of functioning after the acute event subsided. The clinical symptoms and neuroradiologic findings are typically indistinguishable across all reported cases of RPLS, regardless of the underlying cause. Therefore, although the exact mechanism or trigger for RPLS remains unknown, the syndrome should be recognized as a potential complication of chemotherapy

so that it may be diagnosed quickly and potential inciting agents can be discontinued to prevent long term sequelae.

REFERENCES

1. Hinchey J, Chaves C, Appignani B, et al. A reversible posterior leukoencephalopathy syndrome. *N Engl J Med* 1996;334: 494–500.
2. Pavlakis SG, Frank Y, Chusid R. Hypertensive encephalopathy, reversible occipitoparietal encephalopathy, or reversible posterior

- leukoencephalopathy: Three names for an old syndrome. *J Child Neurol* 1999;14:277–281.
3. Casey SO, Sampaio RC, Michel E, et al. Posterior reversible encephalopathy syndrome: Utility of fluid-attenuated inversion recovery MR imaging in the detection of cortical and subcortical lesions. *Am J Neuroradiol* 2000;21:1199–1206.
 4. Antunes NL. Seizures in children with systemic cancer. *Pediatr Neurol* 2003;28:190–193.
 5. Antunes NL, Small TN, George D, et al. Posterior leukoencephalopathy syndrome may not be reversible. *Pediatr Neurol* 1999;20:241–243.
 6. Russell MT, Nassif AS, Cacayorin ED, et al. Gemcitabine-associated posterior reversible encephalopathy syndrome: MR imaging and MR spectroscopy findings. *Magn Reson Imaging* 2001;19:129–132.
 7. Ito Y, Arahata Y, Goto Y, et al. Cisplatin neurotoxicity presenting as reversible posterior leukoencephalopathy syndrome. *Am J Neuroradiol* 1998;19:415–417.
 8. Suminoe A, Matsuzaki A, Kira R, et al. Reversible posterior leukoencephalopathy syndrome in children with cancers. *J Pediatr Hematol Oncol* 2003;25:236–239.
 9. Jarosz JM, Howlett DC, Cox TC, et al. Cyclosporine-related reversible posterior leukoencephalopathy: MRI. *Neuroradiology* 1997;39:711–715.
 10. Sanchez-Carpintero R, Narbona J, Lopez DM, et al. Transient posterior encephalopathy induced by chemotherapy in children. *Pediatr Neurol* 2001;24:145–148.
 11. Rathi B, Azad RK, Vasudha N, et al. L-asparaginase-induced reversible posterior leukoencephalopathy syndrome in a child with acute lymphoblastic leukemia. *Pediatr Neurosurg* 2002;37:203–205.
 12. Schouten D, de Graaf SS, Verrips A. Transient cortical blindness following vincristine therapy. *Med Pediatr Oncol* 2003;41:470.
 13. Taque S, Peudenier S, Gie S, et al. Central neurotoxicity of cyclosporine in two children with nephrotic syndrome. *Pediatr Nephrol* 2004;19:276–280.
 14. Barabino A, Castellano E, Gandullia P, et al. A girl with severe fistulizing Crohn's disease. *Dig Liver Dis* 2000;32:792–794.
 15. Jeruss J, Braun SV, Reese JC, et al. Cyclosporine-induced white and grey matter central nervous system lesions in a pediatric renal transplant patient. *Pediatr Transplant* 1998;2:45–50.
 16. Ay H, Buonanno FS, Schaefer PW, et al. Posterior leukoencephalopathy without severe hypertension: Utility of diffusion-weighted MRI. *Neurology* 1998;51:1369–1376.
 17. Henderson RD, Rajah T, Nicol AJ, et al. Posterior leukoencephalopathy following intrathecal chemotherapy with MRA-documented vasospasm. *Neurology* 2003;60:326–328.

Successful Treatment With Voriconazole of *Aspergillus* Brain Abscess in a Boy With Medulloblastoma

M. Stiefel, MD,¹ T. Reiß, MD,¹ M.S. Staeger, PhD,¹ J. Rengelshausen, MD,² J. Burhenne, PhD,² A. Wawer, MD,³ and J.L. Foell, MD^{1*}

Invasive aspergillosis is an increasing problem in immunocompetent patients after prolonged steroid therapy, cancer radiochemotherapy, and bone marrow or solid organ transplantation. Cerebral aspergillosis is a well-described complication of the invasive aspergillosis but only in rare cases, the brain is the sole site of infection. Despite increasing availability of antifungal drugs, the prognosis of cerebral aspergillosis is poor. We report on an 11-year-old boy with medulloblastoma in the area of the fourth ventricle. Following tumor surgery and radio-chemotherapy, several abscess-like structures occurred in the operating field. After incomplete abscess, resection histology and culture confirmed a localized *Aspergillus fumigatus* infection. The initial treatment of

the *Aspergillus fumigatus* infection with conventional amphotericin B failed, and treatment with the triazole voriconazole was started. Intravenous treatment with voriconazole resulted in a reduction of the *Aspergillus fumigatus* abscess. After switching to oral ambulatory therapy, the *Aspergillus fumigatus* abscess increased in size. To improve treatment, voriconazole dosage was adapted to reach drug concentrations in cerebrospinal fluid (CSF) above the minimal fungicidal concentration and plasma specimens. During the concentration-controlled voriconazole therapy for a period of 18 months, a complete response was achieved. *Pediatr Blood Cancer* 2007;49:203–207. © 2005 Wiley-Liss, Inc.

Key words: aspergillosis; brain tumors; infectious disease; pediatric oncology

INTRODUCTION

Invasive *Aspergillus* species infection is a common and increasing problem in immuno-incompetent patients who received prolonged steroid therapy, radiochemotherapy, organ or bone marrow transplantation [1]. Involvement of the central nervous system (CNS) occurred in 20% of patients with invasive Aspergillosis [2]. CNS aspergillosis is usually secondary to hematogenous dissemination of fungal infection from the lungs or due to contiguous infection secondary to paranasal sinus infection. Occasionally it may also be seen as a complication of a neurosurgical procedure [3–5]. The prognosis of CNS *Aspergillus*

¹Department of Pediatric, Hematology-Oncology, Martin-Luther University Halle-Wittenberg, Halle, Germany; ²Department of Internal Medicine VI, Clinical Pharmacology and Pharmacoepidemiology, University of Heidelberg, Heidelberg, Germany; ³Department of Pediatric, Hematology-Oncology, Children Hospital TU Munich-Schwabing, Germany

*Correspondence to: J.L. Foell, Department of Pediatrics, Hematology and Oncology, Martin-Luther University Halle-Wittenberg, 06097 Halle, Germany. E-mail: juergen.foell@medizin.uni-halle.de

Received 14 June 2005; Accepted 22 August 2005