

SHORT COMMUNICATION

Stroke and pulmonary thromboembolism after a long flight

R. Belvis^a, J. Masjuan^b, N. García-Barragán^b, D. Cocho^a, J. Martí-Fàbregas^a, A. Santamaría^c, R. G. Leta^d, J. C. Martínez-Castrillo^b, L. C. Fernández-Ruiz^b, F. Gilo^b and J. L. Martí-Vilalta^a

^aDepartment of Neurology, Hospital de la Santa Creu i Sant Pau, Barcelona; ^bDepartment of Neurology, Hospital Ramón y Cajal, Madrid; ^cDepartment of Haematology, Hospital de la Santa Creu i Sant Pau, Barcelona; and ^dDepartment of Cardiology, Hospital de la Santa Creu i Sant Pau, Barcelona, Spain

Keywords:

deep venous thrombosis, economy class stroke syndrome, factor XII, patent foramen ovale, pulmonary thromboembolism

Received 9 August 2004

Accepted 3 November 2004

In the economy class syndrome (ECS) the patient presents a deep venous thrombosis (DVT) with or without pulmonary thromboembolism (PTE) during or after a long trip as a result of prolonged immobilization. Economy class stroke syndrome is an infrequent ECS variant in which ischemic stroke is associated with a patent foramen ovale (PFO). Few cases have been published in the literature to date. We present a patient who suffered a PTE and an ischemic stroke immediately after a transoceanic flight. A 36-year-old woman with no significant medical or familial history flew economy class from Lima, Peru, to Madrid, Spain. On disembarkation she presented sudden dyspnea and a depressed level of consciousness, global aphasia, and right hemiparesis. A pulmonary scintigraphy showed a PTE and a cranial MRI revealed an ischemic infarct in the left middle cerebral artery territory. We simultaneously performed a transesophageal echocardiography and a transcranial Doppler and observed a massive right-to-left shunt through a PFO. The patient was a heterozygous carrier of the C46T mutation of coagulation factor XII. The appearance of a stroke following a long trip is suggestive of paradoxical embolism through a PFO, mainly if it is associated with a DVT and/or a PTE. The cause of the initial event, the DVT, could be a prothrombotic state.

Economy class syndrome (ECS) consists of a deep venous thrombosis (DVT), generally in lower limbs, with or without associated pulmonary thromboembolism (PTE), during or immediately after long trips. Homans (1954) made the first description in 1954 but Cruickshank *et al.* (1988) was the first to use the term in 1988. It has also been reported in first-class travelers, airline pilots, and on train and highway journeys (Ferrari *et al.*, 1999). Some experts therefore propose it should best be named 'travelers' thrombosis' (Giangrande, 2002). An ECS variant known as *economy class stroke syndrome* has been described (Beighton and Richards, 1968; Masson *et al.*, 1997; Isayev *et al.*, 2002; Lapostolle *et al.*, 2003; Foerch *et al.*, 2004; Heckmann *et al.*, 2004; Kakkos and Geroulakos, 2004). It is characterized by an ischemic stroke during or shortly after a long flight. A patent foramen ovale (PFO) has been demonstrated in all patients with a concomitant DVT and/or a PTE.

Case report

A 36-year-old woman with no significant medical or familial history traveled by air in an economy class

flight, from Lima, Peru, to Madrid, Spain (5940 miles distance, 11.35 h). She reportedly slept most of the trip and referred a slight pain in her right calf after 8 h of travel.

On the plane and after landing, she presented dyspnea and was attended by the medical airport service. Twenty minutes later, she suddenly presented a depressed level of consciousness, right hemiparesis and global aphasia. The neurological examination showed a low level of consciousness, left conjugated gaze deviation, right homonymous hemianopsia, global aphasia, right central facial paresis, and right hemiparesis. The cranial CT was normal. A pulmonary perfusion scintigraphy showed multiple subsegmentary perfusion defects affecting both lungs, suggesting a multiple PTE (Fig. 1a). We began treatment with intravenous heparin.

Forty-eight hours later, a venous duplex of lower limbs and a supra-aortic vessel duplex were normal. A cranial MRI showed an ischemic infarct affecting lentulostrates, temporal, and parietal branches of left middle cerebral artery (MCA) (Fig. 1b).

We performed a transesophageal echocardiography (TEE) that did not disclose any cardiac or aortic disturbances. A right-to-left shunt (RLS) study, injecting agitated microbubbles (mb) in an antecubital vein, showed a countless passing of mb from the right to the left atrium during Valsalva maneuver (Fig. 2a).

Correspondence: Dr Robert Belvis, Stroke Unit of the Department of Neurology, Hospital de la Santa Creu i Sant Pau, Avda Sant Antoni M, Claret 167, E-08025 Barcelona, Spain (tel.: +34-93-2919049; fax: +34-93-2919275; e-mail: rbelvis@hsp.santpau.es).

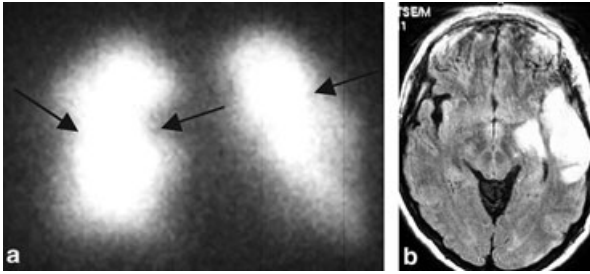


Figure 1 (a) Perfusion pulmonary scintigraphy showing multiple subsegmentary perfusion defects in both lungs, suggesting a multiple pulmonary thromboembolism. (b) Cranial MRI weighted in T2 FLAIR showing an ischemic infarct involving the left MCA territory.

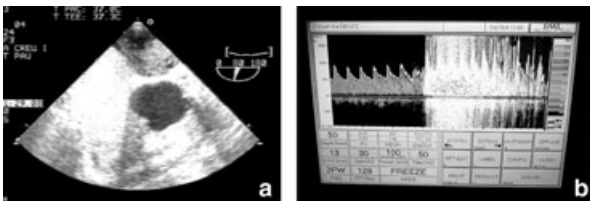


Figure 2 (a) Transesophageal echocardiography showing a countless right-to-left passing of microbubbles during Valsalva maneuver. (b) Simultaneous transcranial Doppler sonography of the right MCA illustrating a massive right-to-left shunt with curtain pattern 4 s after venous injection of microbubbles.

Simultaneously, we applied a transcranial Doppler (TCD) probe of 2 MHz in the right MCA and observed massive mb passing in a curtain pattern (Fig. 2b).

A thrombophilia screening showed normal C and S proteins, factor VIII, antiphospholipid antibodies and lupus anticoagulant. Plasmatic homocysteine was also normal. We ruled out the G1691A mutation of coagulation factor V (factor V Leiden) and the G20210A prothrombin gene mutation. The patient showed a C46T mutation of coagulation factor XII. Neoplastic markers were normal.

The patient received oral anticoagulation on continuation and she was discharged 2 weeks after admission. Three months later, she presented only a nominal aphasia.

Discussion

We report a new case of a patient with *Economy class stroke syndrome*. She presented DVT symptoms and a PTE followed by an ischemic stroke at the airport after a long flight. A new prothrombotic state, the C46T mutation of coagulation factor XII, could be the etiology.

The *economy class stroke syndrome* appeared in 6% of ECS patients diagnosed at Charles de Gaulle airport

over 7 years (Lapostolle *et al.*, 2003). Only 14 previous patients have been reported in the literature and all of them have a PFO (Beighton and Richards, 1968; Masson *et al.*, 1997; Isayev *et al.*, 2002; Lapostolle *et al.*, 2003; Foerch *et al.*, 2004; Heckmann *et al.*, 2004; Kakkos and Geroulakos, 2004). Their mean age is 50 years with a 2:1 female/male ratio. All patients presented symptoms toward the end or immediately after the flight and the mean flight time was 10 h with a mean distance of 9000 km.

RLS size is proportionally related to the probability of an ischemic stroke (Serena *et al.*, 1998) and Valsalva maneuvers, usual during landing to balance air pressure in the middle ear, increase the RLS size. Moreover, in patients with PTE there is an increase of right atrium pressure that in turn induces an RLS size increase (Lapostolle *et al.*, 2003).

PFO is observed in 17–27% (Hagen *et al.*, 1984) of the population, and it has been reported in over 40% of cryptogenic stroke patients, mainly in those under 55 years (Messé *et al.*, 2004). A migrating thrombus proceeding from a DVT, may cross the PFO and occlude a cerebral artery. This is the theory of paradoxical embolism.

A prothrombotic state can originate the thrombus. Recent studies have established high incidences of the new haemostatic gene polymorphisms (factor V Leiden and G21201A prothrombin gene mutation) in patients with cryptogenic stroke and PFO (Pezzini *et al.*, 2003). Prolonged immobilization was the precipitating factor of thrombi in our patient, but she also had a predisposing factor; she was a heterozygous carrier of the C46T mutation of the XII coagulation factor. This mutation has been related to venous thrombosis (Tirado *et al.*, 2004) and the homozygosity of this mutation has been related to ischemic stroke with an adjusted odds ratio of 4.1. (Santamaria *et al.*, 2004). As far as we know, this is the first report of a patient with DVT, ischemic stroke and PFO who carried this mutation.

Recent reports indicate 4.5–10% of airline passengers have an asymptomatic DVT on long flights (Belcaro *et al.*, 2001; Scurr *et al.*, 2001) and an incidence of 0.39 PTE patients per million of airline passengers has been estimated at the Madrid airport (Pérez-Rodríguez *et al.*, 2003). Venous thrombi formation is related to prolonged immobilization, relative dehydration and use of sedatives drugs, alcohol, tea or coffee, and also to low ambient humidity, relative hypoxia and low pressure in the cabin. Some studies have characterized the ECS patient at greatest risk (Table 1). Likewise, the greatest travel risk appears to be flights of over 4–6 h or over 5000 km.

Deep venous thrombosis is frequently not found (Stollberger *et al.*, 1993). We did not find it despite calf

Table 1 Risk factors of economy class syndrome

-
- Obesity
 - Prothrombotic states
 - Major surgery or long bone fracture within previous 2 weeks
 - Prior DVT
 - Venous insufficiency
 - Neoplastic disease within the previous 2 years
 - Oral contraceptives
 - Any condition limiting mobility
-

symptoms. There are several possible explanations. First, venous duplex studies do not have 100% sensitivity, and secondly, the venous duplex was performed 48 h after anticoagulation therapy began. Furthermore, thrombi are not always in lower limbs, as revealed in a recent study showing pelvis venous thrombi as the cause of paradoxical embolism (Cramer *et al.*, 2004).

Established preventive measures are to avoid crossing legs and prolonged awkward hip or knee positions, to do regular leg exercises and to stand up frequently and walk around the cabin. Passengers are also advised to drink a lot of liquids but to avoid alcohol, coffee, tea, and sedative drugs. The physician may recommend taking antithrombotic drugs in high-risk patients prior to the flight.

Stroke during or immediately after a flight is suggestive of a paradoxical embolism through the PFO, better named 'travelers' stroke' than *economy class stroke syndrome*. In these patients, it is necessary to rule out the coexistence of DVT and PTE as they could cause thromboembolic recurrences or hypoxia, aggravating stroke prognosis, and even cause sudden death. Finally, immobilization probably is not enough to cause the initial DVT, and it is necessary to rule out a prothrombotic state.

References

- Beighton PH, Richards PR (1968). Cardiovascular disease in air travellers. *Br Heart J* **30**:367–372.
- Belcaro G, Geroulakos G, Nicolaides AN, Myers KA, Winford M (2001). Venous thromboembolism from air travel: the LONFLIT study. *Angiology* **52**:369–374.
- Cramer SC, Rordorf G, Maki JH *et al.* (2004). Increased pelvic vein thrombi in cryptogenic stroke: results of the Paradoxical Emboli from Large Veins in Ischemic Stroke (PELVIS) study. *Stroke* **35**:46–50.
- Cruickshank JM, Gorlin R, Jennett B (1988). Thromboembolism and air travel. *Lancet* **2**:1501.
- Ferrari E, Chevallier T, Chapelier A, Baudouy M (1999). Travel as a risk factor for venous thromboembolic disease: a case-control study. *Chest* **115**:440–444.
- Foerch C, Kessler KR, Steinmetz H, Sitzer M (2004). 'Economy class' stroke syndrome. *Neurology* **62**:1026.
- Giangrande PL (2002). Air travel and thrombosis. *Br J Haematol* **117**:509–512.
- Hagen PT, Scholz DG, Edwards WD (1984). Incidence and size of patent foramen ovale during the first 10 decades of life. *Mayo Clin Proc* **59**:17–20.
- Heckmann JG, Stemper B, Ringwald J, Nixdorff U, Neundorfer B (2004). Economy class stroke syndrome. *Cerebrovasc Dis* **17**:88.
- Homans J (1954). Thrombosis of the deep leg veins due to prolonged sitting. *N Engl J Med* **250**:148–149.
- Isayev Y, Chan RK, Pullicino PM (2002). 'Economy class' stroke syndrome? *Neurology* **58**:960–961.
- Kakkos SK, Geroulakos G (2004). Economy class stroke syndrome: case report and review of the literature. *Eur J Vasc Endovasc Surg* **27**:239–243.
- Lapostolle F, Borron SW, Surget V, Sordet D, Lapandry C, Adnet F (2003). Stroke associated with pulmonary embolism after air travel. *Neurology* **60**:1983–1985.
- Masson C, Perrote P, Mariescu A (1997). Un accident ischémique cérébral au décours d'un vol transatlantique. *Presse Med* **26**:269–270.
- Messé SR, Silvermann IE, Kizer JR *et al.* (2004). Practice parameter: recurrent stroke with patent foramen ovale and atrial septal aneurysm. Report of the Quality Standards Subcommittee of the American Academy of Neurology. *Neurology* **62**:1042–1050.
- Pérez-Rodríguez E, Jiménez D, Díaz G *et al.* (2003). Incidence of air travel-related pulmonary embolism at the Madrid-Barajas airport. *Arch Intern Med* **163**:2776–2780.
- Pezzini A, Del Zotto E, Magoni M *et al.* (2003). Inherited thrombophilic disorders in young adults with ischemic stroke and patent foramen ovale. *Stroke* **34**:28–33.
- Santamaría A, Mateo J, Tirado I *et al.* (2004). Homozygosity of the T allele of the 46C->T polymorphism in the F12 gene is a risk factor for ischemic stroke in the Spanish population. *Stroke* **35**:1795–1799.
- Scurr JH, Machin SJ, Bailey-King S, Mackie IJ, McDonald S, Smith PD (2001). Frequency and prevention of symptomless deep-vein thrombosis in long-haul flights: a randomised trial. *Lancet* **357**:1485–1489.
- Serena J, Segura T, Pérez-Ayuso MJ, Bassaganyas J, Molins A, Dávalos A (1998). The need to quantify right-to-left shunt in acute ischemic stroke: a case-control study. *Stroke* **29**:1322–1328.
- Stollberger C, Slany J, Schuster I, Leitner H, Winkler WB, Karnik R (1993). The prevalence of deep venous thrombosis in patients with suspected paradoxical embolism. *Ann Intern Med* **15**:461–465.
- Tirado I, Manuel Soria J, Mateo J *et al.* (2004). Association after linkage analysis indicates that homozygosity for the 46C-T polymorphism in the F12 gene is a genetic risk factor for venous thrombosis. *Thromb Haemost* **91**:899–904.