

## Isoflurane in the Management of Status Epilepticus After Surgery for Lesion Around the Motor Area

T. Sakaki<sup>1</sup>, K. Abe<sup>2</sup>, T. Hoshida<sup>1</sup>, T. Morimoto<sup>1</sup>, S. Tsunoda<sup>1</sup>, K. Okuchi<sup>3</sup>, S. Miyamoto<sup>3</sup>, and H. Furuya<sup>4</sup>

Departments of <sup>1</sup>Neurosurgery, <sup>3</sup>Emergent Medicine and <sup>4</sup>Anesthesiology, Nara Medical University, Nara, and <sup>2</sup>Department of Anesthesiology, Osaka Police Hospital, Osaka, Japan

### Summary

When conventional treatment for status epilepticus fails, general anaesthesia is recommended. We present our experience with isoflurane, an inhalational anaesthetic, in the management of four patients with status epilepticus which occurred soon after surgery for motor area lesion. The seizures were controlled with relatively small concentrations of isoflurane. Hypotension, the only adverse effect of isoflurane, was managed easily with the use of dopamine in physiological saline. Although status epilepticus occurring soon after surgery is transient, it carries a risk of persistent brain damage if active treatment is not instituted promptly. Isoflurane general anaesthesia may be recommended to control it in the intensive neurosurgical care.

**Keywords:** Isoflurane; status epilepticus; motor area; postoperative complication.

### Introduction

Status epilepticus is a neurological emergency. When conventional intravenous agents prove unsuccessful, general anaesthesia is advocated<sup>3</sup>. It has been shown that both thiopental and isoflurane produce a dose-related decrease in cerebral function as detected by the electroencephalogram (EEG), with an attendant decrease in cerebral oxygen metabolism (CMRO<sub>2</sub>), with maximal metabolic depression occurring with onset of an isoelectric EEG<sup>17, 18</sup>. Although barbiturate anaesthesia is good treatment for status epilepticus<sup>12, 25, 31</sup> it is often difficult to keep the serum level steady, and to maintain the blood pressure without performing

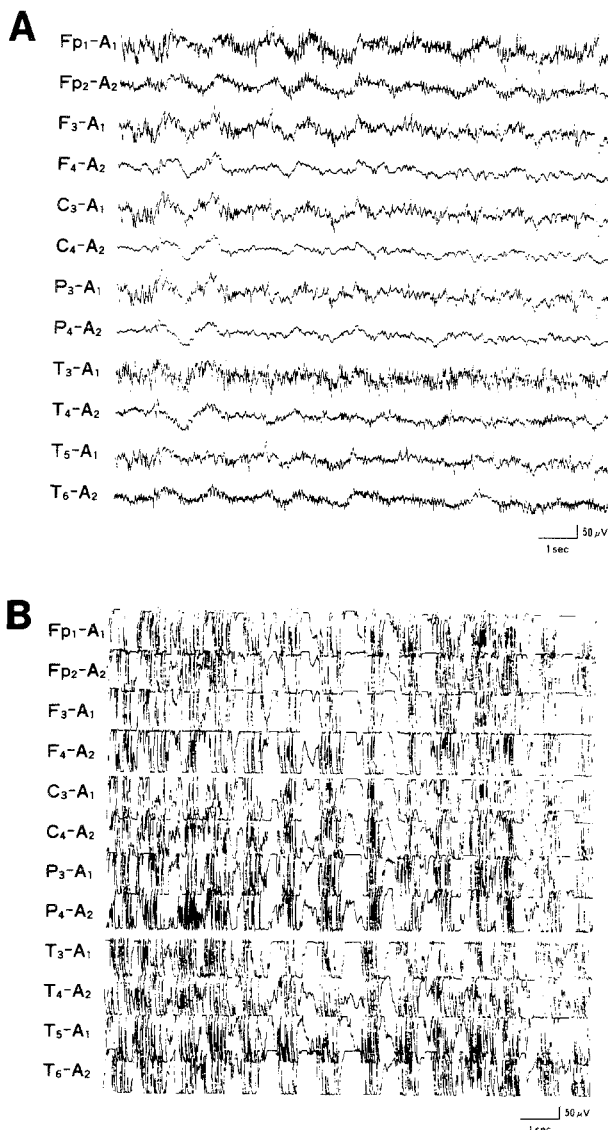


Fig. 1. Electroencephalography demonstrated spike discharges from the hemisphere with the lesion preoperatively (A). But, status epilepticus occurred in spite of pre-operative administration of anti-convulsants soon after removal of the lesion and termination of anaesthesia (B)

a continuous dopamine infusion<sup>21</sup>. Judging from these shortcomings of barbiturate anaesthesia, isoflurane anaesthesia may be the best treatment for patients with status epilepticus resulting from surgery for cerebral organic lesions.

We report four cases whose status epilepticus occurred soon after surgery for cerebral lesions around the motor area and treated effectively with isoflurane general anaesthesia. We describe the effectiveness of isoflurane, an inhalational anaesthetic, in the management of this condition to alleviate attacks and to protect the brain from ischaemic damage during the attack.

### Patients and Methods

Four patients had status epilepticus soon after the operation for a lesion around the motor area (Fig. 1) and were subjected to iso-

flurane anaesthesia, because the seizure did not respond to the prompt administration of therapeutic doses of phenobarbital or phenytoin. Although intravenous diazepam administration alleviated the attacks, the effect was only transient. An administration of thiopental was also effective, but marked hypotension occurred, whenever the dose reached burst-suppression of the EEG pattern. For these reasons, it was decided to administer isoflurane general anaesthesia. Continuous isoflurane general anaesthesia was performed using a vaporizer (Isoflurane vaporizer 952, Siemens-elema, Sweden) attached to the gas supply of the ventilator (Servo 900C, Siemens-elema, Sweden). EEG activity was monitored continuously until electroencephalographic suppression occurred (Fig. 2), and thereafter monitored every thirty minutes. Intracranial pressure (ICP) was also monitored continuously using spinal drainage apparatus. The isoflurane was easily titrated to maintain burst suppression, but an increased volume of intravenous fluid and a transient increase in the dopamine were given to maintain an adequate blood pressure, if necessary. The patient was given concentration of 0.5 to 1 percent of inspired isoflurane. The end-tidal isoflurane concentra-

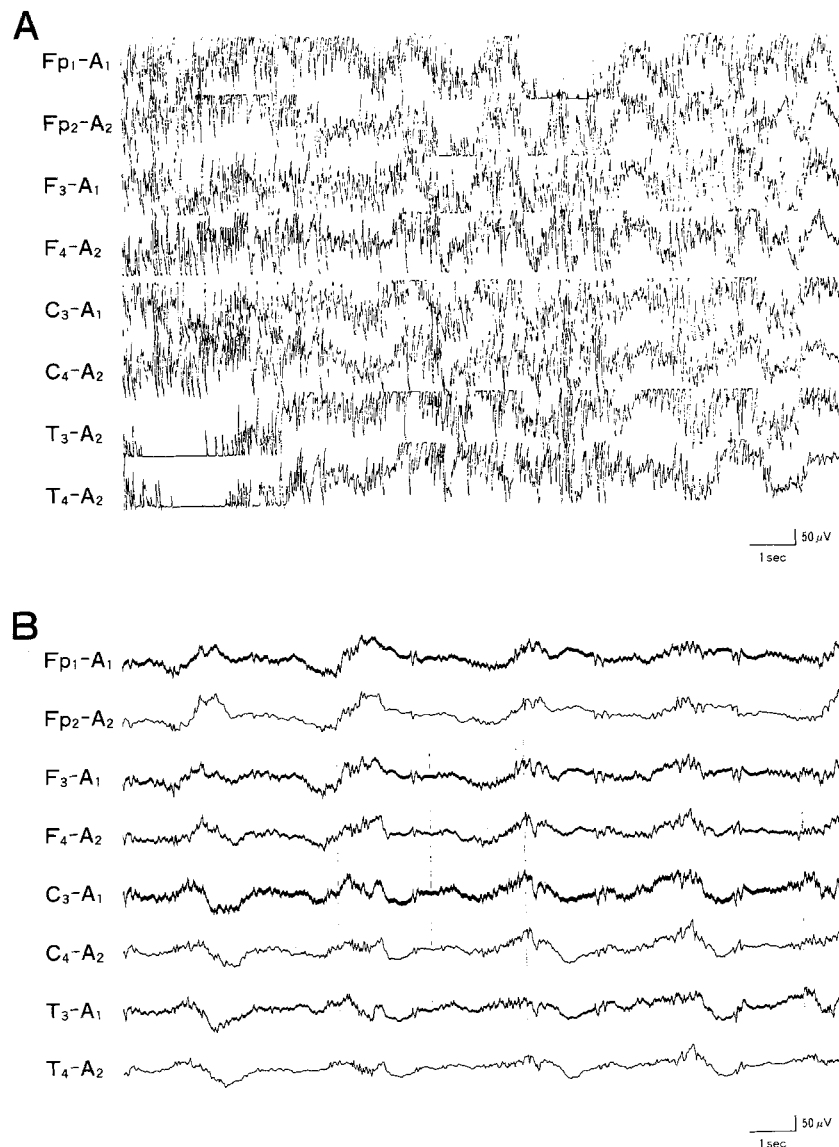


Fig. 2. The remarkable spike discharges (A) were suppressed completely after isoflurane general anaesthesia (B)

tion and endexpiratory CO<sub>2</sub> were monitored continuously (MI025A, Hewlett Packard, U.S.A.). An anaesthetist and a neurosurgeon were always present.

If the ICP exceeded 200 mmH<sub>2</sub>O, instillation of mannitol or glycerol was started in addition to the administration of steroid.

In all patients, seizures were controlled long term with oral administration of conventional anticonvulsants, and the prognosis of the patients was excellent.

## Case Reports

### Case 1

A 39 year-old woman was transferred on April 1, 1988 to our hospital with generalized tonic-clonic convulsions which were soon alleviated by the intravenous administration of diazepam. CT scan performed on admission, demonstrated a large meningioma at the left motor area without perifocal cerebral oedema (Fig. 3). Left external and internal angiography demonstrated a convexity meningioma indenting the brain between prerolandic and vein of Trolard's. Surgical removal of the meningioma was performed on 18th April 1988, and she woke up from anaesthesia without neurological deficit. But partial seizures of right upper extremity occurred two hours after the surgery and developed into generalized status epilepticus in spite of the intravenous administration of diazepam or thiopental. A lidocaine infusion at 4 mg/min for 3 hours and 10% paraldehyde solution in physiological saline infusion 30 ml/h for 6 hours had no effect. Therefore they were discontinued. Considering that maximal therapy with conventional anticonvulsants had not controlled the status epilepticus, it was decided to administer isoflurane general anaesthesia. With the start of anaesthesia, suppression of epileptiform discharge was observed without blood pressure reduction. 12 hours later, valproic acid was administered at a dose of 4 mg/kg/6 hour transenterally through the nasal tube. Although the anaesthesia was gradually withdrawn 24 hours after administration of isoflurane, epileptiform discharges were seldom recognized in the EEG. The patient regained consciousness slowly but steadily and showed monoparesis of the right upper extremity and motor aphasia at first. These signs cleared after 2 days completely. The seizures were well controlled by oral intake of valproic acid thereafter.

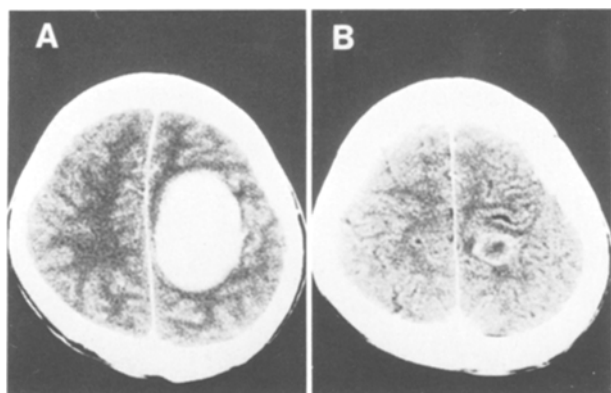


Fig. 3. CT scan demonstrating the meningioma involving the motor area of the left hemisphere without perifocal oedema (A). After surgery, the area of surgical removal demonstrated ring-like enhancement on CT scan with infusion of contrast material (B)

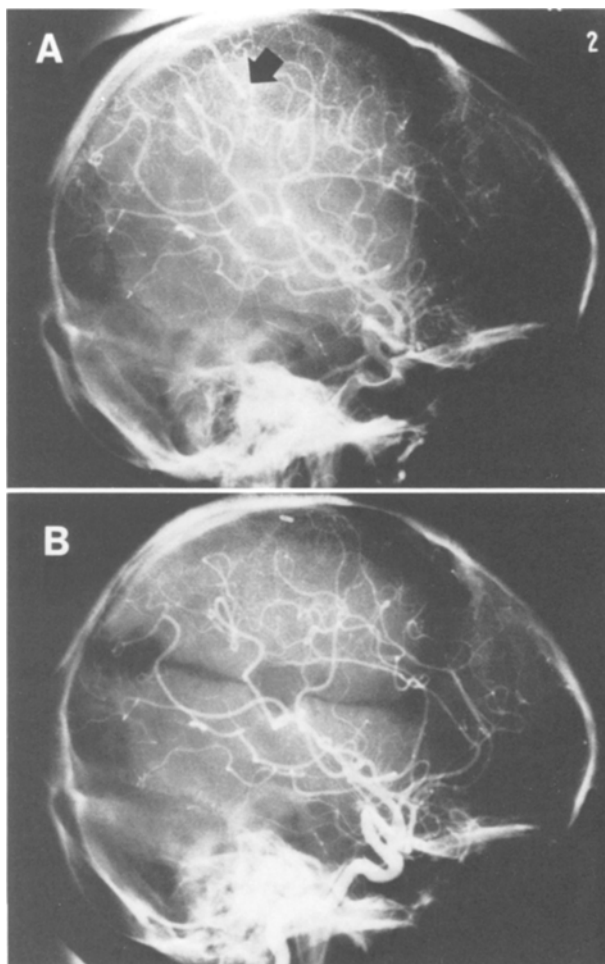


Fig. 4. Angiography of Case 2 showed a small arteriovenous malformation (arrow) at the left post-rolandic gyrus (A), and it was completely removed surgically (B)

### Case 2

A 24 years-old man was admitted with sudden onset of generalized convulsions and loss of consciousness on 5th September 1989. CT scan performed on admission, showed a calcified lesion which was enhanced by the administration of the contrast material. Left internal carotid angiography demonstrated a small arteriovenous malformation at the left parietal motor area (Fig. 4). On 16th September, surgical removal of the arteriovenous malformation was performed. Although the patient woke up from anaesthesia soon, slight paresis of the right upper extremity was recognized. One hour later, right hemiconvulsions occurred. These developed into status epilepticus in spite of aggressive intravenous administration of anticonvulsants such as diazepam, phenytoin, phenobarbital, or lidocaine. Although intravenous administration of thiopental was effective, the blood pressure could not be maintained without titration of dopamine, and his spontaneous respiration disappeared whenever the dose of thiopental was increased to stop the seizure completely. Considering that infusion of conventional anticonvulsants was only partially effective, it was decided to administer isoflurane general anaesthesia under controlled ventilation. Anaesthesia was continued

for 12 hours. With gradual withdrawal of anaesthesia, 30 mg/kg/day of valproic acid, 120 mg/day of phenobarbital, and 300 mg/day of phenytoin were given through nasogastric tube. His seizures were well controlled after discontinuation of anaesthesia, and consciousness returned although the right hemiparesis which improved remarkably three months later, was obvious initially.

#### Case 3

A 34 year-old-woman was transferred to our hospital on 15th March 1990, because of moderate headache, right hemiparesis and speech disturbance. These symptoms and signs occurred gradually over months and were not remarkable. On the next day, she had a partial seizure involving the right upper extremity and thereafter she could not move her right upper extremity and speak fluently. On the CT scan and MRI performed at our hospital, a cystic tumour with partial calcification was visualized.

On 27th March 1990, a left frontoparietal craniotomy was performed and the tumour was removed partially for histological diagnosis, and an Ommaya's reservoir was set up for the purpose of evacuation of the tumour cyst from time to time. Soon after surgery, the patient was conscious although she had increased right hemiparesis and speech disturbance. About three hours later, monotonics of her right upper extremity started, and then status epilepticus with generalized convulsions developed over several hours in spite of the intravenous administration of conventional anticonvulsants. On the basis of our past experience, we decided to perform isoflurane general anaesthesia to control the status epilepticus. Although the inhalational anaesthesia was discontinued twelve hours after start of isoflurane administration, her convulsions were controlled well with oral intake of valproic acid and phenobarbital through the nasal tube.

#### Case 4

A 44-year-old woman was transferred to our hospital on 4th August 1990, because she had an arteriovenous malformation (AVM) involving the posterior part of the right frontal lobe.

On 13th August, surgical removal of the AVM was performed. Although the patient regained consciousness soon after surgery, partial seizures of the left upper extremity started. At first the attacks were confined to the left extremities, however, soon they developed into the generalized tonic-clonic status epilepticus. In spite of the intravenous administration of diazepam, phenytoin, and thiopental, the attacks were very difficult to control. Because of our previous excellent experience with three cases, and afraid of dangerous post-operative bleeding secondary to hypertension accompanying the epileptic attacks, we decided to institute isoflurane general anaesthesia under the EEG monitoring.

Soon after start of the anaesthesia, the status epilepticus was controlled and the blood pressure got down to the normal range. 12 hours after the anaesthesia, conventional anticonvulsant drugs (valproic acid 1200 mg/day, phenobarbital 150 mg/day) were administered via the nasogastric tube. The concentration of isoflurane was gradually reduced and stopped 14 hours after the induction of anaesthesia. The patient recovered from the anaesthesia gradually and did not show any epileptic attacks. After that, the seizures were well controlled by the oral intake of 1200 mg/day of valproic acid alone.

## Discussion

Convulsions which occur early after neurosurgery involving lesions around the motor area, are not so

rare. Even if the convulsion, develops into status epilepticus, initial treatment (i.e., intravenous phenytoin and/or phenobarbital following treatment with intravenous diazepam) for the status is effective in most cases and only a minority of patients require further treatment<sup>12</sup>. But if status supervenes with fits recurring at short intervals, the risk of persistent brain damage may increase<sup>1, 16, 17</sup>. Therefore, it is necessary to stop this as soon as possible. When status epilepticus does not respond to conventional intravenous anticonvulsant drugs, an inhalational anaesthetic can be employed<sup>3, 13</sup>. Halothane was the only inhalational anaesthetic available for this purpose before the introduction of isoflurane<sup>3</sup>. But halothane has many shortcomings such as unacceptable adverse haemodynamic effects due to negative inotropism and systemic vasodilation, hepatotoxicity and so on<sup>5</sup>. Enflurane has been noted to have anti-epileptic actions in laboratory animals<sup>22, 30</sup> and humans<sup>6, 19</sup>. But many investigators have shown that by using relatively high concentration (up to 3.5%) and hypocarbia, enflurane can induce seizures<sup>29</sup>, and some have advised against the use of this anaesthetic for epileptic patients<sup>14, 26</sup>. Isoflurane does not evoke such side effects and causes a dose-related reduction in cortical electrical activity with an attendant decrease in cerebral oxygen metabolism without changing cerebral blood flow<sup>4, 7, 17, 18</sup>.

Many lesions which result in chronic focal epilepsy are associated with focal blood-brain-barrier (BBB) break down<sup>27</sup>. Thus, pathological intracerebral leakage of quinolinic acid might result from the BBB disruption following surgery. Although the mechanism of post-operative status epilepticus is not known exactly, hyperexcitation of nerve cells around the motor cortex may be enhanced by surgical manipulation. MRI or CT scan of these four cases performed pre-operatively, demonstrated no sign of perifocal oedema or cerebral damage. It is supposed that the neural cells around the lesion are already broken down pre-operatively in cases with perifocal abnormality on MRI or CT scan and that they demonstrate no transient hyperactivity in their function after surgery. But, neural cells around the lesion are still functioning actively in cases without perifocal abnormality demonstrated on MRI or CT scan. Therefore, in such cases the incidence of status epilepticus may be higher than in cases with perifocal oedema.

Isoflurane is a very useful agent for the management of status epilepticus<sup>10, 11, 15</sup> because it can produce EEG suppression at concentrations not ordinarily associated

with undesirable haemodynamic effects and because it lacks known organ toxicity<sup>2, 24</sup>. Kofke *et al.*<sup>10</sup> reported that a 10-year-old girl who suffered from intractable epilepsy, was treated with prolonged low flow isoflurane anaesthesia, and suggested that isoflurane may have a role in the earlier management of refractory status epilepticus in the future<sup>10, 11</sup>. Meeke *et al.*<sup>15</sup> reported that a 32-year-old woman with generalized tonic-clonic status epilepticus was managed by isoflurane general anaesthesia using a vaporizer attached to the gas supply of the ventilator, and concluded that isoflurane may be preferable to halothane and possibly thiopental in the management of status epilepticus.

Now, no data are available to guide the clinician who is trying to decide how deeply to anaesthetize a patient with status epilepticus. Barbiturates in animals have been noted to produce maximal depression of cerebral metabolism when a burst-suppression interval of 30 secs is achieved<sup>9</sup>. The dose regimen of barbiturate is chosen empirically on the serum levels during burst-suppression state in the treatment of status epilepticus<sup>12, 31</sup>. Thus a burst-suppression interval of 15 to 30 secs seems a reasonable goal in titrating isoflurane in such patients with intractable seizures.

Even if status epilepticus is transient after surgery, it must be treated promptly and actively because of the risk of persistent brain damage. We conclude that continuous isoflurane anaesthesia may be a good method for the management of status epilepticus developing soon after surgical treatment of lesions of the motor area.

## References

- Aminoff MJ, Simon RP (1980) Status epilepticus: causes, clinical features and consequences in 98 patients. *Am J Med* 69: 657-666
- Baden JM, Rice SA (1986) Metabolism and toxicity of inhaled anesthetics. In: Miller RD (eds) *Anesthesia*. Churchill Livingstone, New York, pp 701-744
- Delgado-Escueta AV, Wasterlain C, Trieman DM, Porter RJ (1982) Management of status epilepticus. *N Engl J Med* 306: 1337-1340
- Eger EI, Stevens WC, Cromwell TH (1971) The electroencephalogram in mean anesthetized with Forane. *Anesthesiology* 35: 504-508
- Egar EI (1981) Isoflurane: a review. *Anesthesiology* 55: 559-576
- Gallagher TJ, Galindo A, Richey ET (1978) Inhibition of seizure activity during enflurane anesthesia. *Anesth Analg* 57: 130-132
- Ito BM, Sato S, Kufta CV, Tran D (1987) Effect of isoflurane and enflurane on the electrocorticogram (ECOG) of epileptic patients (abstract). *Neurology [Suppl]* 37: 91
- Jennett WB (1969) Early traumatic epilepsy. *Lancet* 1: 1023-1026
- Kassell NF, Hitchon PW, Gerk MK, Sokoll MD, Hill TR (1980) Alterations in cerebral blood flow, oxygen metabolism, and electrical activity produced by high dose sodium thiopental. *Neurosurgery* 7: 598-603
- Kofke WA, Snider MT, Young PSK, Ramer JC (1985) Prolonged low flow isoflurane anesthesia for status epilepticus. *Anesthesiology* 62: 653-656
- Kofke WA, Young RS, Davis P, Woelfel SK, Gray L, Johnson D, Gelb A, Meeke R, Warner DS, Pearson KS, Gibson JR, Koncelik J, Wessel HB (1989) Isoflurane for refractory status epilepticus: a clinical series. *Anesthesiology* 71: 653-659
- Lowenstein DH, Aminoff MJ, Simon RP (1988) Barbiturate anesthesia in the treatment of status epilepticus. *Neurology* 38: 395-400
- Lowe HJ, Ernst EA (1981) *The quantitative practice of anesthesia*. Williams and Wilkins, Baltimore/London
- Marshall BE, Wollman H (1980) General anesthetics. In: Gilman AG, Gilman LS (eds) *The pharmacological basis of therapeutics*, 5th Ed. Macmillan, New York, pp 276-299
- Meekre RI, Soifer BE, Gelf AW (1989) Isoflurane for the management of status epilepticus. *DICP* 23: 579-581
- Meldrum BS, Brierly JB (1973) Prolonged epileptic seizures in primates: ischemic cell change and its relation to ictal physiological events. *Arch Neurol* 28: 10-17
- Michenfelder JD (1974) The interdependency of cerebral function and metabolic effects following massive doses of thiopental in the dog. *Anesthesiology* 41: 231-236
- Newberg LA, Milde JH, Michenfelder JD (1983) The cerebral metabolic effects of isoflurane at and above concentration which suppress cortical electrical activity. *Anesthesiology* 59: 23-29
- Opitz A, Oberwetter D (1979) Enflurane or halothane anesthesia for patients with cerebral convulsive disorders? *Acta Anesthesiol Scand [Suppl]* 71: 43-47
- Opitz A, Marschall M, Degan R, Koch D (1983) General anesthesia in patients with epilepsy and status epilepticus. In: Delgado-Escueta AV, Wasterlain CG, Trieman DM, Porter RJ (eds) *Mechanism of brain damage and treatment*. Raven Press, New York, pp 531-535
- Orlowski JP, Erenberg G, Hans L (1984) Hypothermia and barbiturate coma for refractory status epilepticus. *Crit Care Med* 12: 362-372
- Oshima E, Urabe N, Shingu K, Mori K (1985) Anticonvulsant actions of enflurane on epilepsy models in cats. *Anesthesiology* 63: 29-40
- Pagni CA (1990) Posttraumatic epilepsy. Incidence and Prophylaxis. *Acta Neurochir (Wien) [Suppl]* 50: 28-47
- Pauca AL, Dripps RD (1973) Clinical experience with isoflurane (Forane). *Br J Anaesth* 45: 697-703
- Rashkin MC, Youngs C, Penovich P (1987) Pentobarbital treatment of refractory status epilepticus. *Neurology* 37: 500-503
- Rosen I, Soederberg M (1975) Electroencephalographic activity in children under enflurane anesthesia. *Acta Anesthesiol Scand* 19: 361-369
- Rougier A (1990) The epileptic focus versus the pathological focus. *Acta Neurochir (Wien) [Suppl]* 50: 1-5
- Schwarcz R, Whetsell WO Jr, Mangano RM (1983) Quinolinic acid: an endogenous metabolite that produces axon-sparing lesions in rat brain. *Science* 219: 316-318

29. Steen PA, Michenfelder JD (1979) Neurotoxicity of anesthetics. *Anesthesiology* 50: 437–453
30. Triner L, Vulliemoz Y, Verosky M, Woo S-Y (1980) Action of volatile anesthetics in brain. In: Fink BR (ed) *Molecular Mechanisms of Anesthesia*, Vol 2. Raven Press, New York, pp 229–239
31. Welty TE, Kreal RL (1985) Pentobarbital coma for treating intractable seizures in a neonate. *Clin Pharm* 4: 330–32

Correspondence and Reprints: Dr. T. Sakaki, Department of Neurosurgery, Nara Medical University, Nara, Japan.