

Coronary AngioJet catheterization for the management of dural venous sinus thrombosis

Technical note

CELSO AGNER, M.D., M.Sc., ERIC M. DESHAIES, M.D., GARY L. BERNARDINI, M.D., PH.D., A. JOHN POPP, M.D., AND ALAN S. BOULOS, M.D.

Departments of Neurology and Neurosurgery, Albany Medical Center, Albany, New York

✓ In most cases of deep venous sinus thrombosis, systemic anticoagulation represents the initial treatment of choice for preventing propagation of a clot in the dural sinuses. In patients with deep or extensive venous sinus thrombosis, a combination of treatment modalities may be required including systemic anticoagulation, selective venous thrombolysis, and mechanical thrombectomy. In the current study the authors report on a patient who presented with the acute onset of headache, vomiting, a depressed level of consciousness, and a left hemiparesis and in whom a right middle cerebral artery (MCA) territory ischemic stroke with hemorrhagic conversion was initially diagnosed. Results of diagnostic cerebral angiography demonstrated a patent right MCA and a deep venous sinus thrombosis involving most of the dural sinuses. Despite adequate systemic heparinization, the patient's neurological condition deteriorated and direct administration of alteplase into the transverse sinus in conjunction with mechanical clot disruption using a coronary AngioJet was required. Venous flow was successfully reestablished in the deep and superficial venous sinuses by using a 0.014-in exchange wire routed from the right common femoral vein through the sinuses and out the left common femoral vein. Excellent angiographic results were obtained, and the patient had recovered completely by the 7-month follow up.

KEY WORDS • alteplase • AngioJet • dural venous sinus thrombosis • endovascular stroke • thrombolysis

DURAL venous sinus thrombosis is an uncommon but potentially life-threatening condition that can be challenging to diagnose.²⁰ Putative origins for DVST include infection, systemic steroid agents, oral contraceptive agents, anemia, and severe dehydration.^{16,19–21, 23,27,28} This disease affects the dural sinuses and, in severe cases, can extend into the superficial and deep cerebral veins resulting in venous infarction with hemorrhagic conversion. It is initially managed with systemic heparinization even in the presence of hemorrhagic conversion. In refractory cases, catheter-based selective thrombolysis and mechanical clot disruption with AngioJet (Possis Medical, Minneapolis, MN) may be effective.^{1,22} We report on a patient with DVST in whom systemic heparinization failed and who required selective thrombolysis with alteplase and mechanical clot disruption with a coronary AngioJet, a clot-disrupting device integrated with a water-suctioning mechanism capable of retrieving clots located in the distal portions of the catheter. We obtained excellent angiographic and long-term clinical outcomes.

Alteplase is a recombinant fibrinolytic agent that has

been used in the management of acute strokes and situations in which acute clot disruption is indicated. It has been frequently used in endovascular surgery for the management of acute vascular occlusions with successful results. The main advantage of using recombinant fibrinolytic agents lies in the low reaction ratio and the high effectiveness in promoting thrombolysis in patients.

Illustrative Case

History and Examination. This 35-year-old healthy right-handed woman who was taking oral contraceptives had been evaluated at an outside hospital for progressive left hemiplegia and mental status changes for 5 days. An initial diagnosis of the acute onset of a right MCA territory stroke together with hemorrhagic conversion was made. She was then referred to our hospital for further neurological evaluation.

Initial physical examination revealed a lethargic normotensive female with a right gaze preference, equal and reactive pupils, left facial weakness, dense left hemiparesis, and a left extensor plantar reflex. The next day, she suffered several episodes of generalized tonic-clonic seizures requiring ventilatory support for airway protection and treatment with lorazepam and phenytoin for seizure control. A

Abbreviations used in this paper: DVST = dural venous sinus thrombosis; ICH = intracranial hemorrhage; MCA = middle cerebral artery.

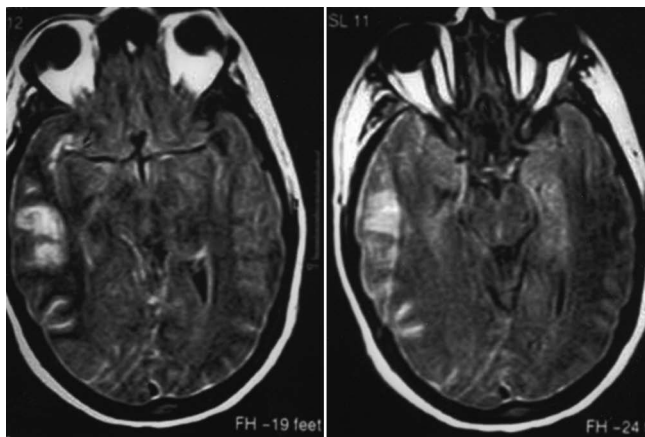


FIG. 1. Magnetic resonance images revealing an area of venous hemorrhagic infarction on the right temporo-parietal lobe.

repeated head computerized tomography scan demonstrated hemorrhagic venous infarction in the territory of the cortical draining veins from the right frontal opercular region. A magnetic resonance image of the brain confirmed our suspicion of cortical venous hemorrhage in the right hemisphere (Fig. 1). The patient became comatose and intravenous heparinization was started. Her condition did not respond to these initial measures, and rapid progression of symptoms led to selective catheterization of the dural sinuses for endovascular thrombolysis of the superior sagittal and transverse sinus thromboses.

Mechanical Thrombolysis. A diagnostic cerebral angiogram demonstrated delayed emptying of the contrast agent from the superior sagittal and transverse sinuses, consistent with extensive DVSTs. Given these findings, we accessed the dural venous sinuses by inserting No. 5 French femoral vein sheaths bilaterally because we planned on traversing the sinuses with a coronary AngioJet. To do so, we first used a 0.035-in Bentson wire (Boston Scientific, Natick, MA) and a No. 5 French Envoy catheter (Cordis Corp., Miami Lakes, FL) to engage the left jugular vein via the brachiocephalic vein. A Prowler-14 (Cordis Corp.) was advanced over a Transcend EX wire (Boston Scientific) and then advanced into the left transverse and sigmoid sinuses. The Transcend wire was exchanged for a Mailman wire. A No. 4 French XMI Coronary AngioJet was then used for mechanical thrombolysis across the sigmoid and transverse sinuses. The wire was advanced out through the contralateral femoral vein sheath. Excellent recanalization of the sinuses was obtained. Control angiograms demonstrated improved flow in the superior sagittal sinus. A microcatheter was advanced into the straight sinus, and 5 mg alteplase was administered in this sinus and the internal cerebral veins because the AngioJet could not be used in these locations.

Follow-Up Evaluation. Follow-up angiography studies demonstrated excellent recanalization of the superior sagittal, straight, transverse, and sigmoid sinuses as well as all vessels of the internal carotid artery and vertebral artery territories (Fig. 2). Systemic heparinization was followed by the administration of Coumadin and aspirin (81 mg/day) for a target therapeutic international normalized ratio of 1.5 to 2 for 6 months. The patient's left hemiparesis improved and she was discharged to the subacute rehabilitation hospital

where she regained strength in her upper and lower extremities. At the 7-month follow up, the hemiparesis had resolved, Coumadin was stopped, and aspirin (81 mg daily) was maintained.

Discussion

Hypercoagulable states and systemic disease predispose patients to strokes and other vascular pathologies such as deep venous sinus thrombosis.^{10,13,29} Overall, DVST mortality rates have been reported to range from 10 to 50%.^{3,23,24} Patients with DVST tend to fare worse clinically because of extensive venous sinus involvement, sepsis, large intracerebral venous hemorrhages, and systemic hypercoagulable states.^{4,5,9,23,30}

Einhaupl, et al.,⁸ published results of a prospective double-blind study in which they had evaluated the use of systemic heparinization compared with no treatment in two groups of patients with DVST: those with evidence of DVST and ICH, and those without ICH. Complete neurological recovery occurred in the majority of heparinized patients with DVST and no evidence of ICH, compared with a 90% chance of no clinical recovery in the nonheparinized group. When there was concomitant ICH, there was also significant neurological recovery and lower mortality rates in patients treated with anticoagulation compared with controls (69% mortality rate). Thus, the study data supported the use of anticoagulation in patients with dural sinus thrombosis independent of whether ICH was present in conjunction with venous infarction. The patients who had received systemic heparinization fared significantly better than those in the nonheparinized group, and the study was stopped prematurely. Other authors have been able to show that heparin anticoagulation is able to improve outcomes in a high proportion of cases with DVST. Endovascular management has been proposed in refractory cases.^{2,3}

Hemorrhage may delay diagnosis and increase the incidence of refractory cases. Endovascular techniques should be considered in such instances.^{4,8,11,12,17,18,25,26}

Selective catheter-based thrombolytic therapy with urokinase and alteplase has been used to manage intracranial dural sinus thrombosis since the 1980s.⁶ Although angiographic evidence of venous sinus recanalization has been provided in the majority of cases following intravenous thrombolytic therapy, there was an increased risk of ICH or systemic hemorrhage. In 1989 Higashida, et al.,¹⁴ reported on the first successful case of selective catheter-based thrombolysis with urokinase into a thrombosed superior sagittal sinus. Other authors demonstrated the effectiveness and safety of alteplase for the treatment of refractory dural sinus thrombosis.¹⁵ In situations in which systemic and selective catheter-based methods of thrombolysis fail to improve flow in the dural venous sinuses, AngioJet can be used to achieve immediate and complete recanalization of the involved sinuses. Opatowsky, et al.,²² were the first to report on mechanical thrombolysis for the management of complicated DVST in a young patient whose diffuse disease was refractory to systemic anticoagulation. There was no associated hemorrhage and the patient improved clinically, with resolution of the initial neurological deficit at the 6-month follow up. In the same year, other authors reported

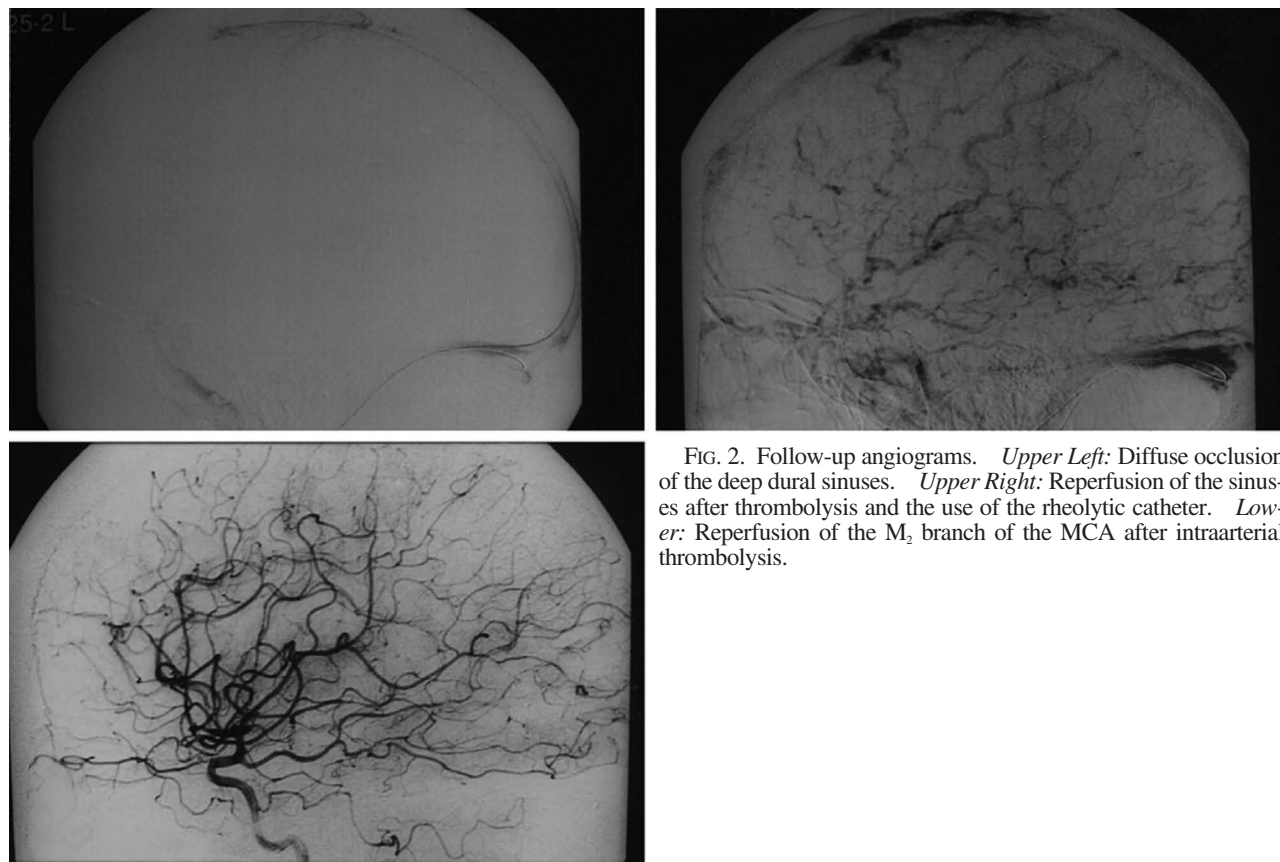

FIG. 2. Follow-up angiograms. *Upper Left:* Diffuse occlusion of the deep dural sinuses. *Upper Right:* Reperfusion of the sinuses after thrombolysis and the use of the rheolytic catheter. *Lower:* Reperfusion of the M₂ branch of the MCA after intraarterial thrombolysis.

the successful use of rheolytic catheters for the management of refractory dural sinus thrombosis.⁷

We reported on the case of diffuse sinus thrombosis, which had initially been diagnosed as a stroke with hemorrhagic conversion, that was treated with mechanical thrombectomy. Delayed medical treatment was associated with a deterioration in the patient's clinical status. Alteplase would unlikely disrupt a 1-week-old clot and mechanical thrombectomy with the coronary AngioJet was indicated. A single use of the device would unlikely allow complete sinus reperfusion, and a method was devised to permit complete opening of the superficial and deep venous sinuses involved. Successful immediate and 6-month follow-up outcomes indicated that our technique may be appropriate for diffuse subacute sinus thrombosis that had not responded to systemic anticoagulation. Furthermore, dual application of the coronary AngioJet is a possible alternative whenever direct thrombolysis does not suffice in completely reopening the dural sinuses. Decreases in morbidity and death are the goals of any treatment and, in particular, for the situation addressed in our paper.

Conclusions

The diagnosis of DVST can be challenging to make, which might lead to a delay in treatment, thus increasing risks of morbidity and death. Signs indicating sinus thrombosis can be subtle or nonexistent, complicating early identification. Prompt recognition of the disease and initiation of treatment are crucial for decreasing complications. We

reported on the excellent outcome in a patient with progressive neurological decline caused by DVST despite the systemic administration of anticoagulation agents. Although not extensively practiced, this technique should be considered in cases of extensive DVST refractory to systemic anticoagulation. A delay in the initiation of systemic anticoagulation and the severity of the disease do not preclude the use of the coronary AngioJet, although the right facility and equipment should be available to optimize application of the therapy in refractory cases.

Disclaimer

None of the authors has a financial interest in the AngioJet or Possis Medical.

References

1. Baker MD, Opatowsky MJ, Wilson JA, Glazier SS, Morris PP: Rheolytic catheter and thrombolysis of dural venous sinus thrombosis: a case series. *Neurosurgery* **48**:487–494, 2001
2. Boussier MG: Thromboses veineuses cerebrales. A propos de 76 cas. *J Mal Vasc* **16**:249–254, 1991
3. Boussier MG, Chiras J, Bories J, Castaigne P: Cerebral venous thrombosis—a review of 38 cases. *Stroke* **16**:199–213, 1985
4. Canhao P, Falcao F, Ferro JM: Thrombolytics for cerebral sinus thrombosis: a systematic review. *Cerebrovasc Dis* **15**:159–166, 2003
5. Chow K, Gobin YP, Saver J, Kidwell C, Dong P, Vineula F: Endovascular treatment of dural sinus thrombosis with rheolytic thrombectomy and intra-arterial thrombolysis. *Stroke* **31**:1420–1425, 2000

6. Del Zoppo GJ: Thrombolytic therapy in cerebrovascular disease. **Stroke** **19**:1174–1179, 1988
7. Dowd CF, Malek AM, Phatourus CC, Hemphill JC III: Application of a rheolytic thrombectomy device in the treatment of dural sinus thrombosis: a new technique. **AJNR** **20**:568–570, 1999
8. Einhaupl KM, Villringer A, Meister W, Mehraein S, Garner C, Pellkofer M, et al: Heparin treatment in sinus venous thrombosis. **Lancet** **338**:597–600, 1991
9. Ferro JM, Correia M, Pontes C, Baptista MV, Pita F: Cerebral vein and dural sinus thrombosis in Portugal: 1980–1998. **Cerebrovasc Dis** **11**:177–182, 2001
10. Gokcil Z, Odabasi Z, Vural O, Yardim M: Cerebral venous thrombosis in pregnancy: the role of protein S deficiency. **Acta Neurol Belg** **98**:36–38, 1998
11. Hanley DF, Feldman E, Borel CO, Rosenbaum AE, Goldberg AL: Treatment of sagittal sinus thrombosis associated with cerebral hemorrhage and intracranial hypertension. **Stroke** **19**:903–909, 1988
12. Hauser D, Barzilai N, Zilish M, Oliver M, Pollack A: Bilateral papilledema with retinal hemorrhages in association with cerebral venous sinus thrombosis and paroxysmal nocturnal hemoglobinuria. **Am J Ophthalmol** **122**:592–593, 1996
13. Heisteringer M, Rimpl E, Illiasch H, Turck H, Kyrle PA, Lechner K, et al: Cerebral sinus thrombosis in a patient with hereditary protein S deficiency: case report and review of the literature. **Ann Hematol** **64**:105–109, 1992
14. Higashida RT, Helmer E, Halbach VV, Hieshima GB: Direct thrombolytic therapy for superior sagittal sinus thrombosis. **AJNR** **10** (Suppl 5):S4–S6, 1989
15. Kim SY, Suh JH: Direct endovascular thrombolytic therapy for dural sinus thrombosis: infusion of alteplase. **AJNR** **18**:639–645, 1997
16. Lew D, Southwick FS, Montgomery WW, Weber AL, Baker AS: Sphenoid sinusitis. A review of 30 cases. **N Engl J Med** **309**:1149–1154, 1983
17. Lin CC, Lui CC, Tain YL: Thalamic stroke secondary to straight sinus thrombosis in a nephrotic child. **Pediatr Nephrol** **17**:184–186, 2002
18. Mehraein S, Schmidtke K, Villringer A, Valdueza JM, Masuhr F: Heparin treatment in cerebral sinus and venous thrombosis: patients at risk of fatal outcome. **Cerebrovasc Dis** **15**:17–21, 2003
19. Nagaraja D, Taly AB, Haridas VT, Veerendrakumar M, Subbakrishna DK: Heparin in haemorrhagic infarction in cerebral venous sinus thrombosis. **J Assoc Physicians India** **46**:706–707, 1998
20. Nagpal RD: Dural sinus and cerebral venous thrombosis. **Neurosurg Rev** **6**:155–160, 1983
21. Nayak AK, Karnad D, Mahajan MV, Shah A, Meisheri YV: Cerebellar venous infarction in chronic suppurative otitis media. A case report with review of four other cases. **Stroke** **25**:1058–1060, 1994
22. Opatowsky MJ, Morris PP, Regan JD, Mewborne JD, Wilson JA: Rapid thrombectomy of superior sagittal sinus and transverse sinus thrombosis with a rheolytic catheter device. **AJNR** **20**:414–417, 1999
23. Scott EB: Intracerebral thrombosis. Case report and brief clinical review. **Am J Phys Med Rehabil** **71**:119–121, 1992
24. Soleau SW, Schmidt R, Stevens S, Osborn A, MacDonald JD: Extensive experience with dural sinus thrombosis. **Neurosurgery** **52**:534–544, 2003
25. Stam J: The treatment of cerebral venous sinus thrombosis. **Adv Neurol** **92**:233–240, 2003
26. Stam J, de Bruijn S, de Veber G: Anticoagulation for cerebral sinus thrombosis. **Stroke** **34**:1054–1055, 2003
27. van Amerongen RH, Moretta AC, Gaeta TJ: Severe hypernatremic dehydration and death in a breast-fed infant. **Pediatr Emerg Care** **17**:175–180, 2001
28. van der Stege JG, Engelen MJ, van Eyck J: Uncomplicated pregnancy and puerperium after puerperal cerebral venous thrombosis. **Eur J Obstet Gynecol Reprod Biol** **71**:99–100, 1997
29. van Krimpen J, Leebeek FW, Dippel DW, Gomez Garcia E: Prothrombin gene variant (G20210A) in a patient with cerebral venous sinus thrombosis. **Clin Neurol Neurosurg** **101**:53–55, 1999
30. Zakharov AG, Saribekian AS, Sharifulin FA: Spontaneous subarachnoidal'noe krovoizliianie u bol'noi s ostrym trombozom lateral'nykh venoznykh sinusov mozga (nabliudenie). **Zh Vopr Neurokhir Im NN Burdenko**:29–32, 1997

Manuscript received June 2, 2004.

Accepted in final form November 3, 2004.

Address reprint requests to: Alan S. Boullos, M.D., Department of Surgery, Albany Medical Center, Albany, New York 12208. email: boullosa@mail.amc.edu.