
Clinical Communications: OB/GYN

HEADACHE AND SEIZURE IN A YOUNG WOMAN POSTPARTUM

Mini R. DeLashaw, MD, PhD, Thomas L. Vizioli Jr., MD, and Francis L. Counselman, MD

Department of Emergency Medicine, Eastern Virginia Medical School and Emergency Physicians of Tidewater, Norfolk, Virginia
Reprint Address: Francis L. Counselman, MD, Department of Emergency Medicine, Raleigh Building, Room 304, 600 Gresham Dr.,
Norfolk, VA 23507

□ **Abstract**—A 19-year-old woman, 8 days postpartum, presented to the Emergency Department (ED) with a chief complaint of headache, decreased vision, and agitation. Past medical history was unremarkable. Physical examination was remarkable only for dry mucous membranes, decreased visual acuity, and trace pedal edema bilaterally. While in the ED, the patient experienced a generalized tonic-clonic seizure. Computed tomography (CT) scan of the head was suspicious for venous infarction. Magnetic resonance imaging (MRI) and MR venography revealed sagittal sinus and left transverse sinus thrombosis. The risk factors, clinical presentation, diagnostic evaluation, and management of cerebral venous thrombosis are reviewed. © 2005 Elsevier Inc.

□ **Keywords**—seizure; cerebral venous thrombosis; sagittal sinus thrombosis; headache; transverse sinus thrombosis

INTRODUCTION

Cerebral venous thrombosis (CVT) is a relatively rare condition. The majority of patients are women, with a median age of 37 years. Common risk factors among women include use of oral contraceptives, pregnancy, and the postpartum period. Typical signs and symptoms include headache, seizure, paresis, and mental status changes. Although computed tomography (CT) scan of the head is frequently used as a screening study, magnetic resonance imaging with magnetic resonance venog-

raphy is considered the best noninvasive method of diagnosing CVT. We present a patient with a classic presentation of CVT.

CASE REPORT

A 19 year-old woman, gravida 1, para 1, presented to the Emergency Department (ED) with the chief complaint of headache and decreased vision. On the night before presentation, the patient gradually developed a generalized headache and took one of her boyfriend's acetaminophen/hydrocodone tablets. Upon awakening on the morning of presentation, she described her headache as greater in intensity. The family became concerned with her symptoms, including her increasing agitation, and called emergency medical services (EMS) for transport to the ED.

The patient described her headache as generalized, dull, constant, and increasing in intensity. She denied any exacerbating or relieving factors. She had no previous history of migraines or other headaches. The only associated symptom was decreased vision. She had some light perception, with only darker and lighter shadows visible.

The patient denied head injury or trauma. She denied tinnitus, sore throat, or upper respiratory tract infection symptoms. She denied chest pain, shortness of breath, nausea or vomiting. Other than the headache and visual

Clinical Communications: Obstetrics and Gynecology is coordinated by Colleen Campbell, MD, of the University of California San Diego Medical Center, San Diego, California

RECEIVED: 23 April 2004; FINAL SUBMISSION RECEIVED: 15 November 2004;
ACCEPTED: 23 February 2005

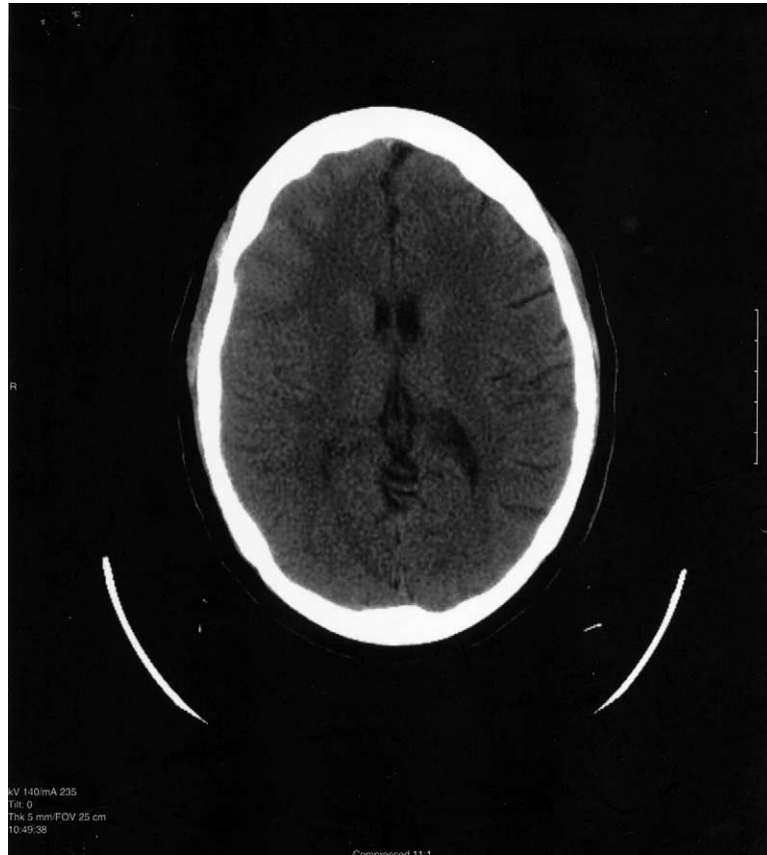

Figure 1. A nonenhanced CT scan of the brain demonstrates loss of cortical sulci in the right frontal, parietal and temporal lobes.

symptoms, there were no other neurologic complaints. She denied any motor weakness or paresthesias.

The past medical history was significant only for a spontaneous vaginal delivery 8 days prior, with decreasing lochia and no vaginal bleeding. The pregnancy and delivery were without complications.

The patient denied alcohol, tobacco, or illicit drug use.

Physical examination revealed an awake and alert woman. Vital signs were: temperature 38.8°C (101.9°F) rectally; pulse 107 beats/min; respiratory rate 20 beats/min; blood pressure 171/113 mm Hg; and an oxygen saturation of 98% on room air. The head and neck examination was remarkable only for dry mucous membranes. A fundoscopic exam was not performed. The neck was supple with full range of motion and without lymphadenopathy. Cardiovascular examination revealed a regular rhythm, without murmurs, rub or gallop. The lungs were clear to auscultation. Examination of the abdomen was normal. The patient had trace pedal edema bilaterally. The neurologic examination revealed an awake and alert patient. Visual acuity was to light perception only. All other cranial nerves were intact. Upper and lower

extremity motor strength was 5/5 and reflexes were 2+ and symmetrical.

Shortly after completion of the physical examination, the patient experienced a generalized tonic-clonic seizure, which terminated immediately after the administration of lorazepam (Ativan) 2 mg i.v. The patient was also given magnesium sulfate 4 g i.v. for suspected postpartum eclampsia.

The serum white blood cell (WBC) count was $9.0 \times 10^3/\mu\text{L}$, with a normal differential. She was slightly anemic, with a hemoglobin of 9.4g/dL and a hematocrit of 28.9%; the platelet count was normal. Electrolytes, glucose, BUN and creatinine were all within normal limits. Urinalysis demonstrated 15 ketones, 1 to 5 red blood cells, 1 to 5 white blood cells, no protein and few bacteria. A urine drug screen was positive for opiates only. Coagulation studies were normal. A portable chest X-ray study was normal. A computed tomography (CT) scan of the head without contrast demonstrated loss of the cortical sulci in the right frontal, parietal and temporal lobes (Figure 1). Magnetic resonance imaging (MRI) of the brain and MR venography were recommended due to suspicion for venous infarction. The MRI demon-

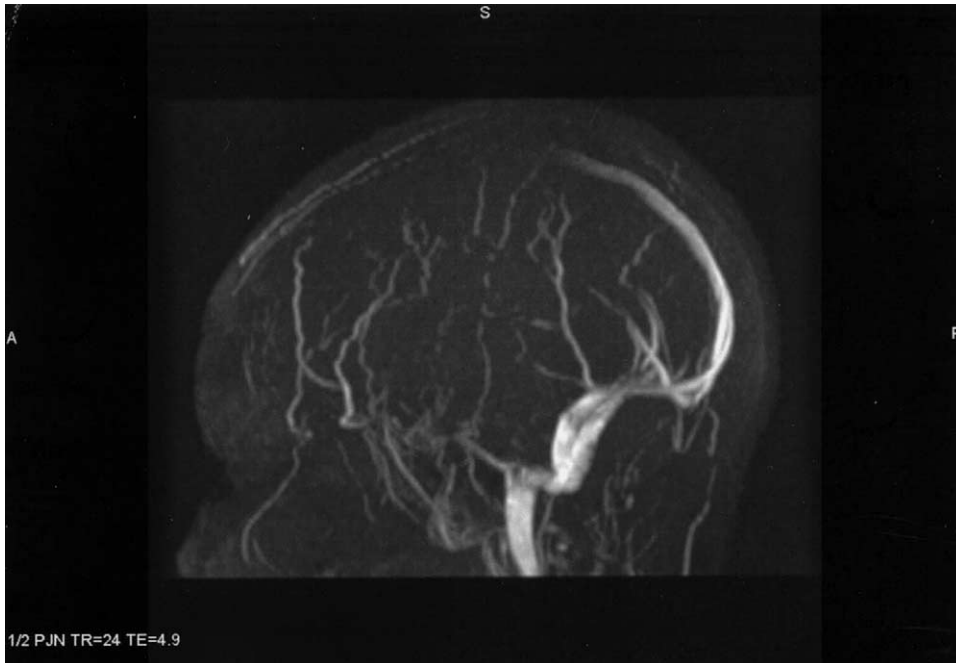


Figure 2. A MR venogram of the brain reveals a relative lack of signal in the superior aspect of the sagittal sinus, consistent with a sagittal sinus thrombosis.

strated increased signal intensity on T2 in the gyri of the frontal lobes bilaterally and in the gray white junction of the occipital lobes bilaterally, suggestive of sagittal sinus and left transverse sinus thrombosis. The MR venogram showed relative lack of signal in the superior sagittal sinus, consistent with thrombus (Figure 2).

After returning from the Radiology department, the patient experienced a second generalized tonic-clonic seizure; this resolved spontaneously. The patient was given phenytoin (Dilantin) 18 mg/kg loading dose i.v. and the Obstetrics and Gynecology and Neurology services were consulted. Hypercoagulation studies were ordered, including Protein S, Protein C, antiphospholipid antibodies, Factor V Leiden and antithrombin III levels.

The patient was postictal on examination by Neurology, but arousable. No focal deficits were identified. In view of the MR venogram findings, the patient received an intravenous heparin bolus and was started on a drip. The patient was admitted to the intensive care unit (ICU).

The patient was continued on Dilantin. In the ICU, an electroencephalogram (EEG) demonstrated only moderate generalized slowing; no epileptiform discharges were noted. On day two, the patient was started on warfarin (Coumadin). Once the International Normalized Ratio reached therapeutic levels, the heparin was discontinued. The hypercoagulation studies were all within normal limits. In view of the patient's persistent high blood pressure, she was started on valsartan (Diovan) 80 mg p.o. daily with

good results. The patient continued to improve and remained without seizure activity in the hospital. The patient was discharged on day five on Diovan, Dilantin and Coumadin, with Neurology follow-up.

DISCUSSION

Cerebral venous thrombosis (CVT) is a relatively rare condition, but the diagnosis was made in our patient after an unexplained seizure and a suspicious head CT scan prompted further evaluation using MRI. Although useful in this case, CT scans are read as normal or nondiagnostic in up to 30% of patients with CVT (1). The diagnosis is based on presenting symptoms, past medical history, and the presence of risk factors. Patients with risk factors and classic symptoms of CVT should receive further evaluation regardless of initial CT scan results to avoid missing this potentially fatal condition.

The International Study on Cerebral Vein and Dural Sinus Thrombosis (ISCVT), a recent multinational, multicenter prospective study that followed 624 patients with CVT, identified common characteristics, risk factors, and prognosis (2). According to the ISCVT trial, 79% of patients diagnosed with CVT are white and 75% are women, and the median age is 37 years. Thrombophilic disorders (protein C and Protein S deficiency, antithrombin III deficiency, activated protein C resistance, factor V Leiden mutation, antiphospholipid antibody, nephrotic

syndrome, and hyperhomocysteinemia) account for 34% of patients with CVT. Patients with active infections (i.e., rhinosinusitis, meningitis, otitis) account for 12%. Among female patients, 54% are on oral contraceptives, 14% are postpartum, and 6% are pregnant. Other less common predisposing conditions include trauma, malignancies, hematologic disorders, vasculitis and systemic inflammatory disorders. Thirteen percent of patients with CVT have no identifiable risk factor, whereas 44% have more than one risk factor (2). Among peripartum women, pregnancy-related hypertension, older age, infections, and cesarean delivery are common risk factors associated with CVT (3–5). Changes that contribute to a prothrombotic state in pregnancy and puerperium include a decrease in inhibitors of protein S and increased levels of fibrinogen, factor VII, factor VIII, factor X, and protein C inhibitors (6). Factor V Leiden and Factor II gene mutations have also been shown to play a role in CVT development in patients taking oral contraceptives (7).

The most frequent signs and symptoms of CVT include headache (88%), seizure (39%), paresis (37%), papilledema (28%), mental status changes (22%), visual changes, cranial nerve deficits, and focal weakness (2,8). In retrospect, our patient presented in a classical fashion for CVT. The course is often indolent, with patients presenting days to weeks after the onset of symptoms. Presentations vary according to the location and size of the thrombosis, the rate of development, and the amount of collateral venous drainage (2,9). Women with CVT associated with pregnancy and puerperium present with similar symptoms, neurological findings, and neuroimaging results when compared to patients with CVT secondary to other causes. However, obstetric patients tend to be younger and present with a more acute onset of symptoms, similar to our patient (10). The diagnosis of CVT should be considered in women with any neurologic symptoms during pregnancy or puerperium (8).

The ED evaluation of a patient suspected of having a CVT begins with a thorough history and physical examination. Other diagnoses that should be considered include simple headache, intracranial hemorrhage, meningitis, aneurysm, and pseudotumor cerebri. In postpartum patients who have received epidural anesthesia, intracranial hypotension from a cerebrospinal fluid (CSF) leak should be considered. Likewise, although postpartum patients who present with seizures are more likely to have eclampsia, seizures secondary to CVT also should be considered. Physical examination findings of CVT most often include papilledema. Neurologic findings range from subtle deficits to profound coma. A classic triad of headache, papilledema, and high opening pressures on lumbar puncture has been described, but is also present in patients with pseudotumor cerebri (9).

Lumbar puncture will usually yield high opening

pressures. Cerebrospinal fluid analysis is useful for ruling out an infectious etiology of a headache and is usually normal in patients with CVT.

Quantitative D-dimer measurement recently has been proven to be useful for the evaluation of suspected venous thrombosis and pulmonary embolism. Lalive et al. investigated the utility of quantitative D-dimer levels in 54 patients suspected of having a CVT (11). Twelve of the 54 enrolled patients were found to have CVT, and 10 of the 12 had D-dimer levels greater than 500 ng/mL (sensitivity of 83% and negative predictive value of 95%). The two patients with CVT and a D-dimer less than 500 ng/mL had a history of headache lasting greater than 30 days. In the 42 patients without CVT, only four had D-dimer levels greater than 500 ng/mL (specificity of 90% and positive predictive value of 71%). The authors concluded that patients with less than 1 month of symptoms and a D-dimer value less than 500 ng/mL are unlikely to have CVT. Alternatively, further workup is warranted in all patients with symptoms consistent with CVT and D-dimer level greater than 500 ng/mL (11). This test is of limited value, however, in pregnant patients. D-dimer has been shown to increase gradually during the course of pregnancy (12). Chablotz et al. demonstrated that for the time period of the 35th week of pregnancy through delivery, D-dimer values are consistently greater than 500 ng/mL (12).

Although laboratory values may contribute to the clinical picture, neuroimaging is the most effective tool for diagnosing CVT. Angiography is considered the gold standard, but is not commonly used unless endovascular thrombolytics are employed for clot dissolution. CT scans of the head are typically obtained in the initial workup, but are not sensitive or specific enough to safely exclude the diagnosis. Findings suggestive of CVT on CT scan include evidence of infarction, hemorrhage, or edema that do not correspond to an arterial distribution. These and other characteristic signs on CT scan may suggest CVT, but are not diagnostic, and additional imaging is usually required. Magnetic resonance imaging with magnetic resonance venography is both sensitive and specific, and is considered the best noninvasive method of diagnosing CVT. Using this imaging method, the thrombus and subsequent changes in flow patterns can be directly visualized (13).

All patients should receive a hypercoagulation workup after being admitted. Even if an etiology for CVT is obvious, 44% of patients have more than one risk factor, including undiagnosed coagulation abnormalities (2).

Neurology should admit these patients. The treatment of choice for CVT is heparin, followed by long-term anticoagulation with warfarin. The recommended length of anticoagulation is 3 to 6 months, or longer if an underlying prothrombotic condition is still present (1).

Patients should be immediately considered for anticoagulation regardless of the duration of symptoms, severity of neurologic deficit, or presence of intracranial hemorrhage due to the potential for full recovery. These patients, when compared to those with arterial strokes, typically respond well to treatment (1). Symptomatic treatment may be accomplished with analgesics, anticonvulsants, medications to decrease intracranial pressure (i.e., mannitol, steroids, acetazolamide, and diuretics), and treatment of the prothrombotic condition.

The use of systemic or local thrombolytics has not been studied in a randomized controlled trial, but results from many case reports suggest that thrombolytics are useful, especially in patients whose condition is refractory to anticoagulation (14).

According to results from the ISCVT trial, the long-term prognosis for patients is better than previously reported, with only 13% of patients dying or having a poor neurologic outcome (2). Factors associated with increased morbidity and mortality include coma, hemorrhage on the admission head CT scan, malignancy, male gender, age greater than 37 years, mental status changes, thrombosis of a deep cerebral vein, and a concurrent central nervous system infection. Patients identified with these risk factors may benefit from local thrombolysis or procedures aimed to reduce intracranial pressures (2). In a retrospective study by Cantu and Barinagarrementeria, mortality of CVT in pregnancy and puerperium was found to be significantly less than CVT in other patient groups. Although the initial symptoms and severity of illness were similar in both groups, the final outcome was good in 80% of patients with obstetric etiologies compared with 58% of patients with other causes. The mortality rates were 9% and 33%, respectively (10).

Cerebral venous thrombosis is a rare, but potentially fatal condition that may be easily dismissed as a simple

headache. The diagnosis should be considered in women with any neurological symptoms during pregnancy or puerperium. Awareness of risk factors and common presenting symptoms will help identify patients who require neuroimaging and who may benefit from the prompt administration of anticoagulation or thrombolysis.

REFERENCES

1. Bousser MG. Cerebral venous thrombosis: diagnosis and management. *J Neurol* 2000;247:252–8.
2. Ferro JM, Canhao P, Starn J, Bousser MG, Barinagarrementeria F. Prognosis of cerebral vein and dural sinus thrombosis: results of the International Study on Cerebral Vein and Dural Sinus Thrombosis (ISCV1). *Stroke* 2004;35:664–70.
3. Lanska DJ, Kryscio RJ. Factors for peripartum and postpartum stroke and intracranial venous thrombosis. *Stroke* 2000;31:1274–82.
4. Lanska DJ, Kryscio RJ. Stroke and intracranial venous thrombosis during pregnancy and puerperium. *Neurology* 1998;51:1622–8.
5. Lanska DJ, Kryscio RJ. Peripartum stroke and intracranial venous thrombosis in the National Hospital Discharge Survey. *Obstet Gynecol* 1997;89:413–8.
6. Martinelli I, Sacchi E, Landi G. High risk of cerebral venous thrombosis in carriers of prothrombotic gene mutation and in users of oral contraceptives. *N Engl J Med* 1988;338:1793–7.
7. Vandenbroucke J. Cerebral sinus thrombosis and oral contraceptive. *BMJ* 1998;317:878–9.
8. Fink IN, McAuley DL. Cerebral venous sinus thrombosis: a diagnostic challenge. *Int Med J.* 2001;31:384–90.
9. Ameri A, Bousser MG. Cerebral venous thrombosis. *Neurol Clin* 1992;10:87–111.
10. Cantu C, Barinagarrementeria F. Cerebral venous thrombosis associated with pregnancy and puerperium. Review of 67 cases. *Stroke* 1993;24:1880–4.
11. Lalive PH, de Moerloose P, Lovblad K, et al. Is measurement of D-dimer useful in the diagnosis of cerebral venous thrombosis? *Neurology* 2003;61:1057–60.
12. Chabloz P, Reber G, Boehlen F, et al. TAFI antigen and D-dimer levels during normal pregnancy and at delivery. *Br J Haematol* 2001;1115:150–2.
13. Patel MR, Edelman RR. MR angiography of the head and neck. *Top Magn Reson Imaging* 1996;8:345–65.
14. Starn J, DeBruijn SF, DeVeber G. Anticoagulation for cerebral sinus thrombosis. *Cochrane Database Syst Rev* 2002;4:CDO02005.