

D. Mandellos • G. Limbitaki • A. Papadimitriou • D. Anastasopoulos

Cerebral autosomal dominant arteriopathy with subcortical infarcts and leukoencephalopathy (CADASIL) in a Greek family

Received: 4 April 2005 / Accepted in revised form: 14 July 2005

Abstract Cerebral autosomal dominant arteriopathy with subcortical infarcts and leukoencephalopathy (CADASIL) is an adult-onset inherited disease, characterised by recurrent strokes, migraine and cognitive impairment. We present the first Greek family with CADASIL, caused by the R153C mutation at exon 4 of the Notch3 gene. A member of this family carrying this mutation was also found to be heterozygotic for the MTHFR mutation, factor V Leiden mutation and had low serum levels of antithrombin III, thus resulting in the appearance of recurrent strokes and thrombotic episodes since his early adulthood. The co-existence of these thrombophilic disorders with CADASIL in a single person poses serious therapeutic dilemmas, as the administration of anticoagulant agents may correlate with increased risk of potentially fatal intracerebral haemorrhage.

Key words CADASIL • Greek • Leiden • MTHFR • Mutation

Introduction

Cerebral autosomal dominant arteriopathy with subcortical infarcts and leukoencephalopathy (CADASIL) is an adult-onset inherited disease, characterised by recurrent strokes, migraine and dementia. It was first described by Van Bogaert in 1955 [1]. This syndrome is caused by mutations in the Notch3 gene, a large gene with 33 exons, located at 19p12, which encodes a transmembrane receptor involved in signalling events that control cell fate decisions during embryonic development.

Notch3 receptors contain a large number of epidermal growth factor-like (EGF) repeats in their external domains. Over 50 mutations have been reported until now, which, in their vast majority, result in the insertion or removal of a cysteine residue in the EGF repeats of the Notch protein [2]. As a consequence of these changes, an accumulation of granular osmiophilic material (GOM) is observed in the area surrounding vascular smooth muscle cells of small- and middle-sized arteries [3–5], but the mechanism involved in the disease pathogenesis remains elusive.

The mean age of onset is 36.7 years, with a range of 10–59 [6]. The most common presentation is ischaemic episodes, TIA or stroke – usually lacunar infarcts, which are observed in 85% of symptomatic individuals. Cognitive deficits are the second most common feature, found in about 60% of patients, followed in frequency by migraine with aura, which is an early manifestation of the disease, and mood disorders [7]. Patients may also suffer gait disturbance and poor sphincter control. Recurrent strokes usually lead to pseudobulbar palsy.

Brain MRI reveals extensive abnormalities of the white matter, appearing as hyperintensities at T2 weighted and fluid attenuation inversion recovery (FLAIR) sequences. The periventricular white matter appears more involved than the subcortical. All cerebral lobes have lesions, but there is a predilection for the anterior temporal lobe [8]. The external capsule is typically involved. Internal cap-

D. Mandellos • D. Anastasopoulos (✉)
Department of Physiology
School of Nursing
University of Athens
8 Tetrapoleos Str, Goudi
Athens 11527, Greece
e-mail: danastas@nurs.uoa.gr

G. Limbitaki • A. Papadimitriou • D. Anastasopoulos
“Henry Dunant” Hospital of the Greek Red Cross
107 Mesogion Avenue, Athens 11526, Greece

sule, basal ganglia, brainstem, corpus callosum and cerebellum may have lesions as well [9]. Cerebral microbleeds are also found in various parts of the brain, usually at the cortical and subcortical regions (38% of patients), white matter (20%), brainstem (14%) and thalamus (13%) [10]. These microbleeds are demonstrated as focal areas of signal loss on gradient-echo images. Microbleeds are age related and they appear more frequently in patients with the R153C mutation of the *Notch3* gene and in patients who are treated with antiplatelet agents [11]. These patients are at increased risk of intracerebral haemorrhage.

The diagnosis is established by mutation detection, or skin biopsy demonstrating the deposition of GOM in the skin arterioles.

CADASIL is probably underdiagnosed because of its recent description and the large number of mutations that make mutational analysis difficult to perform. Some diagnostic strategies have been proposed, suggesting that mutational analysis should start with a screening for exon 4 mutations and if this is proved to be negative, proceed to screening for exons 3, 5 and 6 [12]. Knowing the mutational spectrum present in an area certainly makes diagnosis of CADASIL easier.

Surprisingly, there has been no report in the literature, up till now, of Greek CADASIL cases, giving birth to discussions about whether the disease is underdiagnosed or the prevalence of the disorder is smaller in Greece. In this report we will present the first Greek family diagnosed as having CADASIL.

Case reports

The pedigree of this family is shown in Fig. 1. Note that the pedigree is restricted to a part of the family for which clear information could be obtained, as only three members underwent brain MRI examination and two of them mutational analysis.

I:1 died at the age of 50 because of multiple strokes. During the last years of his life he was demented. He had seven elder brothers and sisters. Four of them had multiple strokes and they all died between the ages of 50 and 60 years, before the era of CT and MRI.

II:1 is a 61-year-old female patient with an unremarkable history, neurological and neuropsychological examination. Brain MRI examination, performed because her son (III:1) had suffered a stroke and was previously diagnosed to have CADASIL, revealed typical, multiple white matter lesions involving the external capsule bilaterally.

II:2 is a 58-year-old female who had experienced migraine attacks with typical visual aura since the age of 21. Neurological examination was unremarkable. Neuropsychological evaluation revealed a Mini Mental State Examination (MMSE) score of 27/30. Brain MRI

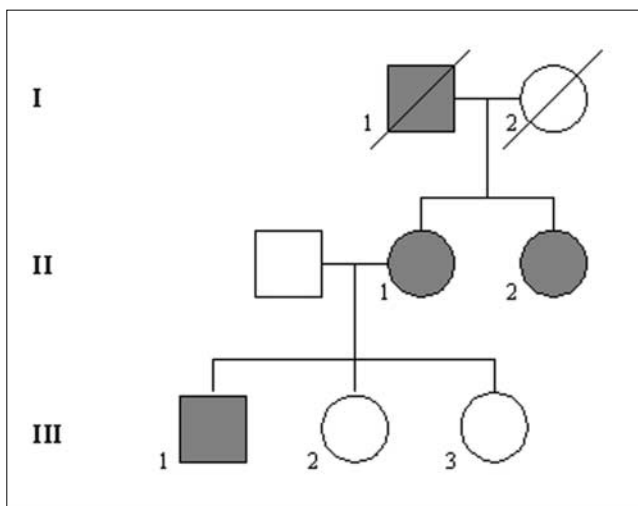


Fig. 1 Genealogy of the family. Affected members are represented with filled symbols (circles for females). I:1 had 7 brothers and sisters who are not presented here because we could not obtain a full description of their families

showed typical bilateral areas of hyperintensity in the white matter, which did not involve the brainstem.

III:1 is a 36-year-old male patient. At the age of 24 he was hospitalised because of deep vein thrombosis of the left lower limb. At 30 years of age he had a sudden episode of abdominal pain. The diagnosis of mesenteric artery occlusion was established. He underwent extensive serological testing for thrombophilic disorders and was found to be heterozygote for the C677T mutation of the gene that codes the synthesis of the 5,10-methylenetetrahydrofolate reductase (MTHFR), as well as a factor V Leiden carrier. He was also found to have low serum levels of antithrombin III. Since then he has been receiving asenocoumarol with a target INR of 3.0. Because of increased serum homocysteine levels (13.5 $\mu\text{mol/l}$), he had been given folate. Five years later he experienced a sudden-onset numbness of the left arm and left facial area and disorientation. Neurological examination demonstrated mild left hemiparesis and disorientation. He underwent brain MRI, which showed multiple sites of T2 and FLAIR hyperintense white matter lesions. His MMSE score was 25/30, while he performed worse in Symbol Digit Modalities Test (SDMT) and digit span backwards, revealing mild deficits in the speed of processing and working memory. His short-term memory was not affected.

II:2 and III:1 underwent mutational analysis for CADASIL. DNA was extracted from leukocytes and PCR amplification of *notch3* exons was carried out. Amplification of *notch3* exons 2, 3, 4 and 5 was then sequenced (Prof. Seelig, Karlsruhe, Germany). They all gave their written consent. Exons 2, 3, 4 and 5 of the *Notch3* gene were analysed. Both were found to be heterozygous for the R153C mutation at exon 4. The father of

III:1 had been previously examined and was found to be a carrier of factor V Leiden and MTHFR mutations. Up till now he has not presented with any thrombotic events.

Discussion

The family presented is the first Greek family with proven CADASIL. The mutation found is the 7th most common among German CADASIL patients [7], and is different from the mutations usually found in the Italian population [13]. The history, clinical examination and MRI findings are suggestive of the diagnosis. However there is a history of deep vein thrombosis and mesenteric artery occlusion in patient III:1, which had been attributed to the co-existence of the MTHFR and factor V Leiden mutations, as well as the low serum levels of antithrombin III.

MTHFR is an enzyme necessary for the production of methylenetetrahydrofolate (MTHF), an essential cofactor, along with vitamin B12 (cobalamin), of methionine synthase which remethylates homocysteine to produce methionine. Subjects with an MTHFR mutation usually have higher than normal levels of serum homocysteine and low levels of folic acid. This has been linked with a higher prevalence of thrombotic events. MTHFR mutations are rather common in the general population and are thought to be a kind of genetic polymorphism rather than a disease.

Low plasma levels of antithrombin III are found in 1 out of 2000 individuals. Slightly lower than normal levels of antithrombin III increase the risk of thrombosis significantly. After an episode of thromboembolism, patients with this disorder should be placed on oral anticoagulants for life, in order to prevent recurrent thrombosis.

Patients that are heterozygous for the factor V Leiden mutation are 3% of the population worldwide. Carriage of this mutation increases the risk of thromboembolism sevenfold. Patients with this disorder and a history of thrombotic events should be treated with anticoagulant agents in order to prevent further complications. Coinheritance of disorders like those found in our patient (III:1), resulting in increased risk of vascular events, may have conceivably additive effects [14, 15]. They may have contributed to the fact that only this patient has suffered a cerebral stroke, while his mother and aunt have not yet.

In the case of patient III:1, the prescription of such a therapy became a matter of discussion, because CADASIL patients are often found to have cerebral microbleeds, especially when carrying the R153C mutation of the *Notch3* gene. There are cases described in the literature of CADASIL patients who died because of intracerebral haemorrhage after beginning anticoagulant therapy [16–18]. On the other hand, this unfortunate patient had already experienced, apart from the strokes, two thrombotic events, one of which was life threatening. Considering the benefit to risk ratio, we did not discontinue the oral anticoagulant treat-

ment, as it has not led to haemorrhagic events until the time of MRI investigations.

References

1. Van Bogaert L (1955) Encephalopathie sous-corticale progressive (Binswanger) a evolution rapide chez deux soeurs. *Med Hellen* 24:961–972
2. Artavanis-Tsakonas S, Rand MD, Lake RJ (1999) Notch signaling: cell fate control and signal integration in development. *Science* 284:770–776
3. Bergmann M, Ebke M, Yuan Y, Bruck W, Mugler M, Schwendemann G (1996) Cerebral autosomal dominant arteriopathy with subcortical infarcts and leukoencephalopathy (CADASIL): a morphological study of a German family. *Acta Neuropathol (Berlin)* 92:341–350
4. Rubio A, Rifkin D, Powers JM et al (1997) Phenotypic variability of CADASIL and novel morphologic findings. *Acta Neuropathol (Berlin)* 94:247–254
5. Ruchoux MM, Guerouaou D, Vandenhaute B, Pruvo JP, Vermersch P, Leys D (1995) Systemic vascular smooth muscle cell impairment in cerebral autosomal dominant arteriopathy with subcortical infarcts and leukoencephalopathy. *Acta Neuropathol* 89:500–512
6. Desmond DW, Moroney JT, Lynch T, Chin S, Mohr JP (1999) The natural history of CADASIL. A pooled analysis of previously published cases. *Stroke* 30:1230–1233
7. Dichgans M (2002) Cerebral autosomal dominant arteriopathy with subcortical infarcts and leukoencephalopathy: phenotypic and mutational spectrum. *J Neurol Sci* 203–204:77–80
8. van Den Boom R, Lesnik Oberstein SA, van Duinen SG, Bornebroek M, Ferrari MD, Haan J, van Buchem MA (2002) Subcortical lacunar lesions: an MR imaging finding in patients with cerebral autosomal dominant arteriopathy with subcortical infarcts and leukoencephalopathy. *Radiology* 224:791–796
9. Chawda SJ, De Lange RPJ, Hourihan MD, Halpin SFS, Clair DS (2000) Diagnosing CADASIL using MRI: evidence from families with known mutations of *Notch 3* gene. *Neuroradiology* 42:249–255
10. Dichgans M, Holtmannspötter M, Herzog J, Peters N, Bergmann M, Yousry TA (2002) Cerebral microbleeds in CADASIL. A gradient-echo magnetic resonance imaging and autopsy study. *Stroke* 33:67–71
11. Lesnik Oberstein SAJ, van den Boom R, van Buchem MA, van Houwelingen HC, Bakker E, Vollebregt E, Ferrari MD, Breuning MH, Haan J for the Dutch CADASIL Research Group (2001) Cerebral microbleeds in CADASIL. *Neurology* 57:1066–1070
12. Markus HS, Martin RJ, Simpson MA, Dong YB, Ali N, Crosby AH, Powell JF (2002) Diagnostic strategies in CADASIL. *Neurology* 59:1134–1138
13. Dotti MT, Federico A, Mazzei R, Bianchi S, Scali O, Conforti FL, Spovieri T, Guidetti D, Aguglia U, Consoli D, Pantoni L, Sarti C, Inzitari D, Quattrone A (2005) The spectrum of *Notch3* mutations in 28 Italian CADASIL families. *J Neurol Neurosurg Psychiatry* 76:736–738
14. Pantoni L, Sarti C, Pescini F, Bianchi S, Bartolini L, Nencini

- P, Basile AM, Lamassa M, Kalaria RN, Dotti MT, Federico A, Inzitari D (2004) Thrombophilic risk factors and unusual clinical features in three Italian CADASIL patients. *Eur J Neurol* 11:782–787
15. Singhal S, Bevan S, Barrick T, Rich P, Markus H (2004) The influence of genetic and cardiovascular risk factors on the CADASIL phenotype. *Brain* 127:2031–2038
16. Baudrimont M, Dubas F, Joutel A, Tournier-Lasserre E, Bousser M-G (1993) Autosomal dominant leukoencephalopathy and subcortical ischemic stroke. *Stroke* 24:122–125
17. Maclean AV, Woods R, Alderson LM, Salloway SP, Correia S, Cortez S, Stopa EG (2005) Spontaneous lobar haemorrhage in CADASIL. *J Neurol Neurosurg Psychiatry* 76:456–457
18. Sourander P, Walinder J (1997) Hereditary multi-infarct dementia. *Acta Neuropathol* 39:247–254