



# Pleomorphism of the clinical manifestations of neurocysticercosis

R. Patel, Sanjeev Jha\*, R.K. Yadav

Neurology Department, Sanjay Gandhi PGIMS, Lucknow, India

Received 15 July 2004; received in revised form 23 June 2005; accepted 23 June 2005  
Available online 7 October 2005

## KEYWORDS

Neurocysticercosis;  
Kluver–Bucy syndrome;  
Weber's syndrome;  
Dementia;  
Cortical blindness;  
India

**Summary** Neurocysticercosis (NCC) remains a major public health problem in developing countries as it is the most common helminthic infection of the central nervous system. Clinical manifestations are non-specific and pleomorphic. Case reports on uncommon presentations of NCC are few. We report six interesting cases of NCC with unusual clinical presentation that demonstrate this spectrum of pleomorphism. These include extrapyramidal disease (parkinsonism and focal dystonia), Kluver–Bucy syndrome, Weber's syndrome, dementia and cortical blindness. The clinical details and possible mechanisms for the uncommon presentations are also discussed. Thus, a high level of suspicion should be kept for NCC, especially in endemic zones and developing countries.

© 2005 Published by Elsevier Ltd on behalf of Royal Society of Tropical Medicine and Hygiene.

## 1. Introduction

Neurocysticercosis (NCC) is the most common parasitic infection of the central nervous system. The incidence of NCC is increasing in non-endemic areas of the world, including India, owing to immigration from endemic areas (Sawhney et al., 1998; Singhi and Singhi, 2004). NCC occurs when ingested ova develop into larvae (cysticerci) and lodge in soft tissues, especially skin, muscle and brain. The cyst may be located anywhere in the brain, and clinical features depend on its location (Del Brutto et al., 1992; Sawhney et al., 1998). Clinical manifestations are pleomorphic, depending on the number,

size and topography of lesions and on the severity of the host immune response to the parasite, which varies according to the stage of cysticercosis (Del Brutto et al., 1992; Singhi and Singhi, 2004). Cysticerci are fluid-filled oval cysts, approximately 1–2 cm in diameter, with an internal scolex. There are four stages in the development of NCC: vesicular, colloidal, granular and calcified. Each stage is characterised by specific changes within the parasite and in the surrounding brain parenchyma, with a distinctive appearance on neuroimaging. In the vesicular stage, the vesicular wall of the parasite is translucent and fluid is transparent with viable invaginated scolex. The brain parenchyma shows a scarce inflammatory reaction. Neuroimaging reveals hypodense cystic lesions showing the scolex; following contrast medium administration

\* Corresponding author.

E-mail address: sjha@sgpgi.ac.in (S. Jha).

there is no abnormal enhancement. In the colloidal stage, the vesicular wall is thick with viscous, turbid fluid and a scolex showing signs of hyaline degeneration. The brain parenchyma shows an intense inflammatory reaction and a thick capsule is formed around the parasite. The lesion is isodense or hypodense, surrounded by oedema and ring-like or nodular enhancement on contrast-enhanced imaging. In the granular stage, there is a thick vesicular wall with a degenerated scolex, astrocytic gliosis around the cyst, and a hyperintense nodule that enhances following contrast medium administration. The calcified stage involves transformation of the parasite into a small, mineralised nodule. The brain parenchyma shows intense gliosis. Imaging reveals a small calcification (Del Brutto and Sutelo, 1988).

Seizures are the commonest clinical features. In addition, other clinical features include raised intracranial pressure, syndromes of cerebellopontine angle lesion, dementia and stroke (pure motor hemiparesis, ataxic hemiparesis, etc.) (Pal et al., 2000; Wallin and Kurtzke, 2004). Perinaud syndrome and Brown–Sequard syndrome have also been documented with NCC (Del Brutto, 1997; Liu et al., 1992). It is important to be aware of these rare and diverse presentations, since they mimic a large number of neurological disorders. Lack of awareness may result in erroneous diagnosis, especially in tropical countries (Sawhney et al., 1998). Here we report a few cases of NCC presenting with clinical manifestations of extrapyramidal disease (parkinsonism and focal dystonia), Kluver–Bucy syndrome, Weber’s syndrome, dementia and cortical blindness.

## 2. Patients

We report six interesting cases of NCC with unusual clinical manifestations who were referred over the last 4 years (2001–2004) to the Department of Neurology, Sanjay Gandhi PGI, Lucknow, which is a tertiary care centre in northern India. The diagnosis of NCC was made on the basis of clinical and radiological features (Del Brutto et al., 2001).

### 2.1. Case 1

A 60-year-old farmer presented with complaints of tremors and difficulty in walking approximately a year prior to reporting. Tremors started from the left upper limb and then gradually progressed to involve the right upper limb over a period of 3 months. The tremors of both types (resting and action) were aggravated by movement (especially

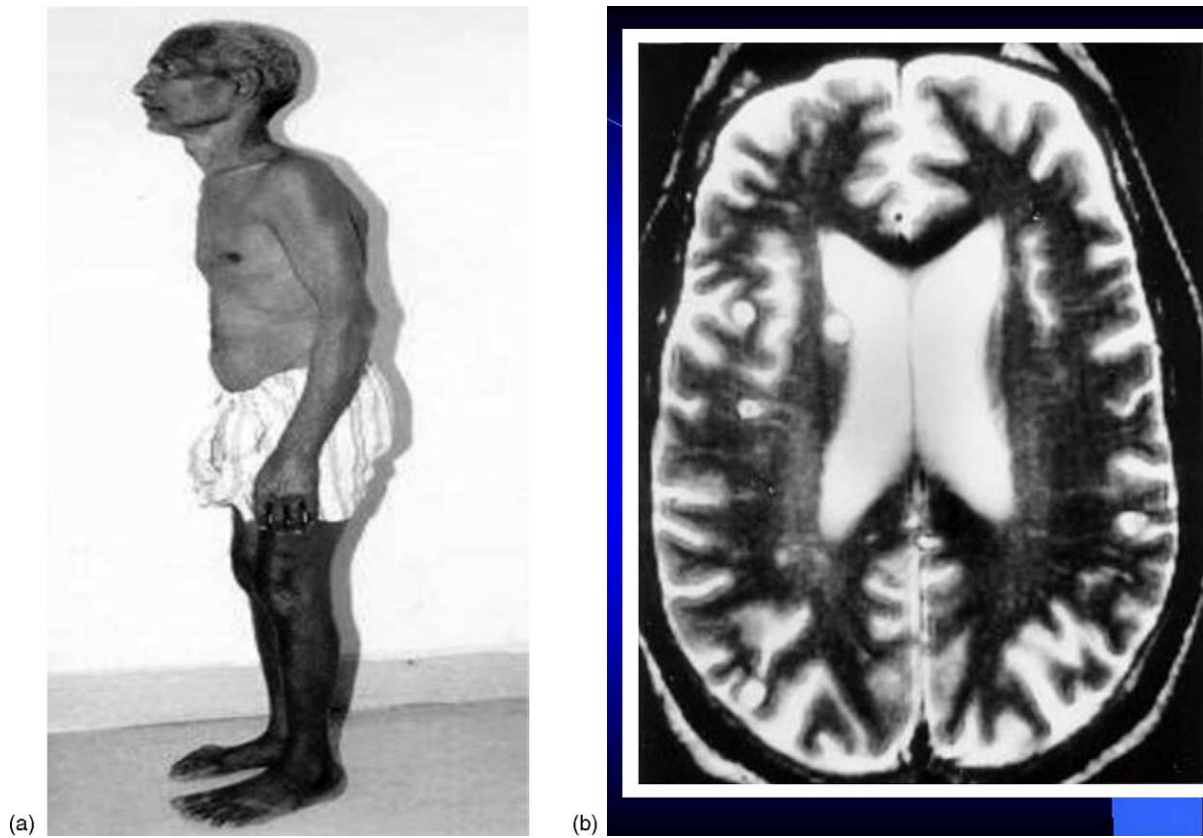
on picking up any object) and emotional stress. He was also having difficulty in walking, resulting in abnormal gait and unstable posture. There was no history of hypertension, diabetes, alcoholism, seizures, motor weakness, bladder/bowel involvement or decline in cognition. In addition, there was no history of familial movement disorder.

Examination revealed characteristic parkinsonian features with a staring, mask-like face. The blink rate was grossly diminished. He had dysarthria of speech, which was scanning, hypophonic and monotonous. Mental activity (Mini Mental State Examination (MMSE)) was normal. There was dystonic posturing of the feet, with the great toe held in a state of sustained dorsiflexion (striatal toe). Resting tremors were present in both hands, which were exacerbated by action. Posture was stooped (Figure 1a) and unstable, and his gait was short, shuffling and festinating. Ocular movements were full. Saccadic movements of the eye were slow, whilst pursuit movements were broken. Power, deep tendon reflexes and plantar response were normal, but cogwheel rigidity was present in all four limbs. Sensory examination did not reveal any abnormality. There were no cerebellar signs or dysautonomia. Other systemic examinations were normal.

Cranial magnetic resonance imaging (MRI) revealed multiple cysticerci in various stages (vesicular and granular). Few of them were cystic with a scolex. They were scattered bilaterally throughout both cerebral hemispheres including the basal ganglion (Figure 1b). ELISA for cysticerci in the cerebrospinal fluid (CSF) was positive, whilst proteins (38 mg%), sugar (60 mg%) and cells (2 lymphocytes/mm<sup>3</sup>) were normal. Haematology, urinalysis, serum chemistry, chest radiography and electroencephalography (EEG) were normal. The patient was managed conservatively with levodopa (110 mg thrice daily) and trihexyphenidyl (2 mg thrice daily). He reported initially with improvement in tremors, rigidity and dystonia but was later lost to follow-up.

### 2.2. Case 2

A 19-year-old female presented with sustained abnormal posturing of the left upper limb approximately 2 years prior to reporting. Onset was acute, first involving the left thumb and then progressing over 2–3 days to involve the whole of the left hand. The abnormal posture was sustained without any fluctuation. She was able to partially correct her abnormality voluntarily. There was no history of seizures, unconsciousness, fever,



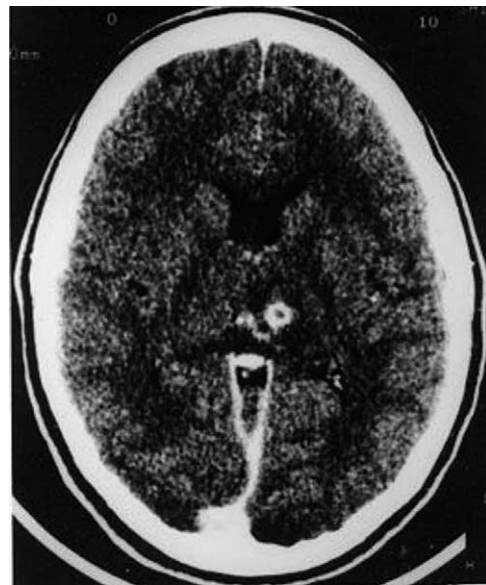
**Figure 1** (a) Photograph of Case 1, showing the stooped posture and parkinsonian features. (b) Cranial MRI of the same case, demonstrating the multiple neurocysticercosis cysts.

jaundice, exposure to toxins or consumption of drugs. There was no history of familial movement disorder.

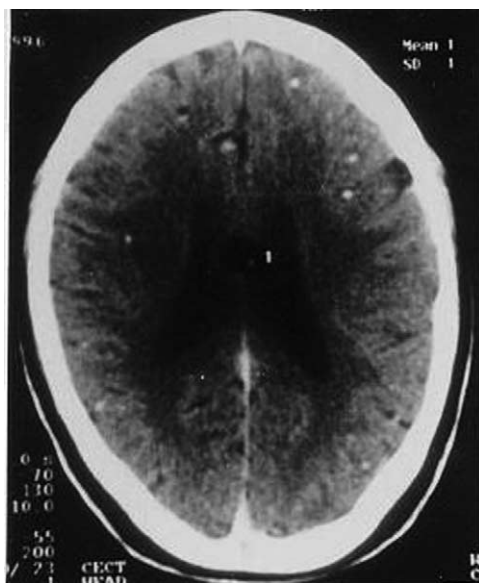
Examination revealed sustained dystonia involving all fingers of the left hand, predominantly the thumb, in attitude of flexion. Other limbs were normal. Her mental functions, speech and cranial nerves were normal. Muscle tone, power and deep tendon reflexes, including plantar response, were normal. There was no craniovertebral abnormality and sensory examination was normal. There were no cerebellar or autonomic dysfunctions.

Her haematology, serum chemistry and chest radiography were normal. Mantoux test was negative. Blood ELISA for cysticerci was positive. CSF examination and EEG were normal. Slit lamp examination did not reveal any Kayser–Fleischer (KF) ring. Cranial computerized tomography (CT) revealed a single, ring-enhancing granuloma in the right thalamic region (colloidal stage) (Figure 2).

She was managed with albendazole (15 mg/kg body weight) daily for 3 weeks. Steroids (0.75 mg/kg/day) were given to prevent any adverse effect. She did not show any improvement and was later lost to follow-up after 6 months.



**Figure 2** Cranial scan showing a single ring-enhancing lesion in the right thalamic region.



**Figure 3** Cranial scan showing multiple, small, calcified lesions, scattered bilaterally in the parenchyma.

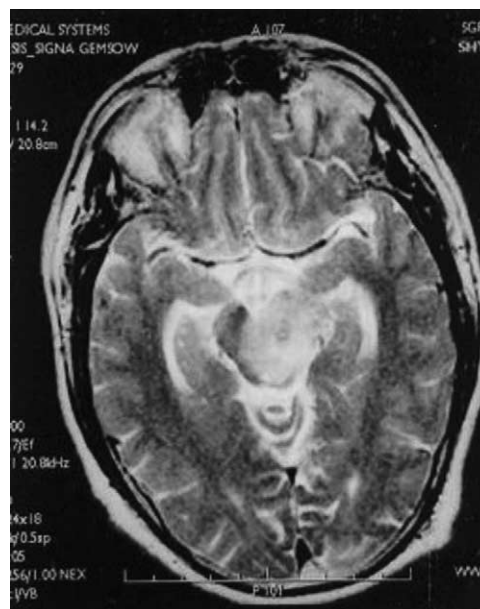### 2.3. Case 3

A young girl, aged 12 years, developed focal seizures and Todd's palsy approximately 6 months prior to reporting. No EEG or cranial imaging was done at that time. The seizures were controlled on carbamazepine, prescribed by her family physician. She presented with acute severe headache, vomiting and abnormal behaviour in the form of explosive temper, hyperorality and increased sexual instincts (stroking sex organs). On being scolded, she immediately became placid. Examination revealed bilateral papilloedema. Other cranial nerves were normal and there was no motor or sensory deficit. Haematology, clinical chemistry (hepatic and renal profile) and chest radiography were normal. EEG was abnormal, with intermittent epileptiform discharges. Cranial CT revealed multiple granulomas scattered bilaterally in the cerebral hemispheres in colloidal and granular stages. Few of them had an eccentric scolex, suggestive of NCC (Figure 3).

There was significant improvement in headache and vomiting with intravenous mannitol and oral glycerine. There was gradual improvement in behaviour, with decreased frequency of outbursts, hyperorality and sexual overtones. She remains seizure free and has normal behaviour on regular follow-up.

### 2.4. Case 4

A 45-year-old male presented with sudden diplopia and hemiparesis of the right side, followed by ptosis on the left eyelid, which progressed over 5–6 h. He



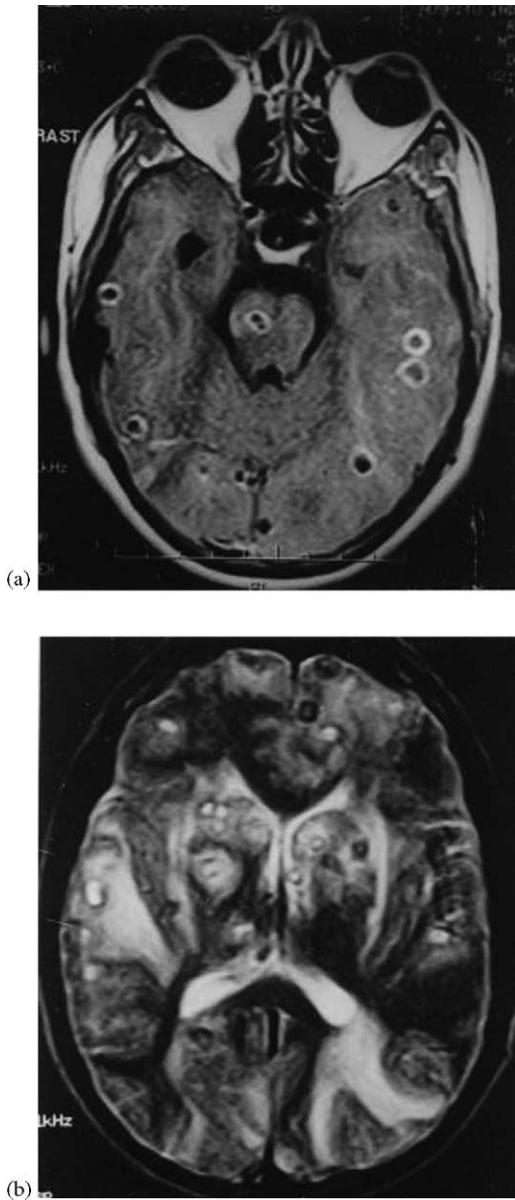
**Figure 4** Cranial MRI ( $T_2$  axial section), showing cystic lesion with scolex in the left midbrain region with marked perilesional oedema.

was managed initially by the family physician with steroids and albendazole, with which he improved gradually over 1 week. He remained asymptomatic for approximately 20 d, when he again developed diplopia, hemiparesis of the right side, along with ptosis with ophthalmoparesis in the left eye. There was no history of hypertension, diabetes, alcoholism, headache, vomiting, fever, unconsciousness, seizure or behavioural abnormalities.

Examination revealed normal mental functions. He had dysarthria in the form of scanning speech. Cranial nerve examination revealed 3rd nerve palsy (ptosis with ophthalmoplegia) on the left side and facial palsy (upper motor neuron type) on the right side. He had hemiparesis (power grade 3/5 in upper and lower limb) on the right side. Cranial MRI revealed multiple ring-enhancing lesions with scolex (vesicular and colloidal stage of NCC) in the left midbrain region with perilesional oedema (Figure 4). The patient was treated by anti-oedema measures on which he recovered completely.

### 2.5. Case 5

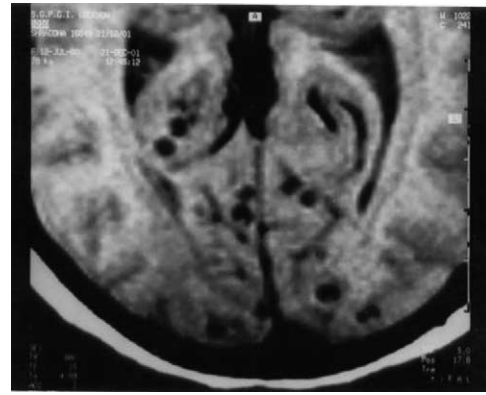
A 40-year-old male presented with progressive forgetfulness 1 month prior to reporting. He forgot the names of close relatives and family members. He also developed progressive inability to perform activities of daily living. He was taking carbamazepine prescribed by his family physician for seizures (focal with secondary generalisation) for 2 years. There was no previous history of diabetes,



**Figure 5** (a)  $T_1$  and (b)  $T_2$  axial cranial MRI section, showing multiple ring-enhancing lesions, i.e. neurocysticercosis cysts in various stages, scattered throughout the parenchyma including the brainstem.

hypertension, coronary artery disease, cerebrovascular accident, transient ischaemic attack, or exposure to drugs or toxins.

On examination he had dementia (MMSE score 17) and made gross errors in calculation. Cranial nerves, and motor and sensory examination were normal. Other systemic examinations, including cardiac, were normal. MRI revealed multiple ring-enhancing granulomas (all four stages of NCC) bilaterally in the cerebral hemispheres and mid-brain (Figure 5a and b). The patient was managed with anti-oedema treatment and anti-epileptics.



**Figure 6** Cranial MRI showing multiple neurocysticercosis cysts located bilaterally in the occipital cortex.

The patient continues to report significant improvement in cognition.

## 2.6. Case 6

An 11-year-old female child had seizures (partial with secondary generalisation) that were well controlled with carbamazepine. She presented with acute bilateral loss of vision, which she denied. She also had severe holocranial headache associated with vomiting.

On examination, her visual acuity was reduced to perception of light and hand movements only. Fundus examination revealed bilateral papilloedema. Motor and sensory examination was normal. Routine investigations including haematology, biochemistry and urine analysis were normal. Cranial MRI revealed multiple cysticerci (colloidal and granular stages) scattered throughout both cerebral hemispheres including the occipital cortex (Figure 6).

She was managed with anti-oedema measures and anti-epileptics. On follow-up her vision had improved significantly.

## 3. Discussion

Epilepsy is the commonest presentation of parenchymal NCC, occurring in 50–80% of patients (Carpio et al., 1998; Medina et al., 1990). Our first patient presented with tremor, rigidity and dystonia. The locations of lesions in the caudate, pallidum and thalamus were responsible for parkinsonian features and dystonia, respectively, in our patients. Potential mechanisms for this are an inflammatory reaction that accompanies death of the parasite, with oedema and dysfunction of perilesional tissue or mass effect (Bhigjee et al., 1987; Garcia et al., 2003). Unilateral dystonic

posturing is an unusual feature of epilepsy that has been reported in complex partial seizure of temporal origin (Cardoso, 1998; Kongel et al., 1989). In our patient, the dystonic posturing was sustained and EEG was normal, which differentiated it from seizures. Focal cerebral lesion may cause unilateral dystonia or hemidystonia due to involvement of the putamen, thalamus and less often the globus pallidus or caudate nucleus, which can be diagnosed by imaging (Bhigjee et al., 1987). The most common cause is cerebral infarction in which dystonia evolves with the resolution of hemiparesis after a variable delay of weeks or months (Cantu and Barinagarrementeria, 1996; Sawhney et al., 1998). Other focal brain lesions such as tuberculoma, NCC or space-occupying lesions are common causes of focal dystonia in tropical countries (Garcia and Del Brutto, 2003; Sawhney et al., 1998). The diagnosis may be missed since patients may present with rare clinical features, more so in developing countries owing to limitations of investigations.

The available data indicate that symptomatic dystonia may be caused by isolated lesions in the putamen, caudate, thalamus, globus pallidus or their connecting pathways. Animal data show that there is a gross somatotopic arrangement of input to the putamen so that the leg area is anterodorsal, the face area is posteroinferior and the arm area is in the middle (Cardoso, 1998; Kongel et al., 1989). This topography of lesions roughly coincides with the distribution of dystonia in our patients. Our second patient presented with dystonia involving the left upper limb, which may possibly be due to involvement of the thalamus as revealed on cranial MRI.

Involvement of the temporal lobes by hydrocephalus and perilesional oedema induced by NCC may be probable explanations for the features of Kluver–Bucy syndrome in our patient. Anatomical analysis of Kluver–Bucy syndrome with other diseases is controversial, although an intimate association with temporal lobe damage has been widely reported (Hart et al., 1986; Poeck, 1985). Isolated damage to the amygdalae and their cortical connections following cancer treatment has been widely confirmed by radioimaging and positron emission tomography. It has been conjectured that this syndrome also results from disruption of pathways connecting dorsomedial thalami with the pre-frontal cortex and other limbic areas that are essential for memory and regulation of emotions (Biswas et al., 1998a; Hayman et al., 1998; Muller et al., 1999).

Localising studies (clinical and anatomical) indicate the involvement of the phylogenetically old

medial temporal lobe regions and bilateral lesions of Ammon's horn for presentation of this syndrome. In addition, compression of hippocampi may also occur (Olson, 2003).

A number of changes in sexual behaviour are associated with temporal lobe epilepsy and its treatment by lobectomy. As many as 71% of patients with temporal lobe epilepsy exhibit altered sexual behaviour associated with ictal events. Interictal hyposexuality occurs in 80% of the patients; 20% exhibit a variety of paraphilias. When these hyposexual patients have a unilateral temporal lobectomy, their libido frequently increases and becomes excessive in some cases. Conversely, aberrant sexual behaviour as part of the ictal manifestation of temporal lobe seizures is also well documented (Greenwood et al., 1983).

Episodes of seizures may reflect transient bilateral dysfunction of the temporal lobe. Such temporary functional bilateral lobectomy could cause the same syndrome as an anatomical lobectomy and would be similar to the pathophysiological mechanism that may account for our patient's abnormal behaviour. Carbamazepine and leuproliids have been found to decrease the sexual behaviour in some individuals with Kluver–Bucy syndrome. Other medications such as haloperidol and anticholinergics may also be useful in treating behavioural abnormalities associated with Kluver–Bucy syndrome (Hooshmand et al., 1974). Our patient with Weber's syndrome had NCC with gross perilesional oedema located in the midbrain region that was possibly responsible for ptosis and ophthalmoparesis. The approximate incidence of cerebral infarcts is 4–12% with NCC (Fleury et al., 2004; Scharf, 1988). Various mechanisms are involved in the genesis of stroke in patients with NCC. It may be related to thrombosis of superficial cortical vessels owing to chronic meningitis. It may be due to fusiform aneurysms produced by weakening of the wall of the vessels or due to occlusion of small perforating vessels affected by endarteritis. Patients may present with lacunar infarct, large artery infarction, progressive midbrain syndrome and recurrent transient ischaemic attacks. The severity of cerebrovascular complication of NCC is related to the distribution of cysticercal disease and the severity of accompanying arachnoiditis. Hence, when cysts are confined to a focal area and associated with mild arachnoiditis, they involve small penetrating vessels manifesting as lacunar syndrome. When the cysts are widespread and accompanied by significant arachnoiditis, the associated vasculitis involves the main vessels of the circle of Willis with segmental narrowing of major intracranial arteries that produce large

cerebral infarcts (Alarcon et al., 1992; Cantu and Barinagarrementeria, 1996; Jha and Kumar, 2000).

The most common cause of Weber's syndrome is vascular due to occlusion of the peduncular and interpeduncular branches of the posterior cerebral artery, often owing to embolic occlusion (Koroshetz and Ropper, 1987). We feel the diagnosis of NCC should be included in the list of causes of stroke in the young, particularly in endemic areas. It is important to diagnose the cysticercotic angitis, as these patients require immediate steroid therapy to reduce subarachnoid inflammatory reaction that may cause recurrent cerebral infarcts (Jha and Kumar, 2000).

In our patient with dementia, there was raised intracranial tension and widespread parenchymal involvement of NCC, which may explain the cognitive impairment. NCC presenting with mental disturbances as the sole manifestation is rare. A cause and effect relationship of NCC with dementia is doubtful. Fuentes suggested that psychiatric symptoms associated with NCC were not due to the direct effect of the parasite on a definite region of the brain but were rather related to mechanical alterations in CSF pressure. Moreover, inflammatory injury of the brain parenchyma may also play some role (Biswas et al., 1998b). Similarly, the multiple lesions with perilesional oedema in the occipital cortex (bilaterally) account for cortical blindness (Fleury et al., 2003). Patients with unusual clinical manifestations should be investigated more thoroughly using immunodiagnostic techniques. However, the short period of observation and lack of advanced immunodiagnostic studies were major limitations of this study.

We conclude that patients from endemic areas presenting with manifestations discussed above should have a high index of suspicion for NCC and must be investigated for it.

#### Conflicts of interest statement

The authors have no conflicts of interest concerning the work reported in this paper.

#### References

- Alarcon, F., Hidalgo, F., Moncayo, J., Vinan, I., Duenas, G., 1992. Cerebral cysticercosis and stroke. *Stroke* 23, 224–228.
- Bhigjee, A.I., Kemp, T., Cosnett, J.E., 1987. Cerebral cysticercosis presenting with hemichorea. *J. Neurol. Neurosurg. Psychiatry* 50, 1561–1562.
- Biswas, A., Anand, K.S., Prasad, A., Ghosh, S., Bansal, J., 1998a. Clinico-radiological profile of Kluver–Bucy syndrome. *J. Assoc. Physicians India* 46, 318–319.
- Biswas, A., Prasad, A., Anand, K.S., 1998b. Cysticercal dementia. *J. Assoc. Physicians India* 46, 569.
- Cantu, C., Barinagarrementeria, F., 1996. Cerebrovascular complications of neurocysticercosis. Clinical and neuroimaging spectrum. *Arch. Neurol.* 53, 233–239.
- Cardoso, F., 1998. Infectious and transmissible movement disorders, in: Jankovic, J., Tolosa, E. (Eds), *Parkinson's Disease and Movement Disorders*, third ed. Williams and Wilkins, Baltimore, MD, pp. 945–965.
- Carpio, A., Escobar, A., Allen Hauser, W., 1998. Cysticercosis and epilepsy: a critical review. *Epilepsia* 39, 1025–1040.
- Del Brutto, O.H., 1997. Neurocysticercosis. *Curr. Opin. Neurol.* 10, 268–272.
- Del Brutto, O.H., Sutelo, J., 1988. Neurocysticercosis: an update. *Rev. Infect. Dis.* 10, 1075–1087.
- Del Brutto, O.H., Santibafiez, R., Noboa, C.A., Aguirre, R., Diaz, E., Alarcon, T.A., 1992. Epilepsy due to neurocysticercosis: analysis of 203 patients. *Neurology* 42, 389–392.
- Del Brutto, O.H., Rajshekhar, V., White, A.C., Tsang, V.C., Nash, T.E., Takayanagui, O.M., Schantz, P.M., Evans, C.A., Flisser, A., Correa, D., Botero, D., Allan, J.C., Sarti, E., Gonzalez, A.E., Gilman, R.H., Garcia, H.H., 2001. Proposed diagnostic criteria for neurocysticercosis. *Neurology* 57, 177–183.
- Fleury, A., Hernandez, M., Frago, G., Parkhouse, R.M., Harrison, L.J., Sciutto, E., 2003. Detection of secreted cysticercal antigen: a useful tool in the diagnosis of inflammatory neurocysticercosis. *Trans. R. Soc. Trop. Med. Hyg.* 97, 542–546.
- Fleury, A., Dessein, A., Preux, P.M., Dumas, M., Tapia, G., Laralde, C., Sciutto, E., 2004. Symptomatic human neurocysticercosis — age, sex and exposure factors relating with disease heterogeneity. *J. Neurol.* 251, 830–837.
- Garcia, H.H., Del Brutto, O.H., 2003. Imaging findings in neurocysticercosis. *Acta Trop.* 87, 71–78.
- Garcia, H.H., Gonzalez, A.E., Evans, C.A., Gilman, R.H.; Cysticercosis Working Group in Peru, 2003. *Taenia solium* cysticercosis. *Lancet* 362, 547–556.
- Greenwood, R., Bhalla, A., Gordon, A., Roberts, J., 1983. Behavior disturbances during recovery from herpes simplex encephalitis. *J. Neurol. Neurosurg. Psychiatry* 46, 809–817.
- Hart, R.P., Kwentus, J.A., Frazier, R.B., Hormel, T.L., 1986. Natural history of Kluver–Bucy syndrome after treated herpes encephalitis. *South. Med. J.* 79, 1376–1378.
- Hayman, L.A., Rexer, J.L., Marykay, P.A., Strite, D., Meyers, C.A., 1998. Kluver–Bucy syndrome after bilateral selective damage of amygdala and its cortical connections. *J. Neuropsychiatry Clin. Neurosci.* 10, 354–358.
- Hooshmand, H., Sepdham, T., Vries, J.K., 1974. Kluver Bucy syndrome: successful treatment with carbamazepine. *JAMA* 229, 1782.
- Jha, S., Kumar, V., 2000. Neurocysticercosis presenting as stroke. *Neurol. India* 48, 391–394.
- Kongel, P., Luders, H., Moris, H.H., Dinner, D.S., Wyllie, E., Godoy, J., Rothner, A.D., 1989. Dystonic posturing in complex partial seizures of temporal onset. A new lateralising sign. *Neurology* 39, 196–201.
- Koroshetz, W.J., Ropper, A.H., 1987. Artery-to-artery embolism causing stroke in the posterior circulation. *Neurology* 37, 292–295.
- Liu, G.T., Crenner, C.W., Logigian, E.L., Charness, M.E., Samuels, M.A., 1992. Midbrain syndrome of Benedikt, Claude, and Nothnagel: setting the record straight. *Neurology* 42, 1820–1822.
- Medina, M.T., Rosas, E.F., Rubio-Donnadieu, F., Sotelo, J., 1990. Neurocysticercosis as the main cause of late-onset epilepsy in Mexico. *Arch. Intern. Med.* 150, 325–327.
- Muller, A., Kwentus, J.A., Frazier, R.B., Hormel, T.L., 1999. Persistent Kluver–Bucy syndrome after bilateral thalamic

- infarction. *Neuropsychiatry Neuropsychol. Behav. Neurol.* 12, 136–139.
- Olson, D.A., 2003. Kluver–Bucy syndrome as a result of minor head trauma. *South. Med. J.* 96, 323.
- Pal, D.K., Carpio, A., Sander, J.W.A.S., 2000. Neurocysticercosis and epilepsy in developing countries. *J. Neurol. Neurosurg. Psychiatry* 68, 137–143.
- Poeck, K., 1985. The Kluver–Bucy syndrome in man, in: Vinken, P.J., Bruyn, G.W., Klawans, H.L. (Eds), *Handbook of Clinical Neurology. Clinical Neuropsychology*. Elsevier Science Publishers, Amsterdam, pp. 257–263.
- Sawhney, I.M.S., Singh, G., Lekhra, O.P., Mathuriya, S.N., Parihar, P.S., Prabhakar, S., 1998. Uncommon presentations of neurocysticercosis. *J. Neurol. Sci.* 154, 94–100.
- Scharf, D., 1988. Neurocysticercosis. Two hundred thirty-eight cases from a California hospital. *Arch. Neurol.* 45, 777–780.
- Singhi, P., Singhi, S., 2004. Neurocysticercosis in children. *J. Child Neurol.* 19, 482–492.
- Wallin, M.T., Kurtzke, J.F., 2004. Neurocysticercosis in the United States: review of an important emerging infection. *Neurology* 63, 1559–1564.

Available online at [www.sciencedirect.com](http://www.sciencedirect.com)

SCIENCE @ DIRECT®