

Pulmonary embolism: An unusual complication of cerebral venous thrombosis

S. Cakmak, MD; N. Nighoghossian, MD; V. Desestret, MD; M. Hermier, MD; S. Cartalat-Carel, MD; L. Derex, MD; J. Honnorat, MD; and P. Trouillas, MD

Pathologic data indicate that venous thrombosis is frequently found simultaneously at several sites.^{1,2} The source of pulmonary embolism (PE) is located in the upper venous tree in 12.6% of autopsy records.¹ Catheterization of internal jugular vein, infectious disease, or co-morbidity related to malignancy are the main sources of PE in these patients.¹ A review of 39 cases of cerebral venous thrombosis (CVT) showed that right heart failure consistent with PE was frequent.² In this report, patients had conditions favoring lower-limb deep vein thrombosis (DVT) and further PE. In contrast, occurrence of CVT and PE without evidence of systemic venous thrombosis is unusual.³

Between January 1, 2002, and March 31, 2005, 28 consecutive patients were diagnosed with CVT in our department. The diagnosis was based on MRI including MR venography. Symptomatic PE was suspected in four patients and confirmed by lung perfusion CT in two patients and by scintigraphy ventilation–perfusion mismatch in two cases. No patient had significant motor weakness that would have increased the risk of lower-limb DVT. Ultrasound examination of lower-limb veins was normal in all cases. Biologic testing included arterial blood gas measurements, D-dimer measurement, and routine coagulation tests. Comprehensive hypercoagulable screening was performed as previously reported.⁴ Antiphospholipid syndrome was diagnosed in one case, detailed further in the text. No deaths were observed. Outcome was good in patients with PE. Clinical features and radiologic and biologic data are summarized in the table.

Case report. A 22-year-old man presented with rapid-onset diffuse headache followed by a generalized seizure. Brain CT showed a right temporal hemorrhagic infarct. MRI revealed a right lateral sinus thrombosis. IV heparin was given for 8 days and switched to oral anticoagulant therapy on day 5. The patient was discharged with efficient international normalized ratio (INR). The following day, he was readmitted because of left thoracic pain. EKG showed sinus tachycardia. Chest radiograph and arterial blood gas measurements were normal. INR was 3.80. Plasma D-dimers were elevated (10 mg/L; normal <0.500 mg/L). Lung perfusion CT revealed a right proximal PE and left-sided pleural reaction. Clinical outcome was favorable. Three-month follow-up brain MRI showed complete recanalization of the right lateral sinus without parenchymal damage. Hypercoagulable

screening showed lupus anticoagulant with IgG-type antiphospholipid antibodies.

Discussion. PE in bedridden stroke patients is a common condition. None of our patients had such a predisposing condition, and all had an early effective anticoagulation. A review of 5,039 autopsy records from 1975 to 1988 indicated that a significant fraction of thrombi in patients who developed PE is found in the upper venous system. However, this study did not examine the possible contribution of intracranial venous thrombosis.¹ An autopsy study of 39 patients with CVT reported nine cases of right cardiac insufficiency, some of them of acute onset. Extracerebral location of venous thrombosis was reported in 18 cases.² In contrast, the follow-up of 624 patients in the International Study on Cerebral Vein and Dural Sinus Thrombosis for a median time of 16.7 months showed occurrence of lower-limb DVT in 2.5% and PE in 0.5% of cases only.³ This discrepancy between autopsy and clinical studies raises concern, as underlined previously.⁵ A comprehensive review collected only 23 cases of PE in CVT patients between 1942 and 1990. The authors indicate that 95% of CVT patients with PE died.⁵ Septic context in 23% of the cases⁵ may have worsened the prognosis. Before 1990, early diagnosis and treatment of CVT were not widely available. These factors may explain the differences in outcome observed in comparison with our data. Moreover, the small sample size in our study does not allow significant statistical comparison.

The association of CVT and PE may be explained by two mechanisms that are not mutually exclusive. PE may be related to a detached thrombus from the lateral sinus as previously suggested.⁵ A global pro-thrombotic state may also be contributive. Based on the chronology of thrombotic events in our study, Patients 17 and 18 may have had a thrombus propagation. The limitations of the ultrasound method in the setting of DVT are well known. MRI may be a valuable tool for the detection of pelvic vein thrombosis.⁶ Indeed, a pelvic vein thrombosis was found on autopsy of a patient with CVT who made a complete recovery and died of PE shortly after.⁷

A prospective study specifically designed to establish the true incidence and mechanisms of PE in CVT patients is needed.

From the Stroke Unit, (Drs. Cakmak, Nighoghossian, Desestret, Cartalat-Carel, Derex, Honnorat, and Trouillas), Neurology and Neurosurgery Hospital, and Neuroradiology Department (Dr. Hermier), CREATIS UMR 5515, INSERM U 630, Lyon, France.

Disclosure: The authors report no conflicts of interest.

Received April 7, 2005. Accepted in final form June 14, 2005.

Table Clinical features and imaging and biological data

Sex/age, y	Symptoms	CVT imaging	Lung imaging	Coagulation studies
M/22	Seizures, headache	RLS, right temporal HI	RPA thrombosis, left-sided pleurisy	INR = 3.8, ATT = 56 s, d-d = 10 mg/L
F/43	ICHT, left-sided cervical pain	LLS, left jugular vein, left temporal HI	Left-sided perfusion, ventilation mismatch	INR = 2.17, d-d = 0.83 mg/L
M/33	Seizure, headache	RLS, no parenchymal damage	Left-sided perfusion mismatch	ATT = 55 s, INR = 1.12, d-d = 0.22 mg/L
F/73	Confusion	SS, ICV, bithalamic infarction	Bilateral proximal pulmonary embolism	ATT = 26 s, INR = 1.04, d-d = 2.0 mg/L

These patients were nos. 17, 18, 26, and 27 of our consecutive series. All presented with thoracic pain or dyspnea. PE followed CVT in Patients 17 and 18. CVT followed PE in patient 26. Chronology of events is unknown for Patient 27. Complete recovery was obtained in three patients and partial improvement in Patient 27. The only risk factor was oral contraceptives for Patient 18; no etiology was found for Patients 26 and 27.

CVT = cerebral venous thrombosis; ICHT = intracranial hypertension; RLS = right lateral sinus; LLS = left lateral sinus; SS = straight sinus; ICV = internal cerebral vein; HI = hemorrhagic infarct; RPA = right pulmonary artery; INR = international normalized ratio; ATT = activated thromboplastin time; d-d = D-dimers, normal range <0.500 mg/L; PE = pulmonary embolism.

References

1. Diebold J, Lohrs U. Venous thrombosis and pulmonary embolism. A study of 5039 autopsies. *Pathol Res Pract* 1991;187:260–266.
2. Barnett HJ, Hyland HH. Noninfective intracranial venous thrombosis. *Brain* 1953;76:36–49.
3. Ferro JM, Canhao P, Stam J, Boussier MG, Barinagarrementeria F, for the ISCVT Investigators. Prognosis of cerebral vein and dural sinus

- thrombosis. Results of the International Study on Cerebral Vein and Dural Sinus Thrombosis (ISCVT). *Stroke* 2004;35:664–670.
4. Cakmak S, Derex L, Berruyer M, et al. Cerebral venous thrombosis: clinical outcome and systematic screening of prothrombotic factors. *Neurology* 2003;60:1175–1178.
5. Diaz JM, Schiffman JS, Urban ES, Maccario M. Superior sagittal sinus thrombosis and pulmonary embolism: a syndrome rediscovered. *Acta Neurol Scand* 1992;86:390–396.
6. Cramer SC, Rordorf G, Maki JH, et al. Increased pelvic vein thrombi in cryptogenic stroke. Results of the Paradoxical Emboli from Large Veins in Ischemic Stroke (PELVIS) Study. *Stroke* 2004;35:46–50.
7. Hyland HH. Intracranial venous thrombosis in the puerperium. *JAMA* 1950;142:707–710.

Herbal energy drinks, phenylpropanoid compounds, and cerebral vasculopathy

Bradford B. Worrall, MD, MSc; C. Douglas Phillips, MD; and Kendrick K. Henderson, MD

We report a 21-year old man with cerebral vasculopathy and concurrent ischemic and hemorrhagic strokes shortly after his first exposure to an “energy drink” containing numerous sympathomimetic herbal compounds.

Several hours after drinking 250 mL of the energy drink XS Cranberry–Grape Blast, the patient had onset of profound headache and hemiataxia while on a hike with friends. His medical history included type I diabetes, asthma, and remote syncope. He denied exposure to over-the-counter stimulants, cold preparations, diet aids, or illicit drugs.

On examination, he had photophobia and marked hemiataxia. His imaging revealed an acute brainstem infarction and bilateral subarachnoid hemorrhage on the cerebral convexities (figure). CSF analysis confirmed subarachnoid blood without elevation of white blood cells or protein. Cerebral angiography revealed multifocal areas of narrowing and dilatation in distal long segments of the middle and posterior cerebral arteries without evidence of aneurysm (see the figure). An extensive evaluation for systemic inflammatory vasculitis or hypercoagulable state and a screen for drugs of abuse were both negative.

The manufacturer’s Web site (<http://www.xsgear.com/store/faqs.asp#Available%20Drinks>) indicates that this energy drink contains an “adaptogenic” mixture of herbal compounds: *Eleutherococcus (Acanthopanax) senticosus* (Siberian ginseng), *Schisandra (Wu Wie Zi or Chinese magnolia vine)*, *Astragalus (Huang Qi or milk-vetch root)*, *Reishi* (a mushroom), and several other *Panax* species (various ginseng species). The manufacturer states that “adaptogenic herbs aid the body in managing stress” (<http://www.xsgear.com/store/faqs.asp#Available%20Drinks>). The patient routinely drank another energy drink (Red Bull Sugar Free) that does not contain these compounds (<http://www.redbullusa.com/extras/ingredients.jsp>). Both drinks contain carbonated water, caffeine, taurine, citric acid, acesulfame k (sweetener), and B vitamins (B₃, B₅, B₆, B₁₂).

Three constituents of the adaptogenic blend in this energy drink, *Eleutherococcus senticosus*, *Schisandra*, and *Panax* species, are sympathomimetic, and all contain phenylpropanoid lignans among other potentially vasoactive compounds.^{1–3} The Food and Drug Administration requested withdrawal of phenylpropanolamine from all prescription and over-the-counter drugs as of November 2000 based largely on evidence of cerebrovascular risk (<http://www.fda.gov/cder/drug/infopage/ppa/default.htm>). Exposure to herbal sympathomimetic substances including ephedra and ginseng is a risk factor for cerebral vasculopathy, subarachnoid hemorrhage, and ischemic stroke.^{4,5} The terms “vasculitis” and “vasospasm” are both used in the literature to describe the angiographic findings, although the more generic term “vasculopathy” is more appropriate.

This case highlights the potential relationship between pharmacologically active and widely available “herbal supplements” and cerebral vasculopathy, although we cannot unequivocally prove a connection. The patient’s diabetes, a known vascular risk factor, may have altered his susceptibility to the vasoactive moieties. Physicians and other health care providers should include a detailed history of exposure to herbal preparations including those found in popular soft drinks. Mechanisms for reporting adverse reactions to these products when used as a dietary supplement are evolving; current options include use of the Food and Drug Administration MedWatch Program. Only through aggressive reporting and critical scrutiny will we be able to determine if legitimate public health risks exist from herbal compounds in “energy drinks” and other sources.

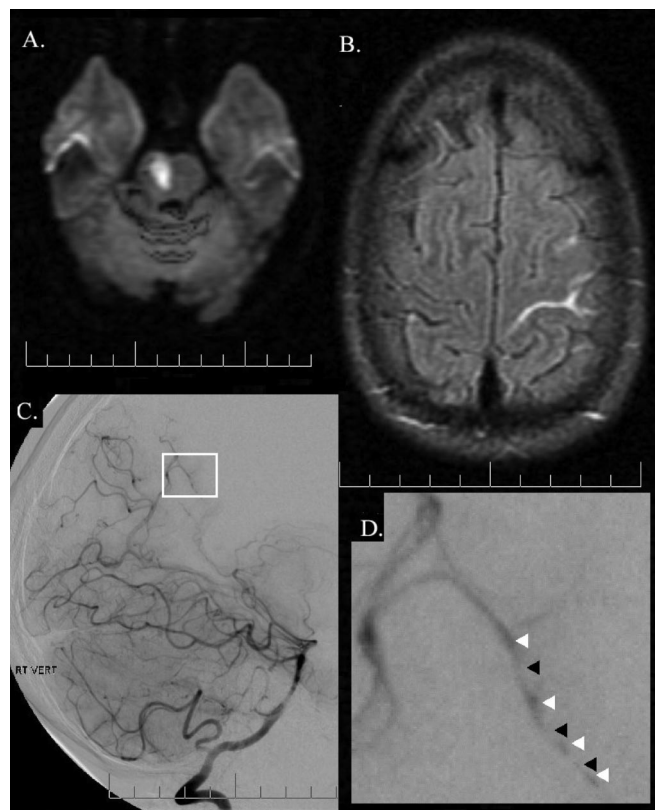

Figure. (A) Diffusion-weighted MR image demonstrating the acute infarct in the upper right pons. (B) Fluid-attenuated inversion recovery MR image showing subarachnoid blood at the convexity. (C) Digital subtraction angiogram right vertebral injection demonstrating areas of narrowing and dilation of distal vessels. (D) Close-up of the area inside the white box in (C). The black-and-white arrowheads indicate the areas of narrowing and dilatation in a posterior cerebral artery branch.

From the Departments of Neurology and Public Health Sciences (Dr. Worrall), and the Department of Radiology (Dr. Phillips), University of Virginia, Charlottesville, and Department of Neurology (Dr. Henderson), University of Tennessee, Knoxville.

Disclosure: The authors report no conflicts of interest.

Received February 17, 2005. Accepted in final form June 20, 2005.

Address correspondence and reprint requests to Dr. B.B. Worrall, Department of Neurology, University of Virginia Health System, Box 800394, Charlottesville, VA 22908; e-mail: bbw9r@virginia.edu

References

1. Hikino H, Kiso Y, Taguchi H, Ikeya Y. Antihepatotoxic actions of lignoids from *Schizandra chinensis* fruits. *Planta Med* 1984;50:213–218.
2. Kang JS, Linh PT, Cai XF, Kim HS, Lee JJ, Kim YH. Quantitative determination of eleutheroside B and E from *Acanthopanax* species by high performance liquid chromatography. *Arch Pharmacol Res* 2001;24:407–411.

3. Steinmann GG, Esperester A, Joller P. Immunopharmacological in vitro effects of *Eleutherococcus senticosus* extracts. *Arzneimittelforschung* 2001;51:76–83.
4. Chen C, Biller J, Willing SJ, Lopez AM. Ischemic stroke after using over the counter products containing ephedra. *J Neurol Sci* 2004;217:55–60.
5. Ryu SJ, Chien YY. Ginseng-associated cerebral arteritis. *Neurology* 1995;45:829–830.

Cervical epidural blood patch for low CSF pressure headaches

Daniel Kantor, MD; and Stephen D. Silberstein, MD

Low CSF pressure headache is divided by the International Headache Society into three categories: 1) postdural puncture headache, 2) CSF fistula headache, and 3) headache attributed to spontaneous low CSF pressure.¹ Finding an optimal way to “seal” a CSF leak with an epidural blood patch is often elusive.² The difficulty lies in finding the site of leak (often lower cervical or upper thoracic).³

We present four patients with low CSF pressure headaches that responded to a cervical but not a lumbar epidural blood patch.

Case reports. Patient 1. A 36-year-old woman developed orthostatic headaches 1 month after a motor vehicle accident. Brain CT and MRI were normal. CSF opening pressure was unobtainable. CT myelogram showed CSF leaks at C1 to C2 and C6 to T2.

The patient was transferred to us with a diagnosis of low CSF pressure headache secondary to a traumatic dural tear. Conservative treatment with bedrest, hydration, nonsteroidal anti-inflammatory drugs, caffeine, and theophylline failed.

Repeat lumbar puncture revealed an unobtainable opening pressure, and CT myelogram showed CSF leaks on the right at C6 to C7, bilateral leaks at T1 to T2 nerve roots, and a subdural collection at C3 to C4. A cervicothoracic junction (T1 to T2) epidural blood patch (10 mL) resulted in immediate headache improvement. Two months later, brain and cervical spine MRI showed no pachymeningeal enhancement. Two years later, she denied disabling or orthostatic headaches.

Patient 2. A 50-year-old woman with episodic migraine without aura developed orthostatic headaches. She was treated with a lumbar epidural blood patch with 3 days of relief.

Brain MRI demonstrated diffuse pachymeningeal enhancement, sagging of the cerebral hemispheres, effacement of the suprasellar cistern, and low-lying cerebellar tonsils. Radionuclide cisternography demonstrated rapid CSF turnover; CSF opening pressure was 20 mm H₂O. A second lumbar epidural blood patch worked for 4 days. A cervical epidural blood patch at C7 to T1 resulted in complete headache relief, which is still present 1 year later.

Patient 3. A 25-year-old man developed sudden occipital orthostatic headaches. IV caffeine produced no relief. A lumbar epidural blood patch produced relief for 3 days; two others failed. Three months later, brain MRI demonstrated diffuse pachymeningeal enhancement, effacement of the subarachnoid spaces at the foramen magnum and inferior frontal region, and sagging of the cerebellum and cerebral cortex. CT myelogram demonstrated contrast extravasation outlining the posterior spinal muscles from the suboccipital region to the C2–C3 level, more on the right, suggesting a dural tear; CSF opening pressure was 140 mm H₂O. A C5 to C6 cervical epidural blood patch produced complete headache relief, which is still present 5 years later.

Patient 4. A 38-year-old woman developed sudden-onset orthostatic headaches. CSF opening pressure was 40 mm H₂O. MRI of the spine demonstrated low-lying cerebellar tonsils and a subdural fluid collection extending from the posterior fossa to the thoracic region. A lumbar epidural blood patch provided 2 days of relief.

A CT myelogram revealed contrast leakage from C2 to C3 to L2 to L3, maximal at C7 to T1. Repeat lumbar epidural blood patch produced transient headache relief for 1 day. Epidural blood patch at the cervicothoracic junction (T1 to T2) produced complete headache resolution. On 18-month follow-up, she denied orthostatic headaches and only had her typical migraines.

Discussion. The most common cause of low CSF pressure headache is lumbar puncture. Some patients have spontaneous low CSF pressure headache, most often due to a cryptic CSF leak. Conservative treatment options include bed rest, abdominal binder, hydration, caffeine, theophylline, and corticosteroids. If conservative treatment fails, lumbar epidural blood patching is often the next option. Epidural blood patches produce headache relief by immediately compressing the dural sac, raising intrathecal pressure and forming a seal at the site of the dural hole.⁴ Lumbar epidural blood patches are not as effective in cryptic tears as the site of leak is often cervical or thoracic.

Cervical epidural blood patches are more commonly used by anesthesiologists than by headache experts.⁵ Their risk includes compression of the spinal cord and nerve roots, chemical meningitis, intrathecal injection of blood,⁶ and neck stiffness. Less blood is injected into cervical than lumbar epidural patches.⁷

One of our patients had a history of trauma; the other three had spontaneous low CSF pressure headaches. All four responded dramatically to cervical epidural blood patches after failed lumbar epidural blood patches, suggesting that even without a specific site of CSF leakage, cervical epidural blood patches may be useful after failed lumbar epidural blood patches.

There are few reported cases of successful treatment of low CSF pressure headaches with targeted cervical epidural blood patches. None of our patients needed a second cervical epidural blood patch to attain headache relief.

From the Department of Neurology and Jefferson Headache Center, Thomas Jefferson University, Philadelphia, PA.

Disclosure: The authors report no conflicts of interest.

Received November 21, 2004. Accepted in final form June 16, 2005.

Address correspondence and reprint requests to Dr. S.D. Silberstein, Jefferson Headache Center, 111 S. Eleventh Street, Suite 8130, Philadelphia, PA 19107; e-mail: Stephen.Silberstein@jefferson.edu

Copyright © 2005 by AAN Enterprises, Inc.

References

1. Headache Classification Committee. The International Classification of Headache Disorders. 2nd ed. *Cephalalgia* 2004;24(suppl 1):1–160.
2. Mokri B. Spontaneous intracranial hypotension. *Curr Neurol Neurosci Rep* 2001;1:109–117.
3. Schaltenbrand G. Normal and pathological physiology of the cerebrospinal fluid circulation. *Lancet* 1953;1:805–808.
4. Carrie LE. Epidural blood patch: why the rapid response? *Anesth Analg* 1991;72:129–130.
5. Forderreuther S, Yousry I, Fuhry L, Straube A. Partial improvement of headache in a patient with spontaneous cervical cerebrospinal fluid (CSF) leakage after lumbar blood patch. *Cephalalgia* 2000;20:674–676.
6. Aldrete JA, Brown TL. Intrathecal hematoma and arachnoiditis after prophylactic blood patch through a catheter. *Anesth Analg* 1997;84:233–234.
7. Walpole JB. Blood patch for spinal headache. A recurrence and a complication. *Anaesthesia* 1975;30:783–785.

Age, dose, and environmental temperature are risk factors for topiramate-related hyperthermia

El Khoury Ziad, MD; Amal C. Rahi, MPH; Sahar Abu Hamdan, BSN; and Mohamad A. Mikati, MD

To determine the risk of occurrence of hyperthermia during topiramate therapy,^{1,4} and the risk factors of developing hyperthermia, we investigated all patients (predominantly Lebanese Arabs) seen in our epilepsy clinic during a 2-year period.

Methods. Inclusion criteria were diagnosis of epilepsy treated with at least one antiepileptic drug (AED) and patient or family able to accurately report side effects.

Exclusion criteria were 1) medical condition or drugs that could cause or mask the occurrence of fever, 2) clinical findings that indicate another cause of hyperthermia, or 3) any episodes of hyperthermia that were not properly evaluated.

Detailed clinical information was gathered on each patient at baseline and every 3 to 4 months during a 2-year prospective follow-up. Patients or family members were systematically asked about adverse experiences, but hyperthermia was not specifically mentioned to avoid bias. If hyperthermia was reported, then detailed clinical and laboratory data were collected. Hyperthermia was defined as a rectal temperature of more than 38.0°C or a rectal temperature of 37.5 °C to 38.0 °C with flushing, hotness, obvious discomfort, and irritability requiring intervention (e.g., antipyretics, cold baths, or evaluation by a physician). Whenever hyperthermia was observed, the patient was evaluated for infectious and noninfectious etiologies. Only patients whose hyperthermia lacked an identifiable etiology were considered to have potentially drug-related hyperthermia (referred to in the rest of the article as hyperthermia). Data were analyzed using the Student *t* test (for normally distributed data), Mann-Whitney test, χ^2 test, and Fisher exact test (for other data as appropriate).

Results. Hyperthermia occurred in 15/143 (10.5%) patients on topiramate and in 1/688 (0.15%) of those on other AEDs without topiramate ($p < 0.001$). The percentage of patients on monotherapy in the topiramate group was 7.0% and in controls 12.1%. Adjunctive AEDs did not differ between the two groups and included valproate, carbamazepine, lamotrigine, benzodiazepines, phenytoin, phenobarbital, vigabatrin, and gabapentin ($p > 0.05$ in all comparisons of % of patients on each drug). Characteristics of patients on topiramate were as follows: 59.4% male, median age 8.0 years, median age at seizure onset 2.0 years, median seizures/month 1.0, 55.2% had partial seizures, 44.8% primary generalized seizures, 55.9% symptomatic epilepsy, 41.3% cryptogenic, 2.8% idiopathic, and 35.7% had brain MRI abnormalities. Patients on other AEDs did not differ in sex, age, or seizure types from the topiramate group. They differed in the following ($p \leq 0.02$): age at seizure onset was higher (3.0 years), seizure frequency was less (median of 0 seizure/month), epilepsy syndrome categorization was different (38.6% symptomatic, 48.2% cryptogenic, and 13.2% idiopathic), and fewer (25.9%) had brain MRI abnormalities. However, none of these variables proved to be a risk factor for hyperthermia (see below). So, it is not very likely that these factors acted as confounding variables.

Age at occurrence of hyperthermia in patients on topiramate was 3.77 ± 2.81 years (mean \pm SD), and median time from starting topiramate until hyperthermia was 0.5 years. Temperature was 37.5 °C to 38.0 °C in 30.8% of patients, 38.1 °C to 38.5 °C in 15.4%, 38.6 °C to 39.0 °C in 38.5%, and 39.0 °C to 39.5 °C in 15.4%. Many parents reported that hyperthermia was refractory to antipyretics, but responded to hydration, cold baths, or cold compressors. Eight patients developed only one cluster of hyperthermia lasting from 1 to 7 days; three reported multiple episodes in 1 month; two reported multiple episodes over 3 months; and two had episodes in both summer and winter.

Patients with hyperthermia on topiramate were compared to those on topiramate but without hyperthermia (table). Significant differences were present in age, daily dose of topiramate, and time of the year. Most patients who developed hyperthermia were 6 years or younger (13/15, $p < 0.001$) and on doses above 6 mg/Kg/day (11/15, $p = 0.001$).

Discussion. Previous case reports suggested that topiramate-related hyperthermia may be secondary to decreased sweating, increased environmental temperature, and possibly young age.¹⁻⁴

Table Risk factors for developing hyperthermia during topiramate therapy

Risk factor	Hyperthermia	No hyperthermia	<i>p</i> Value
Sex, %			
Male*	46.7 (n = 7)	60.9 (n = 78)	0.287
Female*	53.3 (n = 8)	39.1 (n = 50)	0.287
Seizure type, %			
Partial seizures*	46.7 (n = 7)	56.3 (n = 72)	0.480
Primary generalized*	53.3 (n = 8)	43.8 (n = 56)	0.480
Secondary generalized†	6.7 (n = 1)	19.5 (n = 25)	0.306
Epilepsy syndrome category, %			
Symptomatic*	53.3 (n = 8)	56.3 (n = 72)	0.830
Cryptogenic*	46.7 (n = 7)	40.6 (n = 52)	0.653
Idiopathic†	0.0 (n = 0)	3.1 (n = 4)	1.000
Brain MRI abnormality, %*	33.3 (n = 5)	35.9 (n = 46)	0.842
Time of year			
Warm months (May–Oct.),* mean temperature 24.3° C	14/143	129/143	0.001‡
Cool months (Nov.–Apr.),* mean temperature 15.7° C	1/143	142/143	
Age, y§	4.0	8.0	0.001‡
Age at seizure onset, y§	0.5	2.0	0.057
Seizure frequency per month§	1.0	1.0	0.607
Dose of topiramate, mg/kg, mean \pm SD¶	11.26 \pm 6.62	5.88 \pm 4.95	0.000‡

* Chi-square test used.

† Fisher exact test used.

‡ Difference is significant (two-tailed $p < 0.05$).

§ Mann-Whitney test used.

¶ Student *t* test used.

|| Median.

The fact that our and the previous reports came from the Mediterranean region suggests that genetic factors may be important.¹⁻⁴ The predisposition of younger children may be related to their smaller blood volume relative to body surface area, lower sweating rate per gland, and to higher surface-area-to-mass ratio.^{5,6}

In this study, hyperthermia occurred in 10.5% of patients on topiramate vs 0.15% in patients on other antiepileptic drugs. The risk factors were age \leq 6 years, dose \geq 6 mg/Kg/day, and summer months of the year.

From the Department of Pediatrics (Drs. Ziad, Rahi, Hamdan, and Mikati) and Adult and Pediatric Epilepsy Program (Dr. Mikati), American University of Beirut Medical Center, Beirut, Lebanon.

Disclosure: The authors report no conflicts of interest.

Received February 14, 2005. Accepted in final form June 24, 2005.

Address correspondence and reprint requests to Dr. Mohamad A. Mikati, Professor and Chairman, Department of Pediatrics, Director, Adult and Pediatric Epilepsy Program, American University of Beirut Medical Center, Beirut, Lebanon; e-mail: mamikati@ab.edu.lb

Copyright © 2005 by AAN Enterprises, Inc.

References

1. Arcas J, Ferrer T, Roche M, Martinez-Bermejo A, Lopez-Martin V. Hypohidrosis related to the administration of topiramate to children. *Epilepsia* 2001;42:1363–1365.
2. Nieto Barrera M, Nieto Jimenez M, Candau R, Ruiz del Portal L. Anhidrosis and hyperthermia associated with treatment with topiramate. *Rev Neurol* 2002;34:114–116.

- Ben-Zeev B, Watemberg N, Augarten A, et al. Oligohydrosis and hyperthermia: pilot study of a novel topiramate adverse effect. *J Child Neurol* 2003;18:254–257.
- De Carolis P, Magnifico F, Pierangeli G, et al. Transient hypohidrosis induced by topiramate. *Epilepsia* 2003;44:974–976.
- Briggman JV, Tashian RE, Spicer SS. Immunohistochemical localization of carbonic anhydrase I and II in eccrine sweat glands from control subjects and patients with cystic fibrosis. *Am J Pathol* 1983;112:250–257.
- Falk B. Effects of thermal stress during rest and exercise in the paediatric population. *Sports Med* 1998;25:221–240.

Compressive myelopathy presenting as cervical cord neurapraxia: A differential diagnosis of TIA

Thomas Cochrane, MD, MBA; and Jeremy D. Schmahmann, MD

Cervical compressive myelopathy from spondylosis or disc herniation characteristically presents with progressive spasticity, weakness, sensory phenomena, and urinary urgency.^{1–3} In contrast to this scenario, the term cervical cord neurapraxia (CCN) has been applied to the transient clinical phenomenon that occurs following minor trauma in young athletes who have congenital or acquired cervical spine stenosis.^{4,6} It is characterized by sensory changes including burning pain, numbness, tingling and loss of sensation, and motor changes ranging from weakness to quadriplegia, recovering completely within 10 to 15 minutes or occasionally over a period of 48 hours.⁴ In one series of 110 patients⁵ all episodes occurred during athletic activity, 87% while playing football. The average age of the patients was 21 years (range 13 to 33). Spinal stenosis was determined by measuring the ratio of the sagittal diameter of the spinal canal (see “a” in the figure, A) to the diameter of the mid-cervical sagittal vertebral body (see “b” in the figure, A). A ratio of less than 0.8 was indicative of significant spinal stenosis, was present in all CCN patients,^{4,6} and was strongly predictive of recurrence. We describe a man in whom incipient compressive cervical myelopathy presented with recurrent episodes of CCN characterized by unprovoked brief episodes of hemiparesis and sensory abnormalities.

Case report. A 49-year-old man developed abrupt onset of left-sided paresthesia with total paralysis of the left arm and profound weakness of the left leg while standing on the sidelines coaching his daughter’s soccer game. There was no pain, impairment of consciousness or speech, or report of facial droop, vertigo or dysequilibrium. The weakness largely resolved after 20 seconds, with improvement to normal over 20 minutes, but he experienced a feeling of sleepiness for several hours. There were a further seven episodes over the ensuing 2 months, with stereotypical sudden-onset left-sided arm and leg numbness, tingling, and weakness, and some with subsequent drowsiness. One episode was precipitated by wading in the ocean; another by reaching for a telephone on the left side of his bed. He had complete recovery between episodes. Examination revealed normal cranial nerves, motor system, gait, and sensation. The left biceps reflex was diminished compared to the right, and the left brachioradialis and triceps reflexes were minimally brisker. The remainder of the examination was normal. There was no Lhermitte phenomenon. MRI showed intervertebral disc herniation at levels C5–6 and C6–7, causing mild cord deformity, left greater than right, and T2 intrinsic cord signal hyperintensity at C5 and C6 (figure, B and C).

Using cervical spine X-rays, the ratio of the sagittal diameter of the spinal canal (12 mm) to the diameter of the mid-cervical sagittal vertebral body (18 mm) was 0.67 (calculated as a/b ; see the figure, A). Spinal fluid analysis including cell count, chemistry, hematology, cytology, and immunoelectrophoresis for oligoclonal bands; bilateral median nerve somatosensory evoked responses; brain MRI with and without gadolinium; and brain and cervical MR angiography were normal. There were no further episodes with bed rest. Laminoplasties were performed from C4 through C7, with bilateral C7 laminotomy, and the patient has remained asymptomatic.

Discussion. Neurapraxia usually refers to focal segmental demyelination of a peripheral nerve with partial or complete conduction block.⁷ The clinical entity of cervical cord neurapraxia appears to be an electrical phenomenon that can be induced experimentally by mild trauma. The pathophysiology is postulated to be related to stretch-induced axonal membrane hyperpermeability to calcium, resulting in reversible axonal depolarization.⁶

Our patient developed recurrent CCN, without a history of antecedent trauma, as the heralding manifestation of incipient cervical compressive myelopathy. The presentation with transient left hemiplegia has a differential diagnosis that includes TIA, seizure, and migraine. The time course on the order of seconds, the lack of involvement of cranial muscles, the stereotypical nature, and the absence of headache argue against these possibilities. The intrinsic cord signal abnormality at the site of spinal stenosis, negative workup for tumor and demyelinating disease, response to rest, and cure by neurosurgical decompression help establish the diagnosis.

This case demonstrates that CCN, previously thought to occur exclusively following minor trauma in otherwise healthy athletes with narrowing of the cervical spinal canal, may occur in the absence of trauma in adults with incipient compressive cervical myelopathy. The anatomically fixed lesion in cervical spinal stenosis may have a dynamic physiologic component precipitated by minor strain and movement. Cervical cord neurapraxia is thus a consideration in the differential diagnosis of TIA.

Acknowledgment

Dr. Jean-Valerie Coumans performed the surgery in this case.

From the Department of Neurology, Massachusetts General Hospital, and Harvard Medical School, Boston, MA.

Supported in part by the Birmingham Foundation (J.D.S.).

Disclosure: The authors report no conflicts of interest.

Received November 15, 2004. Accepted in final form June 27, 2005.

Address correspondence and reprint requests to Dr. Jeremy D. Schmahmann, Department of Neurology, Massachusetts General Hospital, CPZS-340, Fruit Street, Boston, MA 02114; e-mail: jschmahmann@partners.org

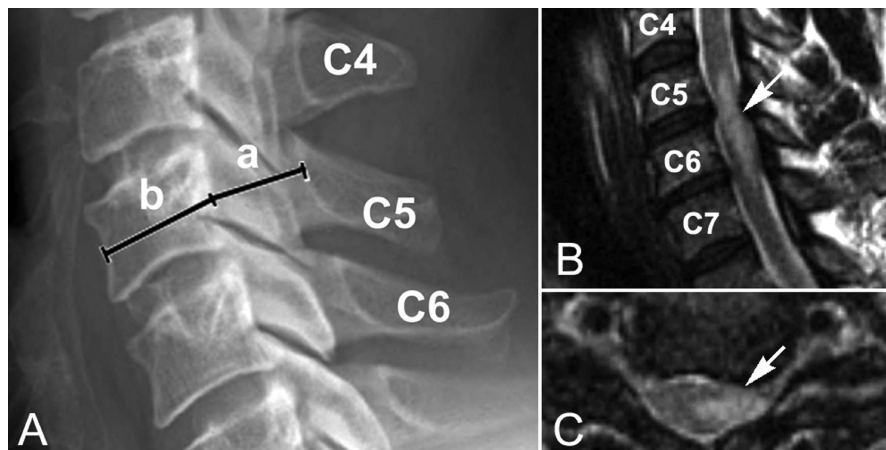


Figure. (A) Measurement of the ratio of the sagittal diameter of the spinal canal (a/b) in this case. (B) Sagittal and (C) axial T2-weighted MRI scans of cervical spine showing subtle cord compression with intrinsic cord signal abnormality at C5–C6 (arrows).

References

1. Brain WR, Northfield D, Wilkinson M. The neurological manifestations of cervical spondylosis. *Brain* 1952;75:187–225.
2. Smith BH. *Cervical spondylosis and its neurological complications*. Springfield, IL: Charles C. Thomas; 1968.
3. Wallack EM, Ng KW, Lockhart WS. Hemiparesis in cervical spondylosis. *JAMA* 1976;236:2524–2525.
4. Torg JS, Pavlov H, Genuario SE, et al. Neurapraxia of the cervical cord with transient quadriplegia. *J Bone Joint Surg Am* 1986;68:1354–1370.
5. Pavlov H, Torg JS, Robie B, et al. Cervical spinal stenosis: determination with vertebral body ratio method. *Radiology* 1987;164:771–775.
6. Torg JS, Corcoran TA, Thibault LE, et al. Cervical cord neurapraxia: classification, pathomechanics, morbidity, and management guidelines. *J Neurosurg* 1997;87:843–850.
7. Castaldo JE, Ochoa JL. Mechanical injury of peripheral nerves. Fine structure and dysfunction. *Clin Plast Surg* 1984;11:9–16.

FALL CONFERENCE

2005 AAN Fall Conference October 28–30, 2005
The Westin Philadelphia, Philadelphia, PA

The AAN Fall Conference is a three-day event designed to fulfill your educational needs, provide a way to network with colleagues, and help you earn CME credits. Enhance your daily practice by learning about the major advances in neurology, training your office staff on the latest coding issues, or getting tips on making the most out of current office technology.

For more information, visit the AAN Web site at www.aan.com/fallconf or call AAN Member Services at (800) 879-1960 or (651) 695-2717 (international).

Neurology[®]

Compressive myelopathy presenting as cervical cord neurapraxia: A differential diagnosis of TIA

Thomas Cochrane and Jeremy D. Schmammann

Neurology 2005;65;1140-1141

DOI 10.1212/01.wnl.0000178892.89896.c1

This information is current as of October 10, 2005

Updated Information & Services	including high resolution figures, can be found at: http://www.neurology.org/content/65/7/1140.full.html
References	This article cites 6 articles, 1 of which you can access for free at: http://www.neurology.org/content/65/7/1140.full.html##ref-list-1
Subspecialty Collections	This article, along with others on similar topics, appears in the following collection(s): All Cerebrovascular disease/Stroke http://www.neurology.org/cgi/collection/all_cerebrovascular_disease_stroke All Spinal Cord http://www.neurology.org/cgi/collection/all_spinal_cord Disc disease http://www.neurology.org/cgi/collection/disc_disease
Permissions & Licensing	Information about reproducing this article in parts (figures, tables) or in its entirety can be found online at: http://www.neurology.org/misc/about.xhtml#permissions
Reprints	Information about ordering reprints can be found online: http://www.neurology.org/misc/addir.xhtml#reprintsus

Neurology® is the official journal of the American Academy of Neurology. Published continuously since 1951, it is now a weekly with 48 issues per year. Copyright . All rights reserved. Print ISSN: 0028-3878. Online ISSN: 1526-632X.

