

CASE REPORT

Ovarian hyperstimulation syndrome and deep cerebral venous thrombosis

JOHN J. WATERSTONE
Research Fellow

BEATRICE A. SUMMERS
Senior Registrar in Neurology

MARGARETTA C. HOSKINS
Senior Registrar in Radiology

JOHN BERRY
Medical Student

JOHN H. PARSONS
Consultant Gynaecologist

King's College Hospital, London SE5 8RX, UK

Case report

A 29-year-old woman with amenorrhoea and polycystic ovaries attended for ovulation induction. Previous treatment had resulted in a triplet pregnancy complicated by ovarian hyperstimulation syndrome. That pregnancy had ended in a vaginal delivery at 24 weeks with one baby surviving. After clomiphene citrate treatment had failed, intramuscular injections of follicle stimulating hormone (FSH), 75 IU daily, were started. This dose was gradually increased in an attempt to avoid overstimulation. Follicle growth was monitored by vaginal ultrasonography. On 31.1.90, after 23 days of FSH, there were two large follicles (20 and 18 mm) and many smaller ones (all <14 mm); human chorionic gonadotrophin (hCG), 5000 units, was given.

The patient complained of abdominal swelling on 4.2.90. Deterioration with vomiting and headache led to hospital admission on 9.2.90. She had ascites with a packed cell volume (PCV) of 58% and a blood urea of 11.6 mmol/l. She received intravenous crystalloids and her condition improved although her abdomen became more distended. Fluid balance was monitored and urine output remained normal. A sudden left hemiparesis occurred on 12.2.90, at which time the PCV and blood urea were 44% and 4.4 mmol/l respectively. On 13.2.90 7.9 litres of fluid were removed by ultrasound directed paracentesis and ovarian cyst aspiration. Power returned rapidly to the patient's hand but a mild weakness of the hand and face persisted over the following days and was accompanied by episodic confusion. A left focal fit on 20.2.90 preceded further weakness and drowsiness. She became mute, with absent

cough and gag reflexes and impaired swallow. Intra-arterial digital subtraction angiography (Fig. 1) showed thrombus in the right transverse sinus and occlusion of the internal cerebral vein and vein of Galen; intravenous heparin (30 000 units daily) was started. She was fed by nasogastric tube. On 24.2.90 a further 6.3 litres of fluid were removed by paracentesis and cyst aspiration. Despite a positive pregnancy test an intra-uterine gestation sac was never seen on scan; bleeding started on 22.2.90 and serum levels of hCG dropped sharply. An early miscarriage was diagnosed and the anticoagulation therapy was changed to warfarin. The bilateral basal ganglia impairment gradually improved and the patient was discharged for rehabilitation on 15.3.90.

Follow-up 28 months later showed that her handwriting remained slightly impaired but she has returned to competitive sport.

Discussion

The ovarian hyperstimulation syndrome is a complication of superovulation treatment. Its pathogenesis is uncertain but a fluid shift from the vascular space explains the ovarian swelling, ascites, haemoconcentration and oliguria that occur. Thromboembolism is the most dangerous manifestation of the syndrome and there have been reports of cerebral infarction (Rizk *et al.* 1990) which was fatal in one patient (Mozes *et al.* 1965), deep venous thrombosis (Kaaaja *et al.* 1989) and leg amputation (Mozes *et al.* 1965). This is the first report of deep cerebral venous thrombosis in association with the syndrome. Probably, extreme haemoconcentration, hyperviscosity and stasis predispose to thrombosis, but increased levels of coagulation factors and platelets have also been described (Phillips *et al.* 1975). In our patient, although the haematocrit was elevated initially (58%), it had returned to normal by the time hemiparesis occurred; thrombus may have been present already at the time of admission.

The ovarian hyperstimulation syndrome is a danger when large numbers of follicles grow in response to ovulation induction. An exaggerated response is particularly likely in women with polycystic ovaries; such women should be identified by pretreatment investigations and should receive a low dose of gonadotrophins. Unfortunately, even with an initial low dose, slowly increased, some women either fail to respond or develop too many follicles. If too many follicles grow, ovarian hyperstimulation may be prevented by withholding hCG or converting to management by in-vitro fertilization; experience with superovulation and oocyte collection suggests that fol-

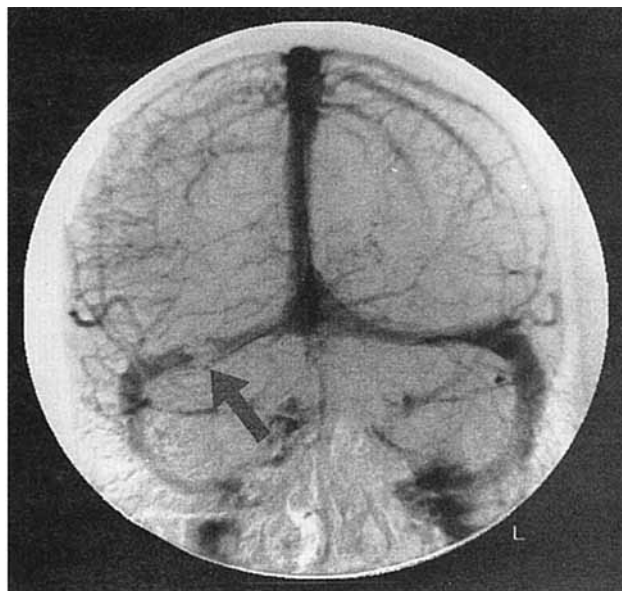


Fig. 1. Venous phase of cerebral digital subtraction study showing thrombus (filling defect arrowed) in the right transverse sinus.

licle aspiration has a protective effect. Patients must be warned about the ovarian hyperstimulation syndrome before treatment is started and should be encouraged to return for review if significant abdominal swelling occurs. Vomiting is a particularly worrying symptom and may increase the risk of thromboembolism by exacerbating haemoconcentration.

Established severe ovarian hyperstimulation syndrome is treated with intravenous fluids to correct haemoconcentration and oliguria, although this may increase ascites. Previously, paracentesis was not recommended but is now gaining favour;

not only does it relieve abdominal discomfort and respiratory embarrassment, but it may also promote a diuresis and accelerate resolution of the disease (Aboulghar *et al.* 1990). Therapeutic aspiration of ovarian luteal cysts has not been reported before. Past advocates of paracentesis have avoided ovarian puncture for fear of bleeding (Padilla *et al.* 1990), but this should not be a significant risk if ultrasound control is used.

References

- Aboulghar M. A., Mansour R. T., Serour G. I. & Amin Y. (1990) Ultrasonically guided vaginal aspiration of ascites in the treatment of severe ovarian hyperstimulation syndrome. *Fertil Steril* **53**, 933–935.
- Kaaja R., Sieberg S., Tiitinen A. & Koskimies A. (1989) Severe ovarian hyperstimulation syndrome and deep venous thrombosis. *Lancet* **ii**, 1043.
- Mozes M., Bogokowsky H., Antebi E., Lunenfeld B., Rabau E., Serr D. M., David A. & Salomy M. (1965) Thromboembolic phenomena after ovarian stimulation with human gonadotrophins. *Lancet* **ii**, 1213–1215.
- Padilla S. L., Zamaria S., Baramki T. A. & Garcia J. E. (1990) Abdominal paracentesis for the ovarian hyperstimulation syndrome with severe pulmonary compromise. *Fertil Steril* **53**, 365–367.
- Phillips L. L., Gladstone W. & van de Wiele R. (1975) Studies of the coagulation and fibrinolytic systems in hyperstimulation syndrome after administration of human gonadotropins. *J. Reprod Med* **14**, 138–143.
- Rizk B., Meaghar S. & Fisher A. M. (1990) Severe ovarian hyperstimulation syndrome and cerebrovascular accidents. *Hum Reprod* **5**, 697–698.

Received 28 October 1991

Accepted 21 November 1991

ERRATUM

FIGO staging for corpus cancer

We regret that there was a serious error in our report of the revised staging for corpus cancer published in our 1989 volume (*Br J Obstet Gynaecol* **96**, p. 889), Stage IIIB was incorrectly described and stage IIIC was omitted. The correct classification is as follows:

Stage		
IA	G123	Tumour limited to endometrium
IB	G123	Invasion to <½ myometrium
IC	G123	Invasion to >½ myometrium
IIA	G123	Endocervical glandular involvement only
IIIB	G123	Cervical stromal invasion
IIIA	G123	Tumour invades serosa and/or adnexa and/or positive peritoneal cytology
IIIB	G123	Vaginal metastases
IIIC	G123	Metastases to pelvic and/or para-aortic lymph nodes
IVA	G123	Tumour invasion of bladder and/or bowel mucosa
IVB		Distant metastases including intra-abdominal and/or inguinal lymph nodes

We are grateful to Dr Tan Kok Hian of Singapore for drawing our attention to this error.