

Vascular

# Brain stem ischemia from intracranial dural arteriovenous fistula: Case report

Motoyoshi Satoh, MD<sup>a,\*</sup>, Mitsuo Kuriyama, MD<sup>a</sup>, Takashi Fujiwara, MD<sup>a</sup>,  
Koji Tokunaga, MD<sup>b</sup>, Kenji Sugi, MD<sup>b</sup>

<sup>a</sup>Department of Neurological Surgery, Kure Kyosai Hospital, Kure, Hiroshima 737-8505, Japan

<sup>b</sup>Department of Neurological Surgery, Okayama University Graduate School of Medicine and Dentistry, Okayama 700-8558, Japan

Received 11 October 2004; accepted 20 December 2004

## Abstract

**Background:** Intracranial dural arteriovenous fistulas (AVFs) with spinal perimedullary venous drainage are rarely reported, but most of the patients initially have presented with myelopathy or subarachnoid hemorrhage. This is the first report of the intracranial dural AVF patient who presented with brain stem infarction.

**Case Description:** A 38-year-old woman experienced nausea and vomiting with an acute onset, followed by vertigo. Magnetic resonance imaging showed ischemic lesion in the medulla oblongata, and she was then sent to our hospital. On admission, she had nystagmus, swallowing difficulties, Horner syndrome, and right hemiparesis and hemisensory disturbance. Cerebral angiography revealed dural AVF draining into spinal perimedullary veins at the left transverse-sigmoid sinus. The patient was treated by transvenous embolization under local anesthesia. A microcatheter proceeded to the left sigmoid sinus via the internal jugular vein, and embolization of the sinus was performed using coils without complications. The patient's swallowing difficulties improved over a few days after the embolization, and 1 month later, there remained only a right mild hemiparesis and hemisensory disturbance. Six months after the onset, there was no ischemic lesion in the brain stem on magnetic resonance imaging.

**Conclusions:** In this case, we showed the possibility of brain stem infarction, caused by the intracranial dural AVF.

© 2005 Elsevier Inc. All rights reserved.

## Keywords:

Brain stem ischemia; Dural arteriovenous fistula; Transvenous embolization

## 1. Introduction

Intracranial dural arteriovenous fistulas (AVFs) account for approximately 12% of all intracranial arteriovenous malformations [8], but the type of intracranial dural AVF with spinal perimedullary venous drainage is rare [2,4]. Most of such patients have presented with myelopathy or subarachnoid hemorrhage, and in case of myelopathy, brain stem signs appear to occur at a later stage of the clinical course [1,2,4,5,9]. We, however, have experienced an intracranial dural AVF patient who had brain stem infarction,

which was not accompanied by myelopathy. A transvenous embolization was performed, and the symptoms of the brain stem were improved. To our knowledge, this is the first case report of the intracranial dural AVF presenting with brain stem infarction.

## 2. Case presentation

A 38-year-old woman experienced nausea and vomiting with a sudden onset, followed by vertigo. She initially presented to her general practitioner, and a stroke was suspected. Magnetic resonance imaging (MRI) showed ischemic lesion in the medulla oblongata, and she was then sent to our hospital. On admission, she had nystagmus, swallowing difficulties, and Horner syndrome on the right side. In addition, she complained of right paresthesia in her

\* Corresponding author. Department of Neurological Surgery, Okayama Kyokuto Hospital, Okayama 703-8265, Japan. Tel.: +81 86 276 3231; fax: +81 86 274 1028.

E-mail address: [motoyoshisato@hotmail.com](mailto:motoyoshisato@hotmail.com) (M. Satoh).

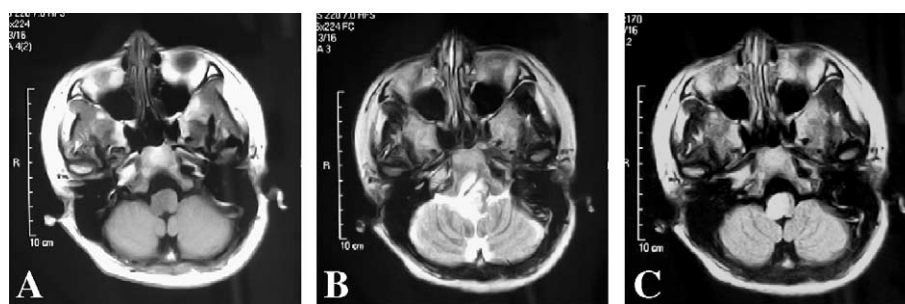


Fig. 1. T1-weighted axial image showing low signal over the right half area in the medulla oblongata (A). T2-weighted (B) and FLAIR (C) axial images showing high signal over the right half area in the medulla oblongata.

upper and lower extremities. Mild weakness affected her right upper and lower limbs, but her upper and lower limbs on the left side were neurologically normal.

Her medical history consisted of schizophrenia. She was orally on major tranquilizers such as phenothiazine and benzamide derivatives. They were injected intramuscularly after admission because her swallowing difficulties were severe.

MRI (T1- and T2-weighted sequences and FLAIR [fluid-attenuated inversion recovery] sequence) showed

ischemic lesion over the right half area of the medulla oblongata (Fig. 1). Cerebral angiography revealed a dural AVF draining into spinal perimedullary veins at the left transverse-sigmoid sinus. Left external carotid artery angiogram demonstrated a dural AVF fed by the petrosal and posterior branches of the middle meningeal artery, transosseous dural branch of the occipital artery, and ascending pharyngeal artery (Fig. 2A). In addition, the dural AVF was supplied by the meningohypophyseal trunk of the left internal carotid artery (Fig. 2B) and posterior

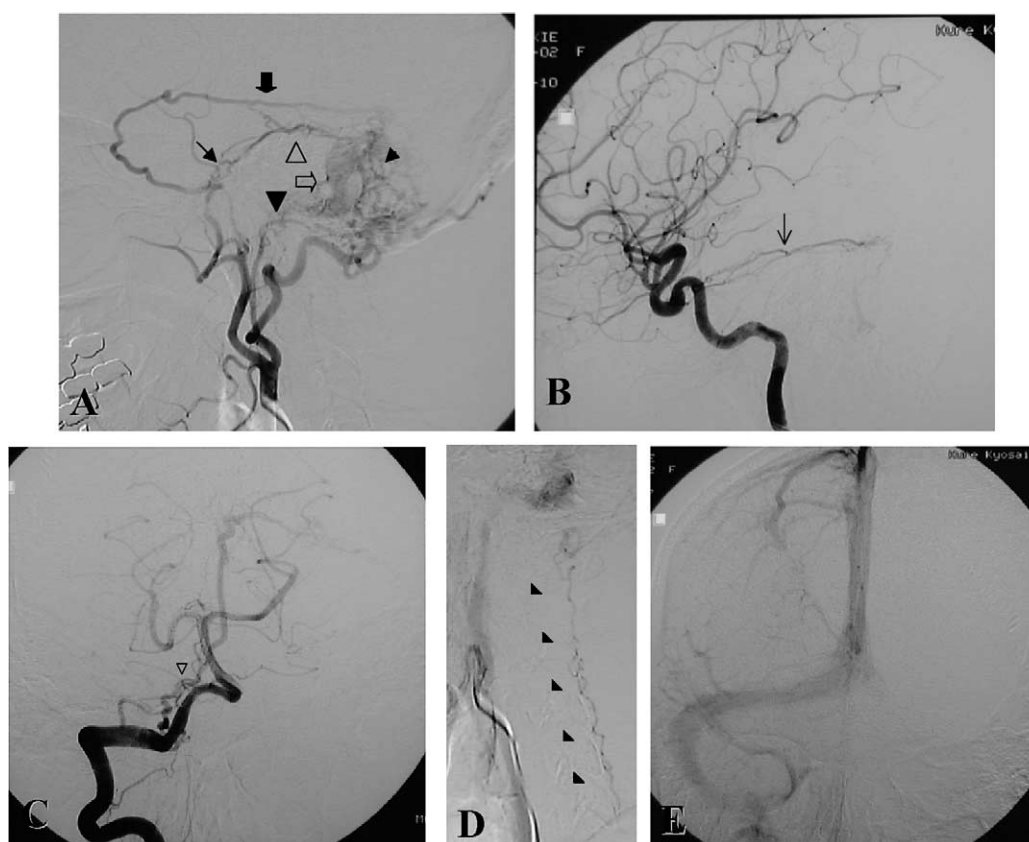


Fig. 2. Left external carotid artery angiogram demonstrating a AVF fed by the petrosal (small arrow) and posterior branch (large arrow) of the middle meningeal artery, transosseous dural branch of the occipital artery (small arrowhead), and ascending pharyngeal artery (large arrowhead) (A). Left internal carotid artery (B) and right vertebral artery angiograms (C) demonstrating a dural AVF supplied by the meningohypophyseal trunk of the left internal carotid artery (open small arrow) and posterior meningeal branch of the right vertebral artery (open small arrowhead), respectively. The fistulas were located on the left superior petrosal sinus (open large arrowhead) and transverse-sigmoid sinus (open large arrow) junction and drained into the posterior spinal perimedullary vein (half arrowheads) through the sigmoid sinus (D). The left transverse sinus was occluded (E).

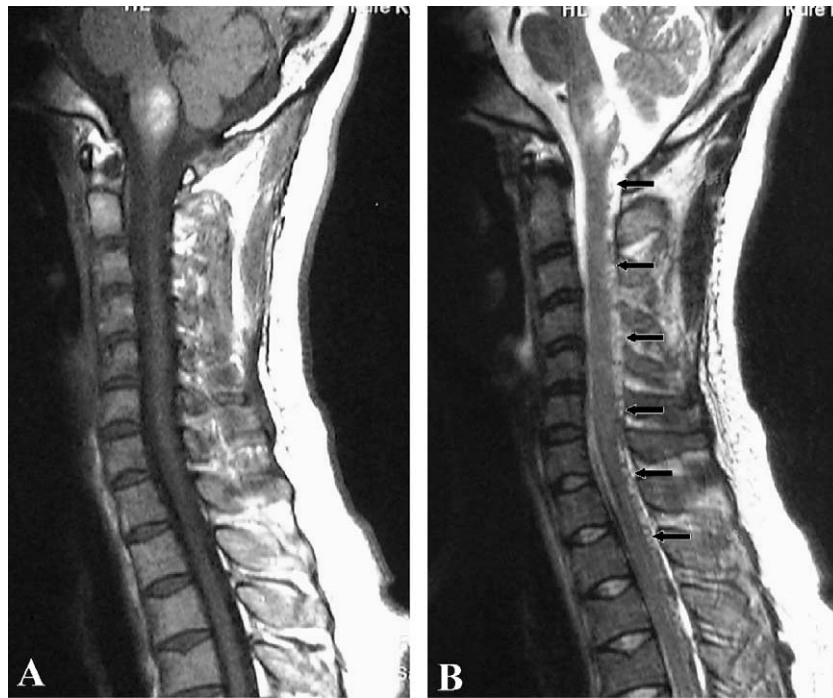


Fig. 3. T1-weighted (A) and T2-weighted (B) sagittal images showing high signal in the medulla oblongata. T2-weighted sagittal image demonstrating the enlarged posterior perimedullary vein behind the cervical cord as flow-void sign (arrows). The cervical cord was intact on MRI.

meningeal branch of the right vertebral artery (Fig. 2C). The fistulas were located on the left transverse-sigmoid sinus (Fig. 2A) and drained into the posterior spinal perimedullary vein through the sigmoid sinus (Fig. 2D). The left transverse sinus was occluded, whereas proximal sigmoid sinus and internal jugular vein were intact (Fig. 2E).

Cranial and cervical MRIs were followed up before the endovascular surgery. T1- and T2-weighted images showed high intensity in the medulla oblongata, which meant hemorrhage (Fig. 3A and B). T2-weighted sequences

demonstrated the enlarged posterior perimedullary vein behind the cervical and thoracic cord as flow-void sign (Fig. 3B). The cervical cord was intact on MRI.

Embolization was performed to occlude the affected sigmoid sinus using coils transvenously. The affected sinus was successfully occluded with platinum coils. The dural AVF was completely obliterated, and venous hypertension of the posterior fossa and spinal cord was released (Fig. 4). The patient's swallowing difficulties improved over a few days after the embolization, and 1 month later, there remained only a right slight hemiparesis and hemipares-

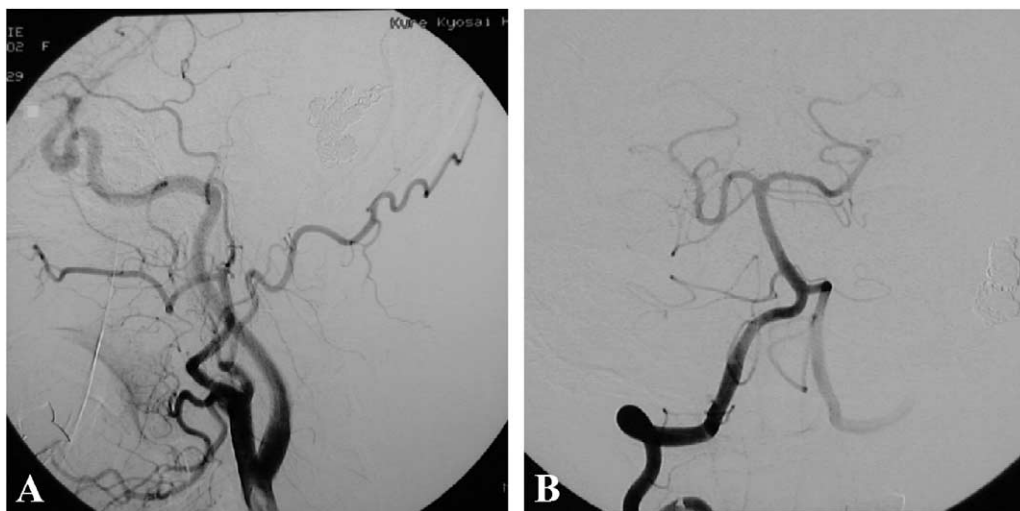

Fig. 4. Left common carotid artery (A) and right vertebral artery (B) angiograms after embolization. The dural AVF was completely obliterated.

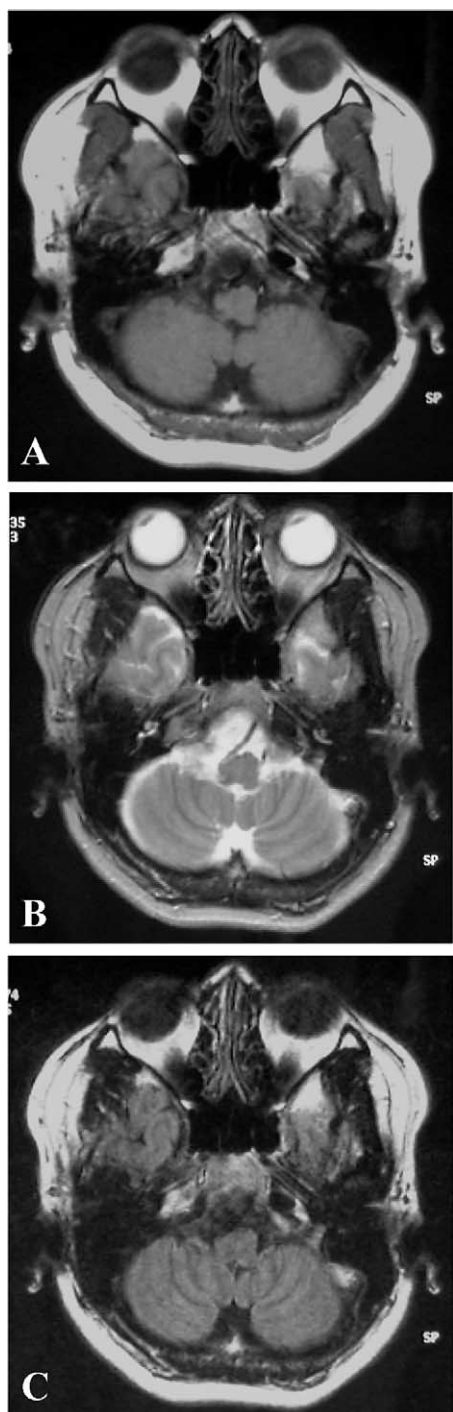


Fig. 5. T1-weighted (A), T2-weighted (B) and FLAIR (C) axial images after embolization. The low signals on T1-weighted sequences or high signals on T2-weighted and FLAIR sequences were remarkably reduced in the medulla oblongata.

thesia. Follow-up angiography was carried out 1 month later, and the dural AVF was completely obliterated. On MRI, the high signals on T1- and T2-weighted sequences and FLAIR sequence were remarkably reduced in the medulla oblongata (Fig. 5).

### 3. Discussion

We have experienced a dural AVF with spinal perimedullary venous drainage. This belongs to type V in the classification of Cognard et al [2]. In type V dural arteriovenous malformation, both anterior and posterior spinal perimedullary veins via pontomesencephalic vein have been observed as draining veins from AVFs [1,2,4,9]. Gobin et al [4] previously suggested that the venous drainage around the brain stem such as the pontomesencephalic vein might be related to brain stem signs. Indeed, in cases of intracranial dural AVFs draining into the spinal veins, the occurrences of myelopathy are attributable to the venous congestion of the spinal cord [1,12]. In the present case, we observed posterior spinal perimedullary vein through the sigmoid sinus, but anterior spinal perimedullary and pontomesencephalic veins were not seen. Moreover, the bulbar ischemia occurred on the opposite side from the dural AVM. This indicates that brain stem ischemia without myelopathy may not only be ascribed to anatomic connection of the draining veins, but also to hemodynamic mechanism at the onset.

As the cause of cerebral or spinal ischemia by AVFs, there are 3 possibilities: venous hypertension, arterial steal, and direct compression by enlarged veins. In the intracranial dural AVF patients with myelopathy, edema by the venous congestion is the main cause of the spinal ischemia because intracranial feeding arteries do not flow into the spinal cord. Some of the patients have been reported to have had sinus thrombosis simultaneously, and the symptom of increased intracranial pressure such as headache or nausea with acute onset preceded myelopathy in such cases [4]. This means that the venous drainage into the spinal perimedullary veins may proceed gradually after sinus thrombosis and subsequently lead to ascending myelopathy owing to edema of the spinal cord. Meanwhile, in our case, intracranial hypertension and brain stem signs appeared at approximately the same time. We suppose that she had nausea and vomiting when the transverse sinus was thrombosed. Sundt and Piepgras [10] postulated that, as the cause of increased intracranial pressure, there is the impairment of venous runoff from associated major sinus occlusion besides intrasinus hypertension by high flow into the draining sinus. The former mechanism seems to induce acute onset of headache or vomiting, comparing with the latter.

The dural AVF existed on the left transverse-sigmoid sinus, but the draining vein was posterior spinal perimedullary vein through the sigmoid sinus. This may explain the occurrence of the bulbar ischemia on the opposite side from the dural AVF because there is no guarantee that all the veins draining into the posterior spinal perimedullary vein exist on the same side of the dural AVF. On MRI before embolization, we observed a hemorrhage in the ischemic territory of the medulla oblongata. Considering that hemorrhage occurs near the malformation or aneurysmally dilated

draining veins [11], there might be a possibility of the hemorrhage owing to the dilated draining veins in this case.

Besides venous hypertension, there might be a possibility of the steal of right posterior inferior cerebellar artery (PICA) for the bulbar ischemia. Indeed, there was a fistula between posterior meningeal branch of the right vertebral artery and the transverse sinus. We, however, could identify PICA on angiogram. In addition, the arterial feeder was not a direct branch of PICA, and Kosnik et al [6] reported that flow problems were created by increased venous pressure more than by arterial steal. Considering these points, there might be little possibility of arterial steal. Meanwhile, brain stem compression by enlarged veins was not observed in this case.

Transvenous embolization was performed in the present case. Mullan [7] has pointed out that dural AVFs can be permanently cured by venous side occlusion because these malformations are primarily venous-based lesions. Transvenous embolization is now recognized as 1 of the most effective treatment of dural AVFs [3], and we also observed the complete obliteration of the dural AVF and spontaneous disappearance of arterial input after transvenous embolization.

To our knowledge, there has been no report of intracranial dural AVF patients who initially have presented with brain stem ischemia. This case has indicated ischemic lesion in the brain stem by dural AVF without the spinal cord lesion. In patients who have brain stem symptoms and who exhibit the ischemic lesion over a wide brain stem area on MRI, a cerebral angiography should be undertaken, taking dural AVFs into consideration.

## References

- [1] Bret P, Salzmann M, Bascoulergue Y, et al. Dural arteriovenous fistula of the posterior fossa draining into the spinal medullary veins—an unusual cause of myelopathy: case report. *Neurosurgery* 1994;35:965–9.
- [2] Cognard C, Gobin YP, Pierot L, et al. Cerebral dural arteriovenous fistulas: clinical and angiographic correlation with a revised classification of venous drainage. *Radiology* 1995;194:671–80.
- [3] Endo S, Kuwayama N, Takaku A, et al. Direct packing of the isolated sinus in patients with dural arteriovenous fistulas of the transverse-sigmoid sinus. *J Neurosurg* 1998;88:449–56.
- [4] Gobin YP, Rogopoulos A, Aymard A, et al. Endovascular treatment of intracranial dural arteriovenous fistulas with spinal perimedullary venous drainage. *J Neurosurg* 1992;77:718–23.
- [5] Kalamangalam GP, Bhattacharya J, Teasdale E, et al. Myelopathy from intracranial dural arteriovenous fistula. *J Neurol Neurosurg Psychiatry* 2002;72:816–8.
- [6] Kosnik EJ, Hunt WE, Miller CA. Dural arteriovenous malformations. *J Neurosurg* 1974;40:322–9.
- [7] Mullan S. Reflections upon the nature and management of intracranial and intraspinal vascular malformations and fistulae. *J Neurosurg* 1994;80:606–16.
- [8] Newton TH, Cronqvist S. Involvement of the dural arteries in intracranial arteriovenous malformations. *Radiology* 1969;93:1071–8.
- [9] Ricolfi F, Manelfe C, Meder JF, et al. Intracranial dural arteriovenous fistulae with perimedullary venous drainage. Anatomical, clinical and therapeutic considerations. *Neuroradiology* 1999;41:803–12.
- [10] Sundt Jr TM, Piepgras DG. The surgical approach to arteriovenous malformations of the lateral and sigmoid dural sinuses. *J Neurosurg* 1983;59:32–9.
- [11] Viñuela F, Fox AJ, Pelz DM, et al. Unusual clinical manifestations of arteriovenous malformations. *J Neurosurg* 1986;64:554–8.
- [12] Wrobel CJ, Oldfield EH, di Chiro G, et al. Myelopathy due to intracranial dural arteriovenous fistulas draining intrathecally into spinal medullary veins: report of three cases. *J Neurosurg* 1988;69:934–9.

---

## Commentary

The authors report an excellent case of dural fistula of the left sigmoid sinus complicated by brain stem ischemia and medullary venous drainage. As the left sigmoid sinus was already thrombosed, the decision for coil embolization of the sinus was excellent, with complete cure of the fistula.

Gerard Debrun, MD  
Interventional Neuroradiologist  
29360 Paris, France