

PARATHYROID APOPLEXY MANIFESTING AS FEVER OF UNKNOWN ORIGIN

Lubna M. Zuberi, MD,¹ Jamsher J. Talati, MBBS, FRCS,² Abdul Jabbar, MBBS, FRCP,³
and Naila Kayani, MD⁴

ABSTRACT

Objective: To describe a rare clinical presentation of necrosis of a parathyroid adenoma, manifesting as fever of unknown origin.

Methods: We present a case report, including detailed clinical and laboratory data, of a patient with previously undiagnosed primary hyperparathyroidism in whom necrosis of a parathyroid adenoma developed during a psychiatric admission for depression.

Results: A 40-year-old woman was admitted with severe depression. During her hospitalization, she was found to have osteitis fibrosa cystica, pathologic fractures of her left femur, and primary hyperparathyroidism. Shortly after her admission, spontaneous necrosis of her parathyroid adenoma developed, in association with high-grade fever, acute hypercalcemic crisis, neck pain, hypophonia, and shortness of breath. Findings on extensive evaluation of the fever remained unremarkable, with persistent high-grade temperatures that resolved postoperatively.

Conclusion: Spontaneous necrosis of a parathyroid adenoma is a rare but well-documented complication of primary hyperparathyroidism. Fever, a previously undocumented associated finding, might be a part of the clinical syndrome of this complication. (*Endocr Pract.* 2005;11:180-183)

Abbreviations:

OFC = osteitis fibrosa cystica; PTH = parathyroid hormone

INTRODUCTION

Infarction of, or hemorrhage into, a parathyroid adenoma is a well-recognized albeit rare complication of primary hyperparathyroidism. It was first reported in 1934 by Capps (1). His patient had cervical and mediastinal hemorrhage from an enlarged and hyperplastic parathyroid gland. Since that time, 30 cases have been reported in the medical literature. The early reports did not include measurements of parathyroid hormone (PTH) levels. In 1946, Norris (2) first included details of serum PTH levels in a patient with spontaneous infarction of a parathyroid adenoma.

We describe a patient who presented with osteitis fibrosa cystica (OFC) and pathologic fractures of her left femur and was diagnosed as having primary hyperparathyroidism. Subsequently, a high-grade fever and acute hypercalcemic crises developed. Extensive investigations related to the fever were unrevealing. She underwent parathyroidectomy, which showed necrosis and hemorrhage of a parathyroid adenoma. The fever resolved postoperatively.

CASE REPORT

A 40-year-old woman was admitted to the psychiatry service because of depression. After admission, she complained of severe pain in her left knee. She also gave a history of lower leg pain for 2 months, difficulty walking, and diffuse myalgias. Radiography of the left femur showed fracture of the femoral neck and an oblique fracture of the shaft, in conjunction with severe osteopenia. OFC of the pelvis was also noted. Subsequent to this x-ray study, the serum calcium level was found to be high at 12.7 mg/dL (with correction for the serum albumin level, it was 14.1 mg/dL) in association with a low serum phosphorus concentration of 1.7 mg/dL and an alkaline phosphatase value of 1,110 U/L (normal, 29 to 132). An intact PTH level was more than 2,500 pg/mL (normal, 7 to 53); thus, the diagnosis of primary hyperparathyroidism was confirmed. She was treated with hydration followed by 60 mg of pamidronate administered intravenously on the third hospital day.

Submitted for publication March 24, 2004

Accepted for publication September 22, 2004

From the ¹Department of Medicine, ²Section of Urology, ³Section of Endocrinology, and ⁴Department of Pathology, Aga Khan University Hospital, Karachi, Pakistan.

Address correspondence and reprint requests to Dr. Lubna M. Zuberi, Department of Medicine, The Aga Khan University, Stadium Road, P.O. Box 3500, Karachi 74800, Pakistan.

© 2005 AACE.

The clinical scenario was complicated by the onset of fever on the second hospital day. Evaluation at this point included a complete blood cell count, urinalysis, and synovial fluid aspiration of the left knee. The patient's total leukocyte count was elevated at $16.0 \times 10^3/\mu\text{L}$ with a shift to the left, and urinalysis results were suggestive of a urinary tract infection. Synovial fluid analysis and cultures showed normal findings. The patient was treated for a urinary tract infection, but her body temperature progressively increased to 40°C by the fifth hospital day. Concomitantly, hypophonia, neck rigidity, and neck tenderness also developed. Evaluation at this point included a repeated complete blood cell count, which indicated a decrease in her hemoglobin level from 10.4 g/dL to 8.2 g/dL (normal, 11.1 to 14.5) and a decrease of hematocrit from 31.6 to 24.1% (normal, 35.4 to 42.0%). The leukocyte count was $9.2 \times 10^3/\mu\text{L}$, with 81.2% neutrophils, 16.3% lymphocytes, 0.4% eosinophils, and 2.1% monocytes. Her platelet count was normal at $334 \times 10^3/\mu\text{L}$. Blood culture, urine culture, spinal tap, and chest radiography were unrevealing. The serum calcium concentration was 9.6 mg/dL (corrected for serum albumin, 11.0 mg/dL).

On the seventh hospital day, the patient was noted to be in respiratory distress, and findings on examination were suggestive of bronchospasm. Because her serum calcium level again began to increase (corrected calcium of 12.2 mg/dL), a second dose of pamidronate was administered on the 10th hospital day. Despite this measure, her hypercalcemia worsened, and she became lethargic, with a serum calcium level of 13.5 mg/dL (corrected, 14.9) by the 24th day of hospitalization. Fever persisted despite empiric administration of broad-spectrum antibiotics.

Fever work-up now included a computed tomographic scan of the abdomen and pelvis, but no clues were identified. An ultrasound study of the neck showed an isoechoic mass (26.2 by 23.5 by 24.0 mm) at the inferior pole of the left lobe of the thyroid.

A month after this prolonged hospital stay, the patient's serum calcium level began to decline spontaneously to 7.3 mg/dL (corrected, 8.7), and it reached a preoperative nadir of 6.6 mg/dL (corrected, 8.0). Serum phosphorus levels were not closely monitored, but a repeat measurement preoperatively was 2.5 mg/dL. The patient underwent parathyroidectomy on the 35th day of hospitalization. Histopathologic examination showed a 2.5-cm encapsulated adenoma of the parathyroid, most of which was necrosed, with areas of hemorrhage and a small limb of viable parathyroid tissue (Fig. 1). A culture of the necrotic tissue showed no bacterial growth. Her fever resolved postoperatively, but she required large replacement doses of calcium and vitamin D. Serial temperature measurements and serum calcium levels are shown in Figure 2. After almost 2 months of hospitalization, the patient was finally discharged. Her serum calcium concentration at that time was 8.2 mg/dL.

DISCUSSION

Primary hyperparathyroidism is a fairly common endocrine disorder (3) that manifests with bone disease in 30 to 40% of patients in developing countries (4,5). Infarction or hemorrhage (or both) of the parathyroid adenoma is a well-recognized event. Nylen et al (6) described this sudden spontaneous necrosis and hemorrhage of the parathyroid as "parathyroid apoplexy" and likened the

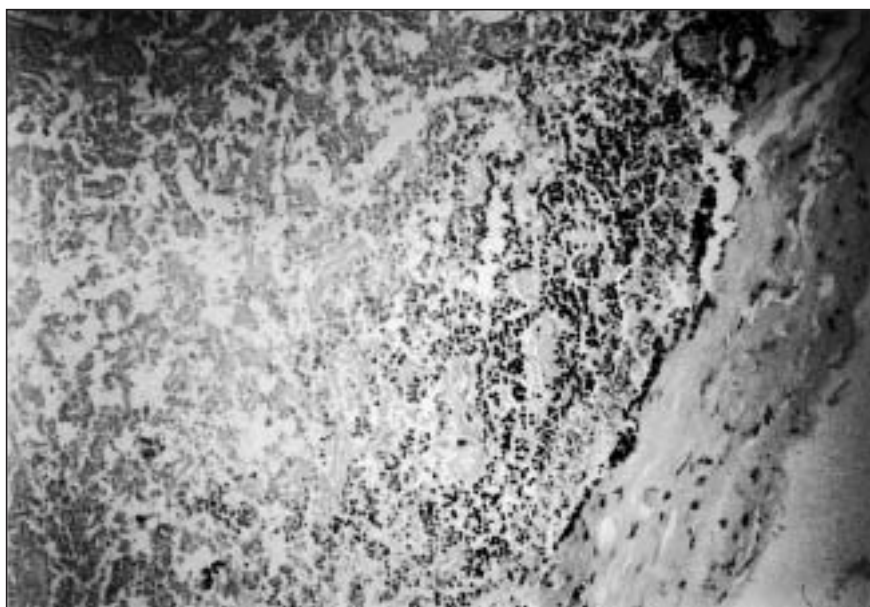


Fig. 1. Photomicrograph showing encapsulated parathyroid adenoma and viable parathyroid tissue at the right. Upper half shows necrotic parathyroid parenchyma. (Hematoxylin-eosin stain; original magnification $\times 100$.)

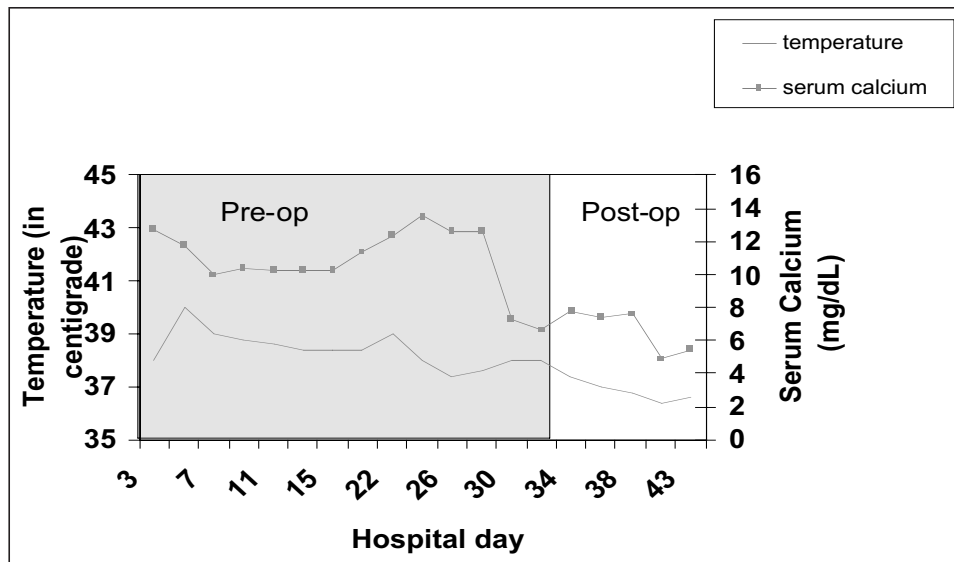


Fig. 2. Temperature and serum calcium trend during hospitalization of study patient, before and after parathyroidectomy.

dramatic initial manifestation to that seen in an acute hemorrhagic event in other endocrine tumors, such as pheochromocytomas and pituitary tumors.

The initial clinical features of this event are variable. Patients may present with asymptomatic decline in serum calcium and PTH levels (7,8). They may have mild neck pain or dysphagia (6,7), severe neck pain, or swelling of the neck along with respiratory distress and dysphonia (9-11). Cervical (12,13) and mediastinal hemorrhage (11) may occur as a result of spontaneous rupture and extracapsular hemorrhage of cervical and mediastinal adenomas.

Nylen et al (6) proposed a classification of patients with parathyroid apoplexy into type I, II, or III, based on the severity of their presentation. Patients subclassified as having "type III parathyroid apoplexy" are those who have acute severe pain (neck to substernal), dysphagia, dysphonia, hoarseness, stridor, hypercalcemic crisis, widened mediastinum, visible hematoma, or ecchymoses. One death has been reported in this subgroup of patients. Our patient categorically fulfills the description of type III parathyroid apoplexy, with an added complication of high-grade fever.

The initiating pathologic event of parathyroid infarction and hemorrhage is not clear. These glands are susceptible to hemorrhage during surgical exploration. Most likely, the process begins acutely, and depending on the extent of infarction, the presence of hemorrhage and extracapsular spread varies the initial clinical manifestations.

The sequela of this process is unclear because in most reported cases the patients underwent parathyroidectomy. In some patients, spontaneous remission of hyperparathyroidism does occur preoperatively (8,14,15), with reports describing development of spontaneous hypocalcemia (16) and even hypocalcemic tetany (17). Ours is another

such example, as evidenced by a declining serum calcium level preoperatively (measurement of intact PTH was not repeated). Whether these patients should undergo clinical follow-up once biochemical analysis reveals spontaneous remission cannot be answered definitively. Some published reports have described spontaneous remission (18), and others have demonstrated biochemical and radiologic recurrence of hypercalcemia and tumor 2 years after spontaneous resolution (16). Thus, some investigators express concern over the regenerative potential of partially infarcted adenomatous parathyroid tissue and advocate surgical treatment of all such patients (7).

What is clear is that these patients can become hemodynamically unstable and may require intensive medical care. Fever may also be a part of the syndrome of parathyroid apoplexy, with resolution after removal of the necrotic parathyroid tissue.

CONCLUSION

Our patient with primary hyperparathyroidism presented with the classic symptoms of bone disease associated with pathologic fractures and OFC. Her presentation was complicated by development of high-grade fever, resistant hypercalcemia, and subsequent sudden hypocalcemia, all of which could be related to precipitous infarction of the parathyroid adenoma followed by development of necrotic tissue. The decline in serum calcium concentration could have been due to the administration of bisphosphonates; however, there was clear histologic evidence of infarction. We suggest that fever should also be included as part of the syndrome of parathyroid apoplexy. Determining any possible role of bisphosphonates in provoking parathyroid necrosis necessitates further investigation.

REFERENCES

1. **Capps RB.** Multiple parathyroid tumors with massive mediastinal and subcutaneous hemorrhage: a case report. *Am J Med Sci.* 1934;188:801-805.
2. **Norris EH.** Primary hyperparathyroidism. *Arch Pathol.* 1946;42:261-273.
3. **Bringhurst FR, Demay MB, Kronenberg HM.** Hormones and disorders of mineral metabolism. In: Wilson JD, Foster DW, Kronenberg HM, Larsen PR, eds. *Williams Textbook of Endocrinology.* 9th ed. Philadelphia, PA: WB Saunders, 1998: 1155-1209.
4. **Harinarayan CV, Gupta N, Kochupillai N.** Vitamin D status in primary hyperparathyroidism in India. *Clin Endocrinol (Oxf).* 1995;43:351-358.
5. **Biyabani SR, Talati J.** Bone and renal stone disease in patients operated for primary hyperparathyroidism in Pakistan: is the pattern of disease different from the west? *J Pak Med Assoc.* 1999;49:194-198.
6. **Nylen E, Shah A, Hall J.** Spontaneous remission of primary hyperparathyroidism from parathyroid apoplexy. *J Clin Endocrinol Metab.* 1996;81:1326-1328.
7. **Lucas DG Jr, Lockett MA, Cole DJ.** Spontaneous infarction of a parathyroid adenoma: two case reports and review of the literature. *Am Surg.* 2002;68:173-176.
8. **McLatchie GR, Morris EW, Forrester A, Fogelman I.** Autoparathyroidectomy: a case report. *Br J Surg.* 1979;66:552-553.
9. **Korkis AM, Miskovitz PF.** Acute pharyngoesophageal dysphagia secondary to spontaneous hemorrhage of parathyroid adenoma. *Dysphagia.* 1993;8:7-10.
10. **Santos GH, Tseng CL, Frater RW.** Ruptured intrathoracic parathyroid adenoma. *Chest.* 1975;68:844-846.
11. **Hotes LS, Barzilay J, Cloud LP, Rolla AR.** Spontaneous hematoma of a parathyroid adenoma. *Am J Med Sci.* 1989;297:331-333.
12. **Jordan FT, Harness JK, Thompson NW.** Spontaneous cervical hematoma: a rare manifestation of parathyroid adenoma. *Surgery.* 1981;89:697-700.
13. **Kihara M, Yokomise H, Yamauchi A, Irie A, Matsusaka K, Miyauchi A.** Spontaneous rupture of parathyroid adenoma presenting as massive cervical hemorrhage: report of a case. *Surg Today.* 2001;31:222-224.
14. **Natsui K, Tanaka K, Suda M, Yasoda A, Yonemitsu S, Nakao K.** Spontaneous remission of primary hyperparathyroidism due to hemorrhagic infarction in the parathyroid adenoma. *Intern Med.* 1996;35:646-649.
15. **Mir R, Gerold T, Khan S, Weitz J.** Spontaneous infarction of parathyroid adenoma: case report and literature review. *Head Neck.* 1993;15:566-568.
16. **Chan WB, Chow CC, King AD, et al.** Spontaneous necrosis of parathyroid adenoma: biochemical and imaging follow-up for two years. *Postgrad Med J.* 2000;76:96-98.
17. **Johnston CC Jr, Schnute RB.** A case of primary hyperparathyroidism with spontaneous remission following infarction of the adenoma with development of hypocalcemic tetany. *J Clin Endocrinol Metab.* 1961;21:196-200.
18. **Kovacs KA, Gay JD.** Remission of primary hyperparathyroidism due to spontaneous infarction of a parathyroid adenoma: case report and review of the literature. *Medicine (Baltimore).* 1998;77:398-402.