

## CASE STUDY

# Foreign accent syndrome following traumatic brain injury

M. LIPPERT-GRUENER<sup>1</sup>, U. WEINERT<sup>2</sup>, T. GREISBACH<sup>3</sup>, & C. WEDEKIND<sup>1</sup>

<sup>1</sup>Department of Neurosurgery, University of Cologne, Cologne, Germany, <sup>2</sup>Department of Neurology, University of Cologne, Cologne, Germany, and <sup>3</sup>Institute of Phonetics, University of Cologne, Cologne, Germany

(Received 17 November 2003; accepted 14 February 2005)

### Abstract

Foreign accent syndrome (FAS) is a very rare disorder, caused by lesions of the dominant brain hemisphere and defined as a loss of normal phonetic contrast when using the mother language. The pronunciation is perceived by native speakers as compromised by a foreign accent. This study reports about a 35-year-old woman, with a FAS following a brain injury with a traumatic left temporal haemorrhage, who experienced excellent remission after 2 years.

**Keywords:** FAS, traumatic temporal haemorrhage, rehabilitation, speech disorder

### Introduction

Foreign accent syndrome (FAS) represents a rare disorder caused by lesions of the dominant brain hemisphere [1, 2]. It is defined as a loss of normal phonetic contrast when using the mother language. The pronunciation is perceived by native speakers as if compromised by a foreign accent. By now, 15 cases of FAS have been described in the literature; the majority of these patients suffered from brain ischemia [3–5]. Only four cases after traumatic brain injury (TBI) have been communicated so far [6–9].

This report presents a further case of FAS consequent to TBI.

### Case report

A native German woman of 35 years was the victim of a traffic accident. Without losing consciousness, she was admitted to the hospital. Two hours later, she presented with amnesic aphasia and became obtunded. She was then transferred to the Neurosurgical Department of the Cologne University and underwent CT scanning there. CT scans revealed traumatic haemorrhage in the left temporal lobe (Figure 1). The speech disorder

increased and finally ended up with severe global aphasia without any capacity to obey commands, to utter words or to write. Surprisingly, she had retained the capacity to obey commands expressed in English and to speak a few short English words. Figure 1 displays the MRI findings in terms of a traumatic left temporal haemorrhage.

After discharge from the Neurosurgical Department, she was admitted to a rehabilitation centre. At that time, neurologic examination revealed no deficits besides amnesic aphasia (with respect to German) and dysprosodia. Three months after trauma, the patient presented with minor aphasic symptoms in terms of amnesic aphasia. However, her German pronunciation was compromised by an English accent. The use of foreign languages (she was experienced in English and Spanish) was merely impossible. A neuropsychological examination at that time did not reveal further neuropsychological deficits. Six and also 12 months after injury, the condition had only slightly improved despite intensive training. Two years after the accident, however, the patient had recovered completely; FAS had remitted spontaneously without further therapeutic intervention.

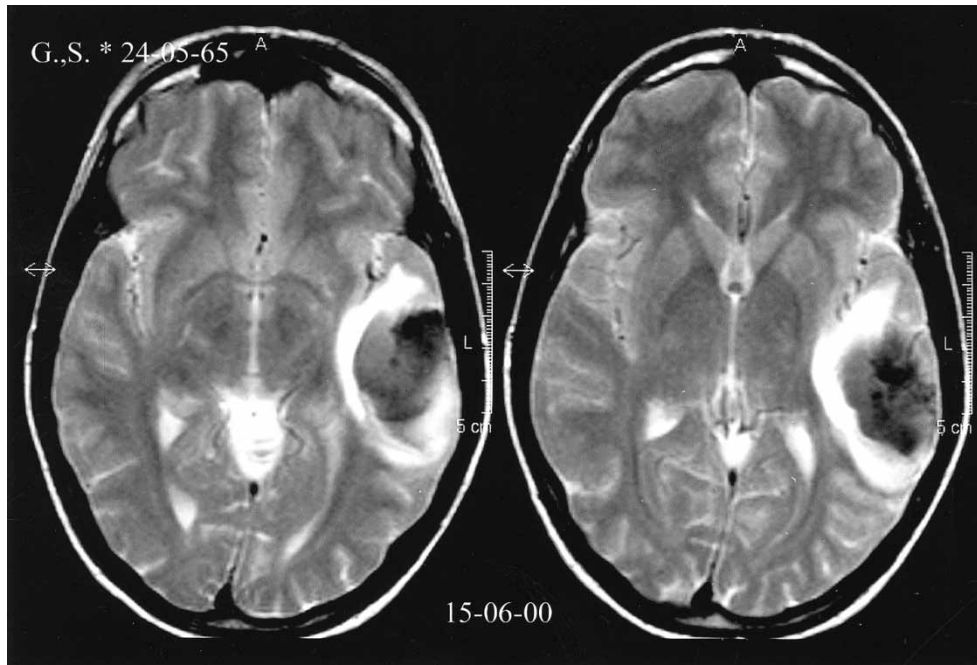


Figure 1. MRI ( $T_2$ -weighted sequence) of the patient described showing the left sided post-traumatic haemorrhagic lesion of the temporal lobe.

Table I. Definition of technical language used.

High vowels	Vowels produced with the tongue in a high position within the mouth, in German 'i', 'ü', 'u'.
Back vowels	Vowels produced with the tongue in a retracted position within the mouth, in German 'u', 'o'—in this case only 'u'.
Strong lowering and centralization	Tongue is not elevated so high as necessary and tends to remain in a central, undifferentiated position.
Unpredictable advancement or retraction	The tongue root can be shifted forward or backward in the mouth. This will alter the sound quality—unpredictable: This seems to be not systematic
Diphthong	Double vowel, in German 'au', 'ei', 'eu'.
Diphthongization	Vowel tends to change its quality at the end to a stronger constriction. Typical for the high vowels of English or Swedish, can be denoted as 'ij', 'uw'.
TCMA (transcortical motor aphasia)	Special kind of motor aphasia with well preserved reproduction of speech.
Amnesic aphasia	Type of aphasia with predominant impairment of retrieval of words, whereas understanding and communication facilities are well preserved.
Closure in dental plosives	Dental plosives are 't' and 'd'. Every plosive consist of a closure (in this case tongue tip is in contact with the palate) and a release (or plosion not to say explosion).
Palato-alveolar fricative	Phonetic term for 'sch'.
Palatal voiceless fricative	Phonetic term for the 'ich' sound.
'Schleifton'	This term is so specific that there is no appropriate term in English.
Strong lowering	The high vowels 'i', 'y' and 'u' tend to be pronounced 'e', 'ø' and 'o'.

**Phonetic findings**

An auditory phonetic analysis was performed on speech samples recorded 2 months after the accident. These recordings consisted of an interview of the patient by her speech therapist. A second recording was done 1 year after injury. It consisted of an interview and of reading a short text. The technical language used in the following is explained in Table I.

The auditory phonetic analysis of the first speech samples revealed some characteristic articulatory differences as opposed to native German speakers. The following phenomena were observed:

- (1) Vowels:
  - Strong lowering and centralization of the high vowels, especially of the back vowels in unaccented function words. Long vowels as well as short ones were affected.

Brain Inj Downloaded from informahealthcare.com by University of Connecticut on 06/17/13 For personal use only.

- Instability in tongue position concerning the vowel 'a', i.e. an unpredictable advancement or retraction of the tongue.
- Nasalization of diphthongs and long vowels.
- Slight diphthongization of long vowels.
- Unusual lengthening of short vowels.

(2) Consonants:

- Delayed release of the closure in dental plosives 't' and 'd' leading to a slight affrication.
- The palato-alveolar fricative sound 'sch' which is rounded in German appeared to be disrounded.
- The realization of the palatal voiceless fricative ('ich' sound in German) seemed to be more advanced as is typical for the German pronunciation in the Cologne area.

The word accent exhibited an additional lengthening of long vowels with an additional 'Schleifton'. The patients' articulatory jaw movements were strongly reduced with the jaw almost immobile during speech production.

The phonetic analysis of the speech samples showed specific variations from standard German pronunciation. The combination of these—especially strong lowering of high vowels, the sound quality of 'a' and diphthongization of long vowels—have evoked the impression of an English accent.

## Discussion

Among the total of 15 cases of FAS described in the literature, there were only four suffering from TBI [6–9]. Moonis et al. [8] analysed a female case of 59 years who exhibited a French accent in her English mother tongue. This developed after minor head injury without any structural brain damage as assessed by magnetic resonance imaging. Carbary et al. [6] have communicated a case of FAS suffering from head injury after a physical assault with a pre-existent lesion of the left frontal cortex. Gonzalez-Alvarez et al. [7] have published a case who developed FAS after TBI located in the right basal ganglia.

Most of the FAS cases reported so far, however, were caused by cerebral ischemia. Neuroimaging studies revealed lesions located in the dominant hemisphere mainly in the frontal pre-central cortex and white matter and also in associated sub-cortical structures (caudate nucleus, internal capsule) (reviewed in [6]). A PET study on the cerebral representation of a second language has put forward the role of left putaminal activation when speaking a second language [10].

In a patient presenting with FAS, Gurd et al. [11] failed to detect any neurological causes. They hypothesized that a functional disorder could also account for the development of FAS since voice disorders are 'a prototype of disorders which reflect the intricate interplay of emotional, cognitive and physiological functions' [12].

In a detailed report on a case of FAS due to left-hemispheric stroke with lesions in the sub-cortical white matter of the pre- and post-rolandic gyri, Blumstein et al. [2] suggested that the acoustic anomaly in the speech of their patient was based on an impairment of speech prosody. They hypothesized that the listener's perception of a 'normal' speaker with a foreign accent instead of an impaired speaker of the native language can be attributed to two factors. On one hand, language is near normal on lexical and grammatical levels. On the other hand, FAS patients' speech only contains features which also occur in natural languages. The latter is in contrast to what is observed in Broca's aphasia or in most dysarthrias.

About 50% of FAS patients, however, additionally suffer from aphasia classified as transcortical motor type aphasia or as Broca type aphasia [4]. Most patients experienced near complete remission of aphasia but FAS persisted. This finding is in contrast to the observations. It is of interest that the patient described here felt FAS helpful in struggling against her aphasia: During situations of increased strain where there was increase of aphasia symptoms, the patient was—due to her foreign accent—supposed to come from abroad and, therefore, was supported without embarrassment in order to enable her to overcome her 'vocabulary restriction'. It is concluded that FAS in this special case of aphasia has favoured social and professional reintegration.

## References

1. Berthier ML. Foreign accent syndrome. *Neurology* 1994;44:990–991.
2. Blumstein SE, Alexander MP, Ryalls JH, Dworetzky B. On the nature of the foreign accent syndrome: A case study. *Brain Language* 1987;31:215–244.
3. Gurd JM, Bessell NJ, Bladon RAW, Bamford JM. A case of foreign accent syndrome, with clinical follow-up, neuropsychological and phonetic descriptions. *Neuropsychologia* 1988;26:237–251.
4. Kurowski KM, Blumstein SE, Alexander M. The foreign accent syndrome: A reconsideration. *Brain Language* 1996;54:1–25.
5. Takayama Y, Sugishita M, Kido T, Ogawa M, Akguchi I. A case of foreign accent syndrome without aphasia caused by a lesion of the left praecentral gyrus. *Neurology* 1993;43:1361–1363.
6. Carbary TJ, Patterson JP, Snyder PJ. Foreign accent syndrome following a catastrophic second injury: MRI correlates,

- linguistic and voice pattern analysis. *Brain Cognition* 2000;43:78–85.
7. Gonzalez-Alvarez J, Parcet-Ibars MA, Avila C, Geffner-Sclarsky D. A rare neurologically originated speech disorder: Foreign accent syndrome. *Reviews in Neurology* 2003;36:227–234.
  8. Moonis M, Svearer JM, Blumstein SE, Kurowski KM, Licho L, Kramer P, Mitchell A, Drachman DA. Foreign accent syndrome following a closed head injury. Perfusion deficit on SPECT with normal MRI. *Neurology* 1996;43:381.
  9. Neilson JM, MacKeown M. Dysprosody. Report of two cases. *Bulletin of the Los Angeles Neurological Society* 1961; 26:157–159.
  10. Klein D, Zatorre RJ, Milner B, Meyer E, Evans AC. Left putaminal activation when speaking a second language: Evidence from PET. *Neuroreport* 1994; 5:2295–2297.
  11. Gurd JM, Coleman JS, Costello A, Marshall JC. Organic or functional? A new case of foreign accent syndrome. *Cortex* 2001;37:715–718.
  12. Matas M. Psychogenic voice disorders: Literature review and case report. *Canadian Journal of Psychiatry* 1991;36:363–365.