


This article was downloaded by: [UZH Hauptbibliothek / Zentralbibliothek Zürich]

On: 26 December 2014, At: 22:06

Publisher: Routledge

Informa Ltd Registered in England and Wales Registered Number: 1072954 Registered office: Mortimer House, 37-41 Mortimer Street, London W1T 3JH, UK



## Neurocase: The Neural Basis of Cognition

Publication details, including instructions for authors and subscription information:

<http://www.tandfonline.com/loi/nncs20>

### Cognitive and neural mechanisms underlying reading and naming: Evidence from letter-by-letter reading and optic aphasia

Elisabeth B. Marsh<sup>a</sup> & Argye E. Hillis<sup>a</sup>

<sup>a</sup> The Johns Hopkins University School of Medicine, Baltimore, MD, USA

Published online: 16 Feb 2007.

To cite this article: Elisabeth B. Marsh & Argye E. Hillis (2005) Cognitive and neural mechanisms underlying reading and naming: Evidence from letter-by-letter reading and optic aphasia, *Neurocase: The Neural Basis of Cognition*, 11:5, 325-337, DOI: [10.1080/13554790591006320](https://doi.org/10.1080/13554790591006320)

To link to this article: <http://dx.doi.org/10.1080/13554790591006320>

PLEASE SCROLL DOWN FOR ARTICLE

Taylor & Francis makes every effort to ensure the accuracy of all the information (the "Content") contained in the publications on our platform. However, Taylor & Francis, our agents, and our licensors make no representations or warranties whatsoever as to the accuracy, completeness, or suitability for any purpose of the Content. Any opinions and views expressed in this publication are the opinions and views of the authors, and are not the views of or endorsed by Taylor & Francis. The accuracy of the Content should not be relied upon and should be independently verified with primary sources of information. Taylor and Francis shall not be liable for any losses, actions, claims, proceedings, demands, costs, expenses, damages, and other liabilities whatsoever or howsoever caused arising directly or indirectly in connection with, in relation to or arising out of the use of the Content.

This article may be used for research, teaching, and private study purposes. Any substantial or systematic reproduction, redistribution, reselling, loan, sub-licensing, systematic supply, or distribution in any form to anyone is expressly forbidden. Terms & Conditions of access and use can be found at <http://www.tandfonline.com/page/terms-and-conditions>

# Cognitive and neural mechanisms underlying reading and naming: Evidence from letter-by-letter reading and optic aphasia

ELISABETH B. MARSH and ARGYE E. HILLIS

*The Johns Hopkins University School of Medicine, Baltimore, MD, USA*

We report detailed analysis of language performance in a patient, RMI, a 55-year-old man who presented with a homonymous hemianopsia, optic aphasia, and alexia without agraphia (with letter-by-letter reading) acutely after stroke. MRI showed infarct in the left occipital and medial temporal lobe and hypoperfusion of the entire posterior cerebral artery territory, including the splenium. Extensive language testing revealed severely impaired picture naming and oral reading, with relatively spared tactile naming and recognition of orally spelled words, consistent with impaired access to lexical and semantic representations from vision. In addition, he had a milder deficit in accessing lexical representations for output from all input modalities. RMI's execution of various language tasks provided considerable insight into the mechanisms that underlie oral reading. His performance indicated that both semantic access and orthographic to phonologic conversion mechanisms were partially intact. When information from these two impoverished systems was coupled (the picture of an object presented with its written name), his ability to read/name improved significantly, consistent with the hypothesis that partially accessed semantic information from vision can combine with partially accessed sublexical orthographic to phonologic conversion mechanisms to access phonological representations for output. Furthermore, his written word and picture recognition improved to normal at a time when magnetic resonance perfusion imaging demonstrated reperfusion of the splenium. We interpret these results, as well as results from previous studies in the literature, within a model of the neural regions critical for various cognitive processes underlying reading.

The ability to read, to convert printed symbols to words and phrases that have meaning, is a complex process. There has been considerable progress in uncovering the underlying cognitive and neural mechanisms. However, despite extensive investigation, there remains uncertainty over the precise neurological pathways critical for processing written stimuli. Analysis of patients with oral reading deficits led to the proposal of at least two "routes" responsible for converting written input to spoken output (Coltheart *et al.*, 1980). The first is a semantically-mediated path for reading familiar words, which involves access to lexical representations in an "orthographic input lexicon" (OIL), access to semantic representations (word meanings), and access to phonological representations in the "phonologic output lexicon" (POL). One line of evidence supporting its existence is seen in patients who exhibit a pattern of semantically-related reading errors (e.g., *one* → "three"), as a result of impairment in accessing semantic representations or accessing representations in the POL from

intact semantics (see Coltheart *et al.*, 1980; Shallice, 1988a; Caramazza and Hillis, 1990; Hillis *et al.*, 1990). The second "route", required for reading unfamiliar words, "orthographic to phonologic conversion" (hereafter OPC), presumably bypasses the OIL and semantics (Coltheart, 1978). Evidence for this "route" comes from regularization errors (e.g., *one* → "own") (see Coltheart *et al.*, 1983). For both of these potential "routes", the printed letter stimuli must first be converted into a string of graphemes independent of case, font, orientation, or size of the visual stimuli.

The two paths detailed have been well described and widely (but not universally) accepted (see for example Seidenberg and McClelland, 1989; Plaut and Shallice, 1993 for alternative views). There is, however, a phenomenon whereby a patient is able to fluently and accurately read irregular words without understanding their meaning (Coltheart *et al.*, 1983), which is difficult to explain on the basis of these two reading mechanisms. Such patients may, for example, be able to read the word *steak* as "stake" (/steIk/) rather than /stik/ ("steek", rhyming with *leak*), but define it as, "a fence post". In addition, their oral reading performance far surpasses their ability to name pictures (e.g., Sartori *et al.*, 1987). Some authors claim that these patients provide evidence of a third "route" for reading that directly connects the OIL and the POL (Schwartz *et al.*, 1980; Bub *et al.*, 1985; Shallice, 1988a). However, there is an alternative explanation. If preserved, or even partially preserved, sublexical mechanisms for converting print to sound (OPC) are coupled with at least partial

---

Received 27 August 2004; accepted 3 February 2005

We are grateful to RMI for his cheerful participation in this study. The research reported in this article was supported by a Student Scholarship in Cardiovascular Disease and Stroke from the American Heart Association to EBM, as well as by an NIDCD grant (RO1 DC05375) and an NINDS grant, ROI NS047691 to AH. The authors gratefully acknowledge this support.

Address correspondence to Argye E. Hillis, MD, Phipps 126, Johns Hopkins Hospital, 600 N. Wolfe St., Baltimore, MD, 21287. E-mail: argye@jhmi.edu

access to semantics, it can be enough to activate the POL, even if neither mechanism is sufficient to activate it alone (Hillis and Caramazza, 1991; 1995a). This concept, “the Summation Hypothesis”, is best understood when considering a distributed model of the semantic system and POL in which all of an object’s semantic features activate in parallel all of the lexical representations in the POL to which they correspond. Therefore, semantically-related representations in the POL are activated in proportion to how closely related they are to the target word. The lexical representation that is activated by the most semantic features becomes available for spoken output. For example, the word *boy* may activate a pattern of semantic features in the semantic lexicon that includes <male>, <young>, and <human>. In the POL, these semantic features will in turn activate all corresponding phonological representations. To illustrate, the feature <male> may activate phonological representations of boy, man, father, buck, stallion, and king; while <young> might activate phonological representations of girl, boy, cub, duckling, and sapling. The lexical representation selected for output is likely to be the one with the most activation, which would normally be the target word (in this case, “boy”). If the phonological representation for boy were in some way impeded or if only a subset of semantic features comprised the semantic representation, another representation activated by a subset of semantic features might become activated instead, resulting in a semantic error (e.g., in this example, “girl”). In a similar way, lexical-phonological representations in the POL can also be activated by even partial sublexical phonological information from OPC mechanisms (Saffran, 1985; Hillis and Caramazza, 1991). For example, in response to the word *boy*, *b* will be converted to [b] and will activate phonological representations of boy, bee, buy, bow, bay, beautiful, etc.; *oy* will be converted to [I] and will activate phonological representations of boy, toy, oil, boil, etc. Thus, strings in the POL are activated in proportion to their degree of phonological similarity to the stimulus. The representation that receives the greatest activation (normally the target) will be selected for output. However, each word has its own threshold value that it must reach in order to become selected. Dysfunction of a brain region can cause thresholds of all or a subset of words to be elevated (or can disrupt orthography to phonology conversion), so that the target representation may not receive suprathreshold activation. In some models, word frequency also affects the threshold, such that a frequently used word has a higher resting threshold or a lower selection threshold, making it more likely to be selected, when activated by only a subset of the graphemes. Therefore, patients with impaired OPC mechanisms often produce high frequency words as errors in response to words or pseudowords that share a subset of graphemes (e.g., *cherub*-> “cherry”) (see Coltheart *et al.*, 1980 for examples). Alternatively, the patient might access the correct lexical representation in the POL by combining information from the semantically mediated path and OPC mechanisms, even if one or both is partially damaged. The reasoning is as follows: phonological output is dependent

solely on a word reaching its threshold level of activation in the POL. Therefore, when partial phonologic information that is by itself insufficient for activation is coupled with partial semantic information that is also insufficient, the target lexical representation may be excited beyond its threshold and be produced.

We hypothesized that this sort of interaction, or summation, of distributed information plays an important role in oral reading of patients with letter-by-letter reading, and that a direct pathway between the OIL and the POL is not necessary to explain the accurate reading responses that cannot be the result of lexical-semantic or sublexical “routes” alone. More specifically, we hypothesize that patients with letter-by-letter reading are impaired in accessing both the lexical-semantic route and the OPC route from a graphemic description that is computed from visual input in the right hemisphere. However, partial information from both routes can be combined to access phonological representations for output to reading aloud some printed words, particularly with additional semantic cues. To evaluate this hypothesis, we administered a comprehensive battery of language tests to a patient with optic aphasia and letter-by-letter reading. We predicted that partially accurate OPC mechanisms achieved through somewhat defective letter-by-letter reading would combine with partial semantic information (activated from impaired visual-to-semantic connections), such that accurate oral reading would at least sometimes be possible, and would be facilitated by additional semantic cues. We also evaluated whether it was necessary to propose separate semantic systems in the right and left hemispheres to account for the data, or whether our patient’s symptoms could be explained by proposing entirely left hemisphere lexical and semantic processing.

This question of multiple semantic systems has also been extensively studied, particularly in the context of optic aphasia (Beauvois, 1982). The classic neurological explanation of optic aphasia is that these patients each had a lesion in the left occipital lobe, preventing early visual processing from occurring in the left hemisphere, as well as damage to the splenium, making it impossible for visual information from the right hemisphere to cross over to left hemisphere language areas (Freund, 1889) — an account that is nearly identical to the classical neuroanatomical explanation of letter-by-letter reading (alexia without agraphia; Dejerine, 1892). However, Coslett and Saffran (1989, 1992) reported that some patients with optic aphasia were able to sort pictures into categories (a task that requires access to semantics) even if they could not name them. On the assumption that there is no “route” for visual information to reach left hemisphere semantics in the temporal, frontal, and parietal regions in these patients, semantic tasks requiring the left hemisphere should be impossible. This proposal of a complete disconnection led to the hypothesis that sorting pictures into semantic categories must have been accomplished by a right hemisphere semantic system. Alternatively, it is possible that small amounts of visual information may in fact still be able to cross via extra-splenial tracks in the corpus callosum and allow these

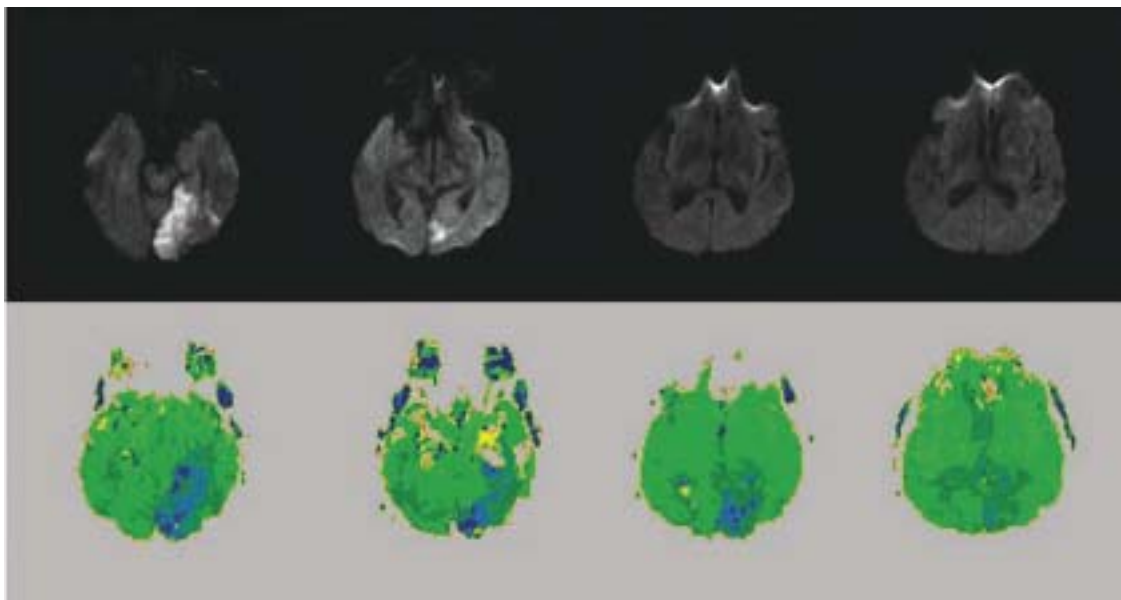
patients to access partial semantic information in the left hemisphere that can explain their performance.

A related account of optic aphasia that involves multiple semantic systems is that patients are able to access the visual semantic system from vision (permitting gestures in response to pictures), and able to access the verbal semantic system (permitting naming to definition), but due to a disconnection between the verbal and visual semantic systems, they cannot name visual stimuli (Beauvois, 1982). However, this pattern of performance can also be accounted for without proposing separate visual and verbal semantic systems, by proposing that component features of pictures or objects (partial semantic information) may support appropriate gestures even if these features are not sufficient to support access to the name of the object (see Caramazza *et al.*, 1990 for discussion).

In this article, we evaluate these various proposals about residual reading and semantic processing in patients with “pure” alexia (with and without letter-by-letter reading) and optic aphasia in a patient who shows the typical patterns of performance associated with each of these clinical syndromes after a stroke involving the territory of the left posterior cerebral artery. Because the patient showed the classic patterns of performance, the conclusions from this case may also help to explain the patterns of performance in similar cases. Furthermore, we carried out serial MRI scans, including perfusion-weighted imaging, to identify the areas of infarction and hypoperfusion associated with his deficits. Based on the finding that his reading and naming improved with restored blood flow to the splenium, along with recent evidence regarding the neural correlates of reading and naming from functional imaging and lesion studies, we provide a neuroanatomical account of reading and naming deficits.

## Case report

RMI is a 55-year-old, right-handed man with a high school education, who was employed as an operations manager for a security firm until three heart attacks caused him to stop working. He was moderately fluent in Polish, his native tongue from childhood, and an avid reader until being admitted to Johns Hopkins Hospital with difficulty seeing in his right visual field. A brain MRI revealed an acute infarct in the left posterior cerebral artery (PCA) territory, involving mainly the posterior portion of the occipital lobe and fusiform gyrus, seen as bright on Diffusion Weighted Image (DWI). There was also hypoperfusion of the entire left PCA territory, including the splenium of the corpus callosum, demonstrated with Perfusion Weighted Imaging (PWI) (see Figure 1). On neurological examination, RMI was found to have a right homonymous hemianopsia, letter-by-letter reading, and the ability to easily write words he could not read (alexia without agraphia). In the days immediately following his stroke, RMI displayed prominent language deficits in oral and written naming of pictures (and to a lesser degree, naming of tactile input), word/picture verification with auditory and written words, oral reading, and lexical decision. His repetition and auditory comprehension of yes/no questions and conversation remained intact. RMI complained of some trouble learning new information that was confirmed with the Rey Auditory Verbal Learning Test (RAVLT) [Western Psychological Services, 1996], Rey-Osterrieth Complex Figure Test (Osterrieth, 1944), and Recall portion of the Mini Mental State Examination (Folstein *et al.*, 1975; see Table 1). He scored within the normal range or just outside the lower boundary on all additional neuropsychological testing (see



**Fig. 1.** RMI's imaging at 2 days post-onset of stroke. Panel A. Diffusion-weighted image, showing acute infarct in left occipital and fusiform gyri (medial BA 37). Panel B. Perfusion-weighted image (PWI) Time to Peak map showing hypoperfusion of the entire PCA territory, including the splenium.

**Table 1.** RMI's performance on standardized neuropsychological tests

Cognitive Test	Number Correct	Z-Score
Mini Mental State Examination	24/30	-2
Weschler Memory Scale		
Information and Orientation	12/14	-2
Digits Forward	11/16	+1
Digits Backward	5/14	0
Rey Complex Figure		
Copy	29/36	0
Delayed Recall	4/36	-1
Rey Auditory Verbal Learning Test		
Trial 1	4/15	-1
Trial 2	5/15	-1
Trial 3	7/15	-1
Trial 4	6/15	-2
Trial 5	6/15	-2
Total	28/75	-2
Interference Trial	2/15	-1
<b>Retention</b>	<b>0/15</b>	<b>-3</b>
Delayed Recall	0/15	-2
Oral Recognition	1/15	
<b>Boston Naming Test</b>	<b>32/52</b>	<b>-5</b>
Controlled Oral Word Association Test	32	0

Table 1). RMI was tested 1–2 times a week for the first six weeks after stroke onset, during which time his mild deficits in auditory retention resolved, and his new learning began to improve. His naming and oral reading performance remained impaired. Although RMI made errors on the right side of words, he did not show evidence of right neglect on a battery of tests for hemispatial neglect, including line cancellation, line bisection, copying a scene, and a gap detection test in which he had to detect gaps on the left or right side of circles scattered across the page.

## Experimental investigations

### Lexical processing

To identify impaired and spared components of lexical processing, RMI was administered a bedside battery of lexical tests (hereafter, Johns Hopkins Lexical Battery) that we routinely administer to acute stroke patients as part of an ongoing project to identify the neural basis of cognitive processes underlying lexical tasks. This battery was administered two days post-onset of stroke, when RMI was first admitted to the hospital.

### Methods

The Johns Hopkins Lexical Battery included tests of oral naming of 60 pictures, oral naming of 48 objects to tactile exploration, written naming of 60 pictures, oral reading of 34 words and 24 pseudowords, spelling to dictation of 34 words

and 24 pseudowords, repetition of 34 words and 24 pseudowords, spoken and written word/picture verification (each with 51 trials, in which 17 items were presented once with a semantic foil, once with a visually/phonologically similar foil, and once with the target), and spoken and written lexical decision (each with 58 trials). Word stimuli were matched across tasks for word frequency (range = 1–274; mean = 42.65), word length in letters (range = 3–10; mean = 4.41), number of syllables (range = 1–3; mean = 1.41), and word class. Pseudowords were matched in letter and phoneme length to the words. Norms and scoring for this lexical battery have been previously described (Hillis *et al.*, 2002). The oral reading list (34 words and 24 pseudowords) was presented for recognition of oral spelling in addition to the standard format of stimuli presented visually one at a time on a computer screen, to identify the effect of input modality on word recognition. All tests were untimed. Differences in accuracy rates for different types of stimuli were evaluated with chi square tests. An alpha level  $p < .05$  was considered statistically significant.

### Results

*Performance across tasks.* RMI's percent correct for each task is presented in Table 2. It is clear from these data that RMI was less accurate when the task involved visual stimuli (words or pictures) than when the task involved only auditory or tactile stimuli. He was significantly less accurate in oral naming of pictured objects than oral naming of tactile objects (66.7% versus 91.7% correct;  $\chi^2 = 4.6$ ,  $p = .03$ ). Similarly, he was less accurate in oral reading than in recognition of orally spelled words and pseudowords (10.3% versus 53.4% correct;  $\chi^2 = 24.8$ ,  $p < .00001$ ). His oral reading was also significantly

**Table 2.** RMI's percent correct on subtests of the lexical battery

Subtest	Percent Correct	Normal Performance*
Tests with Visual Input		
Oral Naming of Pictures: Nouns	66.7%	97 ± 5.1
Written Naming of Pictures: Nouns	56.7%	97 ± 4.4
Spoken Word/Picture Verification	82.4%	100 ± 0
Written Word/Picture Verification	52.9%	94 ± 4.8
Oral Reading: Words	5.9%	98 ± 3.2
Oral Reading: Pseudowords	16.7%	92 ± 8.8
Lexical Decision: Written	65.5%	94 ± 4.8
Tasks with No Visual Input		
Lexical Decision: Auditory	91.4%	96 ± 6.1
Oral Naming to Tactile Exploration	91.7%	100 ± 0
Recognition of Orally Spelled Words	53.4%	No norms available
Spelling to Dictation: Words	76.5%	96 ± 5.9
Spelling to Dictation: Pseudowords	66.7%	96 ± 6.1

\*The original norms from 46 hospitalized controls subjects, who all had  $\geq 10^{\text{th}}$  grade education (range 10–18 years), were higher, ranging from  $98.0 \pm 3.1$  percent correct for oral reading to  $100 \pm 0$  percent correct for tactile naming (Hillis, *et al.*, 2002). These more liberal norms are from normal subjects with mean education level 12.0 (range 8–16) years, mean age 63.1 (range 40–78) years.

less accurate than spelling to dictation (10.3% versus 72.4% correct;  $\chi^2 = 46.1, p < .00001$ ). Written lexical decision was markedly less accurate than spoken lexical decision (65.5% versus 91.4% correct;  $\chi^2 = 11.5, p < .001$ ); written lexical decision was just better than chance, while auditory lexical decision was within normal limits on this test. Repetition was also spared (94.8% correct). Spoken word/picture verification was better than written (82.4% versus 52.9% correct), though both were impaired. In summary, RMI's performance indicated a severe impairment in naming or recognition of visual stimuli (particularly written words), and a milder impairment in all tasks requiring access to a lexical representation for output (e.g., oral naming of objects from tactile exploration and naming of orally spelled words).

*Types of errors.* RMI often said aloud at least the initial letters of the word. He would begin to slowly "sound out" each stimulus, frequently reading at least the first part of the word correctly. The majority (67.8%) of his error responses in reading shared at least the initial letters with the stimulus (e.g., *wheel*->"what"). A total of 77% of his errors were visually similar word errors (e.g., *joy*->"jog", *flair*->"flat", *color*->"polar"); the remaining errors were omissions or perseverations on a previous response.

His errors in spoken word/picture verification were all semantic errors (e.g., accepting "glove" for a picture of a shoe) or in one case, rejection of the target. Errors in written word/picture verification were either semantic errors of the same type (e.g., accepting *horse* for a picture of a sheep) or visually/phonologically similar word errors (e.g., accepting *boat* for a picture of a boot).

*Oral Reading.* To further characterize RMI's reading, we evaluated the influence of various lexical parameters (e.g., frequency, concreteness, ortho-phonological regularity, word length, and word class) on reading accuracy. The Johns Hopkins Dyslexia Battery (Goodman and Caramazza, 1985) was administered between 1 and 2 weeks post onset of stroke.

### Methods

The Johns Hopkins Dyslexia Battery (Goodman and Caramazza, 1985; see Beeson and Hillis, 2001 for a complete description and stimuli) consists of five word lists, each specifically designed for the analysis of a single lexical parameter, by counterbalancing for other potentially important parameters. Lists examine the effect of word length ( $n = 70$ ), concreteness ( $n = 42$ ), frequency ( $n = 272$ ), regularity ( $n = 90$ ), and grammatical word class and lexicality ( $n = 152$ ) on oral reading performance. In addition, since RMI claimed to have more trouble reading certain words in English than he did in Polish (the language he was exposed to at home for the first 2–3 years of his life), The Word Length List ( $n = 70$  words) from the Johns Hopkins Dyslexia Battery was translated into Polish, and RMI was asked to read each word aloud and

determine the English translation on a separate day from reading the same words in English.

RMI was given each list to read aloud without time constraints, and his responses were recorded for analysis.

### Results

*Influence of stimulus type on reading accuracy.* Word length, concreteness, and grammatical word class had no significant effect on reading accuracy. He read correctly 35.7% of 4-letter words, 21.4% of 5-letter words, 0% of 6-letter words, and 14.3% of both 7-letter and 8-letter words ( $\chi^2 = 6.6, ns$ ), given 14 words of each length matched for frequency and word class. However, oral reading was noted to be slower for longer words (but reading latency was unfortunately not documented on initial testing). There was also no significant effect of concreteness (23.8% correct for concrete words versus 9.5% correct for abstract words;  $\chi^2 = 1.5, ns$ ). Likewise, he correctly read 25–35% of the nouns, adjectives, verbs, function words, and nonwords (see Table 3 for details). However, he read high frequency words more accurately than low frequency words (39% versus 22.8% correct;  $\chi^2 = 8.3, p = .004$ ).

**Table 3.** Percent correct for each stimulus type on the Dyslexia Battery

Subtest	Number	Percent correct
Concreteness		
Concrete	21	23.8%
Abstract	21	9.5%
Word length		
4-letter	14	35.7%
5-letter	14	21.4%
6-letter	14	0%
7-letter	14	14.3%
8-letter	14	14.3%
Part of speech		
Open class		
Nouns	28	35.7%
Verbs	28	28.6%
Adjectives	28	25.0%
Function words	20	25.0%
Nonwords	68	27.9%
Nonhomophones	34	17.6%
Pseudohomophones	34	38.2%
Visually similar	17	47.1%
Visually nonsimilar	17	29.4%
Regularity*		
Regular	60	58.3%
Consistent	30	56.7%
Inconsistent	30	60.0%
Irregular	30	30.0%
Frequency*		
High frequency	146	39.0%
Low frequency	146	22.8%

\*statistically significant ( $p < .05$ ) effects; see text for details.

He also read regular words significantly more accurately than irregular words matched in frequency and word length (58.3% correct for regular words versus 30% correct for irregular words;  $\chi^2=6.4, p=.01$ ).

In reading Polish, RMI displayed the same trends he did while reading English words. He correctly “sounded out” at least the first few sounds, but often completed the word with the wrong ending (e.g., target: /konkrɛtn/ ; response: [konkret]). He correctly read 70.3%, which is not significantly different from his score of 58.3% correct in oral reading of regular words in English. Since Polish is a highly transparent language in terms of ortho-phonological regularity, his equivalent performance in oral reading of Polish and oral reading of regular words in English indicates that there was no meaningful difference in oral reading performance across the two languages.

*Error types.* As noted on reading subtests of the Johns Hopkins Lexical Battery, the majority of his errors on the Johns Hopkins Dyslexia Battery were visually similar word errors (e.g., *child*->“chief”, *priest*->“prior”) that usually shared the initial letters with the target. He also was noted to make errors in his letter-by-letter reading on visually similar letters. That is, he frequently confused the letters b, d, p and q (e.g., *pursuit*->“burglar”, *pity*->“big”).

*Access to semantic information from vision: Pictures versus written words.* RMI’s performance on the Johns Hopkins Lexical Battery documented that he had difficulty in language tasks involving visual stimuli. However, he showed greater difficulty on tasks that involved printed words than pictured objects. To determine whether his impairment in naming pictures and words resulted from impaired access to semantic information from vision or from impaired access to only phonological and orthographic lexical representations for output, he was administered tests of semantic association using picture and word stimuli.

#### Methods

Two tests were administered at 3 weeks post onset of stroke in counterbalanced order: the Kissing and Dancing Test (Thomas Bak, unpublished) and the Pyramids and Palm Trees Test (Howard and Patterson, 1992). For each, RMI was given the choice of two pictures and asked to choose the one most closely related to a picture above. Among the 55 triads of pictured objects in the Pyramids and Palm Trees Test and 52 triads of pictured actions in the Kissing and Dancing Test the response choices were semantically related. These tasks were repeated using the same stimuli presented as written words.

#### Results

RMI performed much better when presented with pictures than with words on the Pyramids and Palm Trees and Kissing

and Dancing Tests. He responded correctly on only 47/107 (43.9%) of the sets of words, but 88/107 (82.2%) of the sets of pictures ( $\chi^2=33.7, p<.00000001$ ). However, there was no difference in his performance for the objects versus actions (69.1% versus 71.8% correct;  $\chi^2=.28, ns$ ). Potential explanations of his better access to semantic information from pictures versus written words are presented in the Discussion section.

*Implicit reading (or access to partial semantic information from vision).* Previous studies have reported that some pure alexic patients have the ability to implicitly process words that they cannot overtly read aloud, indicating access to “right hemisphere semantics” or partial semantic information that cannot adequately support naming the word (Saffran and Coslett, 1998). Therefore, we administered three reading tests that evaluated access to semantic information versus oral reading.

#### Methods

RMI was given a list of 30 words; 10 were foods, 10 animals, and 10 pieces of clothing. He was asked to read each word aloud and then to identify the appropriate category to which it belonged. In addition, RMI was given a printed list of 39 objects and asked to circle all of the animals as quickly as he could, without taking time to sound out each word. He was allowed only 2 sec for each word and was then forced to circle or move on. Finally, RMI was given 144 printed words belonging to the following categories matched for word frequency and word length in letters: land animals, ocean animals, birds, furniture, clothing, fruits, vegetables, other foods, body parts, and modes of transportation (see Hillis *et al.*, 1990 for a description of these stimuli). He was not given the category titles, but instead asked to look at each word, and as quickly as possible sort them into sets with a common semantic feature. He was then asked to identify each of his categories.

#### Results

RMI’s ability to classify a word as a food, animal, or piece of clothing was not significantly better than chance (11/30; 36.7%), and no better than his oral reading of the same words (11/30; 36.7%). However, when he had to quickly identify a word as referring to an animal or not, RMI correctly classified 30/39 (76.9%) of words, which is significantly better than chance ( $\chi^2=15.0; p<.0001$ ) and better than his oral reading ( $\chi^2=11.4; p<.001$ ). In sorting words into 10 semantic categories RMI correctly classified 29/144 (20.1%) of the words, again better than chance ( $\chi^2=6.4; p=.01$ ). He created the following categories: face pieces, furniture, rocks, body parts, storage, fruit, things to eat, electrical appliances, animals, parts of food, and “can’t remember”. Although some words were correctly sorted into RMI’s categories, most words in his categories had no common link. Taken together,

RMI demonstrated some access to semantic information from written words when he was unable to read them, but only in tasks where he was required to make a rapid choice requiring minimal semantic information (e.g., animal or not).

*Naming written words versus pictures versus words + pictures.* RMI appeared to have limited access to semantics from visual stimuli (pictures more than words), and at least partially intact sublexical OPC mechanisms in reading. Therefore, we evaluated the hypothesis that partial semantic information coupled with partial phonological information derived from OPC mechanisms would interact to access phonological representations for output. We hypothesized that providing additional semantic cues along with a written word would improve his oral reading performance, and that providing additional phonological cues (from printed words) along with a pictured object would improve oral naming performance. This testing was administered at one month post-onset of stroke, after he had made substantial improvement in oral reading.

#### Methods

RMI was administered four tasks with 144 items from 10 semantic categories matched for word frequency and length (from Hillis *et al.*, 1990). The items were presented in counterbalanced order in the following four tasks: (1) oral reading of the printed name of each object; (2) oral naming of the picture; (3) oral production of the word in response to the written name of each object, along with a picture of the object; and (4) oral production of the word in response to the written name of each object, along with a picture of a semantically-related object (chosen from the set).

#### Results

RMI correctly read 79.9% of the words and correctly named 75.0% of the pictures. When RMI was shown an object's picture along with its printed name (providing him with additional semantic cues along with partial phonological information derived from OPC mechanisms), he correctly read/named 94.1% of the stimuli, significantly better than his performance in oral reading ( $\chi^2=12.1$ ,  $p<.0005$ ) or oral naming ( $\chi^2=19.0$ ,  $p=.00001$ ) of the same stimuli. Importantly, reading/naming was just as accurate when a semantically related picture was paired with the target word. He produced the correct word on 95.6% of trials when the correct picture was presented and 92.4% of trials when the word was paired with a semantically-related picture ( $\chi^2=1.6$ ,  $ns$ ), consistent with the hypothesis that even partial semantic information could be used in combination with partial phonological information derived from sublexical OPC mechanisms to access the lexical representation for output. In this case, information from both the lexical-semantic and sublexical OPC reading routes was faulty due to his "upstream" deficit that affected computation of graphemic description from

vision (essential for either "route"). However, these results can be explained by assuming that partial information from each route combined to access the lexical representation in the POL.

*Follow-up testing.* RMI was retested at 12 months post-onset on a subset of the previous tests, to evaluate his reading and naming. He also had visual field testing at 12 months post-onset that confirmed persistent right homonymous hemianopia with macular sparing. A repeat MRI (see Figure 2) demonstrated the chronic infarct in the left occipital lobe, fusiform gyrus, and medial inferior temporal lobe. Repeat perfusion imaging demonstrated reperfusion of the splenium with no permanent damage to the splenium. Only the infarcted area was hypoperfused at follow-up.

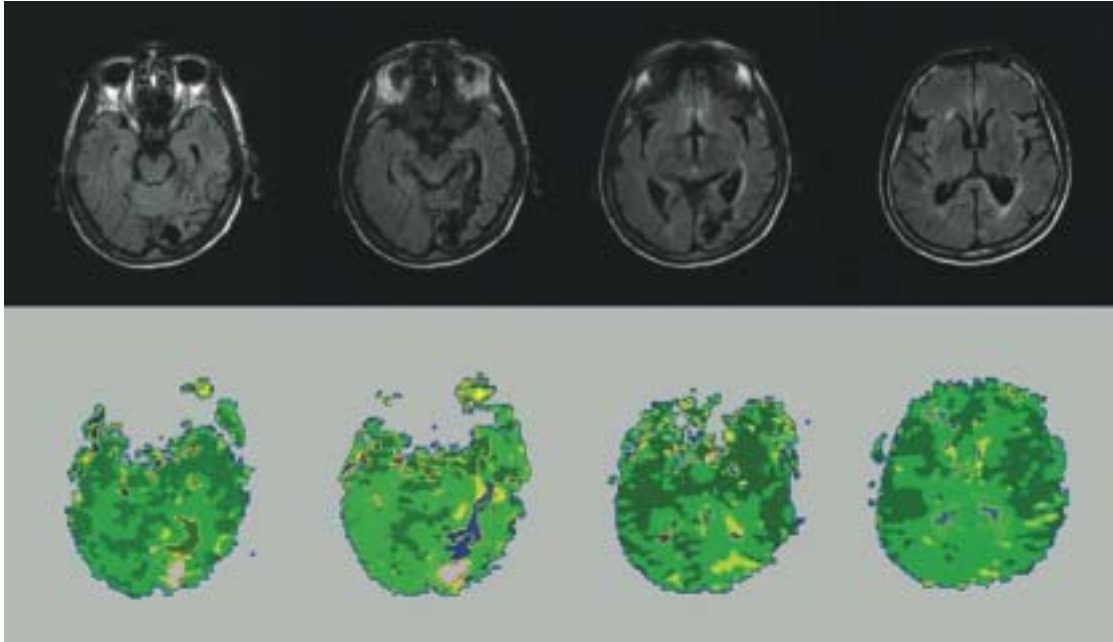
#### Methods

The following subtests from the Johns Hopkins Lexical Battery were re-administered at 12 months post-onset: 1) oral naming of pictured nouns ( $n=30$ ); 2) oral naming of objects to tactile exploration ( $n=17$ ); 3) oral reading ( $n=34$  words and 24 pseudowords) and 4) visual lexical decision ( $n=58$ ). In addition, 10 auditory yes/no questions and the Word Length List from the Johns Hopkins Dyslexia Battery ( $n=70$ ) were also readministered. The 14 words of each word length were read separately, and the reading of the lists was timed, to determine if reading latency was affected by number of letters in the word.

#### Results

Results are reported in Table 4. RMI showed improvement on all tests, although auditory comprehension of questions and tactile naming were near ceiling at onset. Of note, his visual lexical decision improved to within normal limits and written word comprehension improved to 100% accurate. His residual errors on reading were still visually and phonologically similar words (e.g., *blam*->"blame"). In contrast to performance at onset, his oral reading of words was more accurate than oral naming of pictures (85.3% versus 76.7%, with stimuli matched for word length and frequency) at follow-up. He showed significant improvement in oral reading of words (from 12/70 to 59/70 correct on the Word Length List;  $\chi^2 = 63.1$ ;  $p<<.00001$ ; and from 2/34 to 29/34;  $\chi^2 = 43.2$ ;  $p<<.00001$  on the Lexical Battery), but did not show significant improvement in oral naming of pictures on the lexical battery (from 20/30 to 23/30;  $\chi^2= 0.74$ ;  $ns$ ). Oral reading of pseudowords also showed significant improvement (from 4/24 to 11/24;  $\chi^2= 4.7$ ;  $p<.03$ ), although he showed a tendency to "lexicalize" pseudowords at follow-up (e.g., *cherb*->"cherub"). Reading latency was not affected by word length; there was no difference in reading times across the lists of 14 words of each length: 4-letter words: 26 sec; 5-letter words: 24 sec; 6-letter words: 26 sec; 7 letter words: 27 sec; 8-letter words: 25 sec. Furthermore, his accuracy was no longer influenced by visual versus auditory input, but was influenced by





**Fig. 2.** RMI's imaging at 12 months post-onset of stroke. Panel A. FLAIR (Fluid Attenuated Inversion Recovery) sequence showing infarct in the left occipital lobe and fusiform gyrus (medial BA 37). Panel B. PWI Time to Peak map showing reperfusion of the splenium.

**Table 4.** Comparison of testing immediately following stroke to 12 month follow-up

Test	% Correct at onset	% Correct at follow-up	Normal performance
<b>Tests requiring lexical output</b>			
Oral reading: Word length list	17.1%	84.3%	unavailable
Lexical battery: Oral reading words	5.9%	85.3%	98 ± 3.2
Oral tactile naming	91.7%	94.4%	100 ± 0
Oral naming of pictures: Nouns	66.7%	76.5%	97 ± 5.1
Written naming of pictures: Nouns	56.7%	76.7%	97 ± 4.4
Spelling to dictation	76.5%	81.0%	96 ± 5.9
<b>Tests with no lexical output</b>			
Auditory comprehension questions	90%	100%	100 ± 0
Auditory lexical decision	91.4%	98.3%	96 ± 6.1
Visual lexical decision	65.5%	90.5%	94 ± 4.8
Written word/picture verification	82.4%	100%	100 ± 0
Spoken word/picture verification	52.9%	100%	94 ± 4.8

whether or not the task required access to lexical representations for output. Although his tactile naming was relatively intact (compared to his picture naming), it was below the mean for 46 normal controls, who all scored 100% correct on this test (Hillis *et al.*, 2002).

## Discussion

This case has implications for several theoretical issues currently under debate in the cognitive neuroscience literature. First, we will discuss implications of this case for neuroanatomical models of reading and naming. Secondly, we will illustrate

how the data provide evidence for the interaction of partial semantic and partial phonological information in accessing phonological representations for output. Finally, we will discuss implications of the data for theories of how semantic information is accessed from words versus pictures.

### *A neuroanatomical account of RMI's alexia and optic aphasia*

Dejerine (1892) first reported that pure alexia, or alexia without agraphia, can result from a combination of lesions in the left occipital lobe (preventing visual information from being processed directly in the left hemisphere) and the splenium of

the corpus callosum (preventing transfer of visual information from the right hemisphere to the left hemisphere language areas). Alexia without agraphia in patients with both lesions has frequently been described (Geschwind and Fusillo, 1966; Miozzo and Caramazza, 1998; Larsen *et al.*, 2004; Cohen *et al.*, in press), in part because the left occipital lobe and left splenium are both in the territory of the left posterior cerebral artery, so that strokes resulting from left PCA occlusion cause damage to both regions. Binder and Mohr (1992) reviewed a series of patients with left PCA strokes, and found that global alexia, with impairment in letter recognition and profound impairment of reading, required damage to the callosal pathways in addition to left occipital and fusiform gyri. In contrast, composite images of successful letter-by-letter readers (subtracting lesion overlap of patients with normal reading after PCA stroke) showed the overlap of lesions included left fusiform gyrus without damage to the white matter pathways in the splenium. In 1889, Freund proposed a neurological account of optic aphasia very similar to Dejerine's account of pure alexia, according to which the left occipital lobe infarct prevents visual processing from occurring in the left hemisphere, and additional damage to the splenium prevents visual information from crossing from the right hemisphere to left hemisphere language areas. This "visual-verbal disconnection" syndrome, with impaired performance on lexical tasks such as naming from the visual modality, has also been well described (Freund, 1889; Margolin *et al.*, 1985). This pattern of performance has been interpreted as resulting from impaired access to a modality-independent semantic system from visual stimuli (Riddoch and Humphreys, 1987; Hillis and Caramazza, 1995b).

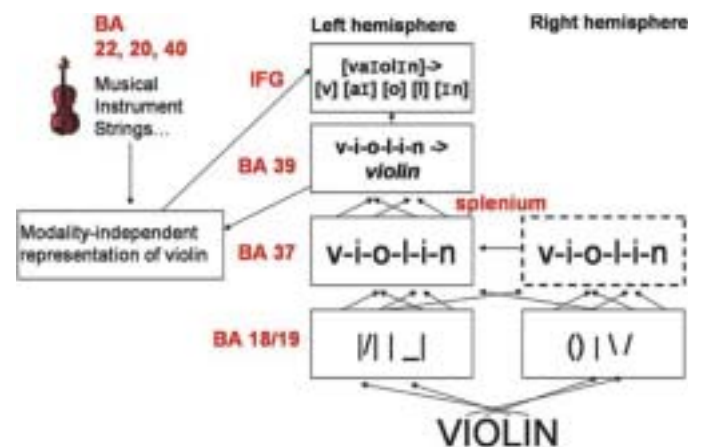
The preceding classic neurological account can explain RMI's poor performance in naming pictures (with relatively spared naming of tactile input), as well as his very poor oral reading of both English and Polish words (with relatively spared recognition of orally spelled words), since his MRI confirmed dysfunction (infarct and/or hypoperfusion) of the left occipital lobe, fusiform gyrus, and splenium. Furthermore, RMI showed rapid improvement in reading, which was likely due to spontaneous reperfusion of the splenium, documented by a subsequent MRI (see Figure 2).

However, there are aspects of RMI's performance that cannot be explained by this classic account. Although he improved to normal performance in written lexical decision, he had persistent, mild-moderate deficits in lexical output tasks of oral reading and naming. These deficits may be attributable to his infarct in the left fusiform gyrus, including Brodmann's area (BA) 37. We have recently reported that in a series of 80 patients with acute stroke, infarct and/or hypoperfusion of left BA 37 was strongly associated with impaired lexical output but not reading comprehension or written lexical decision (Hillis *et al.*, 2005).

The finding that lesions in left fusiform/BA 37 result in impaired lexical output but not impaired reading comprehension seemed at odds with results from functional imaging showing consistent activation in part of left midfusiform/BA 37 in response to words and pseudowords irrespective of case, font, or location (such that this area has been labeled the

"visual word form area"; Cohen *et al.*, 2000; Cohen *et al.*, 2002; Cohen and Dehaene, 2004; but see Price and Devlin, 2003; 2004). However, to accommodate both results from conflicting functional imaging studies and a variety of lesion studies, we proposed that left BA 37 normally has two roles in reading: (1) computation of a prelexical grapheme description that is independent of case, font, location, or orientation; and (2) access to a modality independent lexical representation for output. We further proposed that left BA 37 is not necessary for reading comprehension, however, because the former role can be immediately assumed by the homologous region in right BA 37, as long as there is no disconnection between right BA 37 and left hemisphere areas essential for other components of the reading process (left angular gyrus, other parts of left BA 37, and left inferior frontal gyrus) (Hillis *et al.*, 2005). However, since all left-right temporal connections pass through the splenium, as recently demonstrated by tractography (Huang *et al.*, unpublished observations), damage or dysfunction of the splenium will prevent input from right BA 37 to left hemisphere regions that are critical for other components of the reading task. This elaborated neuroanatomical account is schematically depicted in Figure 3.

This proposal about the neural regions essential for reading results in the following predictions. Impairment in reading comprehension and written lexical decision (reading tasks without lexical output) should **NOT** result from **ISOLATED** damage or dysfunction of any of the following regions: (1) left BA 37 (because right BA 37 can immediately take over its prelexical function); (2) right BA 37 (because left BA 37 can support its role); (3) splenium (because left BA 37 receives intact visual input from left occipital lobe); or (4) left occipital lobe (because left BA 37 can receive visual input from the right occipital lobe). Instead, impaired reading



**Fig. 3.** A schematic representation of the neural regions involved in various components of reading. Note there are two functions of left BA 37: (1) computation of a prelexical grapheme description (which can also occur in right BA 37); and (2) computation of a modality-independent lexical representation for output, that mediates between semantics and modality-specific lexical representations.

comprehension and written lexical decision should result from a combination of lesions in: (1) left and right BA 37 (since neither would be available for computing a prelexical graphemic description); (2) left BA 37 and splenium (since the graphemic description could not cross from intact right BA 37 to left hemisphere regions efficiently); (3) left occipital lobe and splenium (since left BA 37 would be disconnected from visual information, and information from right BA 37 would be disconnected from left hemisphere language areas); or (4) left BA 37, occipital lobe, and splenium (for the same reason as #3). These predictions have been confirmed by cases with the following combination of lesions: (1) left and right BA 37 (Bartolomeo *et al.*, 1998; Wityk *et al.*, 2002); (2) left BA 37 and splenium (see Binder and Mohr, 1992); (3) left occipital lobe and splenium (see Dejerine, 1892; Hillis and Caramazza, 1995b; Chialant and Caramazza, 1998; Cohen *et al.*, in press, a); or (4) left BA 37, occipital lobe, and splenium (as in RMI at onset; see also cases in Binder and Mohr, 1992). Furthermore, those with damage to the left occipital lobe and splenium, sparing BA 37, should have intact lexical output in tasks without visual input, such as oral naming to definition, spontaneous speech, and recognition of oral spelling (as reported in Dejerine, 1892; Cohen *et al.*, in press, a), although they may have at least a transient optic aphasia (e.g., Shallice and Saffran, 1986; Hillis and Caramazza, 1995b). In contrast, those whose damage or dysfunction includes left BA 37 should also have impaired lexical output, irrespective of the modality of input, in addition to alexia and possible optic aphasia when the splenium is disrupted, as in RMI (see also Larsen *et al.*, 2004; Sakurai, 2004). This model would also predict left hemialexia (impaired reading of words presented in the left visual field) in cases of isolated damage of the splenium, since an intact grapheme description computed in the intact right BA 37 would not gain access to left hemisphere regions important for subsequent stages of reading (see Cohen *et al.*, 2000; Molko *et al.*, 2002). It would also predict that restored perfusion of the splenium would result in improved reading (but no substantial change in lexical output tasks), as shown in the case of RMI. Similarly, it would account for improved reading and naming with reperfusion of left occipital lobe and BA 37 in a patient with severe alexia and agraphia with hypoperfusion of bilateral occipital lobes and bilateral BA 37 at onset (see Wityk *et al.*, 2002). It would also account for the reported worsening of alexia after a lesion in right BA 37 in a patient who had shown a reading disturbance due to a previous lesion involving left BA 37 seven months earlier (Bartolomeo *et al.*, 1998). Finally, it would explain the reported worsening of alexia caused by transcranial magnetic stimulation (TMS) over the right posterior temporal and parietal regions in a patient who had shown partial recovery of pure alexia after a lesion in the left splenium and dysfunction in left BA 37 (indicated by atrophy of this region shown by MRI at the time of TMS; Coslett and Monsul, 1994).

How can we account for cases of “pure alexia” or letter-by-letter reading from lesions in BA 37 that spare the splenium

(e.g., some cases in Binder & Mohr, 1992)? One possible explanation is that at least some of these patients have hypoperfusion of the splenium that is not visualized by structural imaging, as demonstrated in RMI. This account is plausible in view of the fact that BA 37 and the splenium are in the same vascular distribution, and likely to be affected by occlusion or stenosis of the left PCA. Successful letter-by-letter reading might be possible if the splenium were only mildly affected, such that individual graphemes can slowly cross the splenium (or other callosal pathways; Cohen, *et al.*, in press, a), even if complete grapheme descriptions computed in right BA 37 cannot be transferred interhemispherically. An alternative (but similar) explanation for letter-by-letter reading, that does not assume any dysfunction of the splenium, has been proposed by Binder and Mohr (1992; see also Saffran and Coslett, 1998, Larsen *et al.*, 2004). They proposed that individuals with successful letter-by-letter reading can only identify single graphemes in right BA 37, that are transferred to the left hemisphere for further processing via an intact splenium. It is conceivable that individuals show variation in the capacity of right BA 37 to compute graphemic descriptions, such that only single grapheme recognition is supported by right BA 37 in some individuals, whereas computation of complete graphemic descriptions is supported by right BA 37 in others. Other cases of “pure alexia” from isolated left BA 37 may in fact be due to modality-independent lexical deficits. For example, one patient with a lesion restricted to left BA 37 at autopsy had reported slow but accurate reading and the need to “sound out words” after the lesion, but had a similar mild deficit in naming objects and persons (Beversdorf *et al.*, 1997).

Furthermore, it is possible that lexical output tasks might be spared in some cases of damage to BA 37, if different parts of BA 37 (or even different parts of fusiform gyrus within BA 37) are devoted to the two different proposed roles of this region in reading: one part devoted to computation of a prelexical grapheme description (and perhaps other letter-like strings), and one devoted to modality-independent lexical output. Functional imaging evidence for proposing two distinct regions in left BA 37, one for computing a case- and location-independent “visual word form” (comparable to our proposal of a grapheme description) and one for modality-independent lexical processing, has recently been reported (Cohen *et al.*, in press, b). Consistent with our neuroanatomical account proposing two roles of left BA 37 in reading (one of which can be supported by right BA 37), their fMRI studies showed activation in left lateral BA 37 (TC -48, -60, -16) in both written and spoken word tasks that required a decision as to whether a word included a visual feature (descending letter) or phoneme. They reported activation in slightly more medial and posterior BA 37 bilaterally, in areas they labeled VWFA and right VWFA (TC -44, -68, -4; and 40, -60, -8) specifically in response to written word input. While VWFA showed some perceptible response to spoken words (less than for written), right VWFA showed activation only to written words, as predicted by our account. The areas for unimodal versus modality-independent processing within BA 37 were only distinguished in individual subject analyses. The hypothesis of

two distinct subregions supporting different roles of left BA 37 could explain occasional cases of alexia without agraphia from lesions including left BA 37, in which lexical output tasks without visual input are entirely spared (Binder and Mohr, 1992).

Another source of evidence for the hypothesized necessity of either left or right BA 37 in computing a case-, font-, and location-independent prelexical graphemic representation comes from functional imaging in patients with lesions either in left BA 37 (including left VWFA) or in visual input to left BA 37 (including left VWFA). These patients show activation in right BA 37, in precisely the same reading tasks that result in activation of left BA 37 in normal subjects (Cohen *et al.*, 2003; Cohen *et al.*, in press, a; see also Sakurai, 2004). Furthermore, the patient reported by Cohen, *et al.* (in press, a) showed some, albeit weaker, activation in left BA 37 (VWFA) that was deafferented from visual input during reading tasks. This activation may have represented the role of left BA 37 in modality-independent lexical processing (accessing a lemma representation; see Hillis *et al.*, 2005 for discussion). Additional evidence from functional imaging studies that is consistent with our model is that many studies have shown bilateral BA 37 activation in reading tasks, although left BA 37 shows greater activation (Fiez *et al.*, 1999; Cohen, *et al.*, in press, b), perhaps because of its additional role in accessing a modality-independent lexical representation. In summary, although the roles of BA 37 both in computing prelexical representations from vision (e.g., whether or not these are specifically graphemic) and in modality-independent lexical processing need to be better defined, the hypothesis articulated here can account for a variety of observations from both functional imaging and lesion studies (see also Hillis *et al.* 2005 for further discussion).

#### ***Evidence for the interaction of partial semantic and partial sublexical information for accessing lexical phonological representations for output***

From the onset of stroke, RMI was often able to identify some information about pictures and words, even though he was unable to name or read them aloud. For example, he was often able to produce a correct gesture in response to a picture that he could not name. Gesturing has been interpreted as access to intact visual and semantic processing in the right hemisphere (Coslett and Saffran, 1989; 1992; Luzzati, 2002), access to “visual semantics” (Beauvois, 1982; Shallice, 1988b; 1993), or as partial access to a modality-independent semantic system (Riddoch and Humphreys, 1987; Hillis *et al.*, 1990; Caramazza *et al.*, 1990; Hillis and Caramazza, 1995b). Similarly, in identifying written words as animals or not, his performance was more accurate than his oral reading. Together, these findings can be accounted for by the hypothesis that RMI’s problems with reading and naming resulted from a disconnection that leaves him impaired in accessing a complete semantic representation from vision (written words or pictures). Such a problem could reflect access to “right

hemisphere semantics” (which is impoverished compared to the left hemisphere lexical-semantic system) from an intact right occipito-temporal area, or it could reflect partial access to the lexical-semantic system in the left hemisphere through a partially damaged splenium.

RMI also demonstrated partial use of OPC mechanisms following letter-by-letter reading. He often “sounded out” the initial syllables of the word. However, his impaired letter identification prevented complete reliance on OPC mechanisms to read aloud, so that he was impaired in reading both pseudowords and words. His better performance on reading regular English words and Polish words, relative to his reading of irregular words, provides further evidence that he was able to use partial information from OPC mechanisms to read some words.

RMI’s significant improvement in reading words when they were paired with either a correct picture or a semantically related picture provides direct evidence that he was able to use combined partial semantic information and partial phonological information from OPC mechanisms to read aloud words that he did not completely understand. Use of OPC mechanisms (to convert a subset of graphemes in the word) likely relied on left hemisphere regions, since it is widely agreed that the right hemisphere has minimal if any ability to carry out such phonological tasks (Coltheart, 1980; Larsen *et al.*, 2004). Although the interaction of semantic and phonological information could have taken place across hemispheres, it seems plausible that the summation of partial semantic information and partial phonological information to access lexical phonological representations for output (which are likely confined to the left hemisphere; Gazzaniga and Sperry, 1967; Zaidel and Peters, 1981) took place entirely in the left hemisphere. This account would require that at least some visual information from the right occipito-temporal regions was able to cross to the left hemisphere via the dysfunctional splenium or right-left occipital pathways elsewhere in the corpus callosum. However, we cannot rule out the possibility that some semantic processing first took place in the right hemisphere, consistent with the proposal of Coslett and Saffran (1992; Luzzati, 2002).

#### ***Access to semantics from vision: words versus pictures***

Despite impaired access to semantics (in the right or left hemisphere) from vision, RMI initially performed more accurately in naming pictures than in naming written words, indicating access to more complete semantic information from pictures than from words. One explanation of this discrepancy is that he accessed a “visual semantic system” but had a disconnection from this system to a “verbal semantic system” required for reading (Beauvois, 1982; Shallice, 1988b). However, this account would predict equally impaired oral naming of pictures, which would also require access to the verbal semantic system. Alternatively, these results are strongly predicted by the hypothesis that pictures have privileged access, relative to words, to a modality-independent semantic system, because

individual components of the picture can access individual semantic features. According to this hypothesis, the “Organized Unitary Content Hypothesis” or OUCH (Caramazza *et al.*, 1990; Hillis *et al.*, 1990), a picture of a lamp might include features like an electrical plug and light bulb that could individually access semantic features of “electrical appliance” and “for light”, even if the entire semantic representation that would be necessary for naming was not accessible. In contrast, individual visual components of written words (letters) would not have such access to components of the semantic representation. This account would explain RMI’s semantic errors in naming, as well as his better performance on naming pictures relative to words. For example, RMI called all birds “pigeons”. It is likely that features of beaks and feathers in pictures of a robin, eagle, and pelican might have individually accessed components of the semantic representation of pigeon. The fact that the advantage of pictures over words was present when he showed hypoperfusion of the splenium, but was no longer evident when he showed reperfusion of the splenium provides further evidence that his initial discrepancy between pictures and words was due to disrupted access to semantic information in the left hemisphere from right hemisphere visual areas. His residual deficit in oral reading and oral naming was likely due to the irreversible damage in left BA 37 that caused a modality-independent lexical output deficit.

In summary, detailed analysis of reading and naming performance by RMI, along with serial MRI (including perfusion-weighted imaging), provided evidence for the following proposals that are consistent with data from a variety of functional imaging and lesion studies. First, left BA 37 may have two functional roles in reading, that may be subserved by separate subregions: (1) computation of a graphemic description from visual input (a role that can be assumed by the homologous area of right BA 37 in most people); and (2) modality-independent lexical output. Secondly, this study provided evidence that incomplete semantic information accessed from vision can interact with incomplete sublexical information derived from OPC mechanisms to access lexical representations for output. Finally, RMI’s better naming of pictures than words is consistent with the proposal that picture stimuli (or objects) have privileged access to semantic information because individual components of the picture can access individual semantic features. The fact that RMI showed this discrepancy between pictures and words only when there was dysfunction of the splenium provides additional evidence for the hypothesis that his initial poorer performance with visual input (letter-by-letter reading and optic aphasia) resulted from impaired access to left hemisphere semantics from visual input to the right hemisphere.

## References

- Barolomeo P, Bachoud-Levi AC, Degos JD, Boller F. Disruption of residual reading capacity in a pure alexic patient after a mirror-image right hemispheric lesion. *Neurology* 1998; 50: 286–288.
- Beauvois MF. Optic aphasia: A process of interaction between vision and language. *Philosophical Transactions of the Royal Society of London* 1982; B 289: 35–47.
- Beeson P, Hillis AE. Comprehension and production of written words. In: R, Chapey, editor. *Language intervention strategies in aphasia and related neurogenic communication disorders*, 4th ed. Baltimore: Williams and Wilkins, 2001; 572–604.
- Beverdsorf DQ, Ratcliffe NR, Rhodes CH, Reeves AG. Pure alexia: Clinical-pathologic evidence for a lateralized visual language association cortex. *Clinical Neuropathology* 1997; 16: 328–331.
- Binder JR, Mohr JP. The topography of callosal reading pathways. A case-control analysis. *Brain* 1992; 115: 1807–1826.
- Bub D, Cancelliere A, Kertesz A. Whole-word and analytic translation of spelling-to-sound in a non-semantic reader. In: KE, Patterson, JC, Marshall, M, Coltheart, editors. *Surface Dyslexia*. London: Lawrence Erlbaum Associates Ltd., 1985.
- Caramazza A, Hillis AE. Where do semantic errors come from?. *Cortex* 1990; 26: 95–122.
- Caramazza A, Hillis AE, Rapp BC, Romani C. Multiple semantics or multiple confusions?. *Cognitive Neuropsychology* 1990; 7: 161–168.
- Chialant D, Caramazza A. Perceptual and lexical factors in a case of letter-by-letter reading. *Cognitive Neuropsychology* 1998; 15: 167–201.
- Cohen L, Dehaene S. Specialization within the ventral stream: The case for the visual word form area. *NeuroImage* 2004; 22: 466–476.
- Cohen L, Dehaene S, Naccache L, Lehéricy S, Dehaene-Lambertz G, Hénaff M-A, Michel F. The visual word form area: Spatial and temporal characterization of an initial stage of reading in normal subjects and posterior split-brain patients. *Brain* 2000; 123: 291–307.
- Cohen L, Henry C, Dehaene S, Martinaud O, Lehericy S, Lemer C, Ferrieux S. The pathophysiology of letter-by-letter reading. *Neuropsychologia* in press a.
- Cohen L, Jobert A, Le Bihan D, Dehaene S. Distinct unimodal and multimodal regions for word processing in the left temporal cortex. *NeuroImage* in press b.
- Cohen L, Lehericy S, Chochon F, Lemer C, Rivaud S, Dehaene S. Language-specific tuning of visual cortex? Functional properties of the visual word form area. *Brain* 2002; 125: 1054–1069.
- Cohen L, Martinaud O, Lemer C, Lehericy S, Samson Y, Obadia M, Slachevsky A, Dehaene S. Visual word recognition in the left and right hemispheres: anatomical and functional correlates of peripheral alexias. *Cerebral Cortex* 2003; 13: 1313–1333.
- Coltheart M. Lexical access in simple reading tasks. In: G, Underwood, editor. *Strategies of information processing*. London: Academic Press, 1978.
- Coltheart M. A right hemisphere hypothesis. In: M, Coltheart, KE, Patterson, JC, Marshall, editors. *Deep dyslexia*. London: Routledge & Kegan Paul, 1980.
- Coltheart M, Masterson J, Byng S, Prior M, Riddoch MJ. Surface dyslexia. *Quarterly Journal of Experimental Psychology* 1983; 35A: 469–495.
- Coltheart M, Patterson K, Marshall JC, editors. *Deep dyslexia*. London: Routledge & Kegan Paul, 1980.
- Coslett HB, Monsul N. Reading with the right hemisphere: Evidence from transcranial magnetic stimulation. *Brain and Language* 1994; 46: 198–211.
- Coslett HB, Saffran EM. Preserved object recognition and reading comprehension in optic aphasia. *Brain* 1989; 112: 1091–1110.
- Coslett HB, Saffran EM. Optic aphasia and the right hemisphere: A replication and extension. *Brain and Language* 1992; 43: 148–161.
- Dejerine J. Contribution à l’étude anatomo-pathologique et clinique des différentes variétés de cécité verbale. *Mémoires Société Biologique* 1892; 4: 61–90.
- Fiez JA, Balota DA, Raichle ME, Petersen SE. Effects of lexicality, frequency, and spelling-to-sound consistency on the functional anatomy of reading. *Neuron* 1999; 24: 205–218.
- Folstein MF, Folstein SE, McHugh PR. Mini-Mental State: A practical method for grading the cognitive state of patients for the clinician. *Journal of Psychiatry Research* 1975; 12: 189–198.

- Freund CS. Uber optische aphasia and seelenblindheit. *Archiv Psychiatric und Nervenkrankheiten* 1889; 20: 276–297.
- Gazzaniga MS, Sperry RW. Language after section of the cerebral commissures. *Brain* 1967; 90: 131–148.
- Geschwind N, Fusillo M. Color-naming defects in association with alexia. *Archives of Neurology* 1966; 15: 137–146.
- Goodman RA, Caramazza A. The Johns Hopkins Dyslexia Battery. The Johns Hopkins University: Baltimore, 1985.
- Hillis AE, Caramazza A. Mechanisms for accessing lexical representations for output: Evidence from a category-specific semantic deficit. *Brain and Language* 1991; 40: 106–144.
- Hillis AE, Caramazza A. Converging evidence for the interaction of semantic and sublexical phonological information in accessing lexical representations for spoken output. *Cognitive Neuropsychology* 1995a; 12: 187–227.
- Hillis AE, Caramazza A. Cognitive and neural mechanisms underlying visual and semantic processing: implications from “optic aphasia”. *Journal of Cognitive Neuroscience* 1995b; 7: 457–478.
- Hillis AE, Newhart M, Heidler J, Barker PB, Herskovits E, Degaonkar M. The roles of the “visual word form area” in reading. *NeuroImage* in press.
- Hillis AE, Rapp BC, Romani C, Caramazza A. Selective impairment of semantics in lexical processing. *Cognitive Neuropsychology* 1990; 7: 191–244.
- Hillis AE, Wityk RJ, Barker PB, Beauchamp NJ, Gailloud P, Murphy K, Cooper O, Metter EJ. Subcortical aphasia and neglect in acute stroke: the role of cortical hypoperfusion. *Brain* 2002; 125: 1094–1104.
- Howard D, Patterson KE. . The pyramids and palm trees test. Thames Valley Test Company: Bury St. Edmunds, 1992.
- Huang H, Zhang J, Jiang H, Wakana S, Miller MI, van Zijl PCM, Hillis AE, Wityk R, Mori S. DTI tractography based parcellation of white matter: Application to corpus callosum. unpublished observations.
- Larsen J, Baynes K, Swick D. Right hemisphere reading mechanisms in a global alexic patient. *Neuropsychologia* 2004; 42: 1459–1476.
- Luzzatti CG. Optic aphasia and pure alexia: Contribution of callosal disconnection syndromes to the study of lexical and semantic representation in the right hemisphere. In: E, Zaidel, M, Iacoboni, editors. *The parallel brain: The cognitive neuroscience of the corpus callosum* (Issues in Clinical Neuropsychology). Cambridge: MIT Press, 2002.
- Margolin DI, Friedrich FJ, Carlson NR. Visual agnosia-optic aphasia: Continuum or dichotomy. Paper presented at the Annual Meeting of the International Neuropsychology Society San Diego CA, 1985.
- Miozzo M, Caramazza A. Varieties of pure alexia: The case of failure to access graphemic representations. *Cognitive Neuropsychology* 1998; 15: 203–238.
- Molko N, Cohen L, Mangin JF, Chochon F, Lehericy S, Le Bihan D, et al. Visualizing the neural bases of a disconnection syndrome with diffusion tensor imaging. *Journal of Cognitive Neuroscience* 2002; 14: 629–636.
- Osterieth PA. Le test de copie d’une figure complex: contribution a l’étude de la perception et de la mémoire. *Archives de Psychology* 1944; 30: 286–356.
- Plaut D, Shallice T. Deep dyslexia: A case study of connectionist neuropsychology. *Cognitive Neuropsychology* 1993; 10: 377–500.
- Price CJ, Devlin JT. The myth of the visual word form area. *NeuroImage* 2003; 19: 473–481.
- Price CJ, Devlin JT. The pro and cons of labelling a left occipitotemporal region: “The visual word form area”. *NeuroImage* 2004; 22: 477–479.
- Riddoch MJ, Humphreys GW. Visual optic processing in optic aphasia: A case of semantic access agnosia. *Cognitive Neuropsychology* 1987; 4: 131–185.
- Saffran EM. Lexicalization in surface dyslexia. In: KE, Patterson, JC, Marshall, M, Coltheart, editors. *Surface dyslexia*. London: Lawrence Erlbaum Associates Ltd., 1985.
- Saffran EM, Coslett HB. Implicit vs letter-by-letter reading in pure alexia: A tale of two systems. *Cognitive Neuropsychology* 1998; 15(1–2): 141–165.
- Sakurai Y. Varieties of alexia from fusiform, posterior inferior temporal and posterior occipital gyrus lesions. *Behavioral Neurology* 2004; 15: 25–50.
- Sartori G, Masterson J, Job R. Direct route reading and the locus of lexical decision. In: M, Coltheart, G, Sartori, R, Job, editors. *Cognitive neuropsychology of language*. London: Lawrence Erlbaum Associates Ltd, 1987.
- Schwartz MF, Saffran E, Marin OSM. Fractioning the reading process in dementia: Evidence for word-specific print-to-sound associations. In: M, Coltheart, K, Patterson, JC, Marshall, editors. *Deep dyslexia*. London: Routledge & Kegan Paul, 1980.
- Seidenberg M, McClelland JL. A distributed, developmental model of visual word recognition and naming. *Psychological Review* 1989; 96: 523–568.
- Shallice T. From neuropsychology to mental structure. Cambridge University Press., 1988a.
- Shallice T. Specialisation within the semantic system. *Cognitive Neuropsychology* 1988b; 5: 133–142.
- Shallice T. Multiple semantics: Whose confusions?. *Cognitive Neuropsychology* 1993; 10: 251–261.
- Shallice T, Saffran E. Lexical processing in the absence of explicit word identification: Evidence from a letter-by-letter reader. *Cognitive Neuropsychology* 1986; 3: 429–458.
- Wityk R, Hillis AE, Beauchamp N, Barker PB, Rigamonti D. Perfusion-weighted MRI in adult moyamoya syndrome: characteristic patterns and change after surgical intervention: case report. *Neurosurgery* 2002; 51: 1499–1506.
- Zaidel E, Peters AM. Phonological encoding and ideographic reading by the disconnected right hemisphere: Two case studies. *Brain and Language* 1981; 14: 205–234.