

TIAs in a Spontaneously Dissecting Aneurysm of the Internal Carotid Artery—A Case Report

Shuzo Shintani, M.D.*
Tatsuo Shiigai, M.D.**
Shin Tsuruoka, M.D.†
and
Hiroshi Tsukagoshi, M.D.‡

IBARAKI and TOKYO, JAPAN

Abstract

A spontaneous internal carotid artery dissection of an aneurysmal form is reported. The patient, a fifty-eight-year-old man, had manifested recurrent transient left hemiparesis, dysesthesia of the left upper limb, and dysarthria for three months. After administration of ticlopidine, the transient ischemic attacks completely disappeared. Three months later, the follow-up angiographic study revealed the same form of dissection in the same portion as compared with the initial study. Conservative therapy was successful.

Introduction

Since Jentzer¹ reported a case of a spontaneously dissecting aneurysm of the internal carotid artery (ICA) in 1954, an increasingly large number of reports have found a higher incidence than had initially been thought.¹⁻⁵ We encountered a spontaneous ICA dissection of an aneurysmal form, and three months later a follow-up angiographic study was done. The clinical symptoms, serial angiographic studies, and the management of this condition are discussed.

CASE REPORT

A fifty-eight-year-old man had manifested recurrent transient left hemiparesis, dysesthesia of the left upper limb, and dysarthria since April, 1990. He suffered from these transient ischemic attacks (TIAs) several times a day and was admitted to our hospital on June 20, 1990.

He had no history of head trauma but did have a history of hypertension for several years. On admission, physical and neurologic examinations revealed no abnormalities except for

From the Departments of *Neurology, **Internal Medicine, and †Neurosurgery, Toride Kyodo General Hospital, Ibaraki, Japan; and the ‡Department of Neurology, Tokyo Medical and Dental University, Tokyo, Japan

mild hypertension (blood pressure was 160/90 mmHg). Results of the laboratory examinations were as follows: Blood cell counts indicated $471 \times 10^4/\text{mm}^3$ of red blood cells (RBCs), 12.9 g/dL of hemoglobin, 40.4% hematocrit, $23.9 \times 10^4/\text{mm}^3$ of platelets, and $7900/\text{mm}^3$ of leukocytes. Urinalysis gave normal results. Serum biochemical analysis results were normal except for 328 mg/dL of triglyceride (TG)(normal values: between 30 and 150 mg/dL). A chest x-ray revealed no abnormality with the exception of 59% cardiothoracic ratio (CTR). ECG showed ST depression in I, II, aVL, aVF, and giant negative T with ST depression in V_5 - V_6 leads. Cardioultrasonography revealed a marked concentric left ventricular hypertrophy (LVH). EEG and brain single photon emission computed tomography (SPECT) appeared normal. Brain computed tomography (CT) showed calcifications of the bilateral basal ganglia and a small low-density lesion beside the right lateral ventricle (Fig. 1.A.B.).

Right carotid angiography by transbrachial method revealed an ICA dissection of an aneurysmal form in the near portion of the bifurcation of the common carotid artery (CCA) (Fig. 2). After administration of ticlopidine, 200 mg daily, the TIAs completely disappeared.

Three months later, he was readmitted to our hospital, and the follow-up angiographic study was done on September 10, 1990. The right carotid angiography showed the same form of dissection in the same portion as compared with the initial study of three months before (Fig. 3).

Discussion

We studied repeat angiography of an ICA dissection. The follow-up study revealed no progressive dissection of ICA, and an expansion of the aneurysm was not seen. Administration of ticlopidine was effective in preventing the recurrent TIAs. Conservative therapy was successful.

The point of view in the present case is the morphologic feature of the dissection. The carotid angiograms in our case showed the simple aneurysmal dilatation of ICA with double contour (Figs. 2,3). Segmental stenoses or fusiform and saccular aneurysms were not seen. The simple aneurysmal dilatation type of dissection without stenosis above and below is rare in the previously reported spontaneous ICA dissections. Sellier et al reported 46 cases of spontaneous dissection of the internal carotid artery⁶; 33 cases were stenotic form dissections in the angiographic features. The other 13 cases were aneurysmal form dissections, which included 8

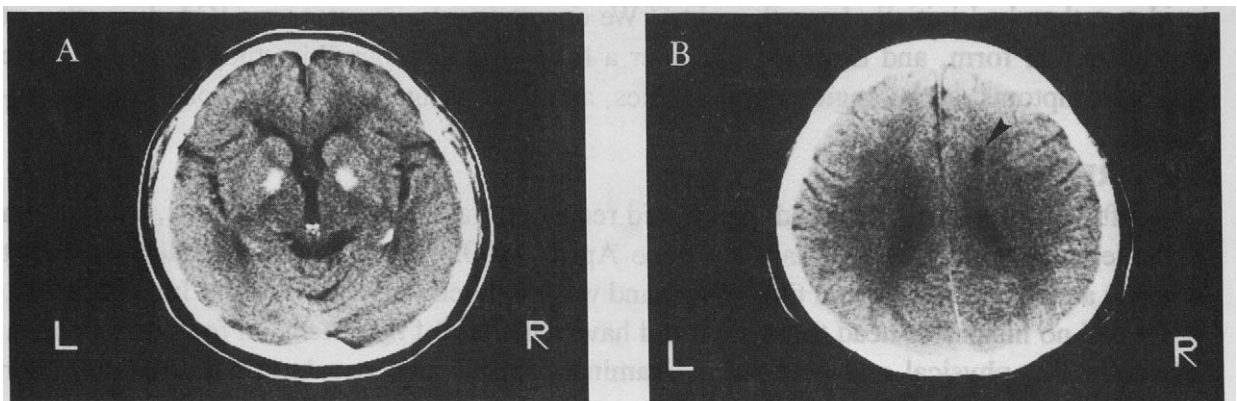


FIG. 1.A.B. Brain CT showed the bilateral calcifications of the basal ganglia and a small low density lesion (arrow head) beside the right lateral ventricle.

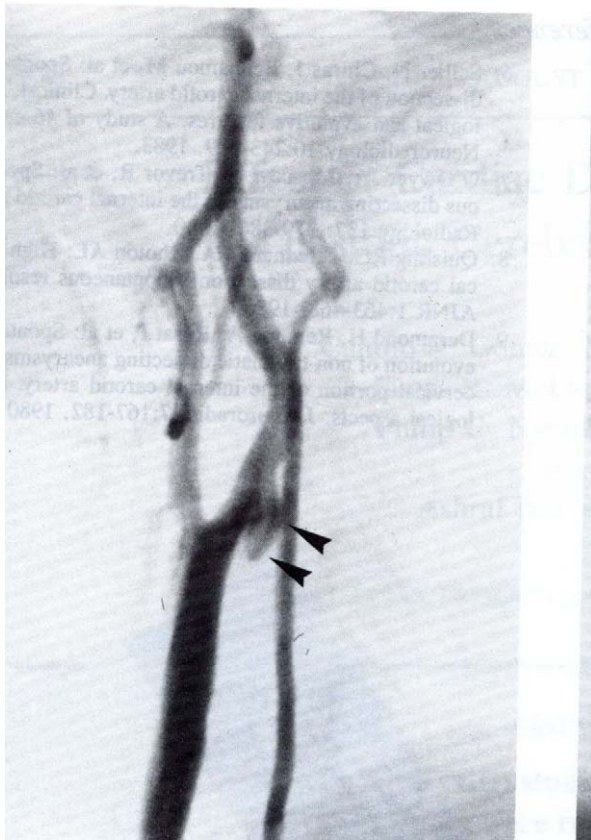


FIG. 2. Serial right carotid angiogram showing a simple aneurysmal dilatation with double contour in the near portion of the bifurcation of the common carotid artery (arrow heads). Neither segmental stenoses nor string signs were seen.

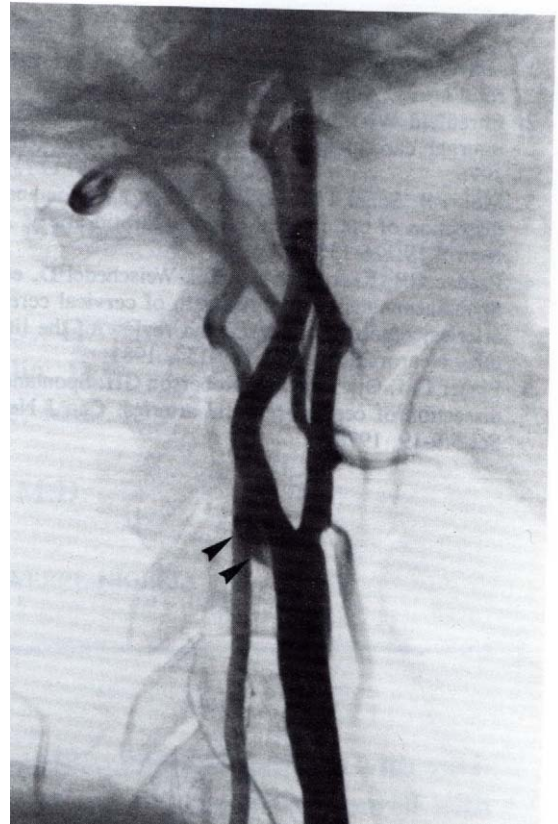


FIG. 3. Repeat arteriography three months later: The simple aneurysmal dilatation of the carotid artery (arrow heads) neither dissected nor expanded as compared with the initial study of three months before.

cases of wide-base saccular aneurysm, 4 cases of fusiform aneurysm, and only 1 case of simple aneurysmal dilatation with double contour. The ICA dissection of simple aneurysmal dilatation without segmental stenoses was seen in only 1 case out of the 46 cases.

Conclusions

The lesions detected by arteriography usually regress under medical treatment, such as with anticoagulants, platelet inhibitors, and so on.⁶ Surgery should be reserved to progressively dissecting aneurysms and to patients who do not respond to anticoagulants or platelet inhibitors. The administration of platelet inhibitor, ticlopidine 200 mg daily, was effective in our case. The TIAs have completely disappeared after the administration. Some authors have recommended repeat arteriography after two or three months^{7,8} or even earlier⁹ in order to decide the indication for surgical operation. We studied the repeat angiography three months later, and the angiography showed neither enlargement of the aneurysm nor stenosis of ICA.

*S. Shintani, M.D.
Department of Neurology
Toride Kyodo General Hospital
5901-1 Terada, Toride City
302 Ibaraki, Japan*

References

1. Jentzer A: Dissecting aneurysm of the left internal carotid artery. *Angiology* 5:232-234, 1954.
2. Ehrenfeld WK, Wylie EJ: Spontaneous dissection of internal carotid artery. *Arch Surg* 111:1294-1301, 1976.
3. Mokri B, Sundt TM, Houser OW, et al: Spontaneous dissection of the cervical internal carotid artery. *Ann Neurol* 19:126-138, 1986.
4. Bradac GB, Kaernbach A, Bolk-Weischedel D, et al: Spontaneous dissecting aneurysm of cervical cerebral arteries; report of six cases and review of the literature. *Neuroradiology* 21:149-154, 1981.
5. Fisher CM, Ojemann RG, Roberson GH: Spontaneous dissection of cervico-cerebral arteries. *Can J Neurol Sci* 5:9-19, 1978.
6. Sellier N, Chiras J, Benhamou M, et al: Spontaneous dissection of the internal carotid artery. Clinical, radiological and evolutive features. A study of 46 cases. *J Neuroradiology* 10:243-259, 1983.
7. O'Dwyer JA, Moscow N, Trevor R, et al: Spontaneous dissecting aneurysms of the internal carotid artery. *Radiology* 137: 379-386, 1980.
8. Quisling RG, Friedman WA, Rhoton AL: High cervical carotid artery dissection: Spontaneous resolution. *AJNR* 1:463-468, 1980.
9. Deramond H, Remond A, Rosat P, et al: Spontaneous evolution of non-traumatic dissecting aneurysms of the cervical portion of the internal carotid artery. Radiological aspects. *J Neuroradiol* 7:167-182, 1980.